3/1061

187

DONALD FERRIER
Medical Bookseller
8, 9, 10 & 18 TEVIOT PLACE
EDINBURGH

DR. A. K. Lal

Lar bert.

Lal

'61


Digitized by the Internet Archive
in 2026

https://archive.org/details/companiontomanua0000ebja_p9r9

A COMPANION TO MANUALS OF PRACTICAL ANATOMY

BY

E. B. JAMIESON, M.D.

Formerly Senior Demonstrator and Lecturer on Anatomy
University of Edinburgh

SEVENTH EDITION

LONDON
OXFORD UNIVERSITY PRESS

NEW YORK TORONTO

Oxford University Press, Amen House, London E.C.4

GLASGOW NEW YORK TORONTO MELBOURNE WELLINGTON
BOMBAY CALCUTTA MADRAS KARACHI
CAPE TOWN IBADAN NAIROBI ACCRA KUALA LUMPUR

First edition 1913
Reprinted 1914, 1915, 1918, 1919 *and* 1920
Second edition 1925
Reprinted 1928 *and* 1931
Third edition 1932
Fourth edition 1935
Reprinted 1938
Fifth edition 1942
Sixth edition 1945
Reprinted 1947 *and* 1949
Seventh edition 1950
Reprinted 1952, 1954, 1957 *and* 1961

PRINTED IN GREAT BRITAIN

DEDICATED

TO

SIR WILLIAM TURNER, K.C.B., F.R.S.

WHOSE STIMULATING TEACHING ALWAYS

MADE ANATOMY AN

INTERESTING

STUDY

PREFACE TO THE SEVENTH EDITION

This book was begun in 1911 at the request of the late Mr. J. Keogh Murphy, F.R.C.S., who was then the Medical Editor of the Oxford University Press. It was meant "to provide, in an easily portable form, an account of naked-eye Anatomy expressed in terms of the Basle nomenclature".

The structures were described under their Systems, for both Mr. Keogh Murphy and the late Professor Arthur Robinson (who was my guide and counsellor) preferred that method. But the more crowded regions were dealt with topographically also; and I included such things as the movements in Swallowing, the relations of the Joints, the relation of Articular Capsules to Epiphyseal Lines, and the relations of the chief structure in the "no man's land" of each Boundary Region.

Throughout, relative positions were given fairly fully—perhaps rather more so than had been customary. As structures vary in different bodies, I examined many specimens in order to estimate what was probably the most common arrangement; and I was at some pains to harmonise the accounts of relations.

At the end of the book (against the counsel of my advisers) I added a compressed account of Development.

To include all this matter and keep the size of the book within the prescribed bounds, I employed very condensed language and made frequent use of contractions.

The *first* edition was published in 1913; and, after several reprints, it was followed by the *second* edition in 1925. In that edition several changes were made:—The division of the Abdomen into artificial regions was omitted; the section on the Lymphatic System was re-written; the account of the Tracts of Nerve-fibres was re-arranged; alterations were made in the chapters on Development, Ductless Glands and the Urogenital Apparatus, and new matter was included in them; and brief descriptions of Bone-marrow, Paraganglia and the Autonomic Nervous System were added.

The *third* edition appeared in 1932, and in it the whole text was drastically revised. Many parts were re-written—and even whole sections, including those on the Perineum, the Heart and Pericardium, the Fœtal Circulation, the Central Nervous System, and certain viscera such as the Liver. This was largely the result of longer practice in teaching and was chiefly an endeavour to make the text more explanatory and more easily read, but it was partly due to the insertion of new matter, especially in the Nervous System. In that system, further, I described the Brain from above downwards, in the belief that the student can follow the narrative better than is possible when it is described from below upwards. In preparing the

third edition, I gained much from consultations with a former pupil and colleague—Professor T. B. Johnston, who was then in Guy's Hospital.

In 1928, the Anatomical Society appointed a sub-committee of three—Professor T. B. Johnston, the late Professor A. Francis Dixon and myself—to revise the Basle Nomina Anatomica; and in 1933, at Birmingham, the Society approved of our revised version. In the *fourth* edition (1935), the text was altered to fit this "Birmingham Revision" of the nomenclature (B.R.); and the *fourth* edition underwent very little other change.

The only new matter in the *fifth* edition (1942) was a short description of the Pterygo-mandibular Ligament (accidentally omitted in previous editions) and a description of the origin, circulation and functions of the Cerebro-spinal Fluid. But there was a great alteration in the arrangement. A large part of the text was re-cast and put into "regional" form, and only a brief outline of the course and distribution of Vessels and Nerves was left in their "systematic" description. This was done in order that the book might have a better claim to its title of *A Companion to Manuals of Practical Anatomy* and because I had come to think that that was the better plan. This re-arrangement seems to have been justified by the rapidity with which the fifth edition and all subsequent impressions ran out of print.

In the *sixth* edition and in this edition—the **Seventh**—there has been no change in scope or in general arrangement, and no change in substance beyond small excisions and additions here and there.

But in these two editions, as in all editions after the first, I have lessened the condensation and tried to make the text more easily read; and I have seen cause in some places to break up paragraphs and to alter the phraseology in order to make statements more emphatic and more likely to be remembered.

The alterations and additions have increased the number of pages from 519 in the *first* edition to 715 in the *sixth* and *seventh*—the biggest increases being 92 pages in the *third* and 75 in the *fifth*.

During the war and after the war, various impediments coupled with rapid exhaustion of printed copies have created regrettable gaps between the issues from the *fourth* edition onwards; and, as the latest reprint of the *sixth* edition was bespoken before it came from the binders, there is a gap between issues again.

As a conclusion, I should like to thank reviewers for their friendly notices—especially the younger reviewers of the later editions, for they had obviously used a previous edition for study, and the favourable opinion expressed by them is therefore very comforting.

E. B. J.

April, 1950.

CONTENTS

	PAGE
Osteology	1
Arthrology	115
Muscles and Fasciæ	161
Blood-Vascular System	405
Lymphatic System	455
Neurology	461
Brain	462
Spinal Cord	542
Spinal Nerves	554
Cranial Nerves	568
Autonomic Nervous System	575
Organs of the Senses	581
Respiratory System	593
Digestive System	614
Urogenital System	654
Urinary Organs	654
Male Genital Organs	661
Female Genital Organs	668
Ductless Glands	673
Development	680
Index	717

A
COMPANION
TO
ANUALS OF PRACTICAL ANATOMY

OSTEOLOGY

THE **vertebrate skeleton** is divisible into: (1) an **exo-skeleton,** comprising hair, feathers, scales, armour-plates, nails, teeth, etc.; (2) an **endo-skeleton,** comprising bones with their cartilages and ligaments; (3) a **splanchnic skeleton,** which may be included in endo-skeleton, and comprises the cartilages of larynx, trachea and bronchi, and the os cordis and os penis of certain mammals.

The **endo-skeleton** is the framework of the body, and accounts for about one-seventh of the body-weight. It is divided into an **axial skeleton,** which belongs to head, neck and trunk, and an **appendicular skeleton,** which belongs to the limbs. The bones and the costal cartilages of the endo-skeleton are dealt with under Osteology.

Uses of Bones.—1. They give lasting form to the body.

2. They provide attachments and support for muscles, tendons, ligaments, fibrous membranes and fasciæ.

3. They articulate with one another to form joints and are the passive levers in the movements at joints; and by means of them precision is given to movements.

4. They protect organs in the cavities of the body.

5. The marrow in them is a blood-forming organ.

Classification.—1. **Long bones,** each possessing a shaft and two ends, *e.g.*, the femur. Metacarpals, metatarsals and phalanges are *miniature long bones.*

2. **Short bones,** *e.g.*, carpal and tarsal bones. *Sesamoid bones* are short bones in tendons.

3. **Flat bones,** *e.g.*, scapula, parietal bone of skull, ribs.

4. **Irregular bones,** *e.g.*, vertebræ.

5. **Pneumatic bones** are certain bones of the skull, *e.g.*, maxilla, which contain air-spaces or sinuses that communicate directly or indirectly with the nasal cavity.

Characters.—Bone is the hardest and most enduring tissue in the body, except the enamel of the teeth; it is elastic, and very strong—almost as strong as cast iron, about twice the strength of oak.

The osseous tissue on the surface of a bone is dense and hard, and is called **compact bone.** The tissue in the interior also is hard, but contains numerous spaces, like a sponge, and it is called **spongy bone.** The spongy substance is arranged in planes adapted to withstand strain and stress; and the spaces are filled with **red marrow.**

Short bones and the bulky parts of irregular bones consist of spongy tissue encased in a shell of compact tissue.

Flat bones and the thinner parts of irregular bones consist of two plates or **tables** of compact tissue separated by a thin layer of spongy tissue. In flat *skull-bones* the outer table is thick; the inner table is thin, dense and brittle. Spongy tissue appears between the tables after the 5th or 6th year and is called the **diploë.**

The *ends* of long bones consist of spongy bone enclosed in a thin crust of compact bone. They are expanded in order:—

1. To provide a larger articular surface, thus reducing the risk of disarticulation and facilitating accuracy of movement.

2. To diffuse shocks received at the joint.

3. To provide a larger area for muscular attachments.

The *shaft* of a long bone is a hollow cylinder, consisting of a thick wall of compact tissue lined with some wide-spaced spongy tissue, and enclosing a **medullary cavity,** which is filled with **yellow marrow.** The shaft is always curved, and usually in more than one plane. This adds to its strength and resistance, which are further ensured by the greater thickness of the compact tissue on the concave sides of the curves. The presence of a cavity makes the bone lighter, with very little diminution of the strength and stability.

Except in skull-bones, the articular surfaces are coated with permanent **articular cartilage**; but in the preparation of specimens used in reading that cartilage has been removed. The non-articular parts present ridges and tubercles for tendons and ligaments, and flatter areas for fleshy attachments.

Bones are covered with a vascular fibrous membrane called **periosteum.** Vessels from the periosteum enter the bone through small foramina on the surface. The **nutrient artery** and **vein,** though small, are the most constant in position. They enter the shaft of a long bone through the **nutrient foramen** to reach the yellow marrow.

Articular cartilage has no membranous covering except at its edges, but other cartilages, *e.g.*, costal cartilages, have a similar vascular covering called **perichondrium.**

Medullary cavity of a long bone and the spaces in spongy bone are lined with membrane called **endosteum.**

Development.—Bones are developed from mesoderm. A condensation of mesodermic tissue takes place to form a **membranous "bone".** In some regions, *e.g.*, vault of cranium, ossification occurs in this membrane. In most situations, chondrification of the membrane-bone takes place before ossification begins, and a **cartilage "bone"** is formed. In any bone, a point at which bony tissue begins to form is called a **centre of ossification.** One or more such **centres** appear in the cartilaginous model, and it is converted into bone proper.

Centres which first appear are called **primary centres.** They appear usually before birth. The part of a bone formed from a primary centre is called the **diaphysis.** In a long bone, this is the shaft. **Secondary** or **epiphyseal centres** appear usually after birth. Parts of bones formed from secondary centres are called **epiphyses.** The unossified plate of cartilage between an epiphysis and the diaphysis is called the **epiphyseal cartilage.** It unites the epiphysis and diaphysis, and the union is a **primary cartilaginous joint.** The position of the edge of the epiphyseal cartilage, on the surface of the bone, is called the **epiphyseal line.**

Ossification and growth take place continually at the surfaces of the epiphyseal cartilage, until the cartilage disappears and the epiphysis joins the diaphysis, and then

growth, in the direction at right angles to the surface of cartilage, ceases. Ossification never spreads into the superficial layers of articular cartilage. Osseous tissue formed in cartilage is all destroyed during the process of growth of the bone, and is replaced by bone formed in the deeper layers of the periosteum.

In a long bone, increase in length takes place by proliferation of cells of epiphyseal cartilage and of the deep layers of the articular cartilage, followed by the preliminary ossification. Increase in girth takes place by deposition of bone under the periosteum.

In a long bone, the epiphysis whose centre appears last is the first to join the diaphysis, except in the fibula.

The nutrient artery is directed towards the epiphysis which joins first. In long bones with only one epiphysis, *e.g.*, clavicle, the artery is directed towards the end which has no epiphysis; and the epiphysis is at the more movable end of the bone.

When an epiphysis has more than one centre, *e.g.*, upper end of humerus, these centres coalesce before the epiphysis joins the diaphysis.

AXIAL SKELETON

Vertebral column	Skull, including mandible
Ribs and costal cartilages	Hyoid bone
Sternum	Auditory ossicles

APPENDICULAR SKELETON

Upper Limb		Lower Limb	
Shoulder-girdle	Clavicle, Scapula	Pelvic-girdle	= Hip-bone
Upper arm	Humerus	Thigh	Femur, (Patella)
Forearm	Radius, Ulna	Leg	Tibia, Fibula
Wrist	8 Carpal bones	Foot	7 Tarsal bones, 5 Metatarsal bones
Palm	5 Metacarpal bones	Digits	Big toe, 2 phalanges; Other toes, 3 phalanges each
Digits	Thumb, 2 phalanges; Fingers, 3 phalanges each	Sesamoid bones	
Sesamoid bones			

Definitions

Alveolus, a deep, narrow pit.
Antrum, a cavity.

Condyle, a smooth, rounded articular eminence.
Distal, applied to limbs, means farther away from root of limb.
Epicondyle, a prominence above an articular surface.
External, farther away from centre of a cavity or an organ.
Fossa, a broad depression, usually shallow.
Fovea, a small shallow depression.
Hamulus, a hook-shaped process.
Hiatus, a slit or a gap.
Incisura, a notch.
Internal, nearer the centre of a cavity or an organ.
Lamella or **Lamina,** a thin plate or sheet.
Lateral, farther away from median plane.
Meatus, a short canal.
Medial, nearer median plane.
Median plane is the antero-posterior or dorso-ventral plane that divides the body into a right and a left half.
Planum, a flat surface.
Processus or **process,** any kind of projection.
Proximal, applied to limbs, means nearer root of limb.
Sinus (1), a cavity in a bone.
(2), a venous blood-channel without muscular walls.
(3), a venous blood-space in an organ.
(4), a cavity within a viscus.
(5), a narrow space lined with serous or mucous membrane.
Spina or **Spine,** a sharp, pointed process.
Sulcus, a groove or furrow.
Trochlea, a pulley or a pulley-shaped surface.
Tuber, tuberculum / **Tubercle, tuberosity** } a rounded eminence, usually rough.

VERTEBRAL COLUMN

33 **vertebræ** grouped according to regions :—
Movable or **true** : 7 cervical, 12 thoracic, 5 lumbar.
Fixed or **false** : 5 sacral, fused in adult to form **sacrum** ; 4 (3 to 5) coccygeal, fused to form **coccyx**.
Common features are seen best in mid-thoracic region.

Parts of a vertebra: (1) **Body** is the bulky part in front, and it varies in size and shape in different regions. *Superior* and *inferior surfaces,* slightly concave and attached to intervertebral discs. *Anterior surface,* convex from side to side ; *posterior surface,* slightly concave from side to side.

(2) **Pedicles** are a pair of horizontal bars that jut backwards from upper part of back of body ; borders are concave, and form floors of (3) **superior** and **inferior vertebral notches,** of which the inferior is the deeper and wider.

(4) **Laminæ** are a pair of broad, flat, sloping plates, joined to each other at median plane, and to the pedicles

laterally. Their borders and internal surfaces are rough for attachments of ligamenta flava.

(5) Pedicles and laminæ together form the **vertebral arch.**

(6) **Vertebral foramen** is bounded by the vertebral arch and the back of the body.

(7) **Spine** extends backwards from junction of laminæ.

(8) **Transverse process** stands out from the junction of the pedicle and the lamina.

(9) **Articular processes, superior** and **inferior,** jut upwards and downwards from the junction of pedicle and lamina, and have smooth surfaces for articulation with articular processes of contiguous vertebræ. The superior pair are farther forward than the inferior.

When vertebræ are placed together, the vertebral foramina form the **vertebral canal,** for the lodgment and protection of the spinal cord and its membranes ; and the vertebral notches, assisted by articular processes, bodies and discs, form a series of **intervertebral foramina,** for the transmission of spinal nerves and vessels.

CERVICAL VERTEBRÆ

Special Characters.—*Small size ; irregular outline ; three foramina*—a small one in each transverse process, and the vertebral foramen in the middle.

Typical Cervical Vertebra.—**Body:** small ; but is wide transversely.

Pedicles : short and rounded.

Laminæ : long, narrow, sloping.

Vertebral foramen : large ; triangular or semilunar.

Spine : short, bifid.

Transverse process : short ; encloses foramen ; is bifid, ending in two **tubercles—anterior** and **posterior.**

Articular facets of **articular processes** are nearly circular.

Upper surface of **body** is concave from side to side, convex dorso-ventrally ; rounded off anteriorly, raised up at sides. *Lower surface* is correspondingly concavo-convex. *Anterior surface* is slightly elevated in the middle, slightly hollowed out on each side. *Posterior surface* is flat. *Lateral surface* is fused with transverse process and pedicle ; and it helps to bound transverse foramen.

Pedicle springs from the dorso-lateral part of the body. It is directed backwards and sidewards ; and its **vertebral notches** are nearly equal in depth.

Vertebral foramen is larger than in thoracic or lumbar regions.

Spine, compressed vertically, points backwards and downwards.

Transverse process extends sidewards and slightly forwards and downwards. Has two parts: (1) posterior part—the *true transverse process*—springs from vertebral arch; (2) anterior part — the *homologue of a rib*—is attached to the side of the body. The two parts are united laterally by **costo-transverse lamella,** and enclose **foramen transversarium.** Bifid, free end terminates in **anterior** and **posterior tubercles.** These are separated by upper surface of costo-transverse lamella, which is grooved to support the anterior primary ramus of a cervical nerve. Anterior tubercle in 6th vertebra is sometimes enlarged, and is called **carotid tubercle** because the common carotid artery can be compressed against it.

Foramen transversarium is bounded by the parts of the transverse process, and by pedicle and side of body. In upper 6 vertebræ it transmits vertebral artery and plexus of veins, and sympathetic plexus from inferior cervical ganglion.

Articular processes assist bodies in supporting weight of head. Articulating surfaces of *superior pair* look upwards and backwards; of *inferior pair*, downwards and forwards.

Typical cervical vertebræ—3rd, 4th, 5th, 6th—of any one skeleton can be distinguished from one another. Costo-transverse lamella in 3 and 4 is oblique. It is more oblique in 3 than in 4, and vertical depth of side of body is greater in 3. The lamella is horizontal in 5 and 6; and 6 often has an enlarged "carotid tubercle".

Special Cervical Vertebræ.—First vertebra or **Atlas** has no body and no spine. Its parts are a pair of **lateral masses** united by an **anterior arch** and a **posterior arch.**

Anterior arch has a circular facet on its posterior surface for articulation with odontoid process of second vertebra; and a small **anterior tubercle** on its anterior surface for the attachment of ligaments.

Posterior arch is much longer than anterior. It has a groove for vertebral artery and first cervical nerve on its upper surface, near lateral mass; and a small **posterior tubercle** on its posterior surface, in median plane.

Upper surface of lateral mass is elongated and concave, and articulates with occipital condyle; lower surface, nearly circular, articulates with upper facet of second vertebra; medial surface presents a tubercle for the attachment of the transverse ligament.

Transverse process juts out from lateral side of lateral mass. It is not bifid; it is large, to provide leverage

for the muscles that rotate the head; and it may be felt in the space behind mandible, below the auricle.

Lateral masses are closer together in front than behind.

Superior articular surface is oval, looks upwards and medially; often notched at the sides. **Inferior articular surface** is slightly concave and looks downwards and medially.

Rectus capitis anterior arises from anterior surface of mass; and accessory ligament of atlanto-axial joint is attached to postero-medial aspect. Transverse ligament crosses the ring and divides it into small anterior compartment for odontoid process, and larger posterior compartment for spinal cord and its membranes.

Transverse process gives attachment to rectus lateralis, obliquus superior and inferior, levator scapulæ, scalenus medius and splenius cervicis. Its anterior tubercle is absent; but its posterior tubercle is often divided into two.

Anterior arch joins the antero-medial part of each mass. Ant. atlanto-occipital membrane is attached to its upper border, and ant. longitudinal lig. and longus cervicis to its **anterior tubercle.**

Posterior arch, tilted upwards posteriorly, is continuous with the back of the mass and with posterior root of transverse process. Posterior atlanto-occipital membrane is attached to upper border, and lig. flava to lower border. Groove on upper surface is overhung by tubercle on back of mass. This tubercle is sometimes sufficiently developed to convert the groove into a canal. **Posterior tubercle,** at median plane, represents the spine, and gives origin to the right and left rectus posterior minor.

Second Cervical Vertebra or **Axis.**—Recognised by the tooth-like **odontoid process** that stands up from its upper surface. The front of this process is faceted for the anterior arch of atlas; and the back is grooved by the transverse ligament of atlas.

Spine is stout, broad, bifid, and can be felt about two inches below the external occipital protuberance.

Transverse process is small and not bifid.

Body: Elevation on the front juts down as a lip.

Odontoid process represents body of atlas; its apex is blunt, and the apical and alar ligaments are attached to it.

Pedicles: Hidden under upper articular surfaces; deeply grooved below.

Laminæ are thick and prismatic.

Spine is the broadest of the cervical series (for muscular attachments), and it is deeply grooved on its under surface.

Superior articular processes are on pedicles and anterior roots of transverse processes, and slightly on body. Weight of head is

transmitted through them to vertebral column. They are nearly circular, slightly convex; look upwards and a little sidewards; are grooved inferiorly by foramina transversaria. Behind each there is a groove for second cervical nerve. (1st and 2nd cervical nerves, unlike others, are behind articular surfaces.)

Inferior articular processes resemble others of the cervical region.

Transverse process: Not bifid; small; turned downwards and backwards. Its foramen is directed upwards and sidewards.

Seventh cervical vertebra has a longer **spine** than any other cervical vertebra; the tip of the spine is the upper knob at the root of the back of the neck.

End of **spine** is broad and not bifid. **Transverse process** is large and broad; its anterior tubercle is small or absent; its costal element may form a separate **cervical rib. Foramen transversarium** is small and transmits a vertebral vein (when there are two).

THORACIC VERTEBRÆ

Special Characters.—*Facets on sides of bodies for heads of ribs, and facets on most transverse processes for tubercles of ribs.* Each thoracic vertebra articulates with rib with which it is in numerical correspondence; and bodies of upper 8 or 9 articulate each with rib below, as well.

Typical Vertebra.—**Body** is heart-shaped. Deeper behind than in front, owing to curve of column. **Costal facets, superior** and **inferior**, are demi-facets on upper and lower margins of posterior part of side of body.

Pedicles are short.

Laminæ: Broad and flat; overlap the laminæ below.

Vertebral foramen: Nearly circular. Small, because there is less movement in the thoracic region and less risk therefore of compression of spinal cord.

Spine is long, sloping and slender.

Transverse process is thick. Its free end is expanded and bears, on anterior surface, a facet for articulation with tubercle of rib of corresponding number.

Articular surfaces of **articular processes** are nearly flat; those on superior pair are directed mainly backwards, on inferior pair, mainly forwards.

Upper and *lower surfaces* of **body** are nearly flat. *Anterior surface* is very convex from side to side, slightly concave from above downwards. *Posterior surface* is concave from side to side, and flat from above downwards. In upper and lower members the shape of body resembles that of cervical and lumbar, respectively. Superior

costal facet is larger than inferior, and, with inferior facet of vertebra above and intervening disc, it forms articular cavity for head of rib.

Pedicle is directed backwards and is flattened from side to side. It is attached close to the upper margin of the body; therefore the upper **vertebral notch** is shallow, and the lower is deep.

Spine tapers to a tuberculated free end; is triangular on section; very oblique (almost vertical) in the middle of the series, shorter and much less oblique in the upper and lower members.

Transverse processes are directed sidewards, backwards and a little upwards; their facets look forwards, sidewards and upwards.

Upper articular processes look slightly up and sidewards as well as backwards. **Lower** look in the opposite direction; partly fused with laminæ.

SPECIAL THORACIC VERTEBRÆ.—First: body resembles that of 7th cervical in outline, and has a whole facet and a half facet on each side. Whole facet is for first rib, which articulates with only one vertebra. Spine is nearly horizontal; easily seen and felt in the living person; even more prominent than 7th cervical.

Ninth may conform to type (in which case the costal facet on 10th is incomplete); or it may lack inferior facet.

Tenth, eleventh and **twelfth** have each only one facet on side of body, and it encroaches on pedicle.

10th is recognised by facet on its transverse process.

11th is distinguished from 10th by absence of this facet, and from 12th by articular processes, which look in typical direction.

12th has its transverse process replaced by *superior, inferior* and *lateral tubercles*, homologous with mamillary process, and with accessory and small part of transverse process of lumbar vertebra, respectively; and its inferior articular surfaces are convex, and directed sidewards and forwards, like those of a lumbar vertebra.

LUMBAR VERTEBRÆ

Distinguished chiefly by large size; and by absence of costal facets and of foramen in transverse process.

Common Characters.—Body is large and reniform.

Pedicles are short and stout.

Laminæ: Thick; separated from those below by a gap near median plane, widest between 4th and 5th.

Vertebral foramen is large and triangular.

Spine is almost horizontal; large, broad and hatchet-shaped, with thickened posterior border.

Transverse process is long, slender, spatula-shaped.

Articular processes are large. *Upper pair*: concave; look mainly medially. *Lower pair*: convex; look laterally.

Upper and *lower surfaces* **of body** are nearly flat; *anterior surface* is convex from side to side, concave from above downwards; *posterior surface* is slightly concave in both directions.

Pedicles are directed backwards from near upper part of body; therefore, superior **vertebral notch** is shallow, inferior is deep.

Laminæ: Broad from above donwwards, and nearly vertical.

Transverse processes are homologous with ribs. Extend sidewards and backwards; on back of base of each there is a small tubercle, called **accessory process.**

Articular processes: **Upper** pair look slightly backwards as well as medially; and they embrace the lower processes of the vertebra above. Rounded tubercle on posterior edge is called a **mamillary process.** **Lower** pair look forwards as well as sidewards; are on the lower and lateral parts of laminæ; and are closer together than the upper pair.

SPECIAL CHARACTERS.—Posterior surface of body of **first** is often deeper than anterior; in **second,** they are of equal depth. Transverse process of **third** is usually the longest, and encroaches on pedicle; and anterior surface of body is deeper than posterior. Anterior surface of body of **fourth** is deeper than posterior; transverse process encroaches on pedicle and may reach body; inferior articular processes are as wide apart as the superior.

FIFTH LUMBAR VERTEBRA is the largest of all vertebræ. Anterior surface of **body** is much deeper than posterior. **Pedicles** run sidewards and backwards. **Transverse process** is short, stout and pyramidal, its base encroaching well on to body. **Spine** is short, and rounded at free end. **Superior articular processes** look more backwards and less medially than in other L. vertebræ; **inferior articular processes** are farther apart than superior, and look more forwards and less sidewards than in other lumbar vertebræ.

Muscles and Ligaments attached to Vertebræ

BODIES—

Longus cervicis. 2nd-7th C., 1st-3rd TH.
Psoas minor. 12th TH., 1st L.
Psoas major. 12th TH., 1st-5th L.
Longitudinal ligs.—anterior and posterior. 2nd C. to sacrum.
Capsular ligaments of small joints at sides of cervical bodies.
Capsular and radiate ligs. of heads of ribs. 1st-12th TH.
Medial arcuate lig. 2nd L.

LAMINÆ—

Ligamenta flava. ALL.
Rotatores. 1st-11th TH.

ARTICULAR PROCESSES—

Longissimus capitis. 4th-7th C.
Semispinalis ,, ,, ,,
,, cervicis. ,, ,,
Multifidus. ,, ,, 1st-5th L.
Capsular ligaments. ALL.

TRANSVERSE PROCESSES—

Rectus capitis lateralis. 1st C.
Obliquus capitis superior. 1st C.
,, ,, inferior. ,,
Levator scapulæ. 1st-4th C.
Intertransversales. 1st C.-5th L.
Splenius cervicis. 1st-4th C.
Scalenus medius. 1st-6th C.
Longissimus cervicis. 2nd-6th C., 1st-6th TH.
Longus capitis. 3rd-6th C.
Longus cervicis. ,, ,,
Scalenus anterior. ,, ,,
Costo-cervicalis. 4th-6th C.
Scalenus posterior. ,, ,,
Levatores costarum. 7th C., 1st-11th TH.
Longissimus capitis. 1st-6th TH.
Semispinalis capitis. ,, ,,
Semispinalis cervicis. ,, ,,
Multifidus. 1st-12th TH.
Longissimus thoracis. 1st-12th TH., 1st-5th L.
Rotatores. 2nd-12th TH.
Semispinalis thoracis. 7th-12th TH.
Psoas major. 1st-5th L.
Quadratus lumborum. 1st-5th L.
Intertransverse ligaments. ALL.
Lumbo-costal ligament. 12th TH., 1st L.
Arcuate ligs. 1st L.
Suprapleural membrane. 7th C.
Capsules of costo-transverse joints. 1st-10th TH.
Costo-transverse ligaments. 1st-11th TH.
Middle and anterior layers of lumbar fascia. 1st-5th L.
Ilio-lumbar ligament. 5th L.
Lumbo-sacral ligament. 5th L.

SPINES—

Obliquus capitis inferior. 2nd C.
Rectus capitis posterior major. 2nd C.
Semispinalis cervicis. 2nd-5th C.
Spinalis cervicis. 2nd-4th C., 7th C., 1st and 2nd TH.
Interspinales. 2nd C.-5th L.
Multifidus. 2nd C.-5th L.
Semispinalis thoracis. 6th and 7th C., 1st-4th TH.
Rhomboideus minor. 7th C., 1st TH.
Serratus posterior superior. 7th C., 1st-3rd TH.
Splenius. 7th C., 1st-5th TH.
Trapezius. 7th C., 1st-12th TH.
Rhomboideus major. 2nd-5th TH.
Spinalis thoracis. 4th-8th TH., 11th and 12th TH., 1st and 2nd L.
Sacrospinalis. 1st-5th L., 1st-3rd S.
Lig. nuchæ. 2nd-7th C.
Interspinous and supraspinous ligs. All TH. and L.
Lumbar fascia. L. TH. S.

OS SACRUM

Sacrum is roughly triangular in shape, possessing *base* or upper surface, *apex* or lower end, *dorsal*, *pelvic* and two *lateral surfaces*. Divided by paired rows of foramina, on dorsal and pelvic surfaces, into (*a*) a *median portion*, composed of most of the parts of five fused vertebræ, and (*b*) a pair of *lateral masses*, composed of their costal elements and transverse processes fused together.

Base is directed upwards and forwards. In the middle, anteriorly, there is the upper surface of body of 1st sacral vertebra. Its anterior margin projects and is called the **promontory.** Behind the body, the **vertebral foramen**—large, sloping, triangular—leads into **sacral canal**; a **superior articular process** stands up on each side of it, and looks backwards and slightly medially. The **ala** of sacrum, or base of lateral mass, spreads fanwise from the side of the body.

Apex is the oval, lower surface of the body of the 5th sacral vertebra—a small vertebra.

Pelvic Surface.—Concave; looks downwards and forwards. Median part is composed of bodies and of ossified discs, whose position is indicated by 4 *transverse lines*. The lines end at the **anterior sacral foramina,** from which shallow grooves extend sidewards.

Dorsal Surface.—Convex and irregular. Presents a vertical row of four **posterior sacral foramina** on each side. Upper three spines are represented by **spinous tubercles** on a median ridge. **Articular tubercles** are the small nodules on the medial edges of the foramina. **Transverse tubercles** are blunt prominences lateral to the foramina. **Sacral hiatus** is the lower end of sacral canal, and it is oblique. **Sacral cornua** are the pair of processes that jut downwards from the sides of the hiatus.

Lateral Surface.—Upper part is broad. Its ventral portion is the ear-shaped **auricular surface,** for articulation with ilium; and dorsal portion is a rough irregular depression for the interosseous sacro-iliac ligament. Part that corresponds to the lowest two vertebræ is narrow, and at the **inferior lateral angle** it turns sharply medially towards the body of the fifth.

Sacral canal is wide and triangular above, small and flattened below; on each side-wall there are four

intervertebral foramina which communicate with both the anterior and the posterior sacral foramina.

Female sacrum is relatively broader than male, and is less uniformly curved, being flat above and abruptly curved below.

Where the laminæ of 5th sacral vertebræ are absent, the posterior wall of **sacral canal** is formed by the superficial posterior sacro-coccygeal lig. Its *contents* are: roots of sacral and coccygeal nerves, filum terminale, and their sheaths; dura mater and arachnoid as far as second piece of sacrum; lateral sacral vessels; spinal plexus of veins. The **sacral hiatus** *transmits* the filum terminale and the primary rami of the 5th sacral nerve and the coccygeal nerve.

Anterior sacral foramina decrease in size from above downwards. Each transmits—anterior primary ramus of a sacral nerve and branches of lateral sacral vessels. The nerves slant downwards and do not lie in the grooves that lead away from the foramina.

Posterior sacral foramina also decrease from above downwards. They lie directly opposite the anterior foramina, and are smaller. They transmit—posterior primary rami of sacral nerves and terminal branches of lateral sacral vessels.

Ala of sacrum is slightly concavo-convex. It slopes downwards and forwards, and is often slightly grooved by the lumbo-sacral trunk. Its lateral margin ends dorsally in a tubercle—the end of the **transverse process.** This is separated by a deep notch from sup. artic. process, which is fused with representative of **pedicle.**

The plate of bone between the spinous and articular tubercles consists of the **laminæ** united by ossified ligaments. Laminæ of the 5th vertebra do not meet and spine is absent; the resulting gap is the sacral hiatus. Articular tubercles are the tips of fused **articular processes.** They lie in line with the intervals between the spines. Articular processes of 5th project downwards as the *sacral cornua.* Each transverse tubercle represents parts of the tips of two **transverse processes.**

First coccygeal vertebra may be fused with the sacrum; less often, the fifth lumbar is partially or entirely fused with the sacrum, or the first sacral may be partially free from the second.

ATTACHMENTS.—Intervertebral disc, ant. and post. longitudinal ligs. to **body of 1st piece.** Capsular ligament to sup. **artic. process.** Lig. flavum and supraspinous lig. to dorsal margin of **vertebral foramen.** Lumbo-sacral lig. and iliacus to **ala.** Ant. sacro-iliac lig. to ventral margin of **auricular surface.** Piriformis from ridges between ant. foramina and from adjoining pelvic surface of **lateral mass.** Coccygeus to surface below and lateral to 4th foramen. Sacro-spinalis, multifidus and gluteus maximus from **dorsal surface.** Long and short posterior sacro-iliac ligs. and

sacro-tuberous lig. to transverse tubercles. Interosseous lig. to rough area behind auricular surface. Gluteus maximus, sacro-tuberous and sacro-spinous ligs. and coccygeus are attached, in that order from behind forwards, to the narrow, lower part of **lateral surface.** Intercornual lig. unites sacral to coccygeal **cornu** and converts the interval into 5th intervertebral foramen, for exit of 5th sacral nerve. Lateral sacro-coccygeal lig. connects **inf. lateral angle** with trans. process of coccyx, and bounds 5th sacral foramen for passage forwards of 5th s. nerve; lig. may ossify. Disc and ant. and post. sacro-coccygeal ligs. to **body of 5th.**

OS COCCYGIS—COCCYX

Coccyx is triangular in shape, with apex downwards. It has *base*, *apex*, *dorsal* and *pelvic surfaces*, and *lateral borders*. It is formed almost entirely of rudimentary bodies of four vertebræ, which tend to fuse.

FIRST PIECE is largest. Oval, concave facet on **body** is the base of coccyx and articulates with body of fifth sacral. **Transverse process** stands out from side of body and is united to inf. lateral angle of sacrum by lateral sacro-coccygeal lig. **Coccygeal cornua** represent articular processes. They project upwards from dorsum of body, and are connected by ligaments to sacral cornua.

SECOND PIECE has small body and rudiments of pedicles and transverse processes. Other pieces are merely small nodules.

ATTACHMENTS.—Gluteus maximus and filum terminale are attached to **dorsum** of coccyx; coccygei, levatores ani, sacro-tuberous and sacro-spinous ligs. to its **edges**; ext. sphincter to its **tip.** Glomus coccygeum and ganglion impar lie on its **pelvic surface.**

VERTEBRAL COLUMN AS A WHOLE

28 inches long in men, nearly 24 in women.

Bodies form a column for support of trunk and head.

Vertebral canal accommodates the spinal cord and its membranes.

Spines and transverse processes are levers for the attachment of muscles. They form three interrupted ridges that bound a pair of grooves of which the laminæ are the floors; the grooves are occupied by many of the muscles which move the column.

Viewed from the side, the bodies form four **curvatures: cervical** and **lumbar,** convex forwards; **thoracic** and **sacro-coccygeal,** concave forwards. **Sacro-vertebral angle** is the projection where lumbar curve passes into sacro-coccygeal, at the lumbo-sacral joint. Thoracic and sacro-coccygeal

curves are present in fœtus and are called **primary**. They are due to shape of bodies. Cervical curve results from elevation and extension of head in infancy; lumbar, from assumption of erect attitude, when child begins to walk. These two are called **secondary** or **compensatory.** They are due chiefly to the shape of the discs. Cervical curve can always be undone by flexion of neck; lumbar curve cannot be undone in adults. Lumbar curve is more pronounced in women than men, and in youth than after middle age. Line along spines does not repeat these curves, owing to differences in length and obliquity. In mid-thoracic region, the tips of spines are considerably below level of bodies of corresponding vertebræ. Intervertebral foramina increase in size down to fifth lumbar. In sacrum, they diminish from above downwards. In cervical region, the transverse processes are in front of articular processes, and in line with intervertebral foramina; in thoracic region, they are behind both; in lumbar region, they are behind foramina, but rather in front of articular processes.

Viewed from the Front.—Bodies increase in breadth from 2 C. to 1 TH.; diminish from 1 TH. to 4 TH. Increase from 4 TH. to 1st sacral, below which there is rapid reduction. Sometimes there is slight lateral curvature in thoracic region, convex usually to right, owing either to greater use of right arm or to pressure of descending aorta. Above and below, there are slight compensatory curves in opposite direction. Transverse processes of atlas are wide and outstanding; those of next five are short and nearly equal in length; those of 7th are long—nearly as long as 1st thoracic. They gradually diminish down to 12th thoracic, where they are represented by tubercles. They are outstanding again in lumbar region, 3rd being longest usually. Column is widest at base of sacrum. Below this, diminution is gradual at first, abruptly increased at 3rd piece of sacrum, and greatly accentuated opposite 5th.

Contents of Vertebral Canal.—*See* p. 286.

Ossification of Vertebræ

Typical Vertebra.—3 primary centres. One for *body* or *centrum* appears first in lower thoracic region, at 10th

week. Process spreads up and down, and by 20th week centres have appeared in all bodies, except lower 2 pieces of sacrum (30th week) and coccygeal (after birth). A pair for the *vertebral arch* appear at the bases of superior articular processes, first in upper cervical region, about 7th week. Process extends downwards and reaches sacrum at 20th week. From this pair the vertebral arch, all processes, and the lateral parts of body are ossified.

Lateral parts of body begin to join central part in neck at 3rd year, and union is complete in all regions at 7th. Till then they are separated by plate of cartilage—**neuro-central joint.** In thoracic region, the ribs articulate with part of body ossified from centre for vertebral arch. Line of neuro-central joint is antero-posterior in cervical region, oblique in thoracic, nearly transverse in lumbar region. Ossification of laminæ is completed after birth—first in lumbar region. Extends up and down. Complete in cervical at 15th month, in sacrum from 7th to 10th year. After union of laminæ, ossification extends into spines.

Centres for **five epiphyses** appear at puberty, and these epiphyses join the rest of the bone about 25th year. One centre for tip of *spine* (double in cervical region). One at end of each *transverse process*. Several centres appear on upper and on lower surface of *body*, and coalesce to form a flat, ring-like epiphysis which adjoins the margins of each surface.

In 6th and 7th cervical, a separate centre may appear in anterior root of transverse process, and may persist as a cervical rib. In lumbar region: mamillary processes have separate centres; vertebral arch of 5th may have two centres on each side; transverse process of 1st L. sometimes has independent costal centre that may persist as a lumbar rib.

ATLAS.—Two centres for **vertebral arch,** *i.e.* for lateral masses, posterior arch, and transverse processes; appear 7th embryonic week, unite dorsally after 3rd year. One or two centres, in 1st year, for **anterior arch,** which unites with lateral masses at 6th to 8th year. **Trans. processes** are completed by epiphyses about 18th year.

AXIS (Epistropheus).—Two centres for **arch** and **processes,** about 7th week. One or two for the **lower part of body,** at 5th month. Two (which coalesce) for the **upper part of body,** including base of odontoid process, a little later. *At birth*, the axis is in four separate pieces, which unite between 3rd and 6th years. One epiphyseal centre for top of *odontoid process* appears 3rd to 5th year, unites 8th to 12th year. Annular epiphysis appears on *lower surface of body* at puberty, and fuses about 25.

SACRUM.—One centre for each **body,** two for each **vertebral arch. Costal elements** of upper 3 have each a centre which appears 6th to 8th month. These unite with arches between 2nd and 5th years. Two epiphyseal plates for each body. One epiphysis for auricular surface, one for narrow edge below it. Fusion of bodies takes place, from below upwards, between 18 and 20 years, and is preceded by fusion of segments of lateral mass.

COCCYX.—*Cartilaginous at birth.* Centre for first piece appears between 1st and 4th years ; for last piece, about puberty. Fusion begins below, and is very variable.

STERNUM OR BREAST-BONE

Sternum.—Lies in anterior wall of thorax. Supports the clavicles and the upper seven pairs of costal arches. Comprises : **manubrium,** above ; **body,** formed by fusion of four segments, in the middle ; **xiphoid process,** below.

Manubrium is the broadest part. Flattened ; triangular, with truncated apex inferiorly. **Anterior surface,** rough, slightly elevated superiorly and in median plane ; **posterior surface,** smooth, concave. **Upper border,** thick ; presents three notches :—*suprasternal notch,* in the middle ; a pair of *clavicular notches* articulate with the clavicles. **Lateral border :** upper part is prominent and hollowed out for 1st costal cartilage ; lower part slopes medially and ends below as facet for upper part of 2nd costal cartilage. **Lower border :** thick, but shorter than upper border ; united with body by fibro-cartilage, forming the *manubrio-sternal joint.*

Body.—Narrower than manubrium, but twice as long. Increases in width down to junction of 3rd and 4th segments, and then rapidly diminishes. **Anterior surface** is slightly convex from above downwards ; subcutaneous in median plane ; crossed by three faintly-marked ridges that mark the fusion of four segments. **Posterior surface :** smoother, concave. **Lateral border :** thick. Opposite the anterior ridges there are the *costal notches* for 3rd, 4th, 5th costal cartilages ; the notch for 6th is at lower part of 4th segment. **Upper end** is united to manubrium, and has a facet on each side for 2nd costal cartilage. Manubrium and body meet at a very obtuse angle, called *sternal angle,* at which the contiguous borders are thickened to form a transverse elevation—the landmark for

the 2nd rib and cartilage. **Lower end** is united by ligaments to the cartilage of the xiphoid process, forming the *xiphi-sternal joint*; and it articulates also with the 7th pair of costal cartilages.

Xiphoid Process.—Lies in anterior wall of abdomen, in front of liver. Varies in size and shape. Cartilaginous; but a bony core in upper part enlarges with age. Thinner than body of sternum, and, its posterior surface being in line with that of body, its anterior surface is on deeper plane than that of body, and forms floor of pit of stomach. **Upper end** articulates with body of sternum and with 7th pair of costal cartilages. **Surfaces, borders** and **lower end** give attachment to muscles and ligaments.

Upper border of manubrium is at level of the lower border of the body of 2nd thoracic vertebra; sternal angle, at level of upper part of body of 5th and therefore opposite interval between 3rd and 4th spines; xiphi-sternal joint is at level of body of 9th and spine of 8th.

ATTACHMENTS.—Articular disc of sterno-clavicular joint to junction of manubrium and first costal cartilage; it intervenes between clavicle and clavicular notch. Capsular ligament to and beyond margins of clavicular notch. Interclavicular lig. to floor of suprasternal notch. Sternal head of sterno-mastoid to upper part of anterior surface of manubrium; sterno-hyoid and sterno-thyroid to upper part of posterior surface. Pectoralis major and ant. sterno-costal capsules to anterior surface of manubrium and body, and sterno-costal capsules to their posterior surfaces. Sterno-costalis to lower part of post. surface of body. Intra-articular ligs. (when present) to floors of costal notches. Ant. intercostal membranes to margins of manubrium and body between notches. Linea alba to lower end of xiphoid process; aponeuroses of obliqui and transversus abdominis to its margin; rectus abdominis to its anterior surface; diaphragm, sterno-costalis, costo-xiphoid and falciform ligs. to posterior surface.

POSTERIOR RELATIONS.—**Manubrium:** Sterno-hyoid and sterno-thyroid; small part of pleuræ and lungs. Thymus; left innominate vein (near upper margin); aortic arch and its branches. **Body:** sterno-costalis, pleuræ, lungs, thymus, lymph-glands, pericardium; within pericardium, asc. aorta opposite 1st segment, right auricle and portions of right atrium and ventricle opposite 2nd, 3rd, 4th segments. **Xiphoid process:** liver and falciform lig.

OSSIFICATION.—**Manubrium**: One or two centres at 5th month. **Body:** centres for segments, in order from above downwards, from 6th month to full term. **Xiphoid process:** centre at 3rd year.

4th and 3rd segments of body unite in early childhood, 3rd and 2nd at puberty, 2nd and 1st from 21 to 25. Body with xiphoid at middle age, with manubrium at advanced age.

COSTÆ—RIBS

12 pairs. Form greater part of bony framework of thorax; overhang upper part of abdomen. Articulate with vertebræ posteriorly; end in costal cartilages anteriorly. First seven pairs are called **true ribs**, because their cartilages articulate with sternum. Other five pairs are called **false ribs**; 11th and 12th are free at their anterior ends, and are called **floating ribs**. Cartilages of 10th, 9th, 8th are connected by their borders, each to the one above.

Ribs vary in length. Longest (7th or 8th) is twice or thrice as long as shortest (1st or 12th). Typical ribs are the 3rd to 9th; 1st, 2nd, 10th, 11th, 12th have special characters.

A typical rib articulates with two vertebræ: the vertebra to which it corresponds numerically and the vertebra above. It has head, neck, tubercle and shaft. Shaft has an angle posteriorly, and costal groove inferiorly.

Head.—Expanded; has two facets for bodies of the two vertebræ with which it articulates.

Neck.—Constricted; about 1 inch long; upper border is raised up as a *crest*. **Tubercle** is placed on the back of the junction of neck and shaft; rough supero-laterally; smooth infero-medially for articulation with transverse process of vertebra of same number.

Shaft.—Long, thin, narrow; curved, bent, twisted. Curvature is greatest posteriorly, and maximum point is at the bend or **angle**, and is marked by a ridge on outer surface. **External surface** is smooth, convex and covered with muscles. **Internal surface** is smooth, concave and clothed with pleura; its lowest part is grooved lengthwise—**costal groove**—for the lodgment and protection of intercostal vessels and nerve. **Upper margin** is thick and rounded. **Lower margin** is sharp. **Anterior end** of shaft is expanded and deeply pitted for costal cartilage.

Facets on **HEAD** form a wedge; the horizontal edge between the facets is the **crest** of head, and gives attachment to intra-articular lig. that binds it to the disc between the two vertebræ. **Capsular**

lig. is attached to margins of articular surface, and lig. radiatum to ant. surface of head. Ant. surface of **NECK** is smooth and clothed with pleura ; posterior is rough for inf. costo-transverse lig. ; lower border is smooth ; upper border gives attachment to sup. costo-transverse lig. Lateral costo-transverse lig. is attached to rough part of **TUBERCLE** ; capsular lig. to margins of smooth facet.

Curvature of the **SHAFTS** of ribs diminishes from above downwards in the series. Ridge which marks the **angle** gives attachment to ilio-costo-cervicalis. On the longer ribs, 2 in. from anterior end, there may be a slight bend, called **anterior angle** ; and, at the same place, the origins of serratus anterior and obliquus externus abdominis may raise a slight ridge on the outer surface.

Typical rib is bent at angle proper, so that the part behind angle slopes more rapidly downwards than anterior part. It is twisted also, so that inner surface of posterior part looks slightly upwards, while that of anterior part looks slightly downwards. Shaft is thicker posteriorly, especially at angle, where bony tissue is heaped up on the concave side to strengthen the bone at maximum of the curve (*i.e.* the weakest point). Upper margin is thicker posteriorly than anteriorly ; posterior intercostal membrane and both intercostal muscles are attached to it.

Costal groove fades away anteriorly, till its margins coalesce ; posteriorly it broadens. Nutrient foramina in it are directed backwards. Its lower margin is sharp and gives origin to ext. intercostal muscle ; upper margin, smooth and rounded, gives origin to internal intercostal ; posterior intercostal membrane is attached to posterior part of the floor of the groove.

For other attachments see table, p. 24.

First Rib.—Short, broad, sharply curved ; articulates with 1st thoracic vertebra only. **Head** : small ; has only one facet ; articulates with body of 1st TH. vertebra and slightly with the disc above. **Neck** : relatively long ; flattened from above downwards ; downturned from shaft, so that when upper surface of shaft is placed on a table, head and neck stand up from the table. **Tubercle** : large ; articulates with 1st thoracic transverse process. **Angle** coincides with tubercle.

Surfaces of **shaft** are superior and inferior ; borders are external and internal. *External border* is convex, and thick posteriorly. *Internal border* is concave and thin ; about its middle is the *scalene tubercle,* which, together with the adjacent elevation on the upper surface, gives insertion to scalenus anterior. *Upper surface* : shallow groove for subclavian vein in front of scalene tubercle ;

better marked *groove for subclavian artery*, behind it; rough depression for scalenus medius, behind arterial groove, between it and tubercle of rib. *Lower surface* is smooth and covered with pleura. *Anterior end* is enlarged. **Costal groove** is absent.

ATTACHMENTS.—Capsular lig. and lig. radiatum to **head.** Inf. costo-transverse lig. to back of **neck.** Capsular lig. and lateral costo-transverse lig. to **tubercle.** Subclavius to ant. part of upper surface of **shaft**; scalenus ant. to *scalene tubercle* and roughness; scalenus medius to posterior part. *External border* gives attachment to 1st intercostals, and posteriorly, where it is thick, to levator costæ, longissimus, costo-cervicalis, the deep fascia of the back and serratus anterior. Suprapleural membrane to *internal border.* Sterno-thyroid to anterior part of *lower surface.* Pectoralis major and clavi-pectoral fascia (costo-coracoid membrane) to *anterior surface* of **1st costal cartilage**; articular disc, subclavius, costo-clavicular lig. to *upper margin*; sterno-thyroid to *posterior surface*; internal intercostal and ant. intercostal membrane to *lower margin.*

RELATIONS.—First costal arch forms the lateral boundary between the neck and thorax, and a boundary between the neck and axilla, as it is the medial margin of the "cervico-axillary canal". It forms the lateral margin of inlet of thorax, extending from the first thoracic vertebra to the manubrium, obliquely downwards and forwards, so that its vertebral end is above the level of the clavicle, while the sternal end is below it; and the apex of the pleura and lung extend an inch and a half or two inches into the neck above the level of its anterior end, but reach only to its neck posteriorly. Lateral edge of longus cervicis overlaps front of head.

On the anterior border of the neck there are the sympathetic trunk medially, first thoracic nerve laterally, superior intercostal artery and first posterior intercostal vein between them; and the first intercostal branch of the artery accompanies the vein along the outer border of the shaft. The first thoracic nerve passes obliquely upwards and laterally, at the junction of neck and shaft, to join the brachial plexus, and it may groove the upper surface immediately behind the subclavian artery. It sends its first intercostal branch obliquely across the lower surface of the shaft to enter the intercostal space well forwards. The deep cervical vessels pass backwards above the neck, between it and the seventh cervical transverse process. Eighth cervical nerve passes laterally above the neck to join the first thoracic in front of scalenus medius; inferior cervical ganglion is in front of that nerve, and may overlap the front of the neck of the rib and fuse with the first thoracic ganglion.

Third part of subclavian artery lies in the groove on the upper surface, between the attachments of scalenus medius and anterior, and becomes the axillary artery at the outer border of the rib. Farther forward, at the outer border, the axillary vein becomes the subclavian, which lies in a groove on the upper surface in front

of scalenus anterior. Clavicle crosses the bony rib near its anterior end—the subclavian vein and subclavius intervening. Internal mammary artery descends behind the cartilage, and sends its first intercostal branch along the outer margin to meet the posterior intercostal. Veins run with arteries in the intercostal space.

Pleura and lung are deep to the arch throughout. Phrenic n. is behind the cartilage, but separated by pleura and lung. Right innominate vein descends behind right cartilage, and, near the lower border, it unites with the left vein to form superior vena cava ; but these veins are separated from the cartilage by overlapping pleura.

(Structures attached constitute additional relations. *See* p. 22.)

Second Rib.—Sharply curved. Not twisted. Angle is just lateral to tubercle. Surfaces oblique, being intermediate in direction between those of first rib and of typical rib. Costal groove is poorly marked. Well-marked **rough elevation,** near middle of outer surface, for lower part of 1st digitation and whole of 2nd digitation of *serratus anterior.*

Tenth rib usually has only one facet on head, and usually has a facet on its tubercle.

Eleventh Rib.—Short. Only one facet on head. No facet on tubercle. Tubercle, angle and costal groove—all poorly marked.

Twelfth Rib.—Very short. Only one facet on head. Tubercle, angle and costal groove are absent.

STRUCTURES ATTACHED TO 12TH RIB AND ITS CARTILAGE.—Capsular ligament and lig. radiatum to **head.** Costo-transverse ligs. and lumbo-costal lig. to **neck.** To **outer surface :** deep fascia of back, ilio-costalis, longissimus, levator costæ, serratus posterior inferior, latissimus dorsi, obliquus externus abdominis. To **upper border :** intercostals. To **lower border :** lateral arcuate ligament, quadratus lumborum, middle and anterior layers of lumbar fascia, obliquus internus abdominis. To **costal cartilage :** diaphragm, transversus abdominis and obliquus internus abdominis, intercostals.

Relations of 12th Rib.—12th rib is in the boundary line between the thorax and abdomen posteriorly ; but the pleura, which, unless the rib is short, clothes only the medial half or two-thirds of its internal surface, crosses it at the level of the lateral border of sacro-spinalis, and extends for a varying distance below its vertebral end ; and the lung probably descends to the lower limit of the pleura on deep inspiration. Diaphragm is separated by pleura from the anterior surface medially, but is in contact with it laterally. Upper end of kidney, the suprarenal gland and the renal fat are anterior, but are separated from it by diaphragm and pleura. Branches of the eleventh intercostal vessels are related to its upper border. Subcostal vessels and nerve run along its lower border—being behind pleura, diaphragm and lateral arcuate lig. along the

medial half of the border. Muscles of the back cover its posterior surface in its medial half, and latissimus its lateral half. On the left side its tip and cartilage are separated from the descending colon, at the lateral border of the kidney, by diaphragm and transversus abdominis. On the right side the liver, being in front of the kidney, is not a close relation. When the rib is long, its tip and cartilage are separated from the upper end of the ascending colon by diaphragm and transversus, and the liver may be in close relation there. Sometimes it is so short that it does not reach beyond sacro-spinalis.

Ossification of Ribs.—**One primary centre** appears at 6th week, first in 6th and 7th ribs. **Three secondary centres**, one for head, one for articular part of tubercle and one for non-articular part, appear at *puberty* and have joined at 25. 11th and 12th ribs have no centre for tubercle.

COSTAL CARTILAGES

Bars of hyaline cartilage fitted into pits at anterior ends of ribs; held there by continuity of periosteum and perichondrium. 1st cartilage is directly continuous with bony tissue of manubrium, and sterno-clavicular articular disc is attached to junction. 2nd to 7th articulate with sternum by synovial joints. 8th, 9th, 10th are indirectly connected with sternum; for synovial joints connect 8th with 7th and 9th with 8th, and the 10th is united to 9th by fibrous tissue. 11th and 12th lie free among the muscles of flank. They increase in length from 1st to 7th, and are successively shorter below that. 1st and 2nd descend obliquely, 3rd is horizontal. 4th to 10th continue direction of ribs for a short distance, increasing from above downwards, and then incline upwards and medially to their terminations. 11th and 12th lie in the direction of their ribs. 10th forms lowest point of outlet of thorax, as seen from front. A line from a little behind this point to side of upper part of manubrium passes through or near junction of cartilages with ribs.

Muscles and Ligaments attached to Ribs and their Cartilages

HEADS—
- Capsular and radiate ligs. ALL.
- Interarticular ligaments. 2nd-9th.

NECKS—
- Inferior costo-transverse ligaments. 1st-10th or 12th.
- Superior ,, ,, 2nd-12th.
- Lumbo-costal ligament. 12th.

TUBERCLES—
- Lateral costo-transverse lig. 1st-11th.
- Capsular lig. 1st-10th.

SHAFTS—

Subclavius. 1st.
Scalenus anterior. 1st.
,, medius. ,,
Sterno-thyroid. ,,
Costo-cervicalis. 1st-6th.
Serratus anterior. 1st-8th.
Costalis. ALL.
External intercostals. ALL.
Internal ,, ,,
Levatores costarum. ,,
Scalenus posterior. 2nd.
Pectoralis minor. 2nd-5th.
Serratus posterior superior. 2nd-5th.
Longissimus thoracis. 3rd-12th.
Obliquus externus abdominis. 5th-12th.
Subcostals, inconstant.
Ilio-costalis (lumborum). 7th-12th.
Latissimus dorsi. 9th-12th.
Serratus posterior inferior. 9th-12th.
Obliquus internus abdominis. 10th-12th.
Quadratus lumborum. 12th.
Suprapleural membrane. 1st.
Posterior intercostal membranes. ALL.
Deep fascia of back. ALL.
Lateral arcuate lig. 12th.
Middle and anterior layers of lumbar fascia. 12th.

COSTAL CARTILAGES—

Sterno-hyoid. 1st (sometimes).
Sterno-thyroid. 1st.
Subclavius. 1st.
Pectoralis major. 1st-6th.
Internal intercostals. ALL.
Sterno-costalis. 2nd-6th.
Rectus abdominis. 5th-7th.
Diaphragm. 7th-12th.
Obliquus internus abdominis. 7th-12th.
Transversus abdominis. 7th-12th.
External intercostals. 10th-12th.
Articular disc of sterno-clavicular joint. 1st.
Clavi-pectoral fascia. 1st.
Costo-clavicular ligament. ,,
Anterior intercostal membranes. 1st-10th.
Sterno-costal capsular ligs. 2nd-7th.
Intra-articular ligaments. 2nd-7th, but inconstant.
Anterior and posterior costo-xiphoid ligaments. 6th and 7th.
Interchondral capsular ligs. 7th-9th.

THORAX

Contracted superiorly. Diameters increase down to level of 8th or 9th rib; below that they are slightly shorter. Wider transversely than antero-posteriorly; antero-posterior diameter is further diminished in median plane by the forward projection of vertebral bodies.

Side-wall is formed of ribs. They slope downwards and forwards, not parallel but spreading, so that **intercostal spaces** are wider in front than behind.

Anterior wall is shorter, especially in median plane; formed of manubrium and body of sternum, anterior parts of first ten pairs of ribs and their cartilages.

Posterior wall comprises thoracic vertebræ, and ribs as far as angles. Ribs have a backward direction as far as their angles, and, with vertebral bodies, form a broad, deep groove internally, for lodgment of thick, posterior part of lung; and assist in forming broad groove externally, occupied by sacro-spinalis. Angle of 1st rib coincides with tubercle. From 2nd to 8th the distance between angle and tubercle increases. Below that it diminishes slightly.

Outlet of Thorax.—Large, irregular.

Occupied by diaphragm and other structures (*see* Diaphragm).

Bounded by 12th thoracic vertebra, 12th pair of ribs, 12th to 7th costal cartilages, xiphi-sternal joint.

Inlet of Thorax.—Reniform; 4 inches by 2 inches. Slopes from behind downwards and forwards.

Bounded by 1st thoracic vertebra, 1st pair of costal arches and upper margin of manubrium.

Occupied by apices of lungs and pleuræ; longi cervicis, sterno-hyoids, sterno-thyroids; trachea, pretracheal fascia, œsophagus, remains of thymus; numerous vessels and nerves; lymph-glands, fat and areolar tissue.

Relations at Inlet of Thorax.—*See* p. 328.

BONES OF SKULL

Bones of Cranial Cavity.—Paired: parietal, temporal. **Unpaired:** frontal, occipital, sphenoid, ethmoid.

Bones of Face and Nasal Cavity.—Paired: zygomatic,

maxilla, nasal, lacrimal, palatine, inferior nasal concha. Unpaired : mandible.

Note.—Position, parts, articulations and ossification are given here in connection with individual bones, but most of the details are included only in the account of the *skull as a whole*, except in the case of the *mandible*.

FRONTAL BONE.—Situated in anterior part of cranium, and forms the forehead. Its halves, originally separate, fuse in early life.

Its FRONTAL SURFACE is convex—the maximum convexity in each half being the **frontal eminence.** It ends below (1) in median **nasal margin,** which bounds **nasal notch** and articulates with nasal bones and frontal processes of maxillæ, and (2) laterally on each side in the **supra-orbital margin,** medial end of which, called the **maxillary process,** curves downwards to articulate with frontal process of maxilla and with lacrimal, while lateral end, called the **zygomatic process,** curves downwards to articulate with the zygomatic bone. **Temporal line** curves upwards and backwards from zygomatic process, and separates the frontal surface from the temporal surface. Each half of **parietal margin** articulates with parietal bone and greater wing of sphenoid—the area for greater wing being large and triangular. **Cerebral surface** is concave.

ORBITAL PLATE extends backwards from each supra-orbital margin ; forms greater part of roof of orbit and of floor of anterior cranial fossa ; articulates posteriorly with lesser wing of sphenoid ; separated from its fellow by a wide interval—the **ethmoidal notch**—which is occupied by cribriform plates of ethmoid. On each side of the notch there are several broken cavities, which are parts of the ethmoidal sinuses and are completed by articulation with the labyrinth of the ethmoid.

NASAL PART is the area in front of the ethmoidal notch. **Nasal spine** projects from its centre and articulates with nasal bones anteriorly and perpendicular plate of ethmoid posteriorly. Groove on each side of spine helps to form roof of nasal cavity. At the side of the groove an opening leads up into the **frontal sinus.**

OSSIFICATION.—In membrane. Centre for each half appears at 7th week. Halves are separate at birth. Fusion is complete at 6th year, except inferiorly. **Frontal sinuses** are recognisable at 7th year, but not fully developed till after puberty.

PARIETAL BONE.—Lies at the side and the top of the head. EXTERNAL SURFACE convex—maximum point of convexity being called the **parietal eminence.** INTERNAL SURFACE is concave. **Upper margin** articulates with the opposite parietal ; **anterior margin,** with frontal ; **posterior margin,** with occipital ; **lower margin,** curved and bevelled, with squamous temporal. **Antero-**

inferior angle, sharp and projecting, articulates with greater wing of sphenoid ; **postero-inferior angle,** blunt, articulates with mastoid temporal.

Ossification.—In membrane. Centre appears at the parietal eminence at 8th week of intra-uterine life.

OCCIPITAL BONE.—Placed at back and base of cranium. Divisible into four parts arranged around **foramen magnum** : basilar part anteriorly, squamous part posteriorly, condylar parts at sides. All are separate at birth ; fused by 5th year.

Squamous part is a large, curved plate of bone ; on each side, the upper part of its margin articulates with the parietal bone, and the lower part with the mastoid temporal. Ossification.—Upper part (the only part of the bone ossified in membrane), by two centres that appear at 8th week ; lower part, ossified in cartilage, by two centres that appear at 8th week. The two parts join during 3rd month of intra-uterine life.

Condylar part comprises :—(*a*) the **occipital condyle,** medially, which articulates with the lateral mass of atlas ; and (*b*) the **jugular process,** laterally, which articulates with petrous temporal. Ossification.—One centre appears at 8th week.

Basilar part.—Fused anteriorly with sphenoid. On each side its margin articulates with the petrous temporal. Ossification.—One centre appears at 6th week.

TEMPORAL BONE lies at side and base of skull. Comprises :—squamous part above and anteriorly ; petrous part medially ; mastoid part posteriorly ; tympanic part below.

Squamous part or Squamous temporal.—**Surfaces** : *cerebral* medially, *temporal* laterally, and a very small *infratemporal,* inferiorly. Anterior part of free margin articulates with the greater wing of sphenoid, and the upper part is bevelled to overlap and articulate with the parietal bone. **Zygomatic process** or **zygoma** projects forwards to articulate with zygomatic bone. Ossification. In membrane. One centre appears at 8th week.

Petrous part or Petrous temporal.—Pyramidal in form. Hardest bone in body. **Surfaces** : anterior, posterior, inferior. **Apex** articulates with sphenoid, in angle between greater wing and body. **Base,** fused with mastoid. (Original fœtal anterior surface is partly fused with squamous and tympanic parts, and partly free, forming medial boundaries of tympanic cavity and antrum, and of canals for pharyngo-tympanic (auditory) tube and tensor tympani.) **Borders** : *Superior* gives attachment to tentorium ; *anterior* partly articulates with greater wing of sphenoid and is partly fused with squamous ; *posterior* articulates with basilar part of occipital. **Styloid process** projects from lower surface, downwards and forwards. Ossification.—In cartilage. Four centres appear at 5th month and rapidly fuse with one another. Styloid process is ossified

from cartilage of second pharyngeal arch by two centres which appear just before and after birth, and fuse in adult life.

Mastoid part or Mastoid temporal.—Is the bone felt behind the auricle. Articulates superiorly with parietal bone, and posteriorly with occipital. **Mastoid process**, blunt and rounded, juts downwards. Ossified by extension from petrous.

Tympanic part or Tympanic plate.—Curved plate which forms the anterior, inferior and posterior walls of external auditory meatus. Ossification.—One centre appears at end of 3rd month. **At birth,** tympanic part is not a plate but a ring, incomplete above ; and temporal bone is divided into squamous, petro-mastoid, tympanic ring, and root of styloid—which all join during 1st year.

SPHENOID BONE lies in base and at sides of skull, in front of occipital and temporals, behind frontal and ethmoid. Has a body and three pairs of processes, namely—lesser wings, greater wings and pterygoid processes.

Body encloses a pair of large sinuses, which are recesses cut off from the nasal cavity that begin to invade the body of sphenoid about 7th year. Articulates *laterally* with apex of petrous temporal ; *inferiorly*, with vomer and sphenoidal process of palatine ; *anteriorly*, with ethmoid and orbital process of palatine ; *posteriorly* with basilar part of occipital, with which it is fused after 25th year.

Lesser wing passes sidewards from the anterior and upper part of body. Its two roots enclose optic foramen. Articulates *anteriorly* with orbital plate of frontal ; *posterior border* is free and ends medially as **anterior clinoid process.** (The part of upper surface of body that unites the lesser wings is called the **jugum sphenoidale.**)

Greater wing extends sidewards from the lateral surface of body. **Surfaces** : orbital, cerebral, temporal and infratemporal. **Borders** : *posterior* forms anterior margin of foramen lacerum, and articulates with petrous temporal ; *postero-lateral* articulates with squamous temporal ; *antero-medial* forms lower margin of superior orbital fissure ; *antero-inferior* forms upper margin of inferior orbital fissure. Upper edges of cerebral, orbital and temporal surfaces enclose a triangle which articulates with frontal. Temporal and orbital surfaces meet anteriorly at a border which articulates with zygomatic bone.

Pterygoid process extends downwards from the junction of the lateral surface of the body and the infratemporal surface of the greater wing. Has a **lateral** and a **medial plate** or lamina. Anteriorly the upper parts of the plates are joined but the lower parts are separated by the **pterygoid fissure,** which is occupied by the tubercle of the palatine bone. **Pterygoid fossa** is the space between the plates posteriorly.

Ossification.—*Medial plate* in membrane. One centre appears at 9th week, fuses with the centre for greater wing during 4th month. In **post-sphenoid**—*i.e.* behind level of tuberculum sellæ—one centre

for *greater wing* and *lateral pterygoid plate* at 8th week, and four for *body*, including lingula, during 3rd and 4th months. In **presphenoid,** one centre for each *lesser wing* at 9th week, fuses with body during 4th month, and two for *body* appear at 10th week and fuse with each other and with post-sphenoid during 8th month. **Sphenoidal conchæ,** fused after 6th year with front and under surface of body, have each one or two centres after 5th month. **At birth,** sphenoid is in three pieces: greater wing and pterygoid process on each side; body with lesser wings. They fuse during 1st year.

ETHMOID BONE lies in front of sphenoid, between the orbits. Has a pair of labyrinths united to median perpendicular plate by a pair of cribriform plates.

PERPENDICULAR PLATE forms a great part of septum of nose. **Borders**: *superior* stands up into cranial cavity as **crista galli.** *Posterior* articulates with sphenoid; *postero-inferior*, with vomer; *antero-inferior*, with septal cartilage; *antero-superior*, with frontal and nasal.

LABYRINTH.—Very thin bone; encloses air-sinuses. **Surfaces**: *superior* is covered by and articulates with orbital plate of frontal; *posterior* articulates with sphenoid and with orbital process of palatine; *anterior* is covered by and articulates with lacrimal bone and frontal process of maxilla; *lateral* is the thin, smooth *orbital plate* that forms a great part of the medial wall of orbit. *Medial*, free in lateral wall of nasal cavity. **Processes**: conchæ, superior and middle, and uncinate process—all on medial surface.

Cribriform plate lies horizontally at the side of crista galli.

OSSIFICATION.—In cartilage. **Labyrinth**: one centre appears at 6th month. **Perpendicular plate**: two centres appear at end of 1st year. **Cribriform plate** by extensions from the other parts. Fusion completed at 6th year, but ossification not completed till puberty.

INFERIOR NASAL CONCHA projects into nasal cavity from its lateral wall, and overhangs inferior meatus. **Borders**: *superior* articulates with palatine, ethmoid, lacrimal and frontal process of maxilla. *Inferior* is free. OSSIFICATION: in cartilage, one centre appears at 5th month.

LACRIMAL BONE.—**Surfaces**: *medial* lies against ethmoid and also looks into nasal cavity; *lateral* forms part of medial wall of orbit. **Borders**: *superior* articulates with frontal; *anterior*, with frontal process of maxilla; *posterior*, with orbital plate of ethmoid; *inferior*, with maxilla and inf. concha. **Lacrimal hamulus**: on lateral surface. OSSIFICATION: in membrane, one centre at 9th week.

VOMER.—Forms posterior part of nasal septum. **Borders**: *superior* splits into a pair of **alæ** and articulates with sphenoid; *anterior* articulates with perpendicular plate of ethmoid and septal cartilage; *inferior*, with nasal crests of palatine and maxillæ; *posterior* is free. OSSIFICATION: in membrane, a pair of centres, at 8th week. The pair of bony plates have coalesced at puberty.

NASAL BONE.—Lies in bridge of nose. **Borders:** *anterior* articulates with its fellow, and posteriorly with nasal spine, perpendicular plate, septal cartilage; *posterior* with frontal process of maxilla. **Ends:** *superior* articulates with nasal margin of frontal; *inferior* is attached to upper nasal cartilage. OSSIFICATION: in membrane, one centre at 8th week.

MAXILLÆ form upper jaw. Each has a body and four processes—frontal, zygomatic, alveolar, palatine.

BODY.—Encloses **the maxillary sinus.** **Surfaces:** *anterior*; *posterior* ends below in **maxillary tuberosity**; *orbital* articulates by its medial border with lacrimal, ethmoid and orbital process of palatine; *nasal* shows opening into maxillary sinus and groove for naso-lacrimal duct; articulates with palatine and inferior concha.

FRONTAL PROCESS extends upwards and medially; forms a part of the nose. **Upper end** lies against and articulates with the front of ethmoid and maxillary process of frontal. **Surfaces:** *medial* articulates with middle and inferior conchæ. *Lateral* is partly in bridge of nose and partly in orbit, and is grooved in orbit for lacrimal sac. **Borders:** *anterior* articulates with nasal; *posterior*, with lacrimal.

ZYGOMATIC PROCESS articulates with zygomatic bone.

ALVEOLAR PROCESS is the thick ridge that bears the teeth.

PALATINE PROCESS extends medially; helps to form the floor of the nose and the roof of the mouth. *Medial border* articulates with its fellow and with vomer; *posterior* articulates with palatine bone.

OSSIFICATION.—In membrane, three centres—one for main part of bone, two (which soon fuse) for premaxilla, *i.e.* part that carries incisor teeth, and line of its fusion can be seen in young skull—appear at 6th week; are fused at 3rd month. Alveolar process begins to appear at 4th month, but is not fully developed till permanent teeth have appeared. Maxillary sinus appears at 4th month, but is not fully developed till after puberty.

PALATINE BONE has a perpendicular and a horizontal plate joined to each other at a right angle. PERPENDICULAR PLATE.—**Surfaces:** *lateral* lies against the nasal surface of the maxilla; *medial* looks into cavity of nose and articulates with middle and inferior conchæ. **Borders:** *anterior* overlaps the opening of maxillary sinus; *posterior* articulates with the medial pterygoid plate. **Orbital** and **sphenoidal processes** project from upper end and bound **spheno-palatine notch**; sphenoidal process articulates with sphenoid and vomer; orbital process with sphenoid, ethmoid and maxilla.

HORIZONTAL PLATE.—Forms the posterior part of the bony palate. **Borders:** *medial* articulates with its fellow and vomer; *anterior*, with palatine process of maxilla; *posterior* is free.

TUBERCLE juts backwards, downwards and sidewards from the junction of the two plates and fits into the pterygoid fissure and between the pterygoid process and the maxilla.

OSSIFICATION.—In membrane, one centre at 8th week.

ZYGOMATIC BONE forms prominence of cheek. **Surfaces :** lateral, orbital, temporal. **Borders :** *superior* or orbital ; *posterior* gives attachment to temporal fascia, *inferior* to masseter ; *anterior* articulates with maxilla. **Processes :** *frontal* articulates with frontal and greater wing of sphenoid ; *temporal*, with zygoma.

Ossification.—In membrane, one centre appears at 8th week.

Mandible has a body and a pair of rami, and each ramus is surmounted by a condyloid process and a coronoid process.

Body.—Symmetrical halves fused during 1st or 2nd year at *symphysis*. **Outer surface :** At symphysis, a faint ridge ends below in triangular *mental protuberance*, whose basal angles form a pair of *mental tubercles*. From each tubercle the *oblique line* extends to ramus. The line gives origin to the depressors of the lower lip and angle of the mouth ; the platysma is inserted below it. The *mental foramen* is above the line, opposite 2nd premolar, and transmits mental vessels and nerve. The *incisor fossa* is below the ridges produced by roots of incisor teeth, and it gives origin to mentalis and orbicularis oris. Buccinator is attached opposite roots of molar teeth.

Inner surface : At the symphysis two pairs of *genial tubercles* (which may be fused) give origin to genio-glossus and genio-hyoid. The *mylo-hyoid line* begins below the tubercles and extends backwards and upwards. It gives attachment to the mylo-hyoid, to the fascia on the deep surface of submandibular gland and, at its posterior end, to the sup. constrictor and pterygo-mandibular lig. The *sublingual fossa* for sublingual gland is above the mylo-hyoid line, near the symphysis ; the *submandibular fossa* for submandibular gland is below the line.

Base of mandible (inferior border) gives attachment to deep fascia of neck, and displays at side of symphysis the *digastric fossa*, for origin of anterior belly of digastric ; and it ends posteriorly at the **angle of mandible.**

Superior border shows sockets for teeth.

Ramus.—Lateral surface gives insertion to masseter.

Medial surface presents the *mandibular foramen* near its middle. The foramen transmits the inferior dental vessels and nerve, and is bounded antero-medially by a sharp spur, called the *lingula*, to which spheno-mandibular lig. is attached. *Mylo-hyoid groove*, for mylo-hyoid vessels and nerve, runs downwards and forwards from the

foramen. Behind and below the groove, the surface is rough for insertion of medial pterygoid muscle. Superior constrictor arises just behind socket of last molar.

Anterior border, sharp, is continuous inferiorly with oblique line of body, and, superiorly, with anterior margin of coronoid process.

Posterior border, smooth and blunt, meets inferior border at the angle; is continuous, superiorly, with back of neck.

Superior border, sharp, forms the floor of **mandibular notch,** which is bounded behind by condyloid process and in front by coronoid process.

Coronoid process is flat and triangular—apex pointing upwards and forwards; temporalis is inserted into its medial surface and its margins, extending down on to anterior margin of ramus.

Condyloid process is divided into head and neck.

Head is convex from before backwards and slightly also from side to side; elongated transversely, but long axis runs backwards as well as medially. Articulates with articular disc of mandibular joint; lies below articular fossa when mouth is shut, and below articular eminence when mouth is open; its own articular surface extends on to its back, but scarcely at all on to its front.

Neck is obliquely compressed, and gives attachment to capsule of mandibular joint. *Lateral* and *medial surfaces* are narrow superiorly, but widen as they approach surfaces of ramus. *Posterior surface* is wider, but narrows to run into posterior margin of ramus. *Anterior surface* forms floor of a hollow for insertion of lateral pterygoid muscle; is overhung by anterior margin of head; is separated from lateral surface by a sharp margin that forms the posterior boundary of mandibular notch; looks slightly medially as well as forwards, and is continuous with medial surface of ramus.

Ossification.—In membrane surrounding cartilage of mandibular arch (Meckel's); one centre for each half appears in lateral surface of membrane at 6th week.

Hyoid Bone.—Lies in the neck, between mandible and larynx, opposite 3rd c. vertebra. Easily felt in living person. Developmentally connected with skull. Has a body and two pairs of horns—lesser and greater.

Body.—**Posterior surface:** concave; separated from

thyro-hyoid membrane by bursa. **Anterior surface:** roughened for attachment of deep fascia of neck, mylo-hyoid, hyo-glossus; stylo-hyoid and fascial sling of tendon of digastric at junction with greater horn. **Upper border**: broad; gives attachment to genio-hyoid, genio-glossus, hyo-epiglottic ligament, thyro-hyoid membrane. **Lower border** gives insertion to sterno-hyoid, omo-hyoid, thyro-hyoid, and levator glandulæ thyreoideæ.

Greater horn curves backwards and upwards from side of body. It is connected with the body in early life by cartilage, but fuses at middle age. Thyro-hyoid, hyo-glossus and middle constrictor are attached to its lateral surface; thyro-hyoid membrane is related to its medial surface, and is attached to its upper border; lateral thyro-hyoid ligament is attached to its free end.

Lesser horn, a pointed nodule that juts upwards and backwards from junction of body and greater horn, articulates there by synovial joint till after middle age, when it fuses. Stylo-hyoid lig. and middle constrictor are attached to it.

Ossification.—One or two centres for body at 8th month, one for greater horn at 9th month, one for lesser horn in 1st year. Body developed from cartilages of 2nd and 3rd pharyngeal arches, lesser horn from 2nd cartilage, greater horn from 3rd.

SKULL AS A WHOLE

FRONT OF SKULL

Frontal Region.—Formed by frontal bone. Maximum convexity, on each side, is *frontal eminence*, which overlies middle frontal gyrus. **Boundaries: Superiorly** it merges into vertex. **Lateral:** *temporal line* arches upwards and backwards from zygomatic process. **Inferior:** *nasal margin* in middle; *supra-orbital margin* at each side. Nasal margin articulates with nasals and frontal processes of maxillæ. Supra-orbital margin ends medially in *maxillary process*, which articulates with frontal process of maxilla and with lacrimal, and laterally in *zygomatic process*, which articulates with zygomatic bone; *supra-orbital notch* or *foramen*, at junction of medial and middle thirds, transmits supra-orbital artery and nerve. *Nasion* is the centre of fronto-nasal suture. Above nasion, there

s a smooth, transverse ridge, called *glabella,* which is nterrupted by the remains of the median *frontal suture.* Glabella unites the *superciliary arches,* which are the olunt, curved ridges situated above the supra-orbital nargin and overlie the frontal sinuses.

Orbits.—Four-sided pyramids, laid on one side. **Base** s the opening on the front of the skull: bounded *above* oy supra-orbital margin; *laterally* by zygomatic bone nd zygomatic process of frontal; *below* by zygomatic nd maxilla; *medially* by frontal process of maxilla and naxillary process of frontal. (*See also* p. 64.)

Facial Region.—Dorsum of nose, between orbits, ormed by nasal bones and frontal processes of maxillæ. *Bony anterior aperture of nose* is bounded by these bones nd by the anterior margins of the maxillæ, which end elow as the *anterior nasal spine.* Below the aperture s the *subnasal fossa,* and, lateral to that, the *canine minence.* Lateral to that is the *canine fossa,* above which s the *infra-orbital foramen.* Lateral to maxilla, the lateral urface of the zygomatic bone presents the *zygomatico-acial foramen,* which *transmits* zygomatico-facial branch f zygomatic nerve and a branch of lacrimal artery.

SIDE OF SKULL

Bones, from behind forwards: *Above,* occipital, parietal, rontal. *Below,* occipital, temporal, sphenoid. *Anteriorly nd below,* bones of face—*see* Front of Skull, p. 34.

Regions.—Pterion, where frontal, parietal, temporal nd greater wing of sphenoid lie close together, 1½ in. bove zygomatic arch, 1¼ in. behind zygomatic process f frontal. Occupies position of *antero-lateral fontanelle* —closed shortly after birth. Overlies anterior branch f middle meningeal artery and the point where lateral ulcus of cerebrum breaks up into its three rami.

Asterion, where parietal, occipital and mastoid meet; ransverse sinus becomes sigmoid sinus immediately in ront of it. Occupies position of *postero-lateral fontanelle* —closed shortly after birth.

Stephanion, where temporal line crosses coronal suture.

Parietal eminence is the maximum convexity of parietal one; overlies anterior part of inferior parietal lobule of erebrum.

Temporal Line.—Usually double. Begins at zygomatic process of frontal, arches backwards over frontal, parietal, and turns down to join **supramastoid crest** on squamous temporal near its junction with mastoid temporal. This crest joins posterior root of zygoma above meatus.

External Auditory Meatus.—Bounded superiorly by the squamous temporal; anteriorly, inferiorly and posteriorly by tympanic plate. **Medial wall of tympanum** is seen when one looks into meatus; it displays the *promontory* produced by first coil of cochlea, with *fenestra vestibuli* above promontory, *fenestra cochleæ* below.

Suprameatal triangle is a depression at the crossing of tangents to upper and posterior borders of meatus. Tympanic antrum is ½ to ¾ inch inwards and slightly forwards from it. *Suprameatal spine*, on antero-inferior margin of triangle, is rarely seen.

Tympano-mastoid fissure, between tympanic plate and mastoid, *transmits* auricular branch of vagus.

Zygomatic arch is formed by the zygomatic bone and the zygoma of the temporal bone. **Lateral surface,** subcutaneous; **medial surface** and **lower border** give origin to masseter. Temporal fascia is attached to **upper border**; anterior end of upper border is called the **jugal point.** **Posterior root of zygoma** runs backwards above meatus from upper border. **Anterior root** turns medially from lower border and is continuous with the articular eminence. *Tubercle of root* of zygoma, where the roots join, gives attachment to the temporo-mandibular ligament.

Temporal Fossa.—**Outlined** by zygomatic process of frontal, temporal line, supramastoid crest, posterior root of zygoma, zygomatic arch, frontal process of zygomatic. Temporal fascia is attached to all these. **Medial wall** gives origin to temporalis; and groove for middle temporal artery ascends over it from posterior root of zygoma. It is formed by parietal, frontal, squamous temporal, greater wing of sphenoid; is limited below by *infratemporal crest*, on which grooves for deep temporal arteries may be found. **Anterior wall:** zygomatic process of frontal, frontal process of zygomatic; on that process there is *zygomatico-temporal foramen*, which transmits zygomatico-temporal branch of zygomatic nerve and a branch of lacrimal artery. **Lateral wall** is the zygomatic arch and temporal fascia.

Infratemporal Fossa.—Lateral wall: ramus and coronoid process of mandible. **Anterior wall:** maxilla, presenting *maxillary tuberosity* behind 3rd molar, and *dental foramina* for posterior superior dental vessels and nerves to molar and premolar teeth. **Medial wall:** lateral pterygoid plate, and tubercle of palatine bone wedged between it and maxilla. **Roof:** infratemporal surface of greater wing of sphenoid.

The fossa *communicates* with orbit through inferior orbital fissure; with pterygo-palatine fossa through pterygo-maxillary fissure; and with temporal fossa directly, under zygomatic arch.

Pterygo-maxillary fissure is bounded by maxilla anteriorly, pterygoid process posteriorly, tubercle of palatine below. Joins inferior orbital fissure above. Transmits maxillary artery and nerve.

Pterygo-Palatine Fossa.—Bounded by maxilla in front; greater wing of sphenoid and pterygoid process behind; perpendicular plate of palatine medially. Roof is body of sphenoid and orbital process of palatine.

Contents: maxillary nerve, spheno-palatine ganglion, terminal branches of maxillary artery, and accompanying veins, fat and fibrous tissue.

Foramina etc. leading from Pterygo-Palatine Fossa.—(1) **Spheno-palatine foramen,** between spheno-palatine notch of palatine and body of sphenoid, leads into nasal cavity; *transmits* spheno-palatine vessels and spheno-palatine nerves (from spheno-palatine ganglion).

(2) **Palatino-vaginal canal,** between body of sphenoid and sphenoidal process of palatine bone; leads backwards and medially to the roof of the pharynx; *transmits* pharyngeal vessels and pharyngeal branch of spheno-palatine ganglion.

(3) **Pterygoid canal** traverses root of pterygoid process to gain foramen lacerum, and *transmits* vessels and nerve of pterygoid canal.

(4) **Foramen rotundum,** in greater wing, opens into middle cranial fossa; *transmits* maxillary nerve.

(5) **Greater palatine canal** leads down between maxilla and perpendicular plate of palatine bone to roof of mouth; *transmits* greater palatine vessels and nerve.

(6) Two **lesser palatine canals** are branches of the greater canal that pass down through tubercle of palatine,

and end on its lower surface as *lesser palatine foramina* they *transmit* lesser palatine vessels and nerves.

(7) *Inferior orbital fissure* (p. 65) leads into orbit.

(8) *Pterygo-maxillary fissure* leads into infratemporal fossa.

BACK OF SKULL

Bones.—Parietals above, occipital below, mastoid temporal at each side.

Points and Lines.—**Lambda,** at apex of occipital, where sagittal and lambdoid sutures meet; is opposite mid-point between parieto-occipital sulci of brain. Occupies position of *posterior fontanelle*—closed shortly after birth.

External occipital protuberance, near centre of occipital squama, gives attachment to trapezius and lig. nuchæ; its centre is the **inion**. **External occipital crest** passes from protuberance to foramen magnum; gives attachment to lig. nuchæ.

Superior nuchal line arches sidewards from protuberance; trapezius, sterno-mastoid, splenius and occipital belly of occipito-frontalis are attached to it. **Highest nuchal line,** above superior, gives attachment to epicranial aponeurosis. **Inferior nuchal line** (really on the lower surface of the skull) extends sidewards from the middle of the occipital crest. Semispinalis capitis and obliquus superior are inserted into area between superior and inferior lines; rectus posterior major and minor, between inferior line and foramen magnum.

Foramina.—**Mastoid foramen,** on mastoid temporal at or near posterior border, leads into groove for sigmoid sinus; *transmits* emissary vein and meningeal branch of occipital art. **Parietal foramen,** $1\frac{1}{4}$ in. above lambda; *transmits* emissary vein to superior sagittal sinus.

TOP OF SKULL

Bones.—Frontal, parietals, occipital. **Sutures**: coronal, sagittal, lambdoid.

Points, etc.—**Bregma,** where sagittal meets coronal suture. Situated at mid-point of line drawn across top of head from front of one auricle to that of the other. May be felt as a depression. Marks the position of *anterior fontanelle*—closed during 2nd year. **Obelion** is the point on sagittal suture between parietal foramina.

Vertex, highest point on sagittal suture; position variable.

Lambda, parietal foramina and **eminences, temporal lines** and **stephanion** are dealt with earlier.

LOWER SURFACE OF BASE OF SKULL

Antero-Median Area.—**Bones:** maxillæ, palatine, body of sphenoid, pterygoid processes, vomer.

Bony palate: formed by palatine processes of maxillæ and horizontal plates of palatine bones. Bounded *anteriorly* and *laterally* by alveolar processes, which bear teeth, and end posteriorly in *maxillary tuberosity* on each side. *Post. margin*, free, gives attachment to soft palate; juts backwards in the middle as *posterior nasal spine*, from which musculus uvulæ arises. **Foramina:** Four *incisive foramina* open into the incisive fossa behind the sockets of incisor teeth. Two are median and transmit long spheno-palatine nerves from the nose; the right and left lateral transmit terminal branches of greater palatine vessels to the nose. *Greater palatine foramen*, at postero-lateral angle, is the lower end of greater palatine canal. Greater palatine vessels and nerve run forwards from it in groove near alveolar process; behind the foramen, there is the *palatine crest* for insertion of tensor palati; behind the crest, there is one *lesser palatine foramen*, and lateral to it the other, when present.

Bony posterior apertures of nose.—Lead into nose. 1 inch long; ½ inch broad; look backwards and downwards. Bounded *below* by palatine; *above*, by sphenoid covered by ala of vomer and vaginal process; *medially*, by vomer; *laterally*, by medial pterygoid plate.

Pterygoid process splits into medial and lateral plates which enclose pterygoid fossa; the upper parts of their anterior borders are joined, but lower parts are separated by *pterygoid fissure*, which is closed up by the tubercle of palatine bone. *Medial plate*, narrower than the *lateral*, ends below in the *pterygoid hamulus*, on under surface of which the tendon of tensor palati turns medially into palate. Superior constrictor and pterygo-mandibular ligament arise from posterior border and hamulus. *Vaginal process* extends medially from upper end of medial plate to articulate with ala of vomer. End of *palatino-vaginal canal* (p. 37) is seen lateral to this

articulation. *Pterygoid tubercle* is at upper end of posterior border of medial plate, on anterior margin of foramen lacerum. *Scaphoid fossa*, below and lateral to tubercle, gives origin to tensor palati. *Pterygoid canal* (p. 37) is above and lateral to tubercle, on anterior margin of for. lacerum. *Emissary sphenoidal foramen* (Vesalius), often absent, above and lateral to scaphoid fossa, *transmits* vein between cavernous sinus and pterygoid plexus.

Tubercle of palatine bone, wedged in between the maxilla and the pterygoid process, appears in the infratemporal fossa between them; fills up the pterygoid fissure between the pterygoid plates, and assists them in bounding pterygoid fossa. Lesser palatine foramina are on its lower surface. Superficial head of medial pterygoid muscle arises from its lateral surface and from maxillary tuberosity; deep head from its posterior surface between the pterygoid plates, and from medial surface of lateral pterygoid plate.

Antero-Lateral Area. — **Bones**: zygomatic process of maxilla, zygomatic arch; infratemporal surface of squamous temporal and of greater wing of sphenoid.

Foramina, etc.: *F. ovale*, at posterior margin of greater wing, near pterygoid process. *Transmits*:—mandibular division of trigeminal n., accessory meningeal art., small veins between cavernous sinus and pterygoid plexus; meningeal lymph-vessels passing to deep cervical glands; lesser superficial petrosal nerve, sometimes.

F. spinosum, postero-lateral to ovale. *Transmits*:—middle meningeal vessels; nervus spinosus; meningeal lymph-vessels to deep glands in the neck.

Spine of sphenoid, postero-lateral to f. spinosum, gives origin to spheno-mandibular lig. and tensor palati; chorda tympani grooves its medial side.

Inferior orbital fissure (p. 65), seen between sphenoid and maxilla.

Infratemporal crest is at lateral margin of infratemporal surface. Upper head of lateral pterygoid arises from infratemporal crest and surface, lower head from lateral surface of lateral pterygoid plate.

Postero-Median Area.—**Bone**: occipital.

Basilar part of occipital or **basi-occiput**, in front of foramen magnum, marked off from sphenoid by irregular groove. *Pharyngeal tubercle*, about its centre, is directly

above the tubercle of anterior arch of atlas ; gives attachment to median raphe of pharynx and fibres of sup. constrictor. *Impressions* : (1) for insertion of longus capitis, antero-lateral to tubercle ; (2) for rectus capitis anterior, immediately in front of condyle.

Foramen magnum: *Contents*: Spinal cord, its vessels, its membranes ; spinal roots of accessory nerves ; vertebral arteries, with plexuses of sympathetic nerves from inf. cervical ganglia, and meningeal lymph-vessels passing to deep cervical glands ; membrana tectoria ; lower part of cerebellum. Ant. and post. atlanto-occipital membranes are attached to its ant. and post. margins, and apical lig. of odontoid process within its anterior margin.

Occipital condyle is at antero-lateral margin of foramen magnum. Inclines towards its fellow anteriorly ; articulates with atlas. *Articular surface*, convex, looks downwards and sidewards ; may be partially divided by notches in its margins ; articular capsule is attached to its circumference. *Tubercle for alar ligament* is on medial margin of condyle.

Anterior condylar canal is above and lateral to the anterior end of the condyle. *Transmits* :—hypoglossal nerve ; meningeal branch of ascending pharyngeal artery ; veins that connect veins of medulla oblongata with pharyngeal plexus ; meningeal lymph-vessels passing to deep cervical glands.

Condylar fossa is behind the condyle. *Posterior condylar canal*, often absent, leads from fossa into groove for sigmoid sinus, from which it transmits an emissary vein to venous plexus in suboccipital triangle.

Jugular process, lateral to condyle, united laterally with petrous temporal by cartilage till 25th year or later ; inferior surface is rough for insertion of rectus lateralis. Anterior border is concave (*jugular notch*), and forms posterior margin of jugular foramen.

Area between foramen magnum and superior nuchal lines displays occipital crest and inferior nuchal lines—*see* p. 38.

Postero-lateral Area.—**Bone** : temporal.

Foramen lacerum (*see also* p. 45) : *Bounded* by petrous temporal, basi-occiput, body and greater wing and pterygoid process of sphenoid ; *pterygoid tubercle* is on its anterior margin, and posterior end of *pterygoid canal* is above and lateral to tubercle and rather hidden by it.

Groove for pharyngo-tympanic tube lodges cartilaginous part of that tube. Extends sidewards and backwards, between the greater wing of sphenoid and the petrous temporal, from the pterygoid tubercle to the end of the bony part of the tube at the medial side of the spine of sphenoid. **Bony part of tube** is a canal in the temporal bone, between petrous and tympanic plate; opens into tympanic cavity; its upper wall is the septum between it and the *canal for tensor tympani*.

Articular eminence, smooth, convex, is lateral to spine of sphenoid, continuous with anterior root of **zygoma**; the **articular fossa** is immediately behind it. Both eminence and fossa articulate with head of mandible (articular disc intervening); and the articular capsule is attached around their circumference.

Squamo-tympanic fissure extends from anterior margin of external auditory meatus, behind articular fossa, to the groove for auditory tube. Its intermediate part *transmits* tympanic branch of mid. meningeal art. The lower edge of the tegmen tympani appears in the medial part of the fissure and divides it into two parts; the anterior part is the *petro-squamous fissure*; and the chorda tympani escapes through the posterior part, which is the *petro-tympanic fissure*.

Tympanic plate, behind and below squamo-tympanic fissure, forms anterior and lower walls of external auditory meatus, and part of its posterior wall. A portion of parotid separates it from back of head of mandible and mandibular joint; and sheath of parotid is attached to its margins. *Upper border* sinks into squamo-tympanic fissure; *lateral border* gives attachment to cartilage of auricle; *medial* fuses with petrous temporal; *lower* is a free edge, and partly ensheaths styloid process.

Styloid process, 1 in. long, slender and pointed, projects downwards, forwards and medially, and gives origin to stylo-pharyngeus, stylo-hyoid and stylo-glossus muscles, and to stylo-mandibular and stylo-hyoid ligaments.

Stylo-mastoid foramen, behind the root of styloid process, is the lower end of the *canal for facial nerve*.

Transmits facial nerve and stylo-mastoid branches of posterior auricular vessels.

Mastoid notch, behind the stylo-mastoid foramen, on medial side of root of mastoid process, gives origin to

posterior belly of digastric. To its medial side, near occipito-mastoid suture, is a *groove for occipital artery*.

Jugular foramen is between the petrous temporal and jugular process of occipital, medial to styloid process.

Transmits :—1. Inferior petrosal sinus, anteromedially.

2. Sigmoid sinus becoming jugular vein, posterolaterally.

3. Between these, glosso-pharyngeal, vagus and accessory nerves, in that order from before backwards.

4. Meningeal arteries from occip. and asc. pharyngeal.

5. Meningeal lymph-vessels to deep cervical glands.

Jugular fossa is a wide, deep depression, on anterolateral wall of foramen, to accommodate the upper bulb of internal jugular vein. In the floor of the fossa there is a pin-point aperture through which the *auricular branch of vagus* enters **mastoid canaliculus,** which conducts it to the tympano-mastoid fissure on the side of the skull.

Right jugular foramen and fossa are usually larger than the left.

Carotid canal, in petrous temporal, in front of jugular foramen.

Transmits :—1. Internal carotid art. with plexus of sympathetic nerves from sup. cervical ganglion.

2. Small veins between cavernous sinus and pharyngeal plexus.

3. Meningeal lymph-vessels passing to deep cervical glands.

On the ridge between jugular foramen and carotid canal here is a minute foramen—the lower end of **tympanic canaliculus,** through which tympanic branch of glossopharyngeal ascends to tympanum.

Rough **quadrate area** on under surface of petrous, between carotid canal and foramen lacerum, gives origin to levator palati.

UPPER SURFACE OF BASE OF SKULL

Anterior Cranial Fossa.—Bones: frontal; crista galli and cribriform plates of ethmoid; lesser wings of sphenoid and jugum sphenoidale.

Median Part.—Crista galli stands up in middle; divides anteriorly into a pair of *alæ*; gives attachment, by its tip and posterior border, to falx cerebri.

Frontal crest, on cerebral surface of frontal bone, gives attachment to falx cerebri; divides above to form the margins of sagittal groove for superior sagittal sinus.

Foramen cæcum is a pit at lower end of crest, between frontal bone and crista galli; may be patent and transmit an emissary vein that connects the beginning of sup. sagittal sinus with veins of frontal sinus and nose.

Nasal slit, at the side of ala of crista galli. Anterior ethmoidal nerve passes through it, or through a hole near it, to reach interior of nose.

Olfactory foramina in cribriform plate transmit olfactory nerves, with meningeal sheaths and small vessels.

Ethmoidal foramina, from orbit (p. 64), open at the side of cribriform plate, from between orbital plate of frontal and ethmoidal labyrinth—the posterior at the posterior end of the cribriform plate, the anterior a little farther forward—both usually hidden by lips of bone.

Jugum sphenoidale is the nearly flat, anterior part of upper surface of body of sphenoid, and connects the two lesser wings (*jugum* = a yoke); its posterior margin is the edge that bounds the optic groove anteriorly; the *ethmoidal spine* projects from its anterior margin, and articulates with posterior edge of the cribriform plates. Olfactory tract and bulb lie on jugum and on cribriform plate at the edge of orbital plate of frontal bone.

Lateral Part.—Shows marks for gyri and sulci of frontal lobe, and grooves for ant. meningeal vessels. Orbital plate of frontal bone roofs in orbit and ethmoidal sinuses, and encloses part of frontal sinus. Posterior margin, formed by lesser wing, is free and overhanging; fits into stem of lateral sulcus of brain; ends laterally opposite pterion, and medially as **anterior clinoid process,** to which the end of free edge of tentorium cerebelli is attached.

Middle Cranial Fossa.—**Bones:** sphenoid, petrous and squamous temporals, antero-inferior angle of parietal.

Median Part.—**Optic groove,** in front, leads on each side to the *optic foramen,* which opens into the orbit (p. 64). *Sella Turcica* is behind the groove.

Sella Turcica is divided into:—(1) *Tuberculum sellæ,* an oval eminence behind optic groove. (2) *Hypophyseal fossa,* a smooth median depression for hypophysis of brain. (3) *Dorsum sellæ* is an upstanding quadrilateral plate behind hypophyseal fossa. Its upper angles are

called *posterior clinoid processes* and give attachment to the ends of attached margin of tentorium. The notch on the side of the root of dorsum accommodates the medial margin of the beginning of inferior petrosal sinus.

Middle clinoid process is a little tubercle postero-lateral to tuberculum sellæ on each side. In some skulls it is large enough to unite with the anterior or the posterior clinoid process, or with both.

Lateral Part.—Carotid groove is a shallow groove for int. carotid art., along the side of body of sphenoid. It ends anteriorly between anterior and middle clinoid processes, and posteriorly at *foramen lacerum*. At for. lacerum it is bounded antero-laterally by *lingula of sphenoid* and postero-medially by *petrosal process* of sphenoid, which articulates with apex of petrous temporal.

Foramen lacerum is a short, wide **canal** that leads from the exterior of base of skull up into middle cranial fossa.

Its *lower end* is bounded postero-laterally by petrous temporal, medially by basi-occiput and body of sphenoid, anteriorly by root of greater wing and pterygoid process.

Its *upper end* is bounded postero-laterally by petrous temporal, medially and anteriorly by the beginning of carotid groove on body of sphenoid and on root of greater wing, laterally by the lingula. Lingula may be long enough to be a complete lateral boundary, but, if short, that boundary is defective, and, if roof of carotid canal is defective or broken, the jagged edges of the incomplete roof are continuous with the margins of foramen lacerum.

The carotid canal opens into foramen lacerum postero-laterally near its upper end, almost at right angles, and the internal carotid artery runs medially *across* the foramen to reach the carotid groove. Cartilage fills the lower part of the foramen. Internal carotid art. lies on that cartilage and occupies the upper part, surrounded by a network of sympathetic nerves and by a network of veins that connect the cavernous sinus with the pharyngeal plexus.

Deep petrosal nerve arises in foramen from the plexus around carotid artery. Greater superficial petrosal nerve enters the foramen and unites with deep petrosal to form the nerve of pterygoid canal, which enters that canal at once, for the posterior end of the canal is in the anterior wall of foramen lacerum below the lingula.

The foramen lacerum *transmits* only :—(1) Meningeal arteries from ascending pharyngeal ; (2) veins between cavernous sinus and pharyngeal plexus ; (3) meningeal lymph-vessels passing to deep glands of neck.

Superior orbital fissure (p. 64) is in anterior wall of lateral part of fossa, between body and wings of sphenoid, and may be completed supero-laterally by frontal.

For. rotundum (p. 37) is below and behind the medial end of sup. orbital fissure. *For. ovale* (p. 40) is near posterior edge of greater wing, half an inch postero-lateral to rotundum. *For. spinosum* (p. 40) is postero-lateral to ovale, at posterior angle of greater wing.

Groove for middle meningeal artery and vein leads sidewards and forwards from f. spinosum on to squamous temporal, over position of articular eminence on inferior surface. Divides at a variable point for the anterior and posterior branches of the artery. *Anterior groove* runs forwards and upwards to the angle of parietal (opposite pterion), sometimes tunnelling the bone ; and turns upwards and backwards over parietal towards mid-point of top of skull. *Posterior groove* runs upwards and backwards, passes on to parietal by crossing its inferior border near its middle, and runs towards lambda.

Arcuate eminence is the low, rounded swelling at upper part of middle of ant. surface of petrous temporal, and is produced by superior semicircular canal of ear. Lateral to it, the smooth bone called **tegmen tympani** slopes downwards and antero-medially, forming roof of tympanic antrum and cavity, and of canal for tensor tympani. Below and medial to arcuate eminence, there is a slit or *hiatus* which transmits greater superficial petrosal nerve and petrosal branch of mid. meningeal art. *Groove for greater superficial petrosal n.* leads downwards and medially from hiatus to foramen lacerum. Lateral to this groove (and lower down) there is the *groove for lesser superficial petrosal n.*, which also emerges through a slit.

Trigeminal impression for trigeminal nerve and ganglion is near apex of petrous temporal. Its floor is the roof of the inner end of carotid canal, and is often deficient.

Posterior Cranial Fossa.—Bones : body of sphenoid, occipital, petrous and mastoid temporal, postero-inferior angle of parietal.

Clivus extends from dorsum sellæ to foramen magnum ;

presents broad median groove related to medulla oblongata, pons and basilar artery, and to which membrana tectoria is attached, in front of for. magnum; laterally, the **groove for inferior petrosal sinus** runs to *jugular foramen* (p. 43), along junction of occipital and petrous.

Internal end of *anterior condylar canal* (p. 41) is on antero-lateral margin of *foramen magnum* (p. 41). *Jugular tubercle* is a smooth eminence above and in front of anterior condylar canal, and its posterior part is grooved by the glosso-pharyngeal, vagus and accessory nerves as they pass to the jugular foramen.

Internal occipital protuberance is almost opposite the external protuberance. Ridges run up, down and sidewards from it. *Internal occipital crest*, running downwards from it to for. magnum, gives attachment to falx cerebelli, which contains occipital sinus; lower part of crest sometimes divides to enclose a fossa which is related to vermis of cerebellum. On each side of the crest there is the wide *cerebellar fossa*.

Groove for transverse sinus extends from protuberance to lateral angle of occipital, and on to the postero-inferior angle of parietal, where it becomes the **groove for sigmoid sinus.** That groove runs downwards over the junction of petrous and mastoid temporals, then medially over mastoid temporal, and then forwards over jugular process of occipital to jugular foramen. Tentorium cerebelli is attached to the lips of the transverse groove. *Mastoid foramen* (p. 38) opens into the sigmoid groove, on mastoid temporal; and *posterior condylar canal* (p. 41), when present, opens into it, on jugular process.

Notch for trigeminal nerve is on upper border of petrous temporal, near apex. **Groove for superior petrosal sinus** runs along this upper border; tentorium is attached to its lips.

Internal auditory meatus, on posterior surface of petrous temporal, *transmits* both roots of facial n., auditory n., internal auditory vessels. At its bottom or far end, there is the beginning of the canal for facial nerve.

The **external opening of aqueduct of vestibule** is in a slit overhung by a lip of bone, half an inch lateral to meatus. It lodges the endolymphatic sac and transmits a small artery and vein. The **subarcuate fossa**—a depression above and between meatus and aqueduct—lodges a process of dura, and transmits small vessels.

Groove for Glosso-Pharyngeal Nerve.—On the anterior margin of

jugular foramen, directly below internal meatus, there is a notch for 9th nerve as it enters jugular foramen. The notch is the upper end of a groove that runs downwards, forwards and sidewards on petrous temporal, just in front of jugular fossa, and ends at the ridge between the fossa and lower end of carotid canal. Groove is seen from lower surface of skull; it lodges 9th nerve; is bridged across by fibrous tissue, or, sometimes, by bone; on the ridge at or near its lower end, there is the opening of the canaliculus for tympanic branch of glosso-pharyngeal. The **external opening of the cochlear canaliculus** is a small hole in a pit in the floor of the glosso-pharyngeal notch on ant. margin of jugular foramen. It lodges a process of dura and arachnoid, transmits a small vein from cochlea to internal jugular vein, and allows perilymph to drain away from scala tympani into the subarachnoid space.

CEREBRAL SURFACE OF VAULT OF CRANIUM

Bones.—Frontal above superciliary arches; occipital above protuberance; parietal, except inferior angles; upper edge of squamous temporal.

Sutures.—Coronal, sagittal, lambdoid, squamous.

Frontal crest is in median plane anteriorly. **Groove for superior sagittal sinus** begins on frontal crest, runs upwards and backwards on frontal, and along sagittal suture to apex of occipital; descends to internal protuberance, where it usually joins right transverse groove, but may join left, or split and join both. Falx cerebri is attached to its lips. *Pits for arachnoid granulations* are found in the skulls of old people at the sides of sagittal groove on frontal and parietal.

Impressions for cerebral gyri are shallow depressions like finger-prints on skull-bones.

Vascular grooves for meningeal vessels are best marked on parietal. Groove for anterior branch of middle meningeal overlies pre-central gyrus (motor area) of brain.

CAVITY OF CRANIUM

Contents.—Brain and its vessels and membranes; cranial nerves; and the vessels associated with the outermost membrane.

The brain is surrounded by three fibrous membranes or meninges named, from without inwards, *dura mater*, *arachnoid mater* and *pia mater*; at the foramen magnum, they are continuous with the corresponding membranes of the spinal cord. When the brain is removed, its vessels and the arachnoid and pia mater also are removed, and they are studied with the brain; but the dura mater

and its vessels are left in the skull. The cranial nerves are divided when the brain is taken away, and parts of them remain in the skull.

Dura Mater.—Firm and dense. Two layers adherent to each other except along certain lines where they separate to enclose venous sinuses.

Outer layer serves as periosteum, and it is called *endocranium*. At the lips of the orifices, it is continuous with the *pericranium*, which is the periosteum on the outside of the skull.

The outer layer is firmly adherent to the floor of the cranial cavity, but less so at the sides and roof, except along the sutures because it is fused there with the **sutural ligaments.** These are fibrous ribbons set between the articulating margins at the sutures, and their edges are continuous with the endocranium and pericranium.

Inner layer is smooth and glistening because it is covered with endothelium. It is separated from the arachnoid mater only by a capillary interval which contains a film of lymph to keep the surfaces moist. It covers over the openings in the lateral part of the middle cranial fossa and is separated from the mastoid and posterior condylar foramina by the sigmoid sinus, but at the other small openings it is carried out as sheaths for the nerves, and at the foramen magnum it is continuous with the spinal dura mater. At four places it is drawn away from the outer layer as folds of two laminæ. These folds are named the falx cerebri, falx cerebelli, tentorium cerebelli and diaphragma sellæ ; and each fold has venous sinuses associated with it. Except where they help to enclose sinuses, the laminæ of each fold are adherent to each other, and, at the free border of the fold, they are continuous with each other.

Falx Cerebri.—A median fold, long and wide, that hangs down from the roof into the longitudinal fissure of the cerebrum and acts as a tense elastic septum that separates the two cerebral hemispheres and keeps them from bruising each other during movements of the head.

It is curved like a sickle (hence the name *falx*) and widens from before backwards, so that it has an apex in front, a base behind and below, and two curved borders.

Apex is attached to crista galli. **Convex margin** is

attached to crista galli, frontal crest and the lips of the sagittal groove on the vault of the skull; the superior sagittal venous sinus is enclosed between the outer layer of the dura and the two laminæ of the falx along this margin.

Concave margin is the free, lower edge; it overhangs the corpus callosum of the cerebrum, and contains the inferior sagittal sinus in its posterior two-thirds.

Base is attached to the tentorium along the median plane. The manner of attachment is that the two layers of the falx separate to become continuous with the right and left halves of the upper layer of the tentorium; the straight sinus is enclosed between them and the lower layer of the tentorium. The falx braces up the tentorium, making it tense so that it keeps the weight of the hinder part of the cerebrum off the cerebellum.

Tentorium Cerebelli.—A tent-like roof for the posterior cranial fossa—highest in the median plane anteriorly and sloping to its circumference.

Anterior border is sharp, free and deeply concave; with the dorsum sellæ, it bounds the doorway of the tent, which is occupied by the mid-brain. On each side anteriorly it is prolonged forwards as a ridge on the roof of the cavernous sinus, and its end is attached to the anterior clinoid process.

Circumferential border is attached to the lips of the groove for the transverse venous sinus on the occipital bone and postero-inferior angle of parietal, and to the lips of the groove for the superior petrosal sinus on the upper margin of petrous temporal; and, anteriorly, it crosses below the anterior margin to be fixed to the posterior clinoid process. Trochlear nerve pierces arachnoid and dura mater at the point of crossing of the margins. Oculomotor nerve pierces them farther forward—on the roof of the cavernous sinus in the interval between the margins after they have crossed each other.

Where the two layers separate to be attached to the lips of the grooves, the transverse sinus and the superior petrosal sinus are enclosed between them and the outer layer of dura.

Falx Cerebelli.—A small crescentic fold that contains the occipital sinus. It is pinched up from the internal occipital crest and lies in the vallecula and posterior notch of the cerebellum.

Diaphragma Sellæ.—A small circular fold. Roofs over the hypophyseal fossa, and has a central aperture through which the infundibulum of hypophysis passes. The anterior and posterior intercavernous sinuses lie between the layers of diaphragma at its anterior and posterior borders.

Venous Sinuses of Cranium.—Are blood-spaces between the layers of dura mater. Like other blood-vessels, their walls are lined with endothelium, but, their walls being dura mater, they are unlike veins in that there is no muscular tissue in them and that their walls are almost rigid; and therefore they cannot expand or contract. To keep the quantity of blood within them constant, **emissary veins** are provided. These veins pass through holes in the skull and connect the sinuses with veins outside; and the blood can flow either way through them. When cut, the sinuses do not collapse like veins, and it is difficult to control the bleeding from a cut sinus in a living person.

The sinuses receive venous blood from the bones, dura mater and brain. Some of them receive also cerebro-spinal fluid, which passes into them through the *arachnoid villi* and *granulations*; these are little protrusions of the arachnoid mater that bulge into the sinuses, stretching and pushing the wall of the sinus before them—villi microscopic; granulations of the size of small peas—and they contain little offshoots of the subarachnoid space, whose every part is filled with a clear liquid called *cerebro-spinal fluid*.

Unpaired Sinuses.—Superior and inferior sagittal; straight; intercavernous; basilar.

Paired Sinuses.—Transverse and sigmoid; cavernous; superior petrosal; inferior petrosal; spheno-parietal; occipital.

Superior Sagittal Sinus.—Begins on the frontal crest by the union of tiny meningeal veins. Occasionally, it communicates with veins of the nose by a small vein that passes through foramen cæcum.

The sinus arches upwards, backwards and finally downwards, in the convex margin of falx cerebri, grooving the vault of the cranium. Widens as it proceeds, and ends at the side of the internal occipital protuberance by turning to the right (sometimes left) and becoming the transverse sinus of that side.

It is the sinus into which most of the arachnoid granulations bulge; and some of them can be seen as soon as the skull-cap is removed.

Veins from the upper part of the cerebrum enter it; they open into it from behind forwards—*i.e.* contrary to the blood-flow in it—and in its hinder half they run

forwards along it for half an inch or more before they enter it.

A pair of **emissary veins** that pass through the parietal foramina connect it with the occipital veins.

Lacunæ laterales are spaces between the two layers of dura alongside the sinus. Three or more on each side. They communicate with the sinus by slit-like openings ; and arachnoid granulations bulge into them as well as into the sinus. Vary in width. The widest—an inch or more across—is usually alongside the middle of the sinus and overlies the motor area for the lower limb.

Straight Sinus.—Formed by the union of inferior sagittal sinus and the great cerebral vein (which comes out of the cerebrum below the posterior end of corpus callosum). Runs backwards and downwards in the junction of falx cerebri and tentorium, dilates at the internal occipital protuberance and turns to the left (sometimes right) and becomes the transverse sinus of that side. *Receives* veins from occipital lobes of cerebrum, cerebellum and falx. *Communicates* with other sinuses at the protuberance.

Confluence of Sinuses.—Is the intercommunication of superior sagittal, straight and transverse sinuses at the protuberance.

Inferior Sagittal Sinus.—Very narrow. Lies in the posterior two-thirds of the free edge of falx cerebri. Ends at the middle of the anterior margin of tentorium by joining the great cerebral vein to form the straight sinus. *Tributaries* from falx and middle third of medial surface of each cerebral hemisphere.

Intercavernous Sinuses.—A network of venous channels that connect the right and left cavernous sinuses. They lie in the floor of the hypophyseal fossa and in the anterior and posterior margins of the diaphragma sellæ ; they are therefore closely related to the hypophysis of the brain.

Network of Basilar Sinuses.—Lies on the clivus of the skull. Connects right and left inferior petrosal sinuses. Communicates with cavernous sinuses and spinal veins.

Transverse and Sigmoid Sinuses.—Widest and most important of sinuses.

Transverse Sinus.—Begins at the internal occipital protuberance. Runs first sidewards and then forwards in the circumference of tentorium as far as the base of petrous temporal, where it becomes the sigmoid sinus.

Sigmoid Sinus.—Leaves the tentorium at once and runs its course between the two layers of dura mater in posterior cranial fossa—first downwards on the side of

the skull, then medially on the base, and, finally, forwards to the jugular foramen, where it bends downwards and becomes the internal jugular vein.

Tributaries.—Superior petrosal sinus; veins from cerebellum and lower part of cerebrum; occipital and posterior temporal diploic veins.

Emissaries.—Sigmoid sinus is connected with the veins behind the auricle by the vein which passes through the mastoid foramen, and with the suboccipital plexus by a vein that goes through the posterior condylar canal.

Position.—Indicated on the surface by a line drawn from external occipital protuberance, slightly convex upwards, to the upper part of back of root of auricle (for *transverse sinus*); then, for *sigmoid*, downwards along the back of root of auricle to the level of the lower border of external auditory meatus and then forwards to the lower border of the meatus.

Relations.—Transverse Sinus:—*Superior* — Cerebrum. *Inferior*—Cerebellum. *External*—Occipital bone and postero-inferior angle of parietal (grooving both); attachments of trapezius, sternomastoid and splenius to superior nuchal line; occipital vessels and greater occipital nerve, an inch lateral to the protuberance; branches of lesser occipital and great auricular nerves, more laterally.

Sigmoid Sinus.—Cerebellum is *posterior*, *medial* and *superior*. As the sinus descends, it grooves mastoid temporal and petrous temporal at their junction—sometimes very deeply. *Lateral*—mastoid temporal and mastoid air-cells; posterior auricular vessels and nerve and branches of great auricular. *Anterior*—Petrous temporal; tympanic antrum (may be very close); lower down, vertical part of facial nerve in facial canal, and sometimes a few air-cells. *Inferior*—Mastoid temporal and jugular process of occipital (grooving both); and, outside skull, posterior belly of digastric, occipital artery and rectus capitis lateralis, in that order latero-medially.

Cavernous Sinus.—Important because of its contents and relations. Lies between the two layers of dura on the side of the body of sphenoid. Cavity is traversed by fibrous bands and sheets which divide it into " caverns ".

Tributaries and Communications.—*Ophthalmic vein* (or veins) and *spheno-parietal sinus* enter its anterior end. *Superficial middle cerebral vein* and one or more smaller cerebral veins enter through its roof.

Intercavernous sinuses and the *basilar network* connect it with its fellow. *Superior* and *inferior petrosal sinuses* connect its posterior end with the transverse and sigmoid sinuses. *Emissary veins* pass through the carotid canal, foramen ovale and sphenoidal emissary

foramen and connect it with the pharyngeal and pterygoid venous plexuses.

Contents.—Imbedded in lateral wall, from above downwards, the oculomotor, trochlear, ophthalmic and abducent nerves; and, medial to the nerves, the internal carotid artery (with sympathetic plexus), bulging across the cavity to the medial wall (but shut off from the blood in the sinus by the endothelium); the artery enters the lower part of the sinus posteriorly and emerges through its roof far forward.

Relations.—Sphenoidal air-sinus is medial—the mucous lining separated only by thin bone. Hypophysis is medial to its upper part. Trigeminal ganglion is postero-lateral, and the maxillary nerve runs forwards along the lower border of the cavernous sinus. Optic tract and uncus of the cerebrum are above and lateral; and above it also there is the terminal part of internal carotid after it has escaped from the sinus and is curving backwards to reach the vallecula of the cerebrum.

Spheno-Parietal Sinus.—Short and very narrow. Lies on the lower surface of the posterior edge of lesser wing of sphenoid, and ends in cavernous sinus. Receives anterior temporal diploic vein Communicates with meningeal veins.

Superior Petrosal Sinus.—Very narrow. Runs from the posterior part of cavernous sinus to the end of transverse sinus. Lies in the attachment of tentorium to the upper border of petrous temporal. *Receives* inferior cerebral, superior cerebellar and tympanic veins.

Inferior Petrosal Sinus.—Wider than the superior, but shorter. Begins at the posterior end of cavernous sinus, runs downwards, backwards and sidewards in the groove on the junction of petrous temporal and basi-occiput. Passes through the anterior part of jugular foramen and ends there in the beginning of internal jugular vein. *Connected with* its fellow by the basilar network. *Receives* inferior cerebellar and internal auditory veins.

Occipital Sinus.—Starts from the beginning of transverse sinus, runs in falx cerebelli to foramen magnum, then forwards, skirting foramen magnum, to end in sigmoid sinus near jugular foramen. In the falx, it may fuse with its fellow to form a single sinus. *Communicates* with spinal veins, and *receives* some inferior cerebellar veins.

Emissary Veins (*see* p. 51).—(1) The vein that occasionally connects the superior sagittal sinus with veins of the nose and frontal air-sinuses. (2) Parietal (p. 52). (3) Mastoid (p. 53). (4) Posterior condylar (p. 53). (5) Of cavernous sinus (p. 53).

Diploic Veins.—Wide, intercommunicating venous spaces, lined with endothelium, in the diploë of the vault and sides of the cranial cavity. They communicate with the venous sinuses, lacunæ laterales, meningeal veins and veins outside the skull. Four are named:—**Frontal** communicates with supra-orbital vein; **anterior temporal,**

with spheno-parietal sinus or with anterior deep temporal vein; **posterior temporal,** with sigmoid sinus or with mastoid emissary vein; **occipital,** with transverse sinus or with occipital veins.

MENINGEAL VESSELS.—Are imbedded in the outer layer of dura mater, but are thicker than the dura and therefore stand out in relief on its surface and groove the skull-bones; they have more to do with supplying the bone and the marrow than the dura—which needs little blood.

Meningeal Veins.—Arise from networks in the dura into which blood from bones and dura is drained. Accompany the arteries—lying external to them and therefore more liable to injury in fracture of the skull. Some end in sinuses; others pass through the holes by which the arteries enter, and end in veins outside.

Middle Meningeal Artery.—By far the largest of the arteries. Arises from the maxillary in the infratemporal fossa and enters the cranial cavity through the foramen spinosum, accompanied by a vein. It then runs forwards and sidewards on the floor of the skull for a variable distance and ends by dividing into an anterior and a posterior branch.

Posterior branch runs backwards and upwards over the side-wall on to the vault, giving off branches as it runs. It is opposite a line drawn towards the lambda from the zygomatic arch midway between the margin of orbit and external auditory meatus.

Anterior branch is larger; and it is more important, for it is the source of middle meningeal hæmorrhage, and in a great part of its course it is opposite the motor area of the cerebrum. It first runs upwards on the side of the skull to a point opposite the pterion, where it tunnels the bone or grooves it deeply, and it then sweeps upwards and backwards towards the middle of the top of the skull. It is opposite a line that begins at the zygomatic arch midway between orbit and meatus, is drawn first to the pterion and then to the mid-point between nasion and inion in the median plane.

Unimportant branches of middle meningeal:—(1) *Superficial petrosal* enters the bone through the slit for the greater superficial petrosal nerve. (2) *Superior tympanic* accompanies the tensor tympani muscle to the middle ear. (3) An *orbital artery* sometimes springs from the anterior branch and passes through the superior orbital fissure into the orbit.

Other meningeal arteries will be mentioned among the contents of the cranial fossæ.

Lymph-Vessels.—Pass from the dura mater through foramen spinosum, ovale, lacerum, jugulare and magnum, and end in glands on the lateral pterygoid muscle and on the carotid sheath.

Nerves.—Dura mater is supplied by minute filaments from vagus, hypoglossal, the three divisions of trigeminal and sympathetic plexuses around the arteries.

CONTENTS OF ANTERIOR CRANIAL FOSSA.—1. **Frontal lobe of cerebrum. Olfactory tract** and **lobe** lie on jugum sphenoidale and lateral edge of cribriform plate.

2. **Nerves.**—*Olfactory* (1st cranial) ascend through the holes in cribriform plate ensheathed by the inner layer of dura, arachnoid and pia mater, and enter olfactory bulb. *Anterior ethmoidal*—a terminal branch of naso-ciliary—passes from orbit through anterior ethmoidal canal into cranial cavity, then forwards between the two layers of dura on cribriform plate, and down into nose through a slit at the side of the anterior part of crista galli. In the nose, it descends along the deep surface of nasal bone giving *internal nasal branches* to the mucous membrane; and it leaves the nose between the nasal bone and the upper nasal cartilage as the *external nasal nerve*, which supplies skin of the lower half of the nose.

3. **Anterior Meningeal Vessels.**—In the medial part they come from the anterior and posterior ethmoidal branches of ophthalmic; in the lateral part they are branches of middle meningeal.

CONTENTS OF MIDDLE CRANIAL FOSSA.—Parts of cerebrum; blood-vessels; nerves.

1. **The parts of the cerebrum** include:—(*a*) *Temporal lobe*, in the lateral part of the fossa. (*b*) *Optic chiasma*, above optic groove; it is the part to which the optic nerves are attached, and it has been removed with the brain. (*c*) The hypophysis.

Hypophysis Cerebri.—Is left in the skull, for it lies below diaphragma sellæ in the hypophyseal fossa (*hypo*=below; *physis*=growth). About the size of a large pea. Has anterior and posterior lobes. **Posterior lobe** is connected with the tuber cinereum of base of brain behind chiasma by a stalk, called **infundibulum,** which passes through the hole in diaphragma. **Anterior lobe,** much larger, is folded round the front of posterior lobe and extends upwards partly ensheathing the infundibulum. Not derived from brain, but from a diverticulum of ectoderm of primitive mouth; the cavity of the diverticulum persists as a narrow cleft far back in the anterior lobe.

The medieval physicians called the hypophysis the "pituitary body" because they thought it was the source of the yellow discharge from the nose in the later stages of a "cold" (the adjective *pituitary*=mucous).

Relations of Hypophysis.—Most intimate relations are its arteries from internal carotid and anterior cerebral; its nerves from internal carotid plexus; and its pial, arachnoid and dural envelopes. Cavernous sinus is on each side of it; and intercavernous sinuses are below, behind and in front of it. Sphenoidal air-sinus in body of sphenoid is below and in front. Chiasma is above it. Dorsum sellæ, basilar artery and pons are behind it.

2. **Blood-vessels in Middle Cranial Fossa.**—Venous sinuses; meningeal vessels; internal carotid artery and its branches.

Cavernous sinuses, on the sides of body of sphenoid, united by *intercavernous sinuses* (p. 53). **Superior petrosal,** along posterior part of rim of fossa (p. 54). **Spheno-parietal,** under anterior part of rim (p. 54).

Middle meningeal artery (p. 55) is much the largest. **Accessory meningeal** arises in infratemporal fossa from maxillary or from middle meningeal, enters through foramen ovale, and supplies trigeminal ganglion and the dura near it; and they are supplied also by a **meningeal branch of ascending pharyngeal** that enters through foramen lacerum. Small **meningeal branches of ophthalmic or of lacrimal** run backwards out of orbit through superior orbital fissure; one of them may be big enough to replace the anterior branch of middle meningeal.

Internal Carotid Artery.—Traverses carotid canal in base of skull, crosses the upper part of foramen lacerum, and enters the cranial cavity at the medial side of the lingula of sphenoid, where it ascends through the outer layer of dura and enters the cavernous sinus.

It then runs forwards on the side of the body of sphenoid in the cavernous sinus, bends upwards and pierces the roof of the sinus (inner layer of dura) and the arachnoid at the medial side of anterior clinoid process.

It now turns backwards above the roof of cavernous sinus; and, finally, it bends upwards to end in the vallecula below the anterior perforated substance of the cerebrum by dividing into the anterior and middle cerebral arteries, after giving off two other branches to the brain—anterior choroidal and posterior communicating.

In the cavernous sinus, it is separated from the venous blood by the endothelium of the sinus; it is medial to the nerves in the lateral wall of the sinus—oculomotor, trochlear, ophthalmic and abducent. It is so close to the body of sphenoid that it grooves the bone, and, if the sphenoidal air-sinus is large, there is only very thin bone between the artery and the mucous lining of the sinus.

It gives off tiny twigs to adjoining structures, but the only branch of any size (apart from those to the brain) is the ophthalmic artery, which passes at once into the optic foramen (p. 64).

3. **Nerves.**—Internal carotid plexus; optic; oculomotor; trochlear; trigeminal; abducent; and the petrosal nerves.

Internal Carotid Plexus.—Surrounds the artery and sends secondary plexuses along its branches. In cavernous sinus, it communicates with the nerves in the sinus, sends branches to trigeminal ganglion and hypophysis, and a branch into the orbit to join the ciliary ganglion.

Optic Nerve (2nd cranial).—Passes from the orbit through optic foramen (with ophthalmic artery) and joins the chiasma.

Oculomotor Nerve (3rd cranial).—Emerges through the front of the mid-brain, pierces the pia mater at once, passes between the posterior cerebral and superior cerebellar arteries and runs forwards to pierce arachnoid and the dura of roof of cavernous sinus at the lateral side of posterior clinoid process in the interval between the borders of tentorium after they have crossed each other. It then runs forwards in the lateral wall of cavernous sinus above the other nerves there, and divides into two branches—upper and lower—which enter orbit through superior orbital fissure.

Trochlear Nerve (4th cranial).—Very slender. Emerges through the back of the brain-stem, pierces the pia mater at once; curves forwards round the side of the mid-brain; pierces arachnoid and dura at the point where the margins of tentorium cross each other; runs forwards in the lateral wall of cavernous sinus below oculomotor nerve; slants upwards across the lateral side of oculomotor nerve, and enters orbit through superior orbital fissure.

Abducent Nerve (6th cranial).—Having ascended between the layers of the dura mater of the posterior cranial fossa, enters the middle fossa at the apex of petrous temporal, and, curving round the lateral side of the ascending part of the internal carotid artery, it passes into the cavernous sinus. It then runs forwards in the side-wall of the sinus below the other nerves there and lateral to the internal carotid artery; and it enters the orbit through the superior orbital fissure.

While in cavernous sinus, the third, fourth and sixth nerves receive filaments from the sympathetic internal carotid plexus and from the ophthalmic nerve. Those from the ophthalmic nerve convey afferent impulses from the muscles which they supply.

Trigeminal Nerve (5th).—Thickest of cranial nerves.

Sensory: for part of dura mater; for contents of orbit; for skin of anterior half of the head, most of the face, upper part of lateral surface of auricle, of external meatus and tympanic membrane; for mucous membrane of nose, air-sinuses, mouth and anterior two-thirds of tongue; for the teeth and the mandibular joint.

Motor: for tensor palati and tensor tympani, for mylo-hyoid and anterior belly of digastric, and for the four "muscles of mastication"—temporalis, masseter, lateral and medial pterygoid.

Has two roots: a **motor root** and a much thicker **sensory root.**

A large ganglion—**trigeminal ganglion**—placed on the sensory

root gives rise to that root and to the three great divisions of the trigeminal nerve, namely—the ophthalmic, maxillary and mandibular nerves.

Trigeminal Ganglion.—Crescentic in outline. The ganglion lies in a space in the dura mater called the *cavum trigeminale*, on the trigeminal impression near the apex of petrous temporal, and overlapping foramen lacerum. (The *cavum* is enclosed in a pocket or diverticulum of the inner layer of dura evaginated forwards, between the outer and inner layers of dura, from the lips of the aperture which transmits the roots of the nerve; it has therefore two of the inner layers of the dura above it, and an inner and an outer layer—fused together—below it.) Motor root of V. and the greater superficial petrosal nerve are below the ganglion. Internal carotid, at first below it in carotid canal and foramen lacerum, becomes medial to it in the posterior part of cavernous sinus. Hippocampal gyrus is above it.

Supplied by twigs from internal carotid, middle and accessory meningeal, and meningeal branch of ascending pharyngeal.

Sensory fibres of trigeminal nerve arise in its cells. While in the ganglion, each fibre divides into a central and a peripheral branch. *Peripheral branches* emerge through its convex, antero-inferior margin, and they form the three large nerves—**ophthalmic, maxillary** and **mandibular.** *Central branches* emerge through its concave, postero-superior margin, and they form the **sensory root** of V.

Sensory Root.—It is unsheathed in a thin, adherent layer of pia mater, and also in a loose layer of arachnoid which encloses subarachnoid fluid. Crosses upper border of petrous temporal near its apex, below superior petrosal sinus and the attached margin of tentorium; passes horizontally backwards and slightly medially to the pons; sinks backwards through the junction of pons and middle cerebellar peduncle for half an inch. Part of it then ends in the upper sensory nucleus (p. 531). The remainder forms the spinal tract, which descends through pons and medulla oblongata into spinal cord, and sends its fibres into a long nucleus placed on its deep surface.

Motor Root.—Arises from a nucleus in the dorsal division of pons; emerges at the antero-medial side of the sensory root; runs along it, first on its medial side and then below it, to the petrous temporal; passes downwards and forwards, below and behind the trigeminal ganglion and mandibular nerve; escapes through foramen ovale with mandibular nerve. It joins that nerve as they go through the foramen, and is distributed by its branches.

Ophthalmic Nerve.—Thinnest of the three divisions. Enters cavernous sinus almost at once, runs forwards in its lateral wall below the third and fourth nerves, and divides into three branches —*frontal, lacrimal* and *naso-ciliary*—which enter the orbit through superior orbital fissure. Near its origin it gives a minute branch to

the tentorium. In the sinus, it communicates with the third, fourth and sixth nerves and with internal carotid plexus.

Maxillary Nerve.—Runs forwards between the layers of dura mater along the lower border of cavernous sinus, separated only by thin bone from the mucous membrane of sphenoidal air-sinus, if that sinus is large. Leaves cranial cavity through foramen rotundum and enters pterygo-palatine fossa.

Mandibular Nerve.—The thickest division. Descends almost at once through foramen ovale into infratemporal fossa, in company with the motor root.

Near their origin, the mandibular and maxillary nerves give slender filaments to the adjacent dura mater.

Petrosal Nerves.—Deep; external; greater and lesser superficial. All very slender. Contain fibres of taste and secretory fibres for lacrimal and parotid glands.

Greater Superficial Petrosal Nerve.—Arises from facial nerve in the substance of petrous temporal bone; emerges through a slit on its anterior surface; runs medially, forwards and downwards in a groove on the bone; passes below trigeminal ganglion, and enters foramen lacerum. It is joined there by the **deep petrosal nerve,** which arises in the foramen from internal carotid plexus.

These two petrosal nerves form the **nerve of pterygoid canal,** which runs forwards through that canal in the floor of the sphenoidal sinus to reach the pterygo-palatine fossa. It ends in the **sphenopalatine ganglion**, which is suspended from the maxillary nerve in that fossa.

Greater petrosal nerve contains—(1) Taste-fibres which pass through the ganglion into its palatine branches, and (2) secretory fibres relayed in the ganglion for the lacrimal gland.

Lesser Superficial Petrosal Nerve.—Arises in the substance of petrous temporal by two roots. One root comes from the ganglion of the sensory root of the facial nerve. The other root enters the bone from the *tympanic plexus*, which lies on the medial wall of middle ear and is composed chiefly of filaments of the tympanic branch of the glosso-pharyngeal.

The lesser petrosal nerve emerges through an inconspicuous slit below the slit for greater petrosal, runs downwards and forwards on the anterior face of petrous temporal in a narrow groove on the roof of the canal for tensor tympani, escapes through foramen ovale or through a special aperture or through the suture between petrous temporal and greater wing, and ends just below the skull in the *otic ganglion* (p. 309). Its fibres convey secretory impulses which are relayed in the otic ganglion and are carried to the parotid gland by the auriculo-temporal nerve.

External petrosal nerve is seldom found. It is said to come from the middle meningeal sympathetic plexus and to run backwards along the greater petrosal to the facial nerve.

CONTENTS OF POSTERIOR CRANIAL FOSSA.—1. Hind-brain—*i.e.* cerebellum, pons and medulla oblongata. The lower

part of the **mid-brain** is in the doorway of the tentorium. After their removal, the upper end of the **spinal cord** is seen in foramen magnum—attached to the side of the foramen by the first tooth of *lig. denticulatum* (p. 288).

2. **Vessels.**—The arteries are the **vertebral** and **basilar** and their branches; they have been removed with the hind-brain except part of the *vertebral artery*, seen at the side of the spinal cord in front of lig. denticulatum. But while tentorium and hind-brain are still in place, the **posterior cerebral** and **superior cerebellar** arteries are seen, with the oculomotor and trochlear nerves between them; and, if veins are full of blood, one is seen curving backwards round the side of the mid-brain, and it is called the **basal vein**.

3. **Nerves.**—**Anterior root of first cervical nerve** (upper part of which arises from medulla oblongata) is seen in foramen magnum in front of the vertebral artery.

Hypoglossal nerve (12th cranial nerve) is behind vertebral artery; and its two parts pierce arachnoid and dura mater on the margin of foramen magnum opposite anterior condylar canal.

Spinal root of **accessory nerve** (11th cranial) ascends through foramen magnum behind lig. denticulatum and joins the cranial root; the nerve-trunk, together with **vagus** (10th cranial), pierces arachnoid and dura mater opposite jugular foramen. **Glossopharyngeal** (9th cranial) pierces the membranes separately immediately above vagus.

Internal auditory meatus is a little above the jugular foramen. **Auditory** and **facial nerves** (8th and 7th cranial) enter it together with the *internal auditory vessels*; the artery is a branch of basilar; the vein joins inferior petrosal sinus. The motor root of facial nerve is above the auditory, and the sensory root (very slender) is between them.

Abducent nerve (6th cranial) pierces arachnoid and dura about midway between foramen magnum and posterior clinoid process, and runs between the layers of dura towards the apex of petrous temporal. Both roots of **trigeminal** (5th cranial) pass through an opening in the dura at the upper border of petrous temporal near its apex. **Trochlear** pierces arachnoid and dura at the point where the borders of tentorium cross each other.

4. **Falx Cerebelli** (p. 50).

5. **Venous Sinuses.**—Between layers of dura:—**Straight** sinus in the roof of the fossa (p. 52). **Superior petrosal** and **transverse** along its rim (pp. 54, 52). **Sigmoid** far forwards on side-wall and floor. **Inferior petrosal** between petrous temporal and basi-occiput. **Basilar network** between right and left inferior petrosal. **Occipital** in falx cerebelli and at the side of foramen magnum.

6. **Meningeal Vessels.**—In outer layer of dura. In posterior cranial fossa there are:—(*a*) Branches of **middle meningeal** sweep

down into the fossa. (*b*) Branches of **occipital** enter through jugular and mastoid foramina. (*c*) Branches of **ascending pharyngeal** enter through jugular foramen and anterior condylar canal. (*d*) A branch **of vertebral** enters through foramen magnum.

AIR-SINUSES

Are called also **paranasal sinuses** because they are cavities in bones that adjoin the nose—frontal, ethmoidal, sphenoidal, maxillary and an occasional one in orbital process of palatine bone.

They are diverticula of the cavity of the nose and remain in communication with the nose.

Filled with air ; enclosed in compact bone ; lined with endosteum fused with mucous membrane which is continuous with that of nose and, like it, is covered with ciliated epithelium. The cilia move in such a way that they urge the mucous secretions towards the openings into the nose.

The purpose of the sinuses is to make the bones big enough without making them heavier. They are also resonating chambers for the voice. They are relatively larger in men than in women, and a man's voice is therefore more resonant than a woman's, as well as deeper and stronger.

They are absent or very small at birth ; enlarge slowly till puberty, but rapidly at puberty and soon reach full size ; and, since they are bigger in men, a boy's face alters more at puberty than a girl's. Enlarge again in old age owing to absorption of adjoining diploë, and that accounts for the hollow resonance of an old person's voice that has not become feeble.

Inflammation from the nose readily spreads into their mucous membrane, giving rise to pain in the bones ; their secretions then become purulent and more abundant, and may accumulate in them if their openings are occluded by the swollen mucous membrane, or if the cilia, enfeebled by the disease, are unable to cope with the increased secretion.

Frontal Sinus.—Seldom recognisable till seventh year, but may appear as early as the second year.

In the frontal bone immediately above the root of the nose and supra-orbital margin. Separated from its fellow by a complete bony septum, which is seldom quite median—the left sinus usually the larger. About an inch in height and an inch in width, and extends a little distance into the roof of orbit. Larger in old people—extending up in the forehead, sidewards to the temple and backwards through the whole roof of orbit. Sometimes small, or even absent.

Opens into middle meatus of nose by means of a passage, called its **infundibulum,** which descends through the anterior part of ethmoid labyrinth. (The opening is into the upper part of *hiatus semilunaris* of middle meatus : p. 72.)

Relations.— Inferior—Orbit, nose, anterior ethmoidal sinuses.

Anterior—Supratrochlear and supra-orbital nerves and vessels; orbicularis oculi and frontalis. *Postero-superior*—Frontal lobes.

Sphenoidal Sinuses.—A right and a left. Occupy the body of the sphenoid. Separated by a complete bony septum, which is seldom quite median. May be limited to the anterior part of sphenoid; usually occupy the whole of its body. Extend, in old people, into roots of greater wings and pterygoid processes, and even into basi-occiput.

Begin in 5th month of intra-uterine life as recesses of nasal cavity which are surrounded and cut off by the sphenoidal conchæ as they ossify; but they do not extend into the real body of sphenoid till the 7th year.

Each *opens* into the spheno-ethmoidal recess (p. 72) of its own side by a round aperture in its anterior wall.

Relations.—*Upper* wall separates each sinus from the intercavernous venous network, hypophysis cerebri, olfactory tract and frontal lobe, and (a little distance away) the optic chiasma.

Lower wall separates it from nasal part of pharynx and posterior inferior part of nasal cavity; and it is traversed antero-posteriorly by pterygoid canal and its vessels and nerve.

Posteriorly, fairly thick bone separates it from the basilar artery and the pons.

Lateral wall separates it from cavernous sinus and its contents, and the maxillary nerve along the lower border of that sinus.

Anterior wall separates it from the nasal cavity and posterior ethmoidal sinuses.

Ethmoidal Sinuses.—Though small at birth, begin in the second half of intra-uterine life as little cavities in the cartilaginous precursor of ethmoid; and papery bone is gradually deposited around them.

Are numerous, small, thin-walled, intercommunicating cavities that occupy the whole of the ethmoid labyrinth and are therefore between the orbit and the nose; many of the outlying sinuses are completed by the bones with which the labyrinth articulates.

Divided into three sets:—**Posterior ethmoidal sinuses** *open* into the superior meatus of nose. **Middle** open on *bulla ethmoidalis* of middle meatus (the bulla is a bulging on the side-wall of the meatus and is bounded in front and below by a curved groove—the hiatus semilunaris). **Anterior** open into the hiatus about its middle.

Relations.—*Lateral*—orbit. *Medial*—upper half of cavity of nose. *Posterior*—sphenoidal sinus (and palatine sinus, when present). *Anterior*—frontal process of maxilla and lacrimal bone, which close in the anterior sinuses. *Inferior*—superior and middle meatuses of nose. *Superior*—ethmoidal vessels and nerves in ethmoidal canals; frontal and sphenoidal sinuses; anterior cranial fossa.

Maxillary Sinus.—*See* p. 312.

ORBITS

Four-sided pyramids laid on one side. Medial walls parallel to each other; lateral walls almost at right angles.

Base opens on the face; looks forwards and slightly sidewards; upper and lower margins incline downwards when traced sidewards. Boundaries are the "orbital margins":—*Superior*: supra-orbital margin of frontal bone. *Inferior*: zygomatic bone and maxilla. *Lateral*: zygomatic bone and zygomatic process of frontal. *Medial*: frontal process of maxilla and maxillary process of frontal.

Apex is the medial part of superior orbital fissure.

Roof: Orbital plate of frontal, and, posteriorly, lesser wing of sphenoid.

Lateral Wall: Greater wing of sphenoid, and, anteriorly, frontal process of zygomatic bone.

Floor: Maxilla; zygomatic, antero-laterally; orbital process of palatine bone, at posterior corner.

Medial Wall: From before backwards—Frontal process of maxilla; lacrimal; orbital plate of ethmoid; side of body of sphenoid.

Foramina, etc.—*Between the roof and the medial wall*: **Optic foramen,** far back, between body of sphenoid and roots of lesser wing, leads from middle cranial fossa. *Transmits* optic nerve, ophthalmic artery and sympathetic filaments from internal carotid plexus.

Posterior ethmoidal foramen, a pin-point aperture a little in front of optic; and **anterior ethmoidal foramen,** half an inch farther forward, and larger. Both lead into ethmoidal canals between orbital plate of frontal and ethmoid labyrinth; and the canals open into anterior cranial fossa at the edge of cribriform plate. *Transmit* anterior and posterior ethmoidal nerves and vessels.

On roof: At its antero-lateral part, **fossa for lacrimal gland,** wide and shallow like a finger-print. Near antero-medial corner, **trochlear fossa,** small and shallow, for the attachment of the pulley for the tendon of superior oblique muscle; may be a small **trochlear spine** instead of a fossa.

Between roof and lateral wall: **Superior orbital fissure,** bounded by the body and wings of sphenoid; leads from

the middle cranial fossa; wide medially at the apex of orbit, and slants forwards, sidewards and upwards, narrowing to a point and crossing lateral rectus muscle of orbit obliquely. *Transmits*: trochlear, frontal and lacrimal nerves, *above lateral rectus*, in that order medio-laterally; and, *between the two heads of rectus*, upper and lower divisions of oculomotor, naso-ciliary, abducent, sympathetic filaments from internal carotid plexus, ophthalmic vein or veins, meningeal branch of ophthalmic or of lacrimal artery, and, sometimes, an orbital branch of middle meningeal.

On lateral wall: **Zygomatico-orbital foramen,** very small, in zygomatic bone; *transmits* zygomatic nerve and a branch of lacrimal artery (with its vein).

Between lateral wall and floor: **Inferior orbital fissure** leads into infratemporal fossa and, medially, into pterygo-palatine fossa. Joins superior fissure medially at an angle. *Bounded* laterally by zygomatic, above by greater wing, below by zygomatic, maxilla and orbital process of palatine. *Transmits*: maxillary nerve as it becomes infra-orbital; infra-orbital vessels; zygomatic nerve; filaments from spheno-palatine ganglion to lacrimal gland and periosteum of orbit; a vein (or veins) that connects veins of orbit with pterygoid plexus in infratemporal fossa.

On floor: **Infra-orbital groove** begins at the middle of the inferior orbital fissure and runs straight forwards into the **infra-orbital canal,** which opens on the face as the **infra-orbital foramen.** Infra-orbital nerve traverses all three; infra-orbital artery—a branch of maxillary—runs along the nerve and is accompanied by a vein.

On medial wall: **Groove for lacrimal sac,** near orbital margin, on lacrimal bone and frontal process of maxilla. Is continuous inferiorly, *between medial wall and floor*, with upper end of **naso-lacrimal canal** for naso-lacrimal duct, which leads down into inferior meatus of nose.

Chief Relations of Orbit.—*Superior*: Anterior cranial fossa; frontal sinus. *Inferior*: maxillary sinus. *Posterior*: middle cranial fossa. *Lateral*: temporal fossa. *Medial*: from before backwards, cavity of nose, ethmoidal sinuses, sphenoidal sinus.

Contents of Orbit.—Eyeball and its fascial sheath, with suspensory and check ligaments.

Muscles: 4 recti; 2 obliqui; levator palpebræ superioris.

Vessels: Ophthalmic and their branches and tributaries; infra-orbital.

Nerves: Infra-orbital and zygomatic; optic, oculomotor, trochlear and abducent; frontal, lacrimal and naso-ciliary; filaments from internal carotid plexus and spheno-palatine ganglion; ciliary ganglion and ciliary nerves.

Lacrimal gland and **sac. Fat. Periosteum.**

Periosteum.—Lines the walls of orbit and is easily stripped off. Encloses all the other contents except zygomatic nerve and infra-orbital nerve and vessels. Continuous—(1) with the outer layer of dura through superior orbital fissure, optic foramen and ethmoidal canals; (2) with periosteum on the outside of skull at inferior orbital fissure and the margins of orbital opening; and (3) with the periosteal lining of naso-lacrimal canal.

Fat.—Soft, lobulated, abundant, lies among the other structures, and, with the recti muscles, forms a socket in which the eyeball rotates as in a ball-and-socket joint.

Eyeball.—In anterior part of orbit, surrounded by orbital muscles and fat and its own fascial sheath. Outer shell is fibrous and strong, and divided into the **sclera** (the white of the eye) and **cornea** (transparent window in front). The part of sclera seen from the front is covered with **conjunctiva**—a moist, transparent membrane that lines the eyelids and, at their roots, is reflected on to the sclera and covers the front of it as far as the edge of the cornea. Reflexion is called the *fornix of conjunctiva*—an upper and a lower.

Eyeball is about an inch in diameter (a halfpenny is exactly one inch). Almost spherical; but the cornea is slightly more convex than the sclera.

Tendons of recti are inserted into sclera an eighth of an inch from cornea, and tendons of obliqui just behind equator of eyeball. Optic nerve pierces sclera a little below and medial to the centre of the back of eyeball; and its sheaths fuse with sclera. Ciliary nerves and short posterior ciliary branches of ophthalmic artery pierce it around optic nerve; and long posterior vessels pierce it farther away—one on each side. Four or five venæ vorticosæ from the interior pierce it a little behind equator. And anterior ciliary vessels (from ophthalmic) pierce it near the cornea.

Fascial Sheath of Eyeball.—Thin, membranous. Lines the socket. Invests the posterior part of eyeball loosely, being connected with it by soft areolar tissue; fuses with sheath of optic nerve at the back of eyeball. Anteriorly, it slips under the conjunctiva and fuses with it near cornea.

Pierced by ciliary vessels and nerves and venæ vorticosæ, and, opposite equator, by the tendons of recti and obliqui. From the lips of the apertures, sheaths like sleeves are reflected backwards on to the muscles and gradually thin away, except that for superior oblique,

which becomes attached to the trochlea, and that for inferior obliqui, which is fixed to the floor of orbit and limits the action of the muscle. Lips of apertures are thickened posteriorly to form pulleys—except that for superior oblique.

Check Ligaments.—Connect the sheaths of rectus lateralis and medialis to zygomatic and lacrimal bones, and restrain these muscles. R. superior is restrained by a connexion with levator palpebræ; and R. inferior by connexion with the suspensory ligament.

Suspensory Ligament.—A hammock on which the eyeball rests. Thin and membranous. Ends attached to zygomatic and lacrimal bones near the check ligaments; if one of these connexions is damaged in an operation, the eyeball drops down. From each end it widens out below the eyeball, where it fuses with the fascial sheath and with the sheaths of rectus and obliquus inferior.

Levator Palpebræ Superioris.—Lies immediately below the middle of the roof of orbit, on the rectus superior.

Origin (tendinous): Roof of orbit in front of optic foramen.

Insertion: Into upper eyelid by three tendinous sheets: one attached to the skin after mingling with orbicularis oculi; another to the upper edge of the tarsus; the third, after fusing with the sheath of rectus superior, into the upper fornix of conjunctiva (to raise it with the lid). The edges of the sheets are connected with the orbital margins to restrain movement.

Nerve: Oculomotor, through its upper branch.

Recti.—Arise from a tendinous ring that surrounds optic foramen and the medial part of superior orbital fissure and is fixed to the bones around the foramen and to a tubercle on the inferior margin of the fissure.

R. superior, inferior and **medialis** spring from it above and below and medial to the foramen. **R. lateralis** springs from the upper and lower parts of the lateral part of the ring by an upper and a lower head, between which certain structures pass (p. 65).

Each rectus passes forwards to the eyeball and, after piercing the fascial sheath of eyeball, it is inserted by a thin, wide tendon into the sclera 3 or 4 lines behind the cornea—medialis nearer the cornea than the others. Lateralis and medialis are at the level of the axis of the eyeball; superior and inferior are in a sagittal plane a little medial to the axis, and therefore do not move the eye straight up and down.

Nerves: Lateralis by abducent. The others by oculomotor—superior through its upper branch; medialis and inferior through its lower branch.

Obliquus Superior.—Lies under the medial border of the roof of orbit. **Origin** (fleshy and tendinous): Roof of orbit medial to levator. Runs forwards and becomes a slender tendon; tendon passes forwards through the trochlea and then backwards and

sidewards over the top of eyeball below rectus superior, and widens out to be **inserted** into sclera behind the equator either under rectus superior or between it and lateralis.

The **trochlea** or pulley is a fibro-cartilaginous ring attached by fibrous tissue to the floor of the trochlear fossa, and from its lateral margin it sends a tough fibrous sheath over the tendon. A *synovial sheath* covers the tendon and lines the pulley and the fibrous sheath.

Nerve : Trochlear.

Obliquus Inferior.—**Origin** (fl.—tend.) : Floor of orbit far forwards, near naso-lacrimal canal. Runs sidewards and backwards below eyeball and rectus inferior, and then upwards between eyeball and lateralis to be inserted, by a thin, wide tendon, a little farther back than obliquus superior, either deep to lateralis or between it and rectus superior.

Nerve : Oculomotor, through its lower division.

Actions of Recti and Obliqui.—R. superior directs pupil upwards and medially. R. inferior directs pupil downwards and medially. R. lateralis directs pupil laterally. R. medialis directs pupil medially. O. superior directs pupil downwards and laterally. O. inferior directs pupil upwards and laterally.

R. mediales of opposite sides act in unison to converge eyes to focus on a near point. R. lateralis acts with R. medialis of opposite side in looking to one side. Direct downward movement is produced by inf. rectus and sup. oblique, and direct upward by sup. rectus and inf. oblique.

Ophthalmic Artery.—A branch from the medial side of internal carotid. Arises at the medial side of anterior clinoid process, after the carotid has pierced dura and arachnoid. Enters optic foramen with optic nerve within the arachnoid and dura sheaths of the nerve. In the foramen, it is at first below the nerve but, gradually piercing the sheaths, it winds round and appears in orbit at the lateral side of the nerve.

Runs forwards a short distance on the lateral side of optic nerve then medially above the nerve to reach the medial wall of orbit and then forwards below obliquus superior to end at the anterior part of orbit by dividing into supratrochlear and dorsal nasal arteries.

Branches.—1. **Arteria retinæ centralis.**—The most important branch, though very small. Arises in optic foramen ; enters the medial side of optic nerve and runs in it to the retina. It has no anastomoses ; and irrecoverable blindness therefore follows injury or occlusion.

2. **Lacrimal artery.**—The largest branch. Arises at the lateral side of optic nerve, runs forwards along the upper border of rectus lateralis, and ends in branches to *lacrimal gland* and *upper eyelid*. Gives branches also to *muscles*, to eyeball (*anterior ciliary*), t

accompany zygomatic nerve, and a *meningeal branch* backwards through superior orbital fissure.

3. **Muscular** branches to muscles of orbit from ophthalmic directly and from its other branches ; and muscular twigs give *anterior ciliary* branches to the eyeball.

Most of the other branches are mentioned elsewhere :—

4. A **meningeal** branch passes backwards from the ophthalmic through superior orbital fissure.

5. **Long and short posterior ciliary** enter the back of the eyeball.

6. **Anterior** and **posterior ethmoidal** pass through ethmoidal canals into cranial cavity, where they end as meningeal branches ; they send branches also to mucous membrane of nose and of frontal, ethmoidal and sphenoidal sinuses.

7. **Medial palpebral,** to both eyelids.

8. **Supra-orbital,** a large branch, accompanies supra-orbital nerve.

9. **Supratrochlear** accompanies supratrochlear nerve.

10. **Dorsal nasal,** to the bridge of the nose.

Veins of Orbit.—Accompany the branches of ophthalmic artery and unite to form two trunks — **superior** and **inferior ophthalmic veins**—one above the optic nerve and one below. These pass backwards through superior orbital fissure to end in the cavernous sinus either separately or after union. They communicate with the supra-orbital and supratrochlear veins at the superior orbital margin, and with the pterygoid plexus through the inferior orbital fissure.

Note : *Ophthalmic artery and vein pass through different apertures.*

The infra-orbital and zygomatic branches of maxillary nerve, being outside the periosteum, will be dealt with later (pp. 310, 311).

Optic Nerve (2nd cranial ; special sense of sight. *See also* pp. 513, 568).—A thick nerve. An inch and a half long ; slightly longer than the distance it has to travel, else it would hamper the movements of the eyeball.

Begins in the retina, emerges through sclera 3 mm. medial to the centre of the back of eyeball and 1 mm. below it, runs backwards and medially out of the orbit through the optic foramen into the cranial cavity, where it joins the optic chiasma. Enclosed in sheaths of pia and arachnoid and a thick sheath of dura.

Relations.—**In orbit.**—Surrounded by orbital muscles and fat, and, near eyeball, by ciliary nerves and vessels. Inferior ophthalmic vein and lower branch of oculomotor nerve are below it. Naso-ciliary nerve and ophthalmic artery, at first lateral, run medially above it ; and superior ophthalmic vein runs laterally above it. Ciliary ganglion is on its lateral side, as also is the upper branch of oculomotor nerve, but farther back ; and the abducent nerve also is lateral, but farther away.

In optic foramen.—Ophthalmic artery is below and lateral to it; sphenoidal sinus is below and medial; arteria retinæ centralis enters it.

In cranial cavity.—Internal carotid and ophthalmic arteries are below and lateral to it. Olfactory tract and gyrus rectus are above it, and anterior cerebral vessels also are above its end.

Trochlear Nerve (4th cranial. *See also* pp. 511, 568).—Enters orbit through superior orbital fissure above rectus lateralis, medial to the other nerves at that level, and soon enters obliquus superior —supplying it alone.

Lacrimal Nerve.—Arises in cavernous sinus from the ophthalmic. Enters the orbit through the lateral angle of superior orbital fissure above rectus lateralis, runs along the upper border of that muscle, ends in branches to lacrimal gland, and sends a *palpebral branch* to the skin and conjunctiva of lateral part of upper eyelid. Its own fibres to lacrimal gland are sensory; secretory fibres come into it through a communicating branch from the zygomatic, which carries impulses brought by the greater superficial petrosal branch of the facial to the spheno-palatine ganglion and relayed in it.

Frontal Nerve.—Largest branch of ophthalmic. Arises in the cavernous sinus, passes into the orbit through the superior orbital fissure above rectus lateralis between the lacrimal and trochlear nerve. Runs straight forwards immediately below the middle of the roof of orbit on the surface of levator palpebræ, and, at a variable point, divides into two branches which are distributed mainly to skin of front of head:—(*a*) **supra-orbital nerve,** which leaves through supra-orbital notch, and (*b*) **supratrochlear nerve**—a smaller nerve—which escapes a finger's-breadth medial to that, above the tendon of obliquus superior near the pulley.

Abducent Nerve (6th cranial. *See also* pp. 532, 569).—Passes from cavernous sinus into orbit through superior orbital fissure between the heads of rectus lateralis; runs forwards along the ocular surface of that muscle, and enters its substance.

Oculomotor Nerve (3rd cranial. *See also* pp. 511, 568).—Splits in cavernous sinus (p. 58) into two divisions—upper and lower—both of which enter the orbit through superior orbital fissure between the heads of rectus lateralis.

Upper branch bends upwards across the lateral side of optic nerve, pierces rectus superior (supplying it) and ends by entering and supplying levator palpebræ.

Lower branch runs forwards in the fat on the floor of orbit to end in obliquus inferior. On its way it sends one branch to rectus medialis and two to rectus inferior, and gives off the motor root to the ciliary ganglion. The fibres of that root end in the ganglion; new fibres arise in the ganglion and are carried by the short ciliary

nerves into the eyeball to supply two of the muscles in it—ciliary muscle and sphincter pupillæ.

Naso-Ciliary Nerve.—Arises in cavernous sinus from the ophthalmic. Enters orbit through superior orbital fissure between the heads of rectus lateralis and between the two divisions of oculomotor nerve; curves medially above optic nerve to reach the medial wall of orbit; runs forwards a short distance between obliquus superior and rectus medialis to the anterior ethmoidal foramen, where it ends by dividing into the infratrochlear and anterior ethmoidal nerves.

Branches of Naso-ciliary.—1. **Sensory root** of ciliary ganglion arises as naso-ciliary enters orbit, and runs forwards along the lateral side of optic nerve.

2. Two **long ciliary nerves** arise as naso-ciliary crosses optic nerve; they run along that nerve and enter the back of the eyeball; they are mainly sensory, but carry some sympathetic motor fibres derived from internal carotid plexus for the supply of a muscle inside eyeball —dilator pupillæ.

3. **Posterior ethmoidal nerve,** very slender, traverses the canal of that name, and is distributed to mucous membrane of sphenoidal and ethmoidal sinuses.

4. **Infratrochlear nerve** runs forwards along medial wall of orbit, sends a communicating branch up to the supratrochlear, passes below the pulley of obliquus superior and leaves orbit *above* the medial angle of the eye to supply skin of upper half of nose, medial part of eyelids, conjunctiva, lacrimal caruncle and sac.

5. **Anterior ethmoidal nerve** passes through anterior ethmoidal canal into cranial cavity (p. 56).

Ciliary Ganglion.—"Pin-head" size. Lies a little behind the eyeball in the fat on the lateral side of the optic nerve.

Roots.—Long, *sensory*, from naso-ciliary. Short, *motor*, from lower branch of oculomotor. *Sympathetic*, from internal carotid plexus: this filament enters orbit alongside ophthalmic vein and either runs straight to the ganglion or joins the sensory root.

Branches.—Several **short ciliary nerves**; they divide into about 20 filaments that run forwards to pierce sclera around the optic nerve. Short ciliary nerves contain :—(*a*) Sensory fibres for interior of eyeball pass through the ganglion from the sensory root. (*b*) Motor fibres for blood-vessels of eyeball pass through the ganglion from the sympathetic root. (*c*) Motor fibres for the ciliary muscle and sphincter pupillæ arise in the ganglion and convey impulses brought to it by its motor root from the oculomotor nerve.

Lacrimal Gland.—About the size of a bean. Lies in a fossa in the antero-lateral part of roof of orbit, separated from eyeball by fat and levator palpebræ and rectus lateralis. Attached to orbital margin by fibrous strands. Sends a **palpebral process** into the lateral part of upper eyelid between the palpebral fascia and the

conjunctiva; and the *palpebral branch of lacrimal nerve* descends in front of the process. In a living person, the process may be seen bulging the conjunctiva when the lid is turned up.

The **ducts,** about a dozen, open into the lateral part of upper fornix of conjunctiva.

Blood-vessels: Lacrimal. **Nerves**: *Sensory*—lacrimal. *Secretory.* Impulses taken by greater superficial petrosal of facial to sphenopalatine ganglion, relayed and sent on by its orbital branches and by the zygomatic branch of maxillary, which sends a communicating filament to the lacrimal nerve.

Lacrimal Sac.—*See* p. 271.

SAGITTAL SECTION OF SKULL

Made on one side of median plane to show side-wall of nasal cavity on one half and septum on the other.

Cavity of Nose.—Roof: *Sloping, anterior part*: nasal bone and nasal part of frontal. *Horizontal, middle part*: cribriform plate of ethmoid. *Sloping, posterior part*: body of sphenoid, supplemented by (1) sphenoidal conchæ—curved plates of bone fused to anterior and under surfaces of sphenoid and presenting the opening of sphenoidal sinus; (2) ala of vomer; (3) sphenoidal process of palatine; (4) vaginal process of medial pterygoid plate.

Floor: Palatine process of maxilla; horizontal part of palatine bone.

Lateral wall: Nasal bone, medial surfaces of frontal process and body of maxilla, lacrimal, labyrinth of ethmoid, perpendicular plate of palatine, medial pterygoid plate. Nasal conchæ — superior and middle — project medially from labyrinth; inferior concha is separate and projects medially from its articulation with maxilla, lacrimal, ethmoid and palatine.

Spaces below and lateral to conchæ are the *superior, middle* and *inferior meatuses* of the nose. On lateral wall of middle meatus there is a rounded eminence called *bulla ethmoidalis,* bounded in front and below by a curved groove called *hiatus semilunaris.*

Spheno-ethmoidal recess is the small interval above superior concha.

Medial wall is the bony part of septum: Perpendicular plate of ethmoid above, vomer posteriorly and below;

upplemented by (1) nasal crest, which is formed by rticulating margins of nasal bones ; (2) nasal spine of rontal bone ; (3) sphenoidal crest on the anterior surface f sphenoid ; (4) nasal crest, which is formed by upturned dges of palatine bone and maxilla where they articulate vith their fellows.

Relations.—*Above*: frontal and sphenoidal sinuses, nterior and middle cranial fossæ. *Below*: mouth. *Laterally*: maxillary sinus, ethmoidal sinuses, orbit, terygoid, pterygo-palatine and infratemporal fossæ. t opens *posteriorly* into nasal part of pharynx, and *nteriorly* on to the face.

Communications—*Naso-lacrimal canal*, from orbit, pens into inferior meatus. **Incisive canal**, near median lane, descends and divides to open into incisive fossa y the lateral and median incisive foramina (p. 39). *pheno-palatine for.* (p. 37) opens into pterygo-palatine ssa from upper and back part, above posterior end of iddle concha. *Olfactory foramina* (p. 44) in cribriform late lead up into anterior cranial fossa.

Maxillary sinus (p. 312) opens into middle meatus. arge opening in the medial wall of the sinus is covered y inferior concha, lacrimal, perpendicular plate of pala- ne, uncinate process of ethmoid, but they leave one or wo small openings into hiatus semilunaris.

Frontal sinus (p. 62) opens into hiatus semilunaris.

Ethmoidal sinuses occupy labyrinth, and are divided into roups : *anterior* open into h. semilunaris ; *middle*, on ulla ethmoidalis ; *posterior*, into superior meatus.

Sphenoidal sinus opens into *spheno-ethmoidal recess.*

Sinus in orbital process of palatine communicates with phenoidal or posterior ethmoidal sinuses.

BONES OF UPPER LIMB

SHOULDER-GIRDLE—CLAVICLE AND SCAPULA

Clavicle.—Lies nearly horizontally on front of upper art of thorax ; palpable in its whole length. Curved like alic letter *f* ; medial half convex forwards ; lateral half onvex backwards, and flattened from above downwards. **Sternal end** can be felt overriding sternum. Rough bove ; smooth below for articulation with first costal

cartilage, and with the articular disc which separates the clavicle from the sternum.

Acromial end: flattened; facet on lateral edge looks sidewards and slightly downwards, and articulates with acromion of scapula—an articular disc intervening.

Shaft.—Medial two-thirds: *Surfaces*: (1) *anterior*, convex and rough; (2) *posterior*, concave and smooth; (3) *superior*, smooth, narrow, and may be merged into anterior surface; (4) *inferior* presents rough *impression for costo-clavicular lig.* medially, and longitudinal *groove for subclavius* laterally.

Lateral third: *Surfaces*: (1) *superior*, subcutaneous in middle; roughened anteriorly and posteriorly by attachments of deltoid and trapezius muscles; (2) *inferior* presents, near posterior border, the *conoid tubercle*, from which the *trapezoid ridge* runs forwards and sidewards. *Borders*: (1) *posterior*, convex; (2) *anterior*, concave, rough, and may present tubercle, called *deltoid tubercle*. Borders are continuous with anterior and posterior surfaces of medial two-thirds. *Nutrient foramen* is on the back and is directed sidewards.

In skiagrams, the shadow of clavicle is nearly always very oblique. For, in recumbent posture, the scapula is moved up, and the lateral end of clavicle moves with it; and, when arm is abducted, the accompanying rotation of scapula raises acromion and lateral end of clavicle.

Ossification.—Two primary centres at 5th or 6th week—first in body to appear—and they soon fuse. Epiphyseal centre for *sternal* end at 20th year, fused at 25. Epiphyseal line is intracapsular.

ATTACHMENTS.—Interclavicular lig. and articular disc to rough part of **sternal end**; articular capsule to margins of smooth part. Sterno-hyoid and sometimes sterno-thyroid from medial part of **posterior surface.** Sterno-mastoid from **upper surface** in medial third; pectoralis major from **anterior surface** in medial two-thirds.

Costo-clavicular lig. to its **impression.** Subclavius to **groove for subclavius,** and clavi-pectoral fascia to its lips. Deltoid from **ant. border of lateral third,** and trapezius to **post. border,** both encroaching on **upper surface.** Conoid lig. to **conoid tubercle.** Trapezoid lig. to **trapezoid ridge.** Articular capsule to margins of facet on **acromial end.** Deep fascia of the muscles is attached at margins of muscular attachments, and deep fascia of roof of posterior triangle of neck is attached, in two layers, to upper and lower margins of the back of middle third.

RELATIONS.—Clavicle forms the boundary between the neck and front of chest and front of upper limb.

Lateral, intermediate and medial supraclavicular branches of the 3rd and 4th cervical nerves descend *superficial* to the corresponding thirds, to supply skin over pectoralis and deltoid. Platysma is superficial to these, over the lateral two-thirds.

Behind the medial inch or so of the clavicle there are, from before backwards, sterno-hyoid, sterno-thyroid, innominate vein, phrenic nerve and int. mammary artery, pleura and lung. More laterally, the nerve to subclavius, ext. jugular and subclavian veins, scalenus anterior, and first rib are behind. More laterally still, about its middle third, the suprascapular vessels run nearly horizontally behind it, and farther back there are the omo-hyoid, the third part of subclavian artery, brachial plexus, and first digitation of serratus anterior. Trapezius occupies the lateral third of posterior aspect.

Beneath the clavicle, there are the costo-clavicular lig., subclavius and clavi-pectoral fascia, coraco-clavicular lig., which are all attached to it. Besides these, from sternal to acromial end, there are: (1) first cartilage; (2) anterior end of first rib; (3) axillary vein; (4) axillary artery; (5) brachial plexus; (6) coracoid process; (7) coraco-acromial lig., supraspinatus and shoulder-joint.

A few lymph-glands lie in the hollow below the clavicle between pectoralis and deltoid.

Scapula.—Lies on the postero-lateral wall of thorax opposite 2nd to 7th ribs, and in posterior wall of axilla.

Flat and triangular. A triangular *spine* juts backwards from dorsal surface; a bent *coracoid process* projects from upper border; and a flat *acromion* is continuous with the apex of the spine.

Margins.—(1) *Superior*, the shortest. **Suprascapular notch**, at its lateral part, is converted by suprascapular ligament into a foramen which transmits suprascapular nerve. (2) *Medial*, the longest. (3) *Lateral*, the thickest; rough patch at its upper end is the *infraglenoid tubercle*.

Angles: (1) *Superior*, obtuse; between superior and medial margins. (2) *Inferior*, acute; between medial and lateral margins; easily felt; lies at level of 7th thoracic spine. (3) *Lateral*, between superior and lateral margins; forms *head* and *neck* of scapula.

Glenoid cavity is a smooth, shallow concavity on head; piriform in shape, apex upwards; looks sidewards, upwards and forwards; articulates with head of humerus; slight roughness above apex is the *supraglenoid tubercle*.

Dorsal surface is unequally divided by the spine into the floors of a small *supraspinous fossa* and a large *infraspinous fossa*, which include also the upper and lower

surfaces of spine. Oval elevated area over inferior angle is for origin of teres major and a slip of latissimus dorsi. Elongated elevated area along lateral margin is for origin of teres minor ; transverse groove (or grooves) on that area is for circumflex scapular vessels.

Costal surface is hollowed out and forms the floor of the *subscapular fossa*—deepest opposite spine. Flat areas at superior and inferior angles and strip along medial margin are for insertion of serratus anterior.

Coracoid process projects from upper margin of neck. Vertical portion or *root* has posterior and anterior surfaces, lateral and medial borders; medial border bounds suprascapular notch laterally. *Horizontal portion* projects forwards and very slightly sidewards when scapula is in place ; has upper and lower surfaces, lateral and medial borders, and its tip can be felt under cover of anterior margin of deltoid, one inch below the clavicle at the junction of its intermediate and lateral thirds.

Spine of scapula extends from medial margin to neck.

Upper and lower surfaces help to bound supraspinous and infraspinous fossæ.

Attached border is called its *root.*

Dorsal border or *crest* is subcutaneous, rough, easily felt ; has upper and lower lips, with a tubercle on lower lip near medial border. Junction of crest and medial border is opposite 3rd thoracic spine ; there, the crest is splayed out and is smooth for bursa under trapezius.

Lateral border is smooth and rounded. *Spino-glenoid notch,* between it and the neck of scapula, is bridged across by spino-glenoid lig., under which the suprascapular nerve and vessels descend to infraspinatus.

Acromion, flattened from above downwards, extends sidewards and forwards from apex of spine.

Lateral border, long ; sharply bent to become continuous with lower lip of crest. The bend is the **acromial angle,** which is easily felt and is opposite the shoulder-joint.

Medial border, short ; facet near the tip slopes downwards and medially and articulates with clavicle.

Superior surface, subcutaneous ; felt in top of shoulder.

Inferior surface is smooth and is separated from supraspinatus by the subacromial bursa.

Nutrient foramina here and there ; largest near spine.

Ossification.—Primary centre at 8th week. Epiphyseal centres: One for horizontal part of coracoid during 1st year, fuses at puberty. One for lateral part of coracoid root and upper part of glenoid at 10, fuses at puberty; its epiphyseal line is partly intracapsular and partly extracapsular. **Two or more for acromion at puberty; epiphysis usually fused at 25,** but **may remain separate.** One for inferior angle and one for medial border at puberty, fuse 20-25. One for lower edge of glenoid at puberty, fuses 20-25.

ATTACHMENTS.—Suprascapular lig. to margins of **suprascapular notch.** Inferior belly of omo-hyoid from ligament and adjoining lateral part of **upper margin.**

Levator scapulæ to **medial margin** above spine, rhomboideus minor opposite spine, rhomboideus major below spine.

Long head of triceps from **infraglenoid tubercle.** Long head of biceps from **supraglenoid tubercle.** Labrum glenoidale and capsular lig. to circumference of **glenoid cavity.**

Supraspinatus from the walls of medial two-thirds of **supraspinous fossa.** Infraspinatus from the walls of **infraspinous fossa,** except (1) near neck, (2) oval area at inferior angle for teres major, (3) elongated area along lateral margin for teres minor.

Subscapularis from **costal surface,** including ridge and elongated hollow adjoining lateral margin, but excluding (1) part near neck and (2) areas and strip for serratus anterior.

Suprascapular lig. to medial margin of **root of coracoid**; coracohumeral lig. to lateral margin. Coraco-brachialis and short head of biceps from tip of **horizontal part of coracoid**; pectoralis minor to medial margin and upper surface of anterior half, clavi-pectoral fascia to posterior half of medial margin; coraco-acromial lig. to lateral margin; coraco-clavicular lig. to upper surface.

Deltoid from lower lip of *crest* of **spine** and from lateral border of **acromion**; trapezius to medial border of acromion, upper lip of crest, and tubercle on lower lip. Capsular lig. to circumference of *facet* on acromion; coraco-acromial lig. to **tip.**

Spino-glenoid lig. to spine and head.

Humerus.—Proximal end is the large, globular end, and comprises *head, anatomical neck, greater* and *lesser tuberosities, bicipital groove* and *surgical neck.*

Head is large, convex, smooth and nearly hemispherical; directed medially, upwards and backwards; articulates with glenoid cavity of scapula.

Anatomical neck is the slight constriction around margin of the head—best marked between head and tuberosities.

Greater tuberosity is the prominence on lateral side of proximal end; is the most lateral part of shoulder or "point of shoulder". Has three impressions for muscles

on top and back; anterior margin is lateral lip of bicipital groove; lateral surface, smooth, covered by deltoid and bursa, is directly continuous with shaft.

Lesser tuberosity is the prominence on the front; may be felt, in the living person, one inch lateral to coracoid process and a little distal to it.

Bicipital groove is between the tuberosities, and it extends on to surgical neck and shaft. It lodges the long tendon of biceps and its synovial sheath, and a branch of the anterior circumflex artery.

Surgical neck is the finger-breadth below the head and the tuberosities.

Distal End.—Compressed antero-posteriorly and bent forwards. Comprises *capitulum, trochlea*; *radial, coronoid* and *olecranon fossæ*; *lateral* and *medial epicondyles*.

Capitulum, situated laterally, on anterior and distal aspects; smooth, convex; articulates with radius.

Radial fossa, on the front, above the capitulum, for head of radius during full flexion.

Trochlea, placed medially on anterior, distal and posterior aspects. Pulley-shaped; medial lip is the more prominent; the floor of a shallow groove unites the lateral lip with capitulum. Articulates with ulna.

Coronoid fossa, on the front above the trochlea, for coronoid process of ulna during flexion. **Olecranon fossa,** on the back above trochlea, for olecranon during extension; it is much larger than the other fossæ, and the bone that separates it from coronoid fossa is very thin.

Lateral epicondyle, lateral to capitulum; impressions on anterior and distal aspects for muscles and ligaments; posterior aspect is broad, smooth, is felt subcutaneously above back of elbow, and is separated by a curved groove from trochlea medially, from capitulum distally.

Medial epicondyle is large and prominent; easily felt above the medial side of elbow; rough on anterior and distal aspects for muscles and ligaments; posterior aspect is smooth, and presents a groove in which the ulnar nerve may be felt and rolled by the finger.

Shaft of Humerus.—3 borders and 3 surfaces.

Anterior margin begins at greater tuberosity, ends near coronoid fossa; proximal part is the lateral lip of bicipital groove; middle part is the anterior margin of deltoid tuberosity.

Medial margin begins at lesser tuberosity, ends at medial epicondyle; forms medial lip of bicipital groove; is roughened in middle for insertion of coraco-brachialis; lowest part is the *medial supracondylar ridge*.

Lateral margin begins below the back of greater tuberosity and ends at lateral epicondyle; indistinct proximally, where lateral head of triceps arises; interrupted at middle by an oblique groove for radial nerve; distal part is the *lateral supracondylar ridge*.

Antero-medial surface is between anterior and medial margins; floor of bicipital groove is its upper part.

Antero-lateral surface is between anterior and lateral margins; ▽-shaped *deltoid tuberosity*, for insertion of deltoid, is just above its middle.

Posterior surface, between medial and lateral margins, is occupied by origin of medial head of triceps. *Spiral groove* begins on posterior surface, runs obliquely downwards and forwards between origins of medial and lateral heads of triceps, and behind the deltoid tuberosity, to end below that tuberosity; radial nerve and profunda vessels lie in it.

Upper part of shaft is rounded, and surfaces are ill-defined. Surfaces are more distinct in lower part; but there the antero-lateral and antero-medial surfaces are often included under one name—*anterior surface*.

Nutrient foramen, on or near middle of medial border, is directed downwards. Another is often present in the floor of the spiral groove.

Ossification.—Primary centre for shaft at 7th week. Epiphyseal centres: one for head shortly after birth; one for greater tuberosity, 2-3 yr.; one for lesser tuberosity, 3-5 yr. These fuse to form one epiphysis at 6 and join shaft at 18 in female and 21 in male. Tuberosities do not always have separate centres, but may be ossified by extensions from head. Epiphyseal line is intracapsular medially, extracapsular laterally. One for capitulum and lateral part of trochlea, 1-2 yr.; one for medial part at 10; these fuse to form one epiphysis at 13 in F. and 15 in M., which joins shaft at 15 F. and 19 M. Lateral end of epiph. line is outside capsule; rest is inside. One for lateral epicondyle at 14; joins shaft at 15 F. and 18 M.; may fuse with capitulum before doing so; may be ossified by extension from capitulum. One for medial epicondyle at 5 F., 8 M.; fuses 15 F., 18 or later M.; epiphyseal line is extracapsular.

ATTACHMENTS.—Capsular lig. of shoulder to **anatomical neck** above, but nearly half an inch from it below and medially ; coraco-humeral lig. to anatomical neck at anterior oart of greater tuberosity.

Supraspinatus, infraspinatus, teres minor to three impressions on **greater tuberosity,** in that order antero-posteriorly. Subscapularis to **lesser tuberosity.** Teres minor and subscapularis both extend their insertions on to **surgical neck.**

To **bicipital groove** : transverse lig., attached to both tuberosities, bridges across its uppermost part ; lower down, on shaft, pectoralis major to its *lateral lip*, teres major to *medial lip*, latissimus dorsi to *floor*.

Common extensor tendon from front of **lateral epicondyle ;** from lower surface—lateral lig. of elbow and supinator anteriorly, anconeus posteriorly.

Medial lig. to lower border of **medial epicondyle ;** common flexor tendon from lower part of anterior surface, pronator teres from upper part, extending to supracondylar ridge.

Ant. lig. of elbow to upper margins of **radial** and **coronoid fossæ** and the front of the epicondyles. Post. lig. to margins of olecranon fossa on each side and across the upper part of its floor, and to the backs of the epicondyles.

Coraco-brachialis to middle of **medial margin of shaft.** Medial intermuscular septum to edge of **medial supracondylar ridge,** pronator teres from lower part of ant. aspect. Lateral head of triceps to upper third of **lateral margin.** Lateral intermuscular septum to edge of **lateral supracondylar ridge ;** brachio-radialis from upper two-thirds of its ant. aspect, extensor carpi radialis longus from lower third.

Brachialis from lower two-thirds of **antero-medial** and **antero-lateral surfaces.** Deltoid to **deltoid tuberosity.** Medial head of triceps from **posterior surface,** below spiral groove.

Ulna.—Medial and longer bone of forearm.

Proximal end is the larger end, and comprises *olecranon, coronoid process, radial notch* and *trochlear notch*.

Olecranon, placed posteriorly, is the uppermost inch of ulna, and forms the prominence of the elbow. It has *anterior, posterior* and *upper surfaces,* and *lateral* and *medial borders* or surfaces. Borders and upper surface are rough. Posterior surface is smooth and triangular, and is separated from skin by subcutaneous bursa. Anterior surface, smooth and articular, helps to bound the trochlear notch.

Coronoid process projects forwards ; has upper, lower, lateral and medial surfaces. *Upper surface,* smooth and articular, is the lower boundary of the trochlear notch.

Lower or *anterior surface* is markedly rough. *Medial surface*, slightly concave, is continuous with medial side of shaft, and is separated from anterior surface by a tubercle and vertical ridge.

Radial notch occupies *lateral surface*. Concave from before backwards ; articulates with head of radius.

Trochlear notch is the wide concavity bounded by olecranon and coronoid ; notched at the sides. Trochlea of humerus fits into it ; and it is divided by a blunt, vertical ridge into areas that correspond to the lateral and medial parts of trochlea.

Distal End.—Comprises *head* and *styloid process*.

Head is smooth and rounded. Its distal surface articulates with triangular articular disc. Its lateral surface articulates with radius when arm is supine ; when arm is prone the anterior surface articulates with radius, and lateral surface is the knob seen above the wrist.

Styloid process, short and blunt, juts downwards from postero-medial aspect ; felt as a ridge above medial side of back of wrist when arm is supine ; is separated from posterior surface of head by a groove occupied by extensor carpi ulnaris tendon ; at its base, between it and distal surface of head, there is a shallow pit for attachment of apex of triangular articular disc.

Shaft of Ulna.—Tapers to distal end. Has anterior, posterior and lateral borders ; posterior, anterior and medial surfaces ; tuberosity ; supinator fossa and crest ; and pronator ridge.

Tuberosity of ulna is the small, raised roughness on anterior surface just below coronoid. **Supinator fossa** is the large, triangular, rough depression below radial notch. **Supinator crest** is the prominent, posterior boundary of the fossa. **Pronator ridge** is on lower part of anterior surface, and may be indistinct. It begins near lateral border about two inches above distal end and runs spirally towards root of styloid process.

Anterior margin, blunt and smooth, extends from tuberosity to styloid process. **Posterior margin,** subcutaneous, easily felt, sinuous ; extends from back of olecranon to styloid process. **Lateral margin** is called **interosseous border,** because interosseous membrane is attached to it. Begins at the supinator fossa, becomes sharp and prominent in the middle but fades away near the distal end.

Anterior surface, between anterior and interosseous borders, presents: (1) **nutrient foramen,** directed towards elbow, on upper third; (2) tuberosity at upper end; (3) pronator ridge in lower part. **Medial surface,** between anterior and posterior margins, is subcutaneous in lower third and easily felt. **Posterior surface,** between posterior and interosseous borders, is divided by vertical ridge into a bare, smooth *medial* part, and a *lateral* part mapped into areas for attachments of extensor muscles.

Ossification.—Primary centre at 8th week. Epiphyseal centres: One for top of olecranon at 11; fuses at 15 F., 18 M.; epiphyseal line may be wholly extracapsular, or may be intracapsular anteriorly. One for distal end at 8; fuses 19 F., 21 M.; epiphyseal line is extracapsular.

ATTACHMENTS.—Olecranon: Triceps to posterior part of *upper surface*; bursa is in relation to middle part; posterior lig. of elbow to anterior part of upper surface and to *lateral surface*; anconeus to lateral surface, behind the lig. Posterior band of medial lig. of elbow to *medial surface*, flexor carpi ulnaris and flexor profundus from medial surface, behind the lig.

Coronoid process: Anterior band of medial lig., flexor sublimis, flexor pollicis longus and pronator teres from *tubercle* and *ridge* between lower and medial surfaces. Anterior lig. of elbow to *anterior margin*. Brachialis to *lower surface*.

Radial notch: Annular lig. to anterior and posterior margins; quadrate lig. to lower margin.

Shaft: Brachialis and oblique cord to *tuberosity*. Supinator from *supinator crest* and *fossa*. Flexor dig. profundus from upper two-thirds of *anterior* and *medial surfaces*, extending on to medial surfaces of coronoid and olecranon. Pronator quadratus from lower fourth of *anterior surface* and from *pronator ridge*. Anconeus to upper part of *posterior surface* of shaft and adjoining lateral side of olecranon. Abductor pollicis longus, extensor poll. longus and ext. indicis from lateral part of *posterior surface*, in that order proximo-distally. Interosseous membrane to *interosseous border*. Flexor carpi ulnaris from medial side of olecranon and proximal three-fifths of *posterior border* of shaft.

Head: Articular capsule of inferior radio-ulnar joint to posterior and anterior surfaces; a septum of extensor retinaculum to posterior surface.

Styloid process: Medial lig. of wrist to tip; apex of triangular articular disc to pit at base; extensor retinaculum to the back.

Radius.—Lateral bone of forearm.

Proximal end is the smaller end, and comprises *head*, *neck* and *tuberosity*.

Head, a disc cupped on its *upper surface* to articulate with capitulum humeri. *Circumference* articulates with radial notch of ulna and is embraced by annular lig. of radius; but it is easily felt at the back of the elbow below the lateral epicondyle.

Neck is the constricted portion that supports head.

Tuberosity of radius, placed on medial side, below the neck; is smooth anteriorly for a bursa, but is rough posteriorly for insertion of biceps.

Distal end, expanded and bent forwards. Has 5 *surfaces,* a *styloid process,* a *dorsal tubercle* and an *ulnar notch.*

Styloid process, short and conical, juts down from the lateral side; can be felt in the hollow on radial side of wrist; its tip reaches a lower level than styloid of ulna.

Dorsal tubercle is the most prominent of the ridges on the back, and can usually be felt in the living limb.

Medial surface is concave and smooth to articulate with head of ulna; the concavity is the **ulnar notch.**

Distal or **carpal surface,** concave, smooth, articular; divided into two areas: *lateral area,* triangular, extends on to styloid process, articulates with scaphoid bone; *medial area,* square, articulates with lunate bone.

Lateral surface, less than ½ in. wide; extends on to styloid process; slightly grooved by tendons of abd. pollicis longus and extensor poll. brevis, which cover it.

Posterior surface, uneven, convex, reaches farther down than anterior surface. Dorsal tubercle is about its centre. Wide, shallow groove lateral to tubercle lodges tendons of extensor carpi radialis longus and brevis and is sometimes divided into two. Narrow, oblique groove at medial side of tubercle is for tendon of extensor pollicis longus; wide, shallow groove medial to that is for tendons of extensor digitorum and extensor indicis.

Anterior surface, wide, smooth, slightly concave; limited distally by a thick, rough ridge that can be felt above wrist; limited laterally by a sharp edge that separates it from lateral surface, and also can be felt in living limb.

Shaft of Radius.—Thickens from above downwards. Has anterior, posterior and medial borders; posterior, anterior and lateral surfaces.

Anterior margin extends from tuberosity to ridge between front and lateral side of distal end; upper part is distinct and oblique, lower part indistinct. **Posterior**

margin extends from back of tuberosity to dorsal tubercle; upper third is oblique and indistinct; middle third distinct; lower third is a blunt, indistinct ridge. **Medial margin** is called **interosseous border,** because interosseous membrane is attached to it. It begins near tuberosity and ends distally by dividing into two lines which enclose a narrow, triangular area above ulnar notch.

Anterior surface, between anterior and interosseous borders, presents *nutrient foramen* on upper third, directed towards elbow. **Posterior surface,** between posterior and interosseous margins, gives origin to muscles in upper two-thirds, but in lower third is only covered by the tendons that groove distal end. **Lateral surface,** between anterior and posterior borders, encroaches in its upper third on anterior and posterior aspects, and on posterior aspect distally; and it has a rough, oval mark about its middle for insertion of pronator teres.

Radius is convex medially in proximal ¼, convex laterally in distal ¼. Biceps and pronator teres are inserted into maximum points of curves and their actions as supinator and pronator are thus enhanced.

Ossification. — Primary centre at 8th week. Epiphyseal centres: one for head, 5-7 yr.; fuses 15 F., 18 M.; epiphyseal line is intracapsular. One for distal end, 1-2 yr., fuses 20 F., 21 M.; epiphyseal line is extracapsular. One for tuberosity at 15 and soon fuses.

ATTACHMENTS.—Distal margin of annular lig. and lateral margin of quadrate lig. around **neck,** loosely. Biceps to posterior part of **tuberosity** and separated from anterior part by bursa.

Shaft: Oblique cord below tuberosity. Flexor dig. sublimis from upper part of *anterior margin.* Flex. poll. longus from upper three-quarters of *anterior surface.* Pronator quadratus to lower quarter of *anterior surface* of shaft, to anterior surface of distal end and to triangle above ulnar notch. Interosseous membrane to *interosseous border* and to the posterior of the two lines into which it divides. Supinator to upper third of *lateral surface,* including its encroachments on to front and back, and extending upwards to neck. Pronator teres to middle of lateral surface. Abductor pollicis longus and ext. poll. brevis from *posterior surface.*

Distal end: Anterior radio-carpal lig. to distal ridge on anterior surface. Lateral lig. of wrist to *styloid process*; posterior radio-carpal lig. to distal margin of posterior surface. Base of triangular articular disc to edge between carpal and medial surfaces. Articular capsule of inferior radio-ulnar joint to anterior and posterior margins of ulnar notch. Lateral end of extensor retinaculum

to ridge between anterior and lateral surfaces, and its septa to ridges on posterior surface. Brachio-radialis to upper part of lateral surface.

Carpus or **Wrist.**—Composed of 8 small bones arranged in two rows, and named from lateral to medial side:—

Proximal row: scaphoid; lunate; triquetrum; and pisiform, on the front of triquetrum.

Distal row: trapezium; trapezoid; capitate; hamate.

All except triquetrum and pisiform have 6 surfaces.

Carpus, looked at as a whole, has 6 surfaces.

Proximal surface: convex; articulates with radius and triangular articular disc to form wrist-joint.

Distal surface: irregular; articulates with metacarpus.

Posterior surface: convex; rough for ligaments; related to extensor tendons, and, laterally, to radial artery.

Anterior surface: rough for ligaments and muscles. Deeply concave on account of projection of tubercle of scaphoid and ridge on trapezium at the lateral side, and pisiform and hook of hamatum at the medial side. This concavity or groove lodges the flexor tendons and their sheaths and the median nerve; and it is bridged across by the flexor retinaculum.

Radial or **lateral surface:** rough for ligaments; is related to extensor tendons of thumb. **Ulnar** or **medial surface** is rough for ligaments and is subcutaneous.

Proximal row, looked at by itself, is convex proximally, concavo-convex distally, and its dorsal surface is smaller than the palmar. **Distal row** is concavo-convex proximally, irregular distally; dorsal surface is larger than palmar.

Parts to be specially noted:—**Tubercle of Scaphoid**—felt immediately above ball of thumb, close by lateral margin of flexor carpi radialis tendon. **Crest of trapezium**—felt in ball of thumb, distal to tubercle. **Pisiform**—the knob at medial margin of front of wrist. **Hook of hamatum**—felt in ball of little finger, one inch below and lateral to pisiform.

Carpus is cartilaginous at birth. Ossification is completed between 20 and 25.

Each bone has one or more salient characters by which it can be distinguished. Triquetrum is a 3-sided pyramid, base being lateral surface. Trapezoid is the smallest except pisiform, and has a fancied

(*Continued on* p. 88.)

Names and Dates of Appearance of Ossifying Centres of Carpal Bones.	Surfaces : Characters, Articula-	
	Proximal.	Lateral.
Os Scaphoideum (Os Naviculare) Female, 4th year. Male, 6th year.	Is the larger of the 2 convex surfaces ; articulates with radius	*Tubercle* ; lateral lig. abductor poll. brevis ; flexor retinaculum
Os Lunatum . . . . F. 3-4. M. 4-5.	Convex ; radius and triangular articular disc	Flat, *crescent facet* ; scaphoid ; interosseous lig.
Os Triquetrum . . . F. 2-3. M. 3-4.	Convex ; with medial lig. of wrist, and, during adduction, with triangular articular disc	Base, flat ; lunatum
Os Pisiforme . . . . F. 9-10. M. 13-14.	*Dorsal surface* is flat, circular and articulates with of *palmar surface* is related to ulnar nerve retinaculum is attached to ridge between latera palmar lig. of carpus, medial lig., piso-hamate and	
Trapezium (Os Multangulum majus) F. 4-5. M. 6.	Concave ; scaphoid	Broad, flat, rough ; lateral ligs. of wrist-joint and carpus
Trapezoid (Os Multangulum minus) F. 4-5. M. 6.	Smallest articular surface, concave scaphoid	Separated from distal surface by triangular roughness ; trapezium
Os Capitatum . . . 6th month after birth.	Convex ; lunatum	Convex proximally for scaphoid, flat distally for trapezoid
Os Hamatum . . . . 6th month after birth.	A border, sometimes articulating with lunatum	Flat ; capitatum

or Names of Structures attached or related to them.

Distal.	Medial.	Palmar.	Dorsal.
ller convex sur-e; trapezium d trapezoid	*Concavity* distally for capitatum, flat proximally for lunatum	Broad, rough, concave; palmar radio-carpal and intercarpal ligs.	Narrow, rough; dorsal radio-carpal and intercarpal ligs.
lunar con-*vity*; capitatum	Flat, quadrilateral; triquetrum	Large, convex, rough; palmar ligs.	Small, rough; dorsal radio-carpal and intercarpal ligs.
avo-convex; matum	Apex, rough; medial ligs. and extensor retinaculum	Flat, circular facet medially for pisiform; articular capsule, palmar ligs.	Confluent with proximal surface; dorsal ligs.

etrum. Other surfaces are confluent. *Distal surface* bulges. Lateral part *al surface* is concave and helps to form medial wall of carpal tunnel. Flexor nterior surfaces. Other attachments are: articular capsule; piso-metacarpal ligs.; r carpi ulnaris, abductor digiti minimi

le-shaped; 1st tacarpal; sur-nded by arti-ar capsule	Large proximal area for trapezoid small distal area for 2nd metacarpal	*Narrow groove* for tendon of flex. carpi rad.; *crest* and rough surface for flexor retinac. palmar ligs.; abd. brevis, adductor, opponens, flex. brev. pollicis	Rough; dorsal intercarpal and carpo-metacarpal ligs. Radial art. crosses it.
avo-convex or ddle-shaped; 2nd tacarpal	Concave; capitatum	Small, rough; palmar ligs., adductor pollicis	Large, rough; dorsal intercarpal and carpo-metacarpal ligs.
rge facet for l metacarpal, 2 aller for 2nd and d	Flat; hamatum	Convex, rough; palmar ligs., adductor pollicis	Broad, flat, rough; dorsal intercarpal and carpo-metacarpal ligs.
oth, divided by tero-posterior ge into *twin ets* for 4th and n metacarpals	Concavo-convex and sloping upwards and laterally for triquetrum, rough edge distally for medial ligs.	Rough for palmar ligs. Presents *hook* for flex. retinac. piso-hamate lig., opponens and flex. dig. minimi	Broad, rough; dorsal intercarpal and carpo-metacarpal ligs.

resemblance to a Chinese boot. Capitatum is the largest and is surmounted by large, rounded head. Distinguishing characters of the others are *italicised* in the TABLE on pp. 86, 87.

In order that a bone may be referred to its proper side it should be held in the position which it occupies in erect body (proximal surface directed upwards, anterior surface forwards). Lateral surface (or border or end) then looks towards side to which it belongs.

Metacarpus.—Skeleton of palm. Five bones, numbered 1 to 5 from radial side. Each has :—(1) proximal end or base, which articulates with carpus ; (2) a shaft ; (3) distal end or head, which articulates with first phalanx. Heads of metacarpals are the proximal row of knuckles.

IN MEDIAL FOUR (2-5) : Head : Convex ; smooth distally and in front, to articulate with phalanx and with palmar lig., which is attached to shaft immediately above head. Rough at sides for collateral ligs.

Shaft : Curved longitudinally, with palmar concavity. Prismatic on transverse section — dorsal, lateral and medial surfaces. 2nd, 3rd, 4th each give origin to two dorsal interossei, 5th to one ; 2nd, 4th, 5th each give origin to one palmar interosseous. Adductor pollicis arises from palmar border of 3rd ; opponens digiti minimi is inserted into ulnar side of 5th.

Bases : Articulate with one another and with carpus ; palmar, dorsal and interosseous ligs. connect them to one another and to carpus. Adductor pollicis arises from palmar surface of 2, 3 and 4, and deep palmar arch lies immediately distal to them.

Distinguishing features are on bases. Second is *notched* for trapezoid. Medial margin of notch articulates with capitatum. *Lateral* boundary, small and pointed, articulates with trapezium. Extensor carpi radialis longus and brevis are inserted into dorsum ; flexor carpi radialis into front.

Third articulates with capitatum. Has a short **styloid process** that juts upwards from dorso-*lateral* part. Ext. carpi radialis brevis inserted into dorsum at base of styloid ; flex. carpi rad. into the front.

Fourth is cuboidal. Articulates with hamatum and slightly with capitatum ; double metacarpal facet is on *lateral side.*

Fifth : Concavo-convex articular surface for hamatum. Tubercle on medial side ; metacarpal facet is on *lateral* side. Ext. carpi ulnaris inserted dorso-medially ; piso-metacarpal lig. on the front.

FIRST METACARPAL : Shorter, stouter than others ; compressed from before backwards.

Head : Elongated transversely, grooved on the front by sesamoid

ones in adductor and flexor pollicis brevis ; collateral ligs. attached t sides, and palmar lig. to shaft immediately above head.

Shaft : Palmar surface divided by ridge into larger *radial area* or opponens and smaller *ulnar area* for first dorsal interosseous. urfaces look laterally and medially rather than backwards and rwards ; and the whole bone is farther forwards than the other etacarpals. This position and obliquity account for the efficiency f the thumb as part of a gripping instrument.

Base : *Saddle-shaped* articular surface for trapezium surrounded v articular capsule ; abductor poll. longus inserted into radial nd palmar surface of base ; first palmar interosseous arises from edial side. *Usually does not articulate with 2nd.*

Ossification.—Primary centre for *shaft and base* of **medial four** ring 9th week ; for *shaft and head* of **first** a little later. Well sified at birth. Epiphyseal centre for heads of medial four— . 2, M. 3. Base of first—F. 2½, M. 3½. Fuse—F. 17, M. 19. piphyseal lines are extracapsular.

To Determine the Side.—Hold base upwards, palmar surface rwards. Lateral aspect then looks to its own side.

Digits are numbered 1 to 5 from radial to ulnar side and re named : pollex (thumb), index (forefinger), digitus edius (middle finger), digitus annularis (ring-finger), igitus minimus (little finger).

Phalanges.—Each finger has three phalanges, which iminish in size, and are named proximal, middle and istal. Thumb has two, named proximal and distal. ach is compressed antero-posteriorly. Base of proximal concave ; head is pulley-shaped. Base of middle has edian ridge with a hollow on each side of it ; head is ulley-shaped. Base of distal like that of middle, but ead is expanded and rough on palmar surface.

Proximal Phalanx : Base, concave, articulates with metacarpal, rrounded by articular capsule ; palmar lig. is attached to e front ; collateral ligs., lumbrical and interosseous muscles to les. *In the thumb*, extensor pollicis brevis to dorsum, adductor d first palmar interosseous to medial side, abductor brevis and xor brevis to radial side. **Shaft :** dorsal surface convex ; palmar, ncave, lodges flexor tendons ; fibrous flexor sheath attached to argins. **Trochlea,** pulley-shaped distal end, articulates with middle alanx, surrounded by articular capsule, collateral ligaments tached to sides ; palmar lig., proximal to palmar surface.

Middle Phalanx : Base has median ridge to fit trochlea of the oximal. Articular capsule surrounds base ; collateral ligs. attached sides, palmar lig. to the front, middle slip of extensor to dorsum. **aft** and **trochlea** are like those of the proximal phalanx, but flexor blimis also is attached to margins of shaft.

Distal Phalanx : Base like that of middle ; but flexor profundus and end of fibrous sheath are attached to the front ; collateral slips of extensor to dorsum. **Shaft :** palmar surface, flat and rough. **Distal end :** flat, expanded, rough on palmar surface.

Distal of thumb resembles distal of finger ; flex. poll. longus is inserted into palmar surface of base, ext. p. longus into dorsum.

Ossification.—Primary centre at 9th week. Well ossified at birth.

Epiphyseal centre for base in 2nd year F., 3 M. Fuses 17 F., 19 M.

Epiphyseal lines are extracapsular.

Sesamoid Bones.—Two nodules imbedded in flexor and adductor tendons inserted into proximal phalanx of thumb ; take the place of palmar lig. of metacarpo-phalangeal joint ; they articulate with palmar surface of head of first metacarpal, and groove it.

BONES OF LOWER LIMB

PELVIC GIRDLE—HIP-BONE

Hip-Bone (Os Coxæ).—Three parts : *ilium*, *ischium*, *pubis*, welded together at a hemispherical cavity called **acetabulum.**

Ilium : superior, large, expanded. **Ischium :** postero-inferior, short, stout. **Pubis :** antero-inferior, more slender.

Ischium and pubis enclose **obturator foramen,** below and medial to acetabulum. Ilium and ischium bound the **greater sciatic notch,** behind the acetabulum.

Os Ilium.—Expanded, flattened, fluted.

Lower end is fused with ischium and pubis, and forms rather less than two-fifths of the acetabulum.

Iliac crest is the long *f*-shaped upper border (or end) felt at lower limit of waist. Its *highest point*, about its middle, is well round at the back, and is at the level of body of 4th L. vertebra. Its margins are called *outer* and *inner lips* ; interval between them is called *intermediate area*. Anterior end of crest is called **anterior superior iliac spine,** which is readily felt. Posterior end, much nearer median plane, is called **posterior superior iliac spine,** position of which is indicated by dimple on skin above buttock, two inches from median plane, opposite middle of sacro-iliac joint, at level of 2nd sacral spine. *Tubercle of crest* is the prominence on the outer lip, felt about two inches and a half above and behind anterior superior spine ; forms highest point on crest in living body, *as seen from*

he front; and is at the level of body of 5th L. vertebra.

Anterior border extends from ant. sup. spine to margin f acetabulum at the *ilio-pubic eminence*, which marks unction between ilium and pubis. *Anterior inferior iliac pine* is the prominence on anterior border a little above cetabulum; ilio-psoas leaves abdomen through notch etween it and ilio-pubic eminence.

Posterior border extends sinuously from post. sup. spine o margin of greater sciatic notch opposite middle of cetabulum. *Posterior inferior iliac spine* is the pro- inence at the posterior end of sacro-iliac joint, one ich below posterior superior spine.

Medial border is a ridge that begins far back on inner p of crest, and runs down to ilio-pubic eminence. is upper part is rough; its lower part is smooth and lunt, and forms iliac part of the *arcuate line*.

Gluteal surface is concavo-convex. It is divided into reas for gluteal muscles by three curved lines that con- erge upon greater sciatic notch :—

1. *Inferior gluteal line* begins above ant. inf. spine and ns towards deepest part of sciatic notch; rough groove elow it, above acetabulum, is for the reflected head of ctus femoris and capsule of hip-joint.

2. *Middle gluteal line* begins in front of tubercle of rest and arches towards the sciatic notch.

3. *Posterior gluteal line* begins about three inches above sterior superior spine and curves downwards and rwards towards sciatic notch.

Iliac fossa is the wide concavity between medial and nterior borders.

Sacro-pelvic surface is the uneven area between medial nd posterior borders, and is divided into three parts :) *Iliac tuberosity* is the rough, upper part. (2) Middle art is the *auricular surface* for articulation with sacrum; s posterior end corresponds to post. inf. iliac spine.) Lowest part is smooth, and helps to form the side all of the true pelvis.

Os Ischii.—**Upper end** is fused with ilium and pubis, nd forms rather more than two-fifths of acetabulum. n upright sitting posture, the body rests on **lower end.**

Ischial tuberosity is the roughness on lower end and on wer part of dorsal surface.

Posterior border is continuous with posterior border of

ilium ; *ischial spine* is the spur that juts medially and backwards from about its middle.

Greater sciatic notch is the wide gap between posterior inferior iliac spine and ischial spine ; it is bounded by the posterior borders of ilium and ischium.

Lesser sciatic notch is the small gap between ischial spine and tuberosity.

The sacro-spinous and sacro-tuberous ligs. convert the notches into *greater* and *lesser sciatic foramina*.

Anterior border helps to bound obturator foramen.

Lateral border is interrupted by a notch which lodges obturator externus, between acetabulum and ischial tuberosity.

Dorsal surface supports piriformis, obturator internus, gemelli and sciatic nerve ; is encroached on by ischial tuberosity below ; is continuous with gluteal surface of ilium above, the junction being marked by a low transverse ridge or fullness on the dorsum of acetabulum.

Femoral surface looks towards thigh, and is covered by obturator externus.

Pelvic surface is continuous with pelvic surface of ilium, and forms a large part of the side-wall of true pelvis.

Ramus of ischium extends forwards and medially from lower end, and joins inferior ramus of pubis ; these " conjoined rami " form the side of the **pubic arch.**

Os Pubis.—The body is the wide, flattened, medial part.

Inferior ramus runs downwards and sidewards from it to meet ramus of ischium.

Superior ramus runs upwards and sidewards, expands to join ilium and ischium and to form one-fifth of acetabulum. *Ilio-pubic eminence* marks the junction with ilium ; the junction with ischium, at the medial side of acetabular notch, is not clearly defined.

Body of Pubis.—*Pelvic surface* looks more upwards than backwards, is smooth, and is in relation to retropubic pad of fat and the bladder. *Femoral surface* is rough.

Symphyseal surface is joined to its fellow by the fibrocartilage and ligaments of pubic symphysis.

Lateral border helps to bound obturator foramen.

Pubic crest is the thick *upper border*, raised and bent forwards and downwards ; easily felt at lower limit of abdomen at side of median plane. **Pubic tubercle** is the

ateral end of crest, felt one inch from median plane in men, little farther away in women. When hip-bone is held n the proper position, the pubic tubercle and anterior uperior iliac spine are in the same coronal plane.

Superior ramus is the real pubic bone; it has two ends, hree borders and three surfaces.

Medial end is expanded and is described as the **body.**

The *lateral end* swells to fuse with ilium and ischium nd to form part of acetabulum.

Upper border is a sharp edge called **pectineal line.** It uns from pubic tubercle to ilio-pubic eminence, where is continuous with lower part of medial border of ilium.

Anterior border is a blunt ridge, called **obturator crest,** hat runs from pubic tubercle to acetabular notch.

Inferior border, seen best from pelvic aspect, forms the pper or anterior margin of obturator foramen.

Pectineal surface is the triangular area between pubic rest and ilio-pubic eminence, and gives origin to pec- neus. **Pelvic surface** is smooth and continuous with elvic surface of body. **Obturator surface,** in the upper oundary of obturator foramen, is occupied by an oblique roove—the *obturator groove*—through which the obtur- tor vessels and nerve pass out of pelvis.

Conjoined Rami of Ischium and Pubis.—**Superior border** ompletes obturator foramen. **Inferior border** forms side f pubic arch. **Femoral surface** is rough for muscles. Broad, shallow groove on infero-medial part of **pelvic** urface lodges crus of penis or of clitoris.

Acetabulum.—Looks sidewards, and also downwards nd forwards; articulates with femur. Horseshoe-shaped rea, coated with cartilage, occupies anterior, upper and osterior parts of cup, leaving the rough **acetabular fossa** floor adjoining the **acetabular notch,** *i.e.* the gap in ower part of cup, above obturator foramen. Rim is ompleted and notch converted into foramen by trans- erse lig. Articular branches of obturator and medial rcumflex arteries enter the joint through acetabular otch.

Obturator Foramen.—Below acetabulum. Closed by bturator membrane, which is attached to its margins, xcept at obturator groove, where obturator vessels and erve pass out of pelvis.

Nutrient foramina of hip-bone are scattered.

Ossification.—Primary centre for **ilium** at 9th week, for **ischium** during 4th month, for **pubis** during 5th or 6th month.

Rami of pubis and ischium unite at 10th year.

Cartilage in acetabulum is reduced to triradiate strip at 12th year; centres then appear in it and fuse with adjoining bone before 17; one of them (between ilium and pubis) is called *os acetabuli*.

Five epiphyseal centres appear at puberty and fuse 20-25: (1) Ant. inf. iliac spine; (2) crest and both superior iliac spines; (3) ischial tuberosity; (4) pubic tubercle; (5) medial end of pubic crest.

ATTACHMENTS.—Ilium. Inguinal lig. to **anterior superior spine.** Sartorius from anterior superior spine and part of notch below. Tensor fasciæ latæ from anterior superior spine, part of notch below and anterior inch of outer lip of crest.

Obliquus ext. abdominis to ant. half of **outer lip**; latissimus dorsi from post. third; fascia lata to whole outer lip. Obliquus internus from ant. two-thirds of **intermediate area.** Transversus abdominis from ant. two-thirds of **inner lip.** Ilio-lumbar lig. and quadratus lumborum to inner lip above posterior part of iliac fossa. Fascia transversalis and fascia iliaca are continuous with each other along the inner lip and adhere to it.

Long posterior sacro-iliac lig. to **post. sup. spine.** Sacro-tuberous lg. to **post. sup.** and **post. inf. spines.**

Piriformis from upper margin of **greater sciatic notch.**

Ilio-femoral lig. to lower part of **ant. inf. spine** straight head of rectus femoris from upper part.

Reflected head of rectus from rough strip on **gluteal surface** above acetabulum. Gluteus minimus from area between inf. and middle gluteal lines. Gluteus medius from area bounded by middle and post. gluteal lines and iliac crest. Gluteus maximus from upper, rough part of area behind post. gluteal line.

Iliacus from upper part of the floor of **iliac fossa.** Sacro-spinalis from upper part of **iliac tuberosity**; posterior and interosseous sacro-iliac ligs. to lower part. Anterior sacro-iliac lig. to convex margin of **auricular surface.**

Ischium and Pubis.—Quadratus femoris from lateral margin of **ischial tuberosity**; sacro-tuberous lig. to medial margin and lower medial impression; semimembranosus from upper lateral impression; semitendinosus and long head of biceps from upper medial impression; adductor magnus from lower lateral impression and from margin of conjoined rami. Gemellus superior, levator ani, coccygeus, sacro-spinous lig. from **ischial spine.** Gemellus inferior from lower margin of lesser sciatic notch.

Obturator internus from **pelvic surface** of **ischium** and **ilium** above and behind the obturator foramen, from margins of obturator foramen except at obturator groove, and from **obturator membrane.** Levator ani and pubo-prostatic ligaments from pelvic surface of

dy of pubis : adductor longus from femoral surface, in angle be-
een crest and symphysis. Gracilis from margin of **symphysis** and
f. ramus ; adductor brevis from area lateral to that ; obturator
ternus from area below and in front of obturator foramen and
om medial half of obt. membrane. Fascia lata to crest, margin
symphysis and of conjoined rami, and lower end of ischium,
edial to gracilis and adductor magnus. To margin of pubic arch,
ore medially still, the deep layer of superficial perineal fascia.
Crus penis to groove on pelvic surface of rami. Ischio-cavernosus,
perficial transversus perinei from or near junction of ischial tuber
d ramus, at posterior end of groove for crus. Perineal membrane,
hincter urethræ and deep transversus, falciform process of sacro-
berous lig. and inferior pubic lig. to strip between groove for
is penis and origin of obturator internus.
Fibro-cartilage of symphysis to **symphyseal surface ;** anterior
sterior, superior and inferior pubic ligs. to its circumference.
Aponeurosis of obliquus externus abdominis to **crest** and ant. lig.
symphysis, and by means of inguinal lig. to **pubic tubercle** and
ctineal line. Conjoint tendon and fascia transversalis to crest
d pectineal line ; cremaster to pubic-tubercle. Pyramidalis from
st, rectus abdominis from crest and ant. lig. of symphysis.
ctineus from pectineal surface and line ; its fascia to pectineal
e. Psoas minor to ilio-pubic eminence and pectineal line.
Transverse lig. bridges across **acetabular notch.** Lig. of head of
nur to transverse ligament and margins of notch. Labrum
tabulare to transverse lig. and **bony rim of acetabulum.** Fibrous
psule to labrum below and anteriorly, to bony rim above and
steriorly, and to rough depression above acetabulum. Ilio-
moral lig. to lower part of **ant. inf. iliac spine.** Pubo-femoral lig.
lateral end of **obturator crest.** Ischio-femoral lig. from ischium
low acetabulum.

Attached from before backwards to **pubic crest** are fascia lata,
l. ext. abd., conjoint tendon, pyramidalis, rectus abd., fascia
nsversalis. To **pectineal line :** pectineus, its fascia, pectineal
d reflected parts of inguinal lig., conjoint tendon, fascia trans-
rsalis and psoas minor.

Pelvis.—Hip-bones in front and at the sides, sacrum
d coccyx posteriorly. **False pelvis** is the part above
e arcuate lines and is in relation to abdominal con-
nts. **True pelvis,** below, contains pelvic viscera.

True Pelvis.— **Bounded anteriorly** by symphysis and
the bodies of the pubic bones ; **on each side** by
chium, conjoined rami, superior ramus of pubis, and
wer part of ilium ; **posteriorly** by sacrum and coccyx.
bturator foramen is closed by obt. membrane ; interval

between hip-bone and sacrum is bridged across by sacro-tuberous and sacro-spinous ligs.

Inlet.—Boundary or *brim* is the sacral promontory, the pubic symphysis, and, on each side, the arcuate line. The *arcuate line* comprises (1) anterior margin of ala of sacrum, (2) lower part of medial border of ilium, (3) pectineal line and (4) pubic crest.

Outlet.—Bounded, from before backwards, by inferior pubic lig., side of pubic arch, lower end of ischium, sacro-tuberous lig., and coccyx.

Pubic Arch.—Bounded, on each side, by the conjoined rami of pubis and ischium ; and its apex is rounded off by the inferior pubic lig.

Cavity of Pelvis.—A short, wide, curved canal, one and a half or two inches in length anteriorly, five or six inches posteriorly.

Axis of plane of inlet is a line drawn at right angles to its centre, and, if continued, would pass through umbilicus and tip of coccyx. *Axis of plane of outlet* is drawn at right angles to its centre, and, if produced, would strike promontory of sacrum. **Axis of pelvis** is a line, curved in conformity with sacrum and coccyx, which passes through centres of planes of inlet and outlet and through centres of a series of planes set between these.

Inclination of pelvis is such that, in erect posture, anterior superior iliac spine and pubic tubercle are in same coronal plane, and plane of the inlet forms an angle of 50° to 60° with the horizontal.

PELVIC MEASUREMENTS.—The four **External Diameters** are the most important :—

Intertrochanteric : between greater trochanters.

Intercristal : greatest distance between outer lips of iliac crests.

Interspinous : line between anterior superior iliac spines.

External antero-posterior : distance from tip of 1st sacral spine to anterior surface of symphysis.

Diameters of Inlet.— *Antero-posterior* (*conjugate*) : from middle of sacral promontory to upper margin of symphysis.

Transverse : across inlet where it is widest.

Oblique : from sacro-iliac joint to opposite ilio-pubic eminence.

Diameters of Cavity.— *Antero-posterior* : from centre of 3rd piece of sacrum to middle of pelvic surface of symphysis.

Transverse : across cavity where it is widest, often bisecting antero-posterior diameter.

Oblique: from the posterior end of one sacro-iliac joint to the ntre of opposite obturator membrane.

Diameters of Outlet.—*Antero-posterior*: from tip of coccyx to ver margin of symphysis (varies owing to mobility of coccyx).

Transverse: across the widest part of outlet; it is on a lower ne than the antero-posterior diameter.

Oblique: from intersection of sacro-tuberous and sacro-spinous aments to junction of rami of ischium and pubis of opposite side.

Sexual Differences.—**In female,** as compared with male, nes are lighter, more slender, and muscular mark-gs less pronounced. Ilium is less everted, iliac fossa allower; anterior superior spines closer together.

Inlet, reniform rather than heart-shaped, and obliquity its plane greater; sacral promontory projects less; bic tubercles wider apart. **All diameters are longer.**

Cavity is roomier, less funnel-shaped, shorter.

Sacrum is shorter and wider, and its curve may be s uniform, being flatter above and more sharply bent wards below.

Outlet: All diameters longer. *Pubic arch wider and*

Approximate measurements in inches.	Female.	Male.
Intertrochanteric	12	12½
Intercristal	11	11¼
Interspinous	10	10¼
External antero-posterior	7½	7¾

True Pelvis.	Inlet.	Cavity.	*Outlet.*	Inlet.	Cavity.	*Outlet.*
Antero-posterior	4	4½	5	4	4¼	3¼
Oblique	4½	4½	4½	4¾	4½	4
Transverse	5	4½	4	5	4¾	3½

more rounded. Ischial spine less inturned; interval between side of sacrum and hip-bone wider and shallower; coccyx more movable and less curved forwards.

Obturator foramen smaller; may be triangular rather than oval.

Acetabula are farther apart and *relatively smaller.*

Femur.—Distal end is larger than proximal, and is close to its fellow. Proximal ends are separated by the width of the pelvis. Shaft is thinnest in the middle and enlarges towards the ends, especially at the distal end.

Proximal end comprises *head, neck, greater* and *lesser trochanters, trochanteric fossa, trochanteric line, trochanteric crest,* and *quadrate tubercle.*

Head, spherical, looks medially, upwards and forwards; articulates with acetabulum; articular margin is wavy, and is sharper behind than in front. **Pit for lig. of head of femur** is on postero-inferior quadrant.

Neck, a thick, oblique bar, about an inch and a half long, unites head to shaft and trochanters; thickens towards each end, especially towards shaft, which it joins at angle of 125° in adult, but more obtuse in child.

Upper border is short and joins trochanter major, which overhangs it. *Lower border,* long, more sloping, joins shaft at trochanter minor. *Posterior surface,* convex from above downwards, is crossed by a very shallow, horizontal groove (for obturator externus tendon) which leads laterally into a rough pit, called **trochanteric fossa** situated between trochanter major and upper part of back of neck. *Anterior surface* is nearly flat and nearly flush with head and shaft; bears smooth patch near head produced by pressure of ilio-femoral lig. in erect posture.

Trochanteric line is the low, rough, oblique ridge at junction of front of neck and shaft. Its upper end is at the front of greater trochanter, and is often marked by a small tubercle. Its lower end is continuous with a faint ridge, called *spiral line,* that winds round below lesser trochanter to the back of the shaft.

Lesser trochanter is the blunt, conical eminence situated at junction of lower border of neck with medial part of back of shaft; it points medially and backwards.

Greater trochanter, a large, quadrilateral prominence united to lateral part of neck and proximal end of shaft

t subcutaneously at side of hip ; tip is opposite the ntre of the hip-joint and the upper margin of pubic mphysis. Has anterior, posterior, lateral and medial rfaces and upper border.

Upper border is marked by insertion of piriformis, and ds posteriorly in prominent *postero-superior angle*, ich is the tip or highest point of trochanter. *Lateral rface* is bounded, at root of trochanter, by a horizontal lge that separates it from lateral surface of shaft ; and is crossed, from postero-superior angle to antero-erior, by oblique ridge for insertion of gluteus medius. *nterior surface*, fairly flat, is rough for insertion of nteus minimus. *Medial surface*, small and rough, over-ngs upper border and back of neck ; its lower part is llowed out by trochanteric fossa. *Posterior surface* is nded ; inferiorly it is continuous with a strong ridge, led **trochanteric crest**, which overhangs back of neck d ends at lesser trochanter. **Quadrate** tubercle is an defined swelling at the upper end of the crest.

Distal End.—Comprises *lateral* and *medial condyles* and *condyles*, *patellar surface*, *intercondylar notch* and *line*, *ductor tubercle*, *pit* and *groove for popliteus*.

The condyles make up nearly the whole distal end. nteriorly they are nearly flush with the shaft, and are ited by the large, articular, patellar surface. Posteri-y, they bulge considerably beyond the plane of the aft, and are separated by the deep, wide intercondylar tch. The top of the tibia and the semilunar cartilages knee-joint articulate with the posterior surfaces of the noral condyles when the knee is bent, and with their erior surfaces when knee is straight ; the inferior faces are therefore in one horizontal plane when the ole femur is in its natural, oblique position.

The **intercondylar notch** is bounded by the central faces of the condyles, which are rough for attachment cruciate ligs. Its anterior margin is opposite the centre lateral condyle ; its floor slopes upwards and back-rds to the horizontal ridge, called **intercondylar line**, ich separates it from popliteal surface of shaft.

Patellar surface, pulley-shaped, marked off from tibial faces of condyles by grooves produced by the nilunar cartilages. Patella articulates with it when ee is straight, but is drawn off it when knee is bent ;

and, in that position, its margins can be felt through tendon of quadriceps. Lateral part of pulley is more prominent than the medial, and extends farther up.

Lateral condyle is broader than medial, and shorter antero-posteriorly; long axis is less oblique, and distal surface less convex. *Lateral epicondyle* is the eminence on posterior part of lateral surface of condyle. A pit or impression for origin of lateral head of gastrocnemius is above epicondyle. *Pit for origin of popliteus* is below the epicondyle. *Groove for tendon of popliteus* runs upwards and backwards from the pit, close to articular margin; tendon lies in groove during full flexion of knee, but crosses its distal lip during extension. When knee is extended, the lateral popliteal nerve, though separated from the back of the lateral condyle by the capsule and the lateral head of gastrocnemius, can be felt and rolled against it by the finger.

Medial condyle stands farther away from side of shaft than the lateral does; is narrower and more curved; its central side is more hollowed out; it reaches a lower level when femur is vertical; and, where it bounds anterior part of intercondylar notch, it has a small semilunar facet for patella in extreme flexion of knee. *Medial epicondyle* is the most prominent point on its medial surface. **Adductor tubercle** is the small, pointed eminence, above the epicondyle, at uppermost part of medial surface.

Sides of condyles and adductor tubercle are easily felt in the living person.

Shaft of Femur.—Curved and slightly twisted. More or less cylindrical. Expands at both ends, especially distally. In erect posture it is oblique, because distal ends of femora are in contact, while proximal ends of shafts are separated by pelvis and by the necks of the femora.

Surfaces: In the middle third, there are *anterior, medial* and *lateral surfaces*, separated by ill-defined *lateral* and *medial borders* and a pronounced *posterior border* called *linea aspera*. But the upper and lower ends of linea aspera divide to become continuous with diverging ridges that mark out an additional surface (*posterior*) in both the proximal third and the distal third. The posterior surface of distal third and the whole medial surface are bare; the other surfaces give attachment to muscles.

Linea aspera is the rough, vertical ridge on the back o

iddle third of shaft; its *lateral lip* is thin and sharp, *edial lip* is broader and interrupted. Lips diverge from ch other both above and below.

Proximally, the lateral lip is continuous with a wide, ugh ridge, called **gluteal tuberosity,** that extends to e back of the greater trochanter, and gives insertion to rt of gluteus maximus; medial lip is continuous with **ral line,** which winds round to the trochanteric line.

Distally, the lips are continuous with the **lateral** and **dial supracondylar lines,** which run down to the con- les. Lateral supracondylar line is more prominent an the medial, for the medial line is worn away, in part, the passage of the femoral vessels into popliteal fossa.

Popliteal surface, between supracondylar lines, is the sterior surface of distal third. It forms the upper rt of floor of popliteal fossa. On it, just above medial ndyle, there is a low, rough elevation, nearly an inch de, for origin of medial head of gastrocnemius.

Nutrient Foramina.—One or two near linea aspera, rected upwards.

Ossification.—Primary centre for shaft and neck at 7th week; ification does not extend into neck till after birth.

Epiphyseal centres: for **distal end,** shortly before birth; **head,** yr.; **greater trochanter,** 4-5 yr.; **lesser,** 9-11 yr.

Fusion takes place in order conforming to size of epiphysis—be- ning with the smallest, *i.e.* lesser trochanter—during 16 and 17 girls, and 18 in boys.

Epiphyseal line: Head is intracapsular; greater trochanter, extra- sular, except superiorly; lesser trochanter, extracapsular. stal end is extracapsular; line passes through adductor tubercle, l just above patellar surface and intercondylar line.

ATTACHMENTS.—Lig. of head to pit on **head.** Capsule of hip- nt to post. surface of **neck** half an inch from trochanteric crest, pper and lower borders near trochanters, and to **trochanteric line.** o-femoral lig. and vastus lateralis and medialis also to **trochanteric** e. Obturator externus to the floor of **trochanteric fossa.**

Obturator internus and gemelli to *medial surface* of **greater** ochanter above neck; piriformis to *upper border*; gluteus minimus *anterior surface*; gluteus medius to oblique ridge on *lateral face*; quadratus femoris to intertrochanteric crest and to **quadrate ercle,** and to a line running down from the tubercle; vastus teralis from the front and lateral side at the *root* of trochanter.

Ilio-psoas to **lesser trochanter** and to shaft immediately below it. Gluteus maximus to **gluteal tuberosity;** vastus lateralis from its

lateral edge. V. medialis from **spiral line.** *On surface between tuberosity and line* (from lateral to medial side): upper part of adductor magnus; adductor brevis to distal two-thirds of strip leading from back of lesser trochanter to linea aspera (and to proximal part of aspera); pectineus to proximal half of same strip; iliacus for an inch below and in front of lesser trochanter.

To **linea aspera,** from lateral to medial side: *Lateral lip*—vastus lateralis and intermedius from upper and lower parts respectively; lateral intermuscular septum; short head of biceps. *Medial lip*—adductor magnus; brevis (only to upper part); longus (to lower two-thirds); medial intermuscular septum; vastus medialis (origin).

Lateral supracondylar line: Vastus intermedius; lateral septum; short head of biceps from upper two-thirds. Plantaris and lateral head of gastrocnemius from lower part; plantaris also from popliteal surface just above condyle, and gastrocnemius also from adjoining impression on lateral surface of lateral condyle.

Adductor magnus and medial septum to **medial supracondylar line.** Vastus medialis from its upper two-thirds.

Medial head of gastrocnemius from the mark on popliteal surface above medial condyle. Vastus intermedius from upper three-fourths of *anterior* and *lateral surfaces* of **shaft.** Articularis genu from lower part of ant. surface.

Anterior cruciate lig. of knee to post. part of medial surface of **lateral condyle;** popliteus from *pit* below epicondyle; lateral lig. of knee to *epicondyle*; lateral head of gastrocnemius from impression behind and above epicondyle.

Post. cruciate lig. to ant. part of lateral surface of **medial condyle;** adductor magnus to *adductor tubercle*; medial lig. of knee to *medial epicondyle.*

Fascia lata to both condyles. Capsule of knee to intercondylar line, to bone immediately above posterior parts of condyles, to lateral epicondyle above popliteal groove, and to medial condyle immediately below epicondyle; no definite fibrous stratum anteriorly, but line of reflexion of synovial membrane is half an inch above the margin of the articular surface. Infrapatellar synovial fold to anterior margin of intercondylar notch.

Muscles with Extensive Attachments: **Vastus lateralis** from upper part of trochanteric line, anterior and lateral aspects of root of trochanter major, lateral edge of gluteal tuberosity, upper part of lateral lip of linea aspera.

Vastus medialis from lower part of trochanteric line, spiral line, medial lip of linea aspera, upper two-thirds of medial supracondylar line.

Vastus intermedius from upper three-fourths of ant. and lateral surfaces of shaft, and adjoining parts of lateral lip of l. aspera and supracondylar line.

Adductor magnus to posterior surface of shaft medial to gluteal

erosity, medial lip of linea aspera, medial supracondylar line, ductor tubercle.

Short head of biceps from lateral lip of linea aspera and upper o-thirds of lateral supracondylar line.

Patella.—Sesamoid bone, developed in tendon of adriceps. Situated in front of distal end of femur. s lower end is immediately above the level of the line knee-joint.

Vasti and rectus femoris are attached to **base** (upper border). stus lateralis and medialis to **lateral** and **medial borders.** ig. patellæ to **apex** and rough, lower part of **posterior surface.** **Anterior surface** is separated from skin by bursæ.

Articular surface, divided by vertical ridge into unequal areas for lateral and medial parts of patellar surface of femur—the lateral ig the larger. Vertical strip marked off along medial side articu- s with condyle at medial side of intercondylar notch during full ion ; remainder is divided by the vertical ridge and two trans- se lines into three pairs of facets.

Ossification begins at 5th year and is completed at puberty.

Tibia.—Medial and larger bone of leg.

Proximal End.—Larger than distal end ; transverse meter is the wider ; bent slightly backwards.

Comprises *tubercle, lateral* and *medial condyles, inter- dylar area* and *eminence, fibular facet,* and *groove for nimembranosus.*

The **tubercle** is the prominence on the front, nearly an h from the top. Easily felt. Its upper part is smooth l gives insertion to lig. patellæ. The lower part is gh but subcutaneous.

In *kneeling posture,* the body rests on lower part of ercle, the fronts of condyles, the lig. patellæ and er part of patella.

The two **condyles** make up nearly the whole proximal end. adily felt *at the sides. Posteriorly,* they are separated the wide, shallow notch. *Anteriorly* they are united, ve the tubercle, by a fairly flat surface which is ered with fat, a bursa and lig. patellæ. *Superiorly,* h is coated with cartilage, and articulates centrally h a condyle of femur, peripherally with a semilunar tilage. Between these articular surfaces, there is a ie, rough strip — the **intercondylar area** — which rises the middle to form the **intercondylar eminence.** The

eminence is bounded by the *lateral* and *medial intercondylar tubercles*, which rise from the articular surfaces.

Medial condyle is larger than the lateral, and articular surface is more oval and more concave. On the posteromedial aspect of the condyle there is a horizontal *groove for insertion of semimembranosus*.

Lateral condyle stands more abruptly away from shaft. Has therefore a small inferior surface separated from the lateral surface by a curved ridge that gives attachment to the deep fascia of the leg. Note: (1) **Facet for head of fibula,** flat and nearly circular, on the posterior part of this inferior surface. (2) On the back, above and medial to the facet, a smooth, wide, shallow groove for passage of popliteus tendon. (3) On the front of the condyle, a raised impression that gives attachment to the thick, posterior part of ilio-tibial tract.

Distal End.—Has five *surfaces*, a *malleolus* and a *fibular notch*.

Medial surface is subcutaneous. *Anterior surface*, rounded; covered with extensor tendons.

Posterior surface, also rounded; groove on malleolus for tibialis posterior encroaches on it; more laterally, a faint groove lodges the flexor hallucis longus tendon.

Tarsal surface, quadrilateral, wider in front than behind; slightly concave from behind forwards, slightly convex from side to side. Articulates with the upper surface of talus.

Medial malleolus, short and thick, juts down from the medial side, and forms the subcutaneous prominence of the medial side of ankle. Its lateral surface articulates with talus. Lower border is pointed anteriorly and notched posteriorly and gives attachment to deltoid lig. Its posterior surface is grooved by tibialis posterior tendon.

Fibular notch is the triangular depression that occupies *lateral surface*. At its base or lower border it articulates with fibula, but the rest of its floor is rough for the interosseous tibio-fibular lig.

Shaft of Tibia.—Diminishes in thickness to distal third and slightly enlarges again. Has anterior, lateral and medial borders; posterior, medial and lateral surfaces.

Anterior border, subcutaneous, is the shin; extends sinuously from tubercle to anterior margin of malleolus.

Lateral border is a low, narrow ridge that begins at the ıteral condyle a little in front of the fibular facet, and ıns to the fibular notch. It is called the **interosseous ɔrder** because the interosseous membrane is attached ɔ it.

Medial border is the blunt margin that extends from ıedial condyle to posterior border of malleolus.

Medial surface, between anterior and medial borders, is ıbcutaneous, except near the upper end where tendons re inserted.

Lateral surface, between ant. and interosseous borders, continuous with anterior surface of distal end.

Posterior surface, between medial and interosseous ɔrders, encroaches on lateral aspect near upper end.

Soleal line is a rough ridge that crosses it obliquely ɔm fibular facet to medial margin.

Vertical line is a faint ridge that runs down for a ıriable distance from soleal line, dividing the surface elow soleal line into unequal lateral and medial areas.

Nutrient foramen, near soleal line, directed downwards.

Ossification.—Primary centre at 7th week. Epiphyseal centre r **proximal end,** including proximal part of tubercle, immediately tore or after birth; for **distal end** in 1st year. Fusion, first in stal end, during 16 in girls and 18 in boys. Epiphyseal lines are tracapsular.

ATTACHMENTS.—Anterior horn of medial semilunar cartilage d ant. cruciate lig. to anterior part of **intercondylar area**; ant. rn of lateral semilunar cartilage to the front of **intercondylar inence,** post. horn to the back; post. horn of medial cartilage posterior part of **intercondylar area**; post. cruciate lig. to same rt and to the notch between the condyles: all in that order from fore backwards.

Capsule of knee, fascia lata and fascia of leg to **both condyles.**

Capsule of superior tibio-fibular joint around facet on **lateral ndyle**; biceps, peroneus longus, ext. dig. longus, tibialis ant., in ıt order from behind forwards, in front of facet; ilio-tibial tract the raised impression on the front.

Semimembranosus to anterior part of horizontal groove on **medial ndyle** and to rough patch below that groove.

Lig. patellæ to smooth, upper part of **tubercle of tibia.**

Tibialis anterior from lateral condyle and upper two-thirds of *eral surface* of **shaft.**

Sartorius, gracilis, semitendinosus, medial lig. of knee to upper rt of *medial surface*, in that order from before backwards, the

ligament being attached to an elongated, rough patch near medial border.

Popliteus to **soleal line** and area above the line. Soleus from soleal line and middle third of medial border. Tibialis posterior from upper two-thirds of lateral area of *posterior surface* ; fascia of tibialis posterior to **vertical line** ; flexor dig. longus from upper two-thirds of the area medial to vertical line.

Fascia of leg to **anterior** and **medial borders** : superior extensor retinaculum to lower part of anterior border. Interosseous membrane to **interosseous border.**

Interosseous tibio-fibular lig. to floor of **fibular notch** ; inferior tibio-fibular ligs. to the lower parts of its anterior and posterior margins. Ant. lig. of ankle to ant. border of *tarsal surface of tibia* ; post. lig. of ankle and transverse tibio-fibular lig. to post. border.

Deltoid lig. to distal border of **medial malleolus** ; flexor retinaculum to its posterior border ; inferior extensor retinaculum to its anterior border.

Fibula.—Lateral and smaller bone of leg. Proximal end cuboidal ; distal end slightly compressed from side to side.

Proximal End.—Comprises *head*, *neck* and *styloid process*.

Head, felt on postero-lateral aspect of leg, at the level of tubercle of tibia ; lateral popliteal nerve can be felt and rolled by finger on back of head, though separated from head by uppermost part of soleus.

Articular surface, directed upwards, forwards and medially, articulates with the lateral condyle of tibia.

Anterior, *posterior*, *lateral* and *medial surfaces* (difficult to recognise till shaft has been examined) give origin to various muscles that arise from the shaft.

Styloid process, stunted, conical and blunt juts upwards from postero-lateral aspect of head.

Neck is the constricted portion just below the head ; lateral popliteal nerve divides on its lateral side.

Distal End = Lateral Malleolus. — Distinguished from proximal end by being compressed from side to side, and possessing a pit postero-medially. It is the large prominence on lateral side of ankle ; and has lateral, medial and posterior surfaces and an anterior border.

Lateral surface is subcutaneous, and is continuous, superiorly, with the *triangular subcutaneous surface* on the lateral side of distal part of shaft.

Medial surface presents a large articular area for talus.

Above that (chiefly on shaft) there is a rough triangle for interosseous lig.; distal edge of triangle is sometimes smooth for direct articulation with tibia. Behind and below the large articular area there is a pit, called **malleolar fossa,** whose floor gives attachment to ligaments.

Posterior surface is occupied by a shallow, longitudinal groove for the passage of the tendons of peroneus longus and brevis—brevis on the bone.

Anterior border, thick and convex, is rough for ligaments.

Shaft of Fibula.—Slender, twisted. **Anterior border,** thin, sharp; recognised by its continuity with apex of triangular subcutaneous surface; extends up to neck. **Interosseous border,** often ill-defined, on medial side of anterior border, may be very near it at upper end; extends from neck to apex of rough triangle on medial side of distal end; gives attachment to interosseous membrane. **Anterior surface** is the strip between anterior and interosseous borders; very narrow proximally, but wider distally.

Posterior border, blunt but well-defined, extends from the neck to the medial margin of the back of lateral malleolus; it is separated from the anterior border by the lateral surface. **Lateral surface** is fairly wide, is often grooved longitudinally, and, owing to the twist of the shaft, it is continuous with the back of the malleolus.

Posterior surface is the area between the posterior and interosseous borders, and is continuous inferiorly with the medial surface of the malleolus. The **medial crest** is often the most outstanding *ridge* on the bone. It begins at the neck and ends inferiorly by running into the interosseous border a few inches above the distal end. It divides the posterior surface into two parts.

Nutrient Foramen.—On posterior surface, near middle, directed downwards. May be elsewhere and directed upwards.

Ossification.—Primary centre at 7th week. Epiphyseal centre for **distal end** in 1st year; for **proximal end,** 3rd year. Fusion during 16 in girls and 18 in boys—first at distal end. Epiphyseal lines are extracapsular, but may be inside medially at distal end.

ATTACHMENTS.—Capsule of superior tibio-fibular joint around articular surface of **head.** Arcuate lig. of knee to tip of *styloid*

process. Lateral lig. of knee and biceps are attached in front of that process. Muscles (and their fascia) that arise from upper part of shaft arise also from adjoining surfaces of head. Fascia lata to lateral side of head.

From *anterior surface* of **shaft**: ext. dig. longus from upper two-thirds, peroneus tertius from lower third; ext. hall. longus, posteromedial to these, from middle three-fifths. Tibialis posterior from *posterior surface* in front of medial crest; soleus from upper third of remainder; and flexor hallucis longus from lower two-thirds. Peroneus longus from upper two-thirds of *lateral surface*, brevis from lower two-thirds; they overlap in middle third, brevis being in front. Anterior intermuscular septum to *anterior border*, and superior extensor retinaculum to anterior border near the distal end. Interosseous membrane to *interosseous border*. Posterior intermuscular septum to *posterior border*.

Ant. inf. tibio-fibular lig. and ant. talo-fibular lig. to ant. border of **lateral malleolus.** Calcaneo-fibular lig. to tip. Post. inf. tibio-fibular lig. to medial edge of posterior surface; superior peroneal retinaculum to medial and lateral edges of posterior surface. Post. talo-fibular lig. and transverse tibio-fibular lig. to *malleolar fossa*: interosseous lig. to rough triangle above articular surface.

Tarsus.—Seven bones. **Posterior row:** talus, calcaneum. **Middle bone:** navicular.

Anterior row: three cuneiforms and the cuboid.

Talus.—Lies below tibia, on the upper surface of calcaneum, and is gripped by the malleoli. Divided into *head, neck* and *body*, head being in front.

Head.—Convex, felt as a prominence one inch or more in front of the ankle-joint when the foot is inverted. Articulates *anteriorly* with navicular; *inferiorly* with anterior part of upper surface of calcaneum, and, medial to that, with plantar calcaneo-navicular ligament or spring lig.

Neck.—Rough for ligaments; slightly constricted.

Body.—*Superior surface*, concavo-convex, wider in front than behind; all articular for tarsal surface of tibia.

Lateral surface stands away from neck and head, is covered with articular facet for lateral malleolus; everted part below is called *lateral tubercle*. Posterior part is separated from upper surface by ill-defined, narrow triangle that articulates with transverse tibio-fibular lig.

Medial surface, flush with head and neck; has a comma-shaped facet above for medial malleolus: is rough below for deltoid ligament.

Posterior surface, very small, has oblique groove for odgment of tendon of flexor hall. longus. The groove s bounded by *medial* and *posterior tubercles* ; posterior ubercle is occasionally separate and called *os trigonum*.

Inferior surface has large, oblique, oval, concave facet posteriorly, for calcaneum ; a deep groove, in front of hat, for interosseous lig. ; and, in front of that, a lesser facet which encroaches on neck and articulates with sustentaculum tali.

ATTACHMENTS.—No muscles or tendons. Ant. lig. of ankle nd dorsal talo-navicular lig. to upper surface of **neck** ; ant. talo-ibular lig. to lateral side ; deltoid lig. to medial side.

Deltoid lig. also to medial side of **body.** Articular capsule of talo-alcanean joint around large facet on lower surface ; interosseous alo-calcanean lig., to the floor of the groove in front of that ; osterior margin of lesser facet gives attachment to the membrane hat closes talo-calcaneo-navicular joint posteriorly. Post. lig. of nkle to upper part of posterior surface. Post. talo-fibular lig. to **osterior tubercle.**

Calcaneum.—Lies below talus ; forms prominence of eel. Has six surfaces, of which the anterior and pos-erior surfaces are the ends of the bone.

Anterior surface is covered with concavo-convex, slop-ng facet for articulation with cuboid.

Posterior surface is smooth superiorly for a bursa ; roughened in the middle by the insertion of tendo alcaneus ; lower area is covered by the pad of the heel, nd divides below into *medial* and *lateral tubercles*, of vhich the medial is the larger. In standing, the lower rea of posterior surface rests on the ground, and the nterior end of the bone is raised well above the ground.

Plantar surface: Rough. Presents *anterior tubercle* near nterior end, and the *medial* and *lateral tubercles* (al-eady seen) at posterior end.

Superior surface: Saddle-shaped area posteriorly sup-orts fat and areolar tissue in front of tendo calcaneus ; val, oblique, convex facet articulates with talus ; groove n front of that is for interosseous lig., and tunnel formed y that groove and the groove on talus is called *sinus arsi* ; rough surface anteriorly usually has facet for head f talus on its medial part.

Sustentaculum tali is the horizontal shelf on the medial ide. Its medial edge may be felt one inch below medial

malleolus. Its upper surface articulates with lesser facet on body of talus; its lower surface is grooved by the tendon of flexor hallucis longus; tendon of flexor digitorum longus is superficial to its edge; medial plantar vessels and nerve are in relation to it between these two tendons; tendon of tibialis posterior is higher up—on deltoid lig.

Medial surface of calcaneum is concave, and its anterior part is overhung by sustentaculum tali.

Lateral surface: Rough; flat or slightly convex. Tendons of peroneus longus and brevis pass obliquely downwards and forwards over its anterior part, and they may produce grooves which are separated by a tubercle called the *peroneal tubercle*.

ATTACHMENTS.—Superior surface: Capsule of talo-calcanean joint around oval facet; interosseous talo-calcanean lig. to floor of groove; rough area anteriorly gives attachment to ext. dig. brevis, stem of inf. extensor retinaculum and stem of bifurcated lig.

Deltoid lig., plantar calcaneo-navicular lig. (spring) and slip from tibialis posterior to edge of **sustentaculum tali**; its upper surface, behind its facet, gives attachment to the ligament that completes talo-calcaneo-navicular joint.

Plantar surface: Flexor retinaculum and plantar aponeurosis to *medial tubercle*, and abductor hallucis and flexor digitorum brevis from it; abductor digiti minimi from medial and *lateral tubercles*. Short plantar lig. (plantar calcaneo-cuboid) to *anterior tubercle*; long plantar lig. to the wide, rough area behind that; lateral head of flexor accessorius from lateral edge of that area, and medial head from **medial surface.**

Dorsal calcaneo-cuboid lig. to lateral and upper edges of facet on **anterior surface.** Tendo calcaneus to middle of **posterior surface.**

Calcaneo-fibular lig. to middle of **lateral surface**; inf. peroneal retinaculum to margins of grooves and to peroneal tubercle.

Navicular Bone.—On medial side of foot, in front of talus.

Surfaces: *Posterior*, concave for head of talus. *Anterior* has three facets for cuneiform bones. *Dorsal*, flat and rough for dorsal ligaments. *Plantar*, rough and irregular for plantar ligaments, especially plantar calcaneo-navicular; and it has a shallow groove for the passage forwards of part of tibialis posterior tendon. *Lateral*, small; rough for ligaments, but may have facet for cuboid.

Medial surface is the **tuberosity**, a landmark felt one inch below and in front of medial malleolus, and it is the chief point of insertion of tibialis posterior.

Cuneiform Bones.—Three in number and each is wedge-shaped. Placed side by side, and named **medial, intermediate** and **lateral.** They articulate with navicular posteriorly, with first three metatarsals anteriorly. By their sides, they articulate (*a*) with one another, (*b*) the lateral one with cuboid and fourth metatarsal, and (*c*) the lateral and the medial grip base of second metatarsal between them.

Dorsal, plantar and interosseous tarsal and tarso-metatarsal ligaments are attached to them ; and tibialis posterior is inserted into their plantar surfaces.

Medial Cuneiform.—The largest. Edge of wedge upwards. **Surfaces :** *Posterior*, small, piriform, articulates with navicular. *Anterior*, kidney-shaped, articulates with first metatarsal. *Medial*, subcutaneous, convex ; impression below and in front for insertion of tibialis anterior. *Lateral :* inverted L-shaped facet along upper and posterior borders for intermediate cuneiform and side of second metatarsal base ; impression below and in front for insertion of peroneus longus. Base of wedge is *plantar surface.*

Intermediate Cuneiform.—Smallest. **Surfaces :** *Anterior*, triangular, articulates with second metatarsal. *Posterior*, triangular, articulates with navicular. *Medial :* inverted L-shaped facet along upper and posterior borders for medial cuneiform. *Lateral :* B-shaped facet along posterior border for lateral cuneiform. Edge of wedge is *plantar surface*, and base is *dorsal surface.*

Lateral Cuneiform.—Distinguished by lateral border of dorsal surface or base being angled, and by large triangular facet for cuboid on postero-superior part of *lateral surface. Anterior and posterior surfaces*, triangular, and articulate with third metatarsal and navicular, respectively. B-shaped facet for intermediate cuneiform along posterior border of *medial surface.* Small facets at anterior parts of medial and lateral surfaces for second and fourth metatarsal bases. Edge of wedge is *plantar surface*, and base is *dorsal surface.*

Cuboid Bone.—On lateral side of foot between calcaneum and metatarsals ; slopes markedly. Dorsal, plantar and interosseous tarsal and tarso-metatarsal ligs. attached to rough areas.

Surfaces.—**Dorsal :** flat, rough, in line with lateral surface of calcaneum. **Posterior :** concavo-convex, sloping, articulates with calcaneum. **Anterior :** Two facets for 4th and 5th metatarsals. **Medial :** large facet and sometimes a small one for lateral cuneiform ; occasional facet posteriorly for navicular.

Lateral: smallest; looks downwards rather than sidewards; shows beginning of groove on plantar surface. **Plantar:** irregular. Groove for passage of peroneus longus near anterior border; long plantar lig. is attached to its lips. Behind the groove there is a prominent, blunt ridge, lateral end of which is called the *tuberosity*, and is faceted by sesamoid bone in peroneus longus tendon. Short plantar lig. and flexor hallucis brevis are attached to the area behind the ridge; and the slip from tibialis posterior to the medial part of the floor of the groove.

Metatarsus.—Five bones, numbered 1 to 5 from tibial to fibular side. Each has proximal end or base, a shaft, a distal end or head.

Bases articulate with tarsus and with one another, and are connected by dorsal, plantar and interosseous tarso-metatarsal and intermetatarsal ligaments.

Head of each articulates with proximal phalanx and with plantar lig. The plantar lig. is attached to the shaft immediately behind the head, and the collateral ligs. are attached to the sides of the head.

First Metatarsal.—Shortest and stoutest. **Base:** kidney-shaped facet for medial cuneiform, concave margin of which looks laterally; occasional facet for second metatarsal; impression on lateral surface, near sole, for insertion of peroneus longus; tibialis anterior is inserted into the medial side near the sole.

Shaft: three-sided. *Dorsal surface*, subcutaneous; flexor hallucis brevis lies on *plantar*, 1st dorsal interosseous attached to *lateral*.

Head: plantar surface is smooth and is grooved by the two sesamoid bones in flexor hallucis brevis; distal surface is smooth and convex.

Second, Third, Fourth Metatarsals.—Compressed from side to side; plantar surface concave. Sides of shaft give origin to dorsal interossei; plantar surface of 3rd and 4th to first and second plantar interossei. Tibialis posterior, long plantar lig. and the oblique part of adductor hallucis are attached to the plantar surface of their bases.

Tarsal surface of base slopes laterally and backwards, so that lateral surface of bone, as a whole, is longer than medial, and bone can be more easily referred to its side than identified.

Second Metatarsal. Base: nearly triangular on section; *tarsal surface* articulates with intermediate cuneiform; *medial surface* with medial cuneiform and sometimes with first metatarsal; *lateral surface* with third metatarsal and lateral cuneiform by two double facets, separated by horizontal groove.

Third Metatarsal.—Base: nearly triangular on section; *tarsal surface* articulates with lateral cuneiform; *medial surface* with

second metatarsal by **two small** facets ; *lateral surface* with fourth metatarsal by large facet which occupies upper and posterior angle, and is limited by oblique groove.

Fourth Metatarsal.—Base : cuboidal ; *tarsal surface* articulates with cuboid ; *medial surface*, with third metatarsal and lateral cuneiform by *large* facet ; *lateral surface*, with fifth metatarsal by large facet like that on lateral surface of third.

Fifth Metatarsal.—Compressed from above downwards.

Fourth dorsal interosseous arises from medial surface of **shaft** ; and third plantar from plantar surface, which is slightly concave.

Base is expanded ; peroneus tertius is inserted into *dorsal surface* ; flexor digiti minimi arises from *plantar surface* ; *tarsal surface* articulates with cuboid ; *medial*, with fourth metatarsal.

Lateral surface presents **tuberosity,** a landmark on lateral side of foot, into which peroneus brevis is inserted ; it is midway between the little toe and the point of the heel.

PHALANGES.—Big toe has two—the thickest in foot or hand.

Other toes have three each, smaller than those of fingers, middle and distal being often mere nodules. *Shaft* of **proximal,** compressed sideways ; *base*, relatively large, concave ; *head*, pulley-shaped. *Base* of **middle** has a vertical ridge for groove of pulley of the proximal ; *head*, pulley-shaped. *Base* of **distal** is like second but more expanded ; *head*, expanded, rough on plantar surface.

ATTACHMENTS.—Ligaments : plantar ligs. of metatarso-phalangeal and interphalangeal joints to *plantar surfaces* of **bases** and **heads,** and collateral ligaments to their *sides* ; and fibrous flexor sheaths to *sides* of **shaft** of proximal of big toe, proximal and middle of other toes and to bases of distal phalanges.

Tendons.—Proximal Phalanx of Big Toe : flexor hallucis brevis to both sides of *base* ; abductor to medial side ; adductor to lateral side ; first tendon of ext. digitorum brevis to dorsum.

Proximal of Little Toe : abductor and flex. brevis to lateral side of *base* ; 4th lumbrical and 3rd plantar interosseous to medial side.

Proximal of Other Toes : plantar and dorsal interossei and lumbricals to sides of *base*.

Distal of Big Toe : flexor hallucis longus to plantar surface of *base* ; extensor hallucis longus to dorsum.

Middle of Other Toes : flexor digitorum brevis to sides of *shaft* middle slip of extensor expansion into dorsum of *base*.

Distal of Other Toes : flexor digitorum longus into plantar surface of *base* ; collateral slips of extensor expansion into dorsum.

Ossification of Bones of Foot.—**Tarsus** :—
Centre for **calcaneum,** 6th month.
Talus, 8th month.
Cuboid, at birth.
Lateral cuneiform, 1st year.
Intermediate and **medial cuneiforms,** 3rd or 4th year.
Navicular, 3rd or 4th year.
Ossification completed shortly after puberty.

Epiphyseal centre for *tubercles of calcaneum*, at 8 in girls and 10 in boys, and fuses at 15 and 18 respectively. *Posterior tubercle of talus* may have separate centre, and may remain separate as **os trigonum.**

Metatarsus.—Primary centre appears early in 3rd intra-uterine month :—

For *shaft and head* of **first.**

For *shaft and base* of **second, third, fourth** and **fifth.**

Epiphyseal centre for *base of* **first** and *head* of **others** :—

At 2 in girls and 3 in boys, and the epiphyses fuse at 15 and 18 respectively.

Epiphyseal lines are extracapsular.

Phalanges.—Centre for *shaft and head* :—

Of **distal phalanx** at the end of 3rd month.

Of **proximal phalanx** at the end of 4th month.

Of **middle phalanx** of 2nd and 3rd toes during 6th month, of 4th toe at birth, 5th toe after birth.

Epiphyseal centre for *bases* at 2 in girls and 3 in boys. Epiphyses fuse during 15 and 18 respectively, beginning with promixal phalanges.

Epiphyseal lines are extracapsular.

Sesamoid Bones.—Patella is by far the largest.

Two small bones in the tendon of flexor hallucis brevis articulate with the head of the first metatarsal.

Occasionally there are nodules in the other joints of the toes.

One in peroneus longus articulates with the cuboid.

Occasional sesamoid bones are found in gluteus maximus, psoas major, lateral head of gastrocnemius, tibialis anterior and tibialis posterior.

ARTHROLOGY

CLASSIFICATION

A JOINT is the union between two (or more) bones or cartilages; and it allows interstitial growth to go on.

Bones may be united in three different ways :—

(1) By intervening fibrous tissue = a *fibrous joint.*

(2) By intervening cartilage = a *cartilaginous joint.*

(3) By a short, wide tube of strong fibrous tissue ; tube surrounds a space between the two bones ; space is filled with an oily liquid, called **synovia,** secreted by a membrane that lines the tube. That kind of union is a *synovial joint.*

In (1) and (2) the fibrous tissue or the cartilage separates the bones as well as unites them ; if the uniting medium ossifies, the two bones are immovably welded together as one. That process of fusion of two originally separate bones is called *synostosis.*

Fibrous Joints.—Two types : syndesmosis ; suture.

Syndesmosis.—Bones, a little distance apart, united by an intervening *ligament* or *membrane* of some thickness and width, which, by twisting and slight stretching, allows a little movement, *e.g.*, lig. flava of vertebræ, coraco-clavicular lig., interosseous membrane of leg.

Syndesmoses persist throughout life.

Suture.—Practically immovable. Found only in skull. Articulating margins (or surfaces) are united by an intervening thin ribbon of fibrous tissue, called *sutural ligament,* whose edges are blended with the periosteum on the surfaces of the bones. Sutures disappear by synostosis—the interfrontal as early as the 6th year ; most of them during middle age ; but some persist till old age.

VARIETIES OF SUTURE.—**Serrate** and **denticulate :** between bones with saw-like or dovetail edges. **Squamous :** between bevelled, overlapping edges. **Limbous :** when overlapping edges

are ridged like the welt of a boot. **Flat :** between two thick, flat edges. **Wedge-and-groove :** an edge fitting into a groove. **Peg-and-socket :** a rounded root fitting into a socket—styloid process is the only example, except the teeth.

Cartilaginous Joints.—Two types: primary; secondary.

Primary Cartilaginous Joint (Synchondrosis).—Immovable. Union by an intervening plate of *hyaline* cartilage whose perichondrium is directly continuous with the periosteum of the united bones. The cartilage is not an independent formation; it is merely part of the primary rod in which the bones were formed, and ossification gradually extends into it. These joints, therefore, all disappear by synostosis—some during childhood, most of them during adolescence, and the rest in the adult.

Primary cartilaginous joints are numerous in youth.—Between :—(1) **All diaphyses and epiphyses.** (2) Ethmoid and sphenoid. (3) Sphenoid and basi-occiput. (4) Basi-occiput and petrous temporal. (5) Petrous temporal and jugular process. (6) Upper and lower parts of styloid process. (7) Body and greater horn of hyoid bone. (8) Body and arch of vertebra ; each pair of laminæ ; arches of atlas ; four parts of axis ; bodies, arches and costal parts of sacrum. (9) Segments of body of sternum. (10) Sternum and first pair of ribs.

Joint between sternum and first rib differs from other primary cartilaginous joints in that (*a*) the cartilage is long enough to allow slight movement by bending and twisting, and (*b*) it does not ossify.

Secondary Cartilaginous Joint. (Amphiarthrosis).—Exists only in median plane—between bodies of vertebræ, between manubrium and body of sternum, between pubic bones (pubic symphysis).

Articular surfaces are coated with hyaline cartilage, and are united by an intervening disc of fibro-cartilage surrounded by a ring of strong fibrous tissue which is continuous with the periosteum of the two bones. Twisting of disc and yielding at different points under pressure allow limited movement.

These joints persist throughout life between bodies of movable vertebræ and at pubis. They disappear by synostosis in sacrum between 18 and 25, in coccyx at very variable dates, between manubrium and body of sternum in old age.

The thin layers of hyaline cartilage that coat the articular surfaces are persisting parts of the separate cartilages in which the bones were formed. The cartilage in a disc arises from an independent and partial chondrification of the tissue between two primary cartilages.

Synovial Joints (Diarthroses).—Free to move. Include most joints in the adult. Persist throughout life—with a few unimportant exceptions.

The bones are united by a **joint-capsule** that encloses a **joint-cavity** filled with **synovia**; the parts of the bones in contact with each other are coated with smooth, hyaline **articular cartilage**. Capsule has two layers—*capsular ligament* and its lining of *synovial membrane*.

Capsular ligament is a short, wide tube attached by its ends to the bones at a varying distance from the margins of articular cartilages; bone inside a capsule may, therefore, be partly non-articular. Capsular lig. is the essential bond between the bones, but is loose enough to allow movement of the bones. It is made of strong fibrous tissue; and in many joints it is strengthened by thickenings of its own substance, by expansions from tendons and deep fascia, or by accessory ligaments.

Synovial membrane lines capsular lig., is reflected on to the bone, and covers its non-articular parts up to margins of articular cartilage, which it overlaps. It covers also the structures that lie within certain joints, and excludes them from the joint-cavity. It bulges out through gaps in the capsular lig. of certain joints to form (1) bursæ under tendons or (2) sheaths around tendons that have escaped from joints.

Synovial membrane is velvety and very vascular. It is made of very fine fibrous tissue containing numerous connective-tissue cells. From its surface, small elevations of varying shapes, called **synovial villi**, project into the joint-cavity; and in certain places it is pinched up to form **synovial folds.**

Synovia lubricates the surfaces, nourishes articular cartilage, and contains phagocytic cells that remove micro-organisms and the detritus from the articular surfaces.

INTRA-ARTICULAR STRUCTURES.—Are of different kinds:—

(1) **Fatty pads** that fill up inequalities, and sometimes bulge the synovial membrane into the joint-cavity.

(2) **Discs** and **menisci** of fibro-cartilage that are attached to capsular lig., and separate articulating surfaces—completely in *mandibular* and *sterno-clavicular* joints and *between ulna and carpus*; incompletely in *acromio-clavicular* joint and *knee.*

(3) A fibro-cartilaginous ring, called a **labrum,** attached to the rim of the acetabulum and the rim of the glenoid cavity of scapula.

(4) **Ligaments** that stretch across a joint between articulating

parts: *cruciate ligs.* of knee; *lig. of head of femur*; *intra-articular ligs.* of costo-vertebral and chondro-sternal joints.

(5) **Tendons** that arise within joints: *popliteus*, in knee; *long head of biceps*, in shoulder.

Synovial Joints that Disappear.—Joint between body of hyoid bone and lesser horn disappears after middle age, almost invariably. Chondro-sternal joints, at varying periods, frequently. Distal joints of smaller toes, occasionally.

CHIEF MOVEMENTS AT SYNOVIAL JOINTS.—Around a Transverse Axis. *Flexion:* making an angle between two segments, or making the angle more acute. *Extension:* straightening out an angle, or undoing an angle made by flexion. Occasionally flexion and extension mean bending forwards and backwards respectively, an angle being made in both movements. **Dorsiflexion** at wrist, fingers and toes means bending backwards from the straight or extended position, and it is sometimes called *hyperextension*. At the ankle, the term *dorsiflexion* is a substitute for flexion, and *plantar flexion* for extension.

Around a Horizontal Antero-posterior Axis.—*Abduction* and *adduction* from and towards the median plane, or some other plane agreed upon.

Circumduction is a succession of movements around the transverse and antero-posterior axes and all intervening horizontal axes. In circumduction the moving segment describes or moves round a conical figure, of which the base is never quite circular.

Around a Longitudinal Axis.—*Rotation.* Rotatory movement can take place at the flat joints, pivot-joints and ball-and-socket joints. Rotatory movements of the radius, combined with rotation of the humerus, are called *supination* and *pronation*; the combined rotatory movements of the tarsal bones are called *eversion* and *inversion*.

VARIETIES OF SYNOVIAL JOINT.—Shape of articular surfaces alone may determine the variety; or shape and kind of movement allowed.

Homomorphic Joints.—The two articulating surfaces are alike. (1) **Plane joint:** Surfaces flat or nearly flat; slight gliding or rotation of one surface on the other, *e.g.*, carpal joints. (2) **Saddle-joint:** two saddle-shaped surfaces, the convexity of the one fitting the concavity of the other; chief movements are around two axes at right angles; best example is the carpo-metacarpal joint of thumb.

Heteromorphic Joints.—The articulating surfaces are unlike. (1) **Hinge-joint:** Movement around one horizontal axis, *e.g.*, elbow. Capsular lig. is lax and weak in front and behind; strong and taut at the sides. (2) **Pivot-joint** is another kind of hinge, but the movement is around a longitudinal axis—a ring moving round a pivot, *e.g.*, atlas around odontoid process; a pivot moving within a ring, *e.g.*, head of radius. (3) **Ellipsoid joint:** A convex surface of oval

outline fits into an oval concavity. Chief movements are around two axes at right angles, but movements take place around intervening axes also; the joint can therefore be flexed, extended, abducted, adducted and circumducted, *e.g.*, wrist-joint.

(4) **Ball-and-socket joint**—most movable of joints, and capsular lig. is very lax. Movement around axes in every position. Chief axes are a longitudinal axis for rotation, and horizontal axes for flexion, extension, abduction, adduction and circumduction. Best examples are hip-joint and shoulder-joint. (5) A **condyloid joint** resembles a ball-and-socket joint in that a rounded surface (the condyle) fits into a socket; but there is no rotation around a longitudinal axis owing to restraint by ligaments and to the absence of rotator muscles. Metacarpo-phalangeal joints are examples.

JOINTS OF VERTEBRAL COLUMN

Between Movable Vertebræ.—Bodies are united by secondary cartilaginous joints—*fibro-cartilaginous discs* supplemented by *longitudinal ligaments*. In cervical region, they are united also by the capsules of small synovial joints between their lateral parts.

Vertebral arches are united by the capsules of synovial joints between articular processes, and by ligaments—intertransverse, interspinous, supraspinous and lig. flava.

Intervertebral discs are attached firmly to the articular cartilage that covers upper and lower surfaces of bodies. They form one quarter of length of vertebral column, and contribute largely to cervical and lumbar curvatures. Each disc is fibrous at circumference; pulpy and very elastic in centre. They are thickest in loin. In neck they do not reach the postero-lateral edges of bodies, for there the bodies are united by synovial joints, which are in series with the joints of heads of ribs. The disc between the axis and the third vertebræ is small, and that is the weakest point in the vertebral column—though the disc between the fifth and sixth cervical vertebræ is even smaller.

Anterior Longitudinal Lig.—Wide and thick; extends from anterior arch of atlas to sacrum; attached to the fronts of bodies and discs. It is reinforced in the abdomen from the crura of the diaphragm, and in the thorax from the lower parts of the longus cervicis muscles. Its upper part is a thick, narrow band set between that pair of muscles.

Posterior Longitudinal Lig.—Narrower, but widened opposite the discs, and therefore has toothed margins. Lies in anterior wall of vertebral canal from axis vertebra to sacrum; attached to the backs of bodies and discs.

Intertransverse ligs. are very weak.

Capsules of synovial joints between articular processes are thin and loose, to allow gliding.

Lig. flava are a pair of thin, strong, elastic sheets that connect the laminæ of each two contiguous vertebræ. *Laterally*, each blends with the capsule. *Medially*, they are separated by a little fatty areolar tissue. Attached *inferiorly* to outer surface and upper border of lamina; *superiorly* to inner surface and lower border of cervical or lumbar lamina, to inner surface only of thoracic lamina. Therefore seen better from within vertebral canal.

Interspinous ligs. are attached to adjacent spines, from base to tip.

Supraspinous ligs. form a long, continuous band attached to tips of spines along whole length of column. In the neck, it is specialised to form *lig. nuchæ* (p. 279).

Between Fifth Lumbar Vertebra and Sacrum.—Joints and ligaments as between two typical vertebræ. But *intertransverse lig.* is a triangular band called **lumbo-sacral lig.**, covered by psoas major, attached by apex to 5th lumbar transverse process, by base to ala of sacrum, blending with anterior sacro-iliac lig.

Between Sacrum and Coccyx.—*Fibro-cartilage* and *anterior* and *deep posterior sacro-coccygeal ligs.* connect 5th sacral and 1st coccygeal bodies; a pair of *intercornual ligs.* connect the cornua; a pair of *lateral sacro-coccygeal ligs.* connect lower lateral angles of sacrum with transverse processes of 1st piece of coccyx; and the *superficial posterior sacro-coccygeal* ligs. connect the margins of sacral hiatus with the back of the coccyx.

MOVEMENTS OF VERTEBRAL COLUMN.—Limited between any two vertebræ; considerable over column as a whole.

Flexion is most extensive of all; least in thoracic region. *Produced* mainly by sterno-mastoid, longus cervicis and capitis, scaleni, rectus abdominis, psoas major and minor. *Checked* by posterior part of the discs and all ligaments behind that.

Extension is limited; least in thoracic region. *Produced* mainly by sacro-spinalis and its divisions. *Checked* by ant. longitudinal ligament, the discs, and approximation of spines.

Lateral flexion is best marked in cervical region, where it is always combined with rotation owing to the oblique direction of the articular surfaces. *Produced* by sacro-spinalis, semispinales, splenius, scaleni, quadratus lumborum, psoas major. *Checked* by all ligaments on opposite side, and by resistance of ribs and sternum.

Circumduction is a combination of above movements.

Rotation is best marked in the upper half of the column; and is absent in the upper part of the lumbar region owing to the shape of articular processes. *Produced* by sterno-mastoid, scaleni, longus capitis, semispinales, multifidus, rotatores, abdominal muscles.

Checked by locking of articular processes, by the resistance of twisted discs and by all the ligaments.

Articulations of Atlas and Axis with each other and with Skull

AXIS WITH ATLAS.—By anterior longitudinal lig., lig. nuchæ, lig. flava, a pair of synovial joints at the sides, and by the articulations of the odontoid process.

Uppermost part of **anterior longitudinal lig.** connects front of body of axis with anterior arch of atlas.

Part of **lig. nuchæ** connects spine of axis with posterior tubercle of atlas.

First pair of **ligamenta flava** unite laminæ of axis to posterior arch of atlas. Lie under cover of obliquus capitis inferior.

Synovial joint between superior articular surface of axis and lower surface of lateral mass of atlas is homologous with the small synovial joint between the lateral parts of bodies of other cervical vertebræ, and not with joints between articular processes; second cervical nerve is therefore behind the joint instead of in front of it, and the nerve pierces lig. flavum. *Articular capsule* is attached near the margins of the articular surfaces, and is greatly strengthened postero-medially.

Longus capitis and cervicis are *anterior* relations of this joint. Obliquus capitis inferior is *behind* it. *Lateral* relations are—vertebral artery, anterior primary ramus of second cervical nerve, the posterior intertransverse muscle, and a slip of scalenus medius. The trunk of the second cervical nerve is *medial* to the joint; its anterior primary ramus runs sidewards immediately above the back of the joint before it curves forwards to cross the lateral side of the vertebral artery at the lateral side of the joint.

Capsules of **synovial joints** connect odontoid process with the back of anterior arch of atlas and the front of the transverse lig.

Transverse ligament is a strong curved band that stretches between the lateral masses of atlas, across the back of the odontoid process and holds it in place against the anterior arch of atlas.

AXIS WITH SKULL.—By lig. nuchæ, by longitudinal bands of cruciate ligament, by apical and alar ligaments of odontoid process, and by membrana tectoria.

Lig. nuchæ connects all cervical spines with each other and with external occipital crest and protuberance.

Cruciate lig. is made up of the *transverse lig.* with two *longitudinal bands*, one of which stretches down from it to the back of body of axis, while the other stretches up from it to the basi-occiput within the anterior lip of foramen magnum.

Apical lig. of odontoid process.—Weak and short. Connects

the apex of odontoid process with the middle of the anterior margin of foramen magnum. It is in front of the upper band of the cruciate lig. and behind the anterior atlanto-occipital membrane. Contains the remains of the notochord.

Alar ligs. are a pair of strong bands that pass from the top of the odontoid process to the medial sides of the occipital condyles.

Membrana tectoria is a thin, wide ligament, continuous inferiorly with posterior longitudinal lig. It stretches from the back of body of axis to the upper surface of basi-occiput a little above foramen magnum, being attached along a curved line that connects the anterior condylar canals. It lies behind the cruciate lig. and the odontoid process and its ligaments, and conceals them. It is adherent, posteriorly, to the uppermost part of the spinal dura mater. On each side it fuses with the articular capsules.

ATLAS WITH SKULL.—By anterior and posterior atlanto-occipital membranes and a pair of synovial joints.

Synovial joint between lateral mass and occipital condyle is homologous with the small synovial joints between the lateral parts of bodies of cervical vertebræ; the first cervical nerve therefore emerges behind it. *Capsule* is attached near the margins of the articular surfaces and is fairly loose.

The joint is opposite the mastoid process. It is related *anteriorly* to rectus capitis anterior; *posteriorly* to suboccipital veins and rectus posterior major; *laterally* to hypoglossal nerve and internal jugular vein, and, behind them, to rectus lateralis; *medially* to medulla oblongata and upper end of odontoid process. The vertebral artery winds medially round the back of the lateral mass below the joint-level and the first cervical nerve crosses the posterior arch of atlas below the artery.

Anterior atlanto-occipital membrane connects anterior arch of atlas with anterior margin of foramen magnum; at each side it fuses with the capsule. A thickening in its middle is continuous with anterior longitudinal lig.; on each side of that it is covered by longus capitis; posteriorly it is related to the apical and alar ligs.

Posterior atlanto-occipital membrane is much wider than the anterior. Superiorly, it is attached to the posterior margin of foramen magnum. At each side, it fuses with the capsule. Inferiorly, its median part is attached to posterior arch of atlas between the pair of grooves for the vertebral arteries, while each lateral part has a free, thickened edge that arches over the groove for vertebral artery to be attached laterally to the lateral mass, and is sometimes ossified—converting the groove into a foramen. Internally, it is adherent to the uppermost part of the spinal dura mater; externally, it is covered by the posterior recti.

MOVEMENTS.—I. **Atlas,** carrying head with it, **rotates on axis**—pivoting around odontoid process, and gliding at the synovial joints. Movement *produced* mainly by semispinalis capitis and sterno-

mastoid of one side, with obliqui, rectus posterior major, splenius, longissimus, and longus capitis of opposite side; *checked* by the alar ligs. and by tension of the capsules.

II. **Nodding movements of head on atlas** take place at joints between occipital condyles and lateral masses (and are accompanied by movement of neck). **Flexion,** *produced* mainly by longus capitis and rectus anterior; *checked* by posterior ligaments. **Extension,** mainly by recti posteriores, semispinalis capitis, splenius, trapezius (and possibly sterno-mastoid, which, however, flexes cervical vertebræ); *checked* by anterior ligaments. **Lateral movements,** very slight, *produced* by rectus lateralis, sterno-mastoid, trapezius splenius, semispinalis capitis); *checked* by capsules and alar ligs.

MANDIBULAR JOINT

Is a synovial joint formed by articulation of head of mandible with the articular fossa and eminence of temporal bone; but the articulating surfaces are completely separated by an articular disc that divides the joint-cavity into an upper and a lower chamber.

Capsular lig. is lax, and is attached near the margins of the articular surfaces. Its lateral part is thickened to form the *temporo-mandibular lig.*, which stretches from the zygoma and the tubercle at its root to the lateral and posterior surfaces of neck of mandible.

The circumference of the **articular disc** is fused with the capsular lig. Its lower surface is concave, to fit on to head of mandible. Its upper surface is undulating, to fit the fossa and eminence.

Synovial membrane is in two separate parts, lines the capsular ligament in each chamber and is reflected on to the disc (from which it disappears in the adult).

Vessels and Nerves.—Superficial temporal and masseteric arteries; auriculo-temporal and masseteric nerves.

MOVEMENTS.—Depression, produced by digastric, mylo-hyoid, genio-hyoid, platysma, and by gravity. **Elevation,** by masseter, medial pterygoid, temporalis. These movements take place around an axis that passes through mandibular foramina. **Protrusion,** by pterygoids and superficial fibres of masseter. **Retraction,** by posterior part of temporalis, deep part of masseter. **Grinding,** by pterygoids of opposite sides acting alternately. In protrusion and retraction, movement is mainly between disc and temporal bone. When depression and elevation are slight it is mainly between disc and condyle; when considerable it is in both situations, and disc

and condyle both pass forwards on to articular eminence. Depression is checked by temporo-mandibular ligament. Sudden excessive depression may lead to dislocation.

RELATIONS.—Superficial or **lateral** to the joint there are :—(1) skin and fasciæ, (2) parotid gland, and (3) some of the temporal branches of the facial nerve emerging from parotid. A little lower there are the transverse facial vessels and the zygomatic branches of the facial nerve.

The lateral pterygoid muscle is inserted into the **anterior** part of the capsule of the joint ; and the nerve and vessels to masseter pass laterally, above the lateral pterygoid, in front of the joint.

Posterior surface is related to the parotid gland, which separates it from both the cartilaginous and osseous parts of the external auditory meatus ; but when the jaws are closed the head of mandible exerts pressure on the cartilaginous part, through the parotid. The pressure is relieved when mouth is opened ; this may be tested by the finger placed in the meatus. Superficial temporal artery and the upper part of the posterior facial vein, which accompanies the artery here, lie between the joint and the parotid, near the skin surface. Auriculo-temporal nerve, at first medial to the joint, runs laterally, behind the joint, between it and the parotid, before ascending over the posterior root of zygoma.

Medial :—(1) *Tympanic plate* and bony part of *pharyngo-tympanic tube* separate the capsule from the *internal carotid artery*, which, as it enters the carotid canal, is medial to the posterior part of the joint, opposite the anterior margin of the external auditory meatus.

(2) Farther forward, the *spine of sphenoid* and the upper end of *spheno-mandibular lig.* with *chorda tympani* running downwards and forwards grooving the medial side of the spine and the *auriculo-temporal nerve* running sidewards and backwards on the lateral side of the ligament.

(3) Still farther forward, the *middle meningeal artery*, approaching the foramen spinosum, and, in front of that, the *mandibular nerve* descending from the foramen ovale medial to the most anterior part of the capsule, opposite the tubercle of the root of zygoma.

(4) The *lateral pterygoid muscle*, together with *fat* and *veins*, separates 3 and 2 from the joint ; for, owing to the obliquity of the long axis of the articular head, the muscle is a close medial relation of the capsule (as well as an anterior relation), especially when the mouth is shut and the head is below the articular fossa.

Below the medial side of the joint, the maxillary artery (with its vein or veins) passes forwards between the neck of the mandible and the spheno-mandibular lig.

Above the joint, there is the middle cranial fossa with its contents ; the trunks of the middle meningeal vessels groove the floor of the cranial fossa directly above the articular eminence.

Cranial Ligaments not directly associated with Joints

Spheno-mandibular lig. is a thin band, fairly long and fairly wide, that stretches from the spine of the sphenoid to the lingula and the margins of mandibular foramen. It is probably derived from the fibrous sheath around Meckel's cartilage. *Medially*, its upper part is separated by fat from the wall of naso-pharynx (tensor and levator palati and cartilage of tube), while its lower part lies on the medial pterygoid muscle. *Laterally*, it is related to mandibular joint and mandible, but is separated from them, from above downwards, by auriculo-temporal nerve, lateral pterygoid muscle, maxillary vessels, and inferior dental vessels and nerve; a process of parotid gland sometimes accompanies the maxillary vessels.

Pterygo-mandibular lig. is a slender tendinous band that stretches from the tip of the pterygoid hamulus to the posterior end of the mylo-hyoid line of mandible. It can be felt as a ridge under the mucous membrane by the finger passed back in the mouth and pressed sidewards behind the last molar teeth. It gives origin to part of buccinator, which passes forwards from it, and to a great part of the superior constrictor, which curves backwards from it.

Pterygo-spinous lig. is a variable band that passes from the spine of the sphenoid to the lateral pterygoid plate. May contain fleshy and tendinous fibres; may ossify and form, with the base of the skull, a foramen that transmits the branches of mandibular nerve to masseter, temporalis and lateral pterygoid.

Stylo-mandibular lig. is a thickened part of the extension of cervical fascia that clothes the deep surface of the parotid gland. It extends from styloid process to the posterior border and angle of mandible; it separates parotid and submandibular glands.

Stylo-hyoid lig. is a slender band that passes from tip of styloid process to lesser horn of hyoid bone. May ossify, and be mistaken for a foreign body in wall of pharynx (*see also* p. 316).

JOINTS OF RIBS AND OF STERNUM

Heads of ribs are united to bodies of vertebræ by synovial joints; **necks** to transverse processes by fibrous joints; **tubercles** to transverse processes by synovial and fibrous joints.

Shafts are continuous with costal cartilages.

Some **costal cartilages** are united to each other, mostly by synovial joints; the upper seven are united to the **sternum** by synovial joints (except the first).

Segments of sternum are united by cartilaginous joints,

and manubrium is united to the two clavicles by a pair of synovial joints (p. 128).

JOINT OF HEAD.—Head of typical rib articulates with vertebra of corresponding number and vertebra above and with the disc between them; and is held in place by *capsular*, *radiate* and *intra-articular* ligs.

Capsular lig. is attached to margins of articulating surfaces.

Radiate lig., the thickened anterior part of capsule, radiates in three bands from anterior surface of head of rib to the disc and the bodies of the two vertebræ; pleura and sympathetic trunk are related to its anterior surface.

Intra-articular ligament extends from crest of head of rib to the disc, and is attached to capsular lig. in front and behind. It divides joint-cavity into an upper and a lower part; absent in 1st, 10th, 11th, 12th joints, where rib articulates with only one vertebra.

JOINT OF NECK.—Neck of rib is firmly attached by the *costo-transverse* ligs. to the transverse process of the same number and to the one above.

Inferior costo-transverse lig. consists of short, strong fibres that pass from the back of the neck of a rib to the front of the transverse process of the same number, and fill up the interval between them. Weak or absent in 11th and 12th ribs.

Superior costo-transverse lig. is a flat fibrous band of some width that passes upwards and sidewards from the upper border of neck of rib to the lower border of transverse process next above. Related *posteriorly* to longissimus thoracis; *anteriorly* to intercostal vessels and nerve. *Lateral margin* is continuous with posterior intercostal membrane; *medial margin* is a free edge that bounds the aperture for transmission backwards of posterior branches of intercostal vessels. Absent from 1st rib.

Lumbo-costal lig., in the same series, extends from 1st lumbar transverse process to 12th thoracic transverse process and to 12th rib.

JOINT OF TUBERCLE.—Tubercle of rib, by its facet, articulates with the front of the transverse process of the same number, near its tip. It is attached by the **capsular lig.** of that joint and by the **lateral costo-transverse lig.** This ligament is a strong band that lies on the postero-lateral surface of the capsule, and stretches from the rough part of the tubercle to the tip of the transverse process. The joint and ligs. are absent in 11th and 12th ribs.

JOINT OF SHAFT AND CARTILAGE.—Costal cartilage fits into a pit at the anterior end of a rib, and it is held there by the continuity of perichondrium and periosteum.

INTERCHONDRAL JOINTS.—Fifth to ninth costal cartilages articulate by oblong, elevated facets on their contiguous margins. Capsular ligs. are strengthened on their deep and superficial surfaces. Tenth is united to ninth by intervening fibrous tissue.

COSTO-STERNAL JOINTS.—First costal cartilage is attached to the margin of manubrium by the continuity of perichondrium and periosteum. It is the cartilage of a cartilaginous joint between the first rib and the manubrium.

2nd, 3rd, 4th, 5th and 7th articulate with the margin of sternum at the junctions of its segments, and the 6th at the side of the fourth segment of the body. They are synovial joints, and in each of them the ligaments are *capsular*, *radiate* and *intra-articular*.

Capsular lig. is attached to the margins of articulating surfaces.

Radiate ligs. are the thickened anterior and posterior parts of the capsular lig., whose fibres radiate from the costal cartilage to the front and back of sternum, mingling with those above and below and of opposite side. Those on front are stronger, and form a thick, pelted membrane which is fused with the fibres of pectoralis major.

Intra-articular lig. stretches from cartilage to side of sternum, and divides joint-cavity into an upper and a lower chamber. Always present in second. Inconstant in the others. Sometimes obliterates cavities of sixth and seventh.

STERNAL JOINTS.—Segments united by cartilage supplemented by the radiate ligs. The joints are not permanent. (*See* p. 20.) But joint between manubrium and body persists till old age and the union is by fibro-cartilage; for, during respiration, the manubrium moves less than the rest of the sternum, and a little yielding movement takes place between manubrium and body.

Movements of Ribs

Around two axes. (1) Whole rib is moved around an axis that passes through sternum and the posterior end of the shaft of the rib. (2) Anterior end of rib, with sternum, is raised and thrust forwards by movement around an axis that passes through head, neck and tubercle.

Elevation, in ordinary inspiration, is produced by intercostals and subcostals; **depression,** by elasticity and gravity.

MOVEMENTS IN RESPIRATION.—Type of ordinary respiration may be either *abdominal* or *thoracic*, or a combination of these two.

In the *abdominal* type, **inspiration** is produced by the diaphragm. The central tendon and the peripheral attachments are relatively fixed. The fleshy fibres contract and straighten, and therefore descend between the points of their attachment, changing the dome of the diaphragm into a cone with the apex cut off, and enlarging the thoracic cavity; by this movement, the abdominal viscera are displaced, and push out the anterior abdominal wall. **Expiration** is brought about by the elastic recoil of the abdominal wall, which, acting through the viscera, pushes the diaphragm up again into its position of rest. Ordinary quiet abdominal respiration is accompanied by exceedingly little movement of thoracic walls.

In the *thoracic* type, ordinary quiet **inspiration** is produced by

the intercostals, but is accompanied by movement of the diaphragm, unless there is some impediment to its action. In ordinary inspiration the 1st and 2nd ribs move little, if at all. The middle parts of the shafts of 3rd to 6th ribs are raised like pail-handles and, therefore, increase the transverse diameter of the thorax; for ribs are arcs of circles that increase in size from above downwards, and each is raised towards the position of the one above. The anterior ends also are raised; and, since ribs are oblique in position, that means that they are thrust forwards as well, raising and pushing forwards the body of the sternum, which moves on the manubrium. The antero-posterior diameter is increased in this way, and the transverse as well, for the costal ends of costal cartilages are raised with the ribs, so that the oblique costal cartilages come to occupy positions nearer the horizontal and push the anterior ends of the ribs farther away from the median plane.

The anterior ends of 7th to 10th ribs also are slightly elevated. The shafts are not only raised but are drawn sidewards and backwards. That movement undoes the movement of the anterior ends in the forward direction, but increases the infracostal angle and the width of the thorax, and increases also the capacity of the upper part of the abdomen, in order to accommodate abdominal viscera—displaced by the descent of the diaphragm.

Expiration is brought about by gravity and the elasticity of the ligaments and costal cartilages.

Twelfth rib is fixed by sacrospinalis, quadratus lumborum and fascia, and its fixation makes eleventh rib practically immovable.

In *forced respiration* the head and shoulders are fixed; the sterno-mastoid and trapezius, and all muscles attached to ribs and costal cartilages, may be called into play. All the movements are exaggerated, and, in addition, the manubrium and anterior ends of 1st and 2nd ribs are raised, and the vertebral column is straightened and bent backwards during inspiration. At the end of forced inspiration the anterior abdominal wall is retracted, for it follows the viscera as they retreat into the space created at upper part of the abdominal cavity by the increased splaying out of 7th to 10th ribs.

JOINTS OF UPPER LIMB

Sterno-Clavicular Joint.—Synovial. Sternal end of clavicle articulates with sternum at the clavicular notch (articular disc intervening) and with first costal cartilage. Union is by *capsular lig.*; reinforced by *anterior* and *posterior sterno-clavicular ligs.*, and supplemented by *interclavicular* and *costo-clavicular ligs.* and *articular disc.*

Capsular lig. is attached to margins of articular surfaces; it is strengthened behind and still more so in front by fibres that pass upwards and sidewards to clavicle from manubrium and first cartilage, forming the *anterior* and *posterior sterno-clavicular ligs.*

Interclavicular lig. is blended with the upper part of the apsular lig. Each end is attached to the rough, upper art of sternal end of clavicle; its middle is adherent to ıe upper margin of manubrium.

Articular disc helps to hold the clavicle in place. It lso divides the joint-cavity into two, separating clavicle om manubrium (but not from first costal cartilage).

Anteriorly and *posteriorly* it is fused with the capsular g. It is attached *superiorly* to sternal end of clavicle above rticular surface; *inferiorly* to first cartilage, close to anubrium.

Costo-clavicular lig., short, thick, strong, is close to ıe inferior part of capsule, which is weak. Passes upards and sidewards and backwards from first rib and rtilage (at their junction) to a rough impression on the wer surface of clavicle near its sternal end.

Nerve-Supply.—Medial supraclavicular.

RELATIONS.—Superior: capsule and interclavicular lig. are subtaneous. **Anterior:** upper fibres of pectoralis major; sternal head sterno-mastoid. **Posterior:** sterno-hyoid and sterno-thyroid, ıich separate right joint from innominate artery, and left joint ım left innominate vein (and common carotid behind the vein). Costo-clavicular lig. is related *anteriorly* to the origin of subavius; right lig. is related *posteriorly* to right innominate vein; t lig. to left innominate or subclavian or both.

MOVEMENTS.—Elevation of shoulder: *produced* by upper part of apezius, levator scapulæ, sterno-mastoid, rhomboids; *checked* by sto-clavicular ligament. **Depression:** by subclavius, pectoralis nor, lower part of trapezius, and by gravity; *checked* by disc d interclavicular ligament. **Movement forwards of shoulder** by ratus anterior, pectoralis minor; **backwards,** by trapezius and mboids. **Circumduction** is a combination of these. Some **rotan** takes place, especially with the up and down movements. Movements are chiefly in lateral compartment; but some of the ward and backward movement is between disc and manubrium.

Acromio-Clavicular Joint.—Synovial. Acromial end of avicle articulates with medial margin of acromion. nited by **capsular lig.**, which is attached to margins articular surfaces, and is strengthened superiorly to rm *acromio-clavicular lig.* An **articular disc**, attached to pper part of capsular lig., hangs down into the cavity; ually incomplete; often absent.

Superiorly, the joint is subcutaneous; *inferiorly*, it is related to fat and supraspinatus.

Coraco-clavicular lig. is reckoned an accessory ligament of this joint, because it helps to keep clavicle and acromion in apposition and to prevent dislocation, which tends to be upwards owing to oblique direction of articular surfaces at this joint.

It is hidden behind deltoid and subclavius, in front of the fat below trapezius.

It is the chief bond between clavicle and scapula; and its chief function is to suspend the major part of upper limb from the clavicle.

It is divided into two parts: (1) *Trapezoid lig.* situated antero-laterally, broad and flat; attached to upper surface of coracoid process and to trapezoid ridge of clavicle; lateral border is free. (2) *Conoid lig.* placed postero-medially; base is attached to conoid tubercle of clavicle, apex to coracoid process near scapular notch; medial border free, lateral border joined to trapezoid.

Conoid lig. restrains backward movement of clavicle on acromion, and trapezoid restrains forward movement. A *bursa* occupies angular recess between them in front, and lessens friction between them in these movements.

MOVEMENTS.—Scapula follows clavicle in its movements, but by slight gliding at this joint it is able, while following clavicle, to remain applied to chest-wall and retain direction of glenoid cavity practically unchanged in its relation to head of humerus.

Ligaments of Scapula.—**Coraco-acromial lig.** forms, with coracoid process and acromion, an *arch* for the greater protection and security of shoulder-joint.

Hidden under deltoid and clavicle, above subacromial bursa and supraspinatus.

Flat and triangular in shape. *Apex* attached to tip of acromion in front of facet for clavicle; *base* to lateral border of coracoid process. Thinnest in centre, where it is sometimes perforated by prolongation of tendon of pectoralis minor to capsule of shoulder-joint. *Upper surface* is in relation to deltoid and clavicle, *lower* to supraspinatus, subacromial bursa intervening.

Suprascapular lig. attached to upper margin of scapula and to root of coracoid process. Bridges across suprascapular notch; may ossify. Inferior belly of omo-

yoid arises from it. Suprascapular vessels pass back-
ards above it, suprascapular nerve below it.

Spino-glenoid lig. Very weak. May be absent. Stretches from
e lateral border of the spine to the back of the head of scapula.
iprascapular vessels and nerve pass deep to it on their way to the
fraspinous fossa.

Shoulder-Joint.—Synovial. Ball-and-socket. Head of
umerus articulates with the floor of the glenoid cavity
f scapula, which is slightly deepened by the *labrum*
lenoidale.

Union is by *capsular lig.* supplemented by *coraco-*
umeral and *gleno-humeral ligaments.*

Labrum glenoidale is a ring of dense fibro-cartilaginous
ssue, triangular on section, attached to the rim of
enoid cavity to deepen and widen it. Long tendon of
iceps is largely incorporated in the upper part of it.

Transverse lig. is an important retinaculum that bridges
ross the upper end of the bicipital groove and holds
ie long tendon of biceps in position.

Capsular Lig.—Strong, but thin and exceedingly lax.

Scapular attachment is to outer surface of labrum and
rim of glenoid cavity outside the labrum, rising to
clude attachment of long head of biceps within the joint.

Humeral attachment encircles the head—close to articu-
r margin superiorly, but falling away from it behind
id in front till, inferiorly, it is half an inch below
ticular margin. Between the tuberosities, it is attached
the transverse lig.

Tendons of subscapularis, supra- and infra-spinatus
se with capsular lig. near their insertions and strengthen
, and, by pulling it away during their contraction, pre-
nt nipping of the lax capsule between the articular
rfaces. Capsule is further strengthened anteriorly by
n expansion from pectoralis major tendon.

Capsular lig. is least supported by muscles inferiorly,
id dislocation most often takes place there.

There is a gap in the ligament near the root of
racoid process under cover of subscapularis, and, some-
mes, another, at the back, under cover of infraspinatus.

Coraco-humeral lig., on upper part of capsule, re-
esents a prolongation of pectoralis minor tendon; ex-
nds from lateral margin of root of coracoid process to

anatomical neck at greater tuberosity. Blends with capsule behind and distally ; anterior border is free.

Gleno-humeral ligs. are three unimportant, ill-defined bands that lie between synovial membrane and the anterior part of capsular lig. **Superior** stretches from the labrum just in front of long tendon of biceps to upper part of lesser tuberosity. **Middle** begins near upper band and stretches to the middle of lesser tuberosity. The hole in the front of the capsular lig. is between upper and middle bands. **Inferior** stretches from middle of anterior edge of glenoid cavity to medial side of humerus half an inch below the head.

Synovial membrane lines the capsular lig. ; is reflected on to the labrum, and also over neck of humerus up to articular margin. It bulges through the gaps in the capsular lig. to form bursæ under subscapularis and infraspinatus. It gives a sheath to the long tendon of biceps ; the sheath extends down the bicipital groove and is then reflected upwards to become continuous with the joint-lining again beneath the transverse lig.

Nerve-Supply and Blood-Supply.—Suprascapular, upper subscapular and circumflex nerves ; suprascapular and humeral circumflex vessels.

RELATIONS.—(1) **Immediate.** Subscapularis and its bursa *anteriorly* ; supraspinatus *above* ; infraspinatus and bursa *above* and *posteriorly* ; teres minor *posteriorly*—all in close contact. Long head of triceps, posterior circumflex vessels and circumflex nerve, in the quadrilateral space, are *inferior* and are in close contact when arm is abducted ; and the part of subscapularis that arises alongside lateral margin of scapula is below the joint near the scapula.

Long tendon of biceps passes *through the joint* over the head of the humerus, but is excluded from the cavity by its synovial sheath.

(2) **More remote.** *Superiorly*, the subacromial bursa is covered by coraco-acromial arch and deltoid. *Anteriorly*, short head of biceps, coraco-brachialis, axillary vessels and the nerves in axilla are separated by subscapularis. *Inferiorly*, teres major is separated by the post. circumflex vessels and circumflex nerve in the quadrilateral space.

Deltoid overlaps anteriorly, posteriorly, laterally and above, but is nowhere in contact with capsule, being separated by coracoid process, coraco-acromial lig., subacromial bursa, and by the muscles attached to the tuberosities.

MOVEMENTS.—Accompanied by movements of shoulder-girdle. **Flexion** (movement forwards), *produced* by pectoralis major, coraco-brachialis, anterior part of deltoid, biceps. **Extension** (movement backwards), by latissimus dorsi, teres major and minor, posterior part of deltoid, infraspinatus, long head of triceps.

Abduction, by deltoid and supraspinatus. **Adduction,** by subscapularis, pectoralis major, teres major and minor, latissimus dorsi, coraco-brachialis, long head of triceps, and by gravity.

Circumduction, a combination of these four movements.

Lateral rotation, by infraspinatus, teres minor posterior part of deltoid. **Medial rotation,** much stronger owing to the number of muscles employed, viz., pectoralis major, anterior part of deltoid, subscapularis, latissimus dorsi, teres major.

Elbow-Joint.—Synovial; hinge. Capitulum of humerus articulates with head of radius; and trochlea, in trochlear notch, with olecranon and coronoid process of ulna.

Union is by a capsular lig. thickened at the sides to form *medial* and *lateral ligs.* The intervening parts are called the *anterior* and *posterior ligaments* of elbow.

Anterior ligament, broad and thin. Attached *superiorly* to upper margins of radial and coronoid fossæ and to the epicondyles; *inferiorly* to anterior margin of coronoid process and to annular ligament of radius.

Posterior ligament, very thin. Attached *superiorly* to the floor and lateral and medial margins of the olecranon fossa, and to the epicondyles; *inferiorly* to anterior and lateral margins of olecranon.

Lateral lig. spreads out from the lower edge of lateral epicondyle to the annular ligament.

Medial lig., thick in front and behind, and thin in the middle, radiates from the lower edge of medial epicondyle to medial margins of coronoid process and olecranon, and to an oblique band that bridges across the interval between them.

Synovial membrane lines capsular lig., covers bone within capsule up to margins of articular surfaces; is continuous with the lining of upper radio-ulnar joint. Pads of fat lie between capsular lig. and synovial membrane opposite radial, coronoid and olecranon fossæ.

Blood-Vessels.—The anastomosis around elbow-joint.

Nerves.—Ulnar, musculo-cutaneous, median, radial.

RELATIONS.—Anterior: brachialis covers nearly whole of ant. lig.; and some of its fibres arise from it. It separates the joint from brachial art. and venæ comitantes, tendon of biceps and median nerve. Medial to brachialis, the anterior recurrent ulnar artery is in relation to anterior lig., overlapped by pronator teres. Lateral to brachialis, the ant. ligament is covered by brachio-radialis and extensor carpi

radialis longus; under cover of these, there are radial recurrent art., and the radial nerve and its posterior interosseous branch.

Lateral: the common tendon of the extensors overlies the lateral ligament, and parts of the extensor carpi radialis brevis and supinator arise from it.

Medial: the common tendon of the flexors overlies the anterior band of the medial ligament, and the flexor sublimis arises from it; the flexor carpi ulnaris overlies the posterior band, and the ulnar nerve and the posterior ulnar recurrent artery lie directly on it and also on the middle portion, which is very thin.

Posterior: triceps and its bursa above the olecranon, and some fibres of triceps are inserted into the capsule; anconeus and the interosseous recurrent artery at the lateral side of the olecranon; the olecranon origin of the flexor carpi ulnaris at the medial side.

MOVEMENTS.—Flexion: *produced* mainly by biceps, brachialis, pronator teres, brachio-radialis, assisted to a small extent by the flexors and extensors of the hand and fingers, which are attached to the fronts of the epicondyles; *checked* by contact of the forearm and upper arm.

Extension: mainly by triceps and anconeus, *checked* by the anterior and lateral and medial ligaments before the olecranon can touch the humerus.

The line of the articulation is oblique; hence, the extended forearm forms with the upper arm an obtuse angle laterally. But the axis of movement is transverse, for it passes through the epicondylar ends of the lateral and medial ligaments.

RADIO-ULNAR JOINTS.—The ends of radius and ulna are united by synovial, pivot joints; the shafts by the interosseous membrane and the oblique cord.

Superior Radio-Ulnar Joint.— Head of radius is encircled by annular ligament and radial notch of ulna.

Annular lig. of radius is a strong band curved to form three-quarters of a circle (or more), and attached by its ends to the anterior and posterior margins of radial notch of ulna—forming, with the floor of the notch, a ring to hold head of radius in place. The ring is narrower below than above, and the head of radius is therefore more securely held.

Upper margin gives attachment to the lateral and anterior ligs. of elbow. *Lower margin* is very loosely connected to neck of radius by a thin fibrous ring which closes the joint inferiorly except in the interval between radius and ulna, where it is closed by the quadrate lig.

Outer surface is covered with muscles, and gives partial origin to supinator.

Synovial membrane, prolonged from elbow-joint, lines the *inner surface*, from which it is reflected on to neck of radius, and then extends upwards as a tube to overlap the articular margin of head.

Quadrate lig., small and weak, lies in the interval between neck of radius and lower margin of radial notch of ulna, to both of which it is attached. Anteriorly and posteriorly, it is attached to the lower margin of the annular lig.

Inferior Radio-Ulnar Joint.—Head of ulna articulates with the floor of the ulnar notch of radius laterally, and with articular disc inferiorly.

Union is by the *articular disc*, aided by a weak *capsular lig.* attached to the margins of the articular surfaces.

Articular disc, triangular in outline, is attached by its base to the edge between carpal and medial surfaces of distal end of radius, by its apex to the floor of the pit between styloid process and head of ulna, by its margins to the capsular lig. and the radio-carpal ligaments.

Surfaces are covered with synovial membrane; upper surface articulates with head of ulna; lower with os unatum, and, when hand is adducted, with triquetrum.

Synovial membrane lines disc and ligaments, and bulges upwards to line the *recessus sacciformis* (when present).

Nerves and Vessels.—Ant. and post. interosseous.

The **capsular ligament,** thin and membranous, is made of transverse fibres that pass from the anterior and posterior margins of ulnar notch of radius to the margins of the articular surface on the front and back of head of ulna. Inferiorly, it fuses with the margins of the articular disc. Superiorly, it fuses with the lower end of the interosseous membrane, but may extend upwards for some distance between the bones before doing so—enclosing a space called the *recessus sacciformis.*

Interosseous Membrane.—Broad, thin, strong. Attached to interosseous margins of radius and ulna and to the posterior of the two ridges into which the lower end of the interosseous margin of the radius divides. Begins one inch below radial tuberosity, and extends to capsule of inferior radio-ulnar joint, with which it blends.

Interosseous membrane binds radius and ulna together, and increases surface for origin of muscles. Its fibres run mostly downwards and medially, from radius to ulna; in this way, shocks transmitted to radius from hand are passed on to ulna and thence

to humerus. Flexor pollicis longus and digitorum profundus arise from upper three-quarters of **anterior surface**; ant. interosseous vessels lie between them, and perforate it near lower end; pronator quadratus lies on lower quarter. **Posterior surface** gives origin to abductor pollicis longus, extensor poll. brevis and longus, and extensor indicis; supinator lies on its upper part, and anterior interosseous vessels and posterior interosseous nerve on its lower part.

The **oblique cord** is a slender band that passes from tuberosity of ulna to the radius immediately below its tuberosity. The posterior interosseous vessels pass backwards through the gap between the cord and the interosseous membrane.

MOVEMENTS OF RADIO-ULNAR JOINTS. — Initiated by brachio-radialis. **Pronation,** *produced* mainly by pronator teres and quadratus, and brachio-radialis. **Supination,** mainly by supinator, biceps and brachio-radialis.

Position of supination is that in which the bones of forearm are parallel, and *thumb points laterally*.

In the **position of pronation**, the radius crosses in front of ulna, the upper end remaining lateral; and *thumb points medially*.

The limb is held usually in an intermediate position, or in the prone position; but in the description of structures in the forearm it is assumed that the limb is in supine position and dependent.

Movement of supination brings forearm and hand from intermediate or prone position into supine position. **Movement of pronation** reverses. Supination is the stronger movement, owing to strength of biceps; and screws and screwing instruments are constructed accordingly. **Axis of movement** passes through centre of head of radius and apex of articular disc. Head of radius rotates within annular ligament. Distal end of radius carries hand with it, and revolves around head of ulna; disc moves with radius, and its ulnar attachment is the centre of movement.

Starting from supine position, the upper limb can be rotated so that palm, originally looking forwards, looks successively medially, backwards and laterally, *i.e.* it moves through 270°. Greater part of that movement is not pronation, but medial rotation at shoulder-joint, assisted by some movement at intercarpal joints. Pronation alone can move hand through about 130°.

The ridge felt above ulnar margin of back of carpus, when arm is supine, is the styloid process of ulna and tendon of extensor carpi ulnaris. The knob seen above ulnar margin of back of carpus, in prone position, is the lateral surface of head of ulna and a small part of anterior surface, while styloid process and tendon may be felt above ulnar aspect of carpus.

Wrist-Joint or **Radio-Carpal Joint.**—Synovial; ellipsoid. Distal surface of radius and triangular articular disc form an elliptical concavity for convex surface formed by the scaphoid, lunatum and triquetrum and their interosseous ligaments.

Union is by a *capsular lig.* strengthened by *anterior* and *posterior radio-carpal ligs.* and *lateral* and *medial ligs. of wrist.*

Capsular lig. is attached close to margins of articular surfaces—the upper attachment being chiefly to radius.

Posterior radio-carpal lig. extends downwards and medially from dorsal margin of distal end of radius to the back of first row of carpus.

Anterior radio-carpal lig., much stronger, extends downwards and medially from the anterior margin of distal end of radius and its styloid process to the first row of carpus and to capitatum.

Medial lig. of wrist extends from styloid process of ulna to triquetrum and pisiforme.

Lateral lig. of wrist extends from radial styloid process to the scaphoid and trapezium.

Blood-Vessels.—Carpal branches of radial and ulnar; interosseous; recurrent branches of deep palmar arch.

Nerves.—Anterior and posterior interosseous, dorsal and deep branches of ulnar.

MOVEMENTS OF RADIO-CARPAL JOINT. — Are supplemented by movements at intercarpal joints. **Flexion,** *produced* by flexor carpi radialis and ulnaris, palmaris longus (and flexors of digits). **Extension** and **dorsiflexion,** by ext. carpi radialis longus and brevis, and ext. carpi ulnaris (and extensors of digits). Extension and dorsiflexion are freer than flexion; this is more than counterbalanced by greater freedom of "flexion" at intercarpal and carpometacarpal joints.

Abduction or **raidal flexion** by extensores radiales, extensors of thumb and flexor carpi radialis. **Adduction** or **ulnar flexion** by flexor and extensor carpi ulnaris. More extensive than abduction.

Circumduction is a consecutive combination of these four.

Movement is checked in each case by ligaments; restrained in some positions by tendons, *e.g.*, when fingers are flexed the stretched extensor tendons do not allow full flexion of wrist. Abduction is less free than adduction owing to styloid of radius meeting carpus.

RELATIONS.—Immediate: *Anterior*: superficial palmar artery, flexor pollicis longus and flexor digit. profundus, with their sheaths, from radial to ulnar side; and recurrent branch from deep palmar arch and terminal branches of anterior interosseous nerve are deep to profundus. *Lateral*: radial artery. *Posterior*: extensors carpi radialis longus and brevis, pollicis longus, digitorum and indicis, digiti minimi, carpi ulnaris, with their sheaths, from radial to ulnar side; termination of anterior interosseous vessels and posterior

interosseous nerve are deep to tendons. *Medial*: dorsal branch of ulnar nerve and posterior ulnar carpal artery.

More remote: *Anterior*: flexor carpi radialis, palmar branch of median nerve, palmaris longus, median nerve, flexor sublimis, ulnar artery, palmar cutaneous branch of ulnar nerve, ulnar nerve, flexor carpi ulnaris. Flexor retinaculum is immediately distal to the level of the joint; anterior carpal arch is immediately proximal. *Lateral*: abductor longus and extensor brevis pollicis and their sheaths, separated from lateral lig. of wrist by radial vessels. *Posterior*: Extensor retinaculum crosses obliquely. Dorsal carpal arterial arch is distal to the joint.

RELATIONS EXAMINED IN MORE DETAIL.—With forearm prone: Find the head (*i.e.* distal end) and styloid process of the ulna, styloid process and dorsal tubercle of radius, and ascertain the line of the joint **on the back of the limb.** Beneath the skin are veins and branches of cutaneous nerves.

At the radial side, above the metacarpal of thumb, feel the tendons of abductor pollicis longus and extensor pollicis brevis. They form the antero-lateral boundary of the hollow on the radial side of the wrist. Under cover of them, the radial artery is lying on lateral lig. of the wrist. In the hollow at the radial side of the wrist, superficial branches of the radial nerve cross the joint; they may be felt farther down as they cross extensor pollicis longus tendon. Radial artery may be felt pulsating in the distal part of the hollow, on the trapezium, beyond the wrist-joint, near the carpo-metacarpal joint of thumb.

Next, at the ulnar side of the hollow, feel the tendons of extensor carpi radialis longus and brevis, and the extensor pollicis longus. Extensor pollicis longus crosses extensor carpi radialis longus and brevis obliquely, lying on brevis opposite the joint. Next, in order, come—extensor digitorum, with extensor indicis deep to its radial edge; extensor digiti minimi; and extensor carpi ulnaris, felt at the ulnar border of this aspect. All these tendons are enclosed in synovial sheaths. Extensor retinaculum lies obliquely across the back of the joint, superficial to the tendons, its distal border being above the joint on the radial side, and below it on the ulnar side. Branches from both interosseous arteries pass deep to the tendons to anastomose with the dorsal carpal arch, which lies on the distal row of the carpus; and the termination of the posterior interosseous nerve crosses the joint under cover of extensor indicis.

With forearm supine: Feel the ridge on the distal end of the radius, and ascertain the line of the joint **on the front**—at a slightly higher level than on the back. Some superficial veins lie beneath the skin.

The tendons seen descending across the middle of the line of the joint are flexor carpi radialis laterally, and palmaris longus medially. Palmaris may be absent.

Feel the tubercle of the scaphoid immediately above the ball of the thumb, in the angle between the ball and flexor carpi radialis; note also the pisiform, which is the knob immediately above the

ball of the little finger. Proximal border of the flexor retinaculum stretches between these bones, a little below the level of the wrist-joint, usually opposite the lowest transverse skin-crease.

Feel the radial artery beating on the distal end of the radius. Before it turns laterally to reach the radial side of the wrist, it sends its superficial palmar branch across the front of the joint to the ball of the thumb.

Flexor pollicis longus tendon crosses the joint directly behind flexor carpi radialis; each has a separate synovial sheath. Flexor profundus, on the ulnar side of pollicis, is in relation to the greater part of the anterior lig. of the joint, and is enveloped in a sheath common to it and sublimis. Median nerve is, at this level, in front of the tendon of profundus for index (or opposite the interval between it and pollicis), on the radial side of sublimis. The nerve is behind the ulnar edge of flexor carpi radialis, and behind the palmaris longus if the two tendons are close together. Palmar cutaneous branch of median nerve is descending superficially between flexor carpi radialis and palmaris.

Superficial to profundus, on the ulnar side of the median nerve, are the four tendons of flexor sublimis—those for the middle finger and ring-finger being in front of the other two. Palmaris overlaps them on the radial side, but on the ulnar side of palmaris the tendon to the ring-finger can be seen or felt moving while the fingers are being flexed.

Ulnar artery and nerve are lying on profundus, close to flexor carpi ulnaris, between it and flexor sublimis, the nerve on the ulnar side of the artery, which may be felt beating if the hand is dorsi-flexed. Palmar cutaneous branch of ulnar nerve passes towards ulnar border of the forearm, above the pisiform. It is separated to the palm on the ulnar artery. Flexor carpi ulnaris is felt at the from the joint by an interval containing areolar tissue and fat, and by the ulnar nerve and flexor profundus, which it overlaps.

Recurrent branch from the deep palmar arch runs upwards across the joint, deep to profundus, to anastomose with the anterior carpal arch, which lies on the distal end of the radius above the joint; and the terminal branches of the anterior interosseous nerve are descending to supply the anterior ligaments of wrist and intercarpal joints.

On the ulnar side of the wrist-joint (which is between flexor and extensor carpi ulnaris), there is a quantity of fat in which the dorsal branch of the ulnar nerve and posterior carpal branch of the ulnar artery run downwards beneath the skin.

Intercarpal Joints.—Synovial; plane—having slight gliding and rotatory movements.

Bones of proximal row are united by dorsal, palmar and interosseous ligaments; bones of distal row united by the same. Proximal row is united to distal row by dorsal, palmar, medial and lateral ligaments.

Pisiforme is united to triquetrum by capsular lig.; to hook of hamatum by piso-hamate lig.; and to base of fifth metacarpal by piso-metacarpal lig.

Carpo-Metacarpal Joints.—Synovial; mostly plane.

Bases of the medial four metacarpals are united to carpus by dorsal, palmar and interosseous ligaments. First metacarpal is united to trapezium by a **capsular lig.**

Intermetacarpal Joints.—Synovial; plane. Bases of media, four metacarpals are united together by dorsal, palmar and interosseous ligaments.

Joints between pisiforme and triquetrum and between trapezium and first metacarpal have each a separate cavity. The other intercarpal, carpo-metacarpal, and intermetacarpal joints have a common cavity and synovial membrane. Joint between hamatum and 4th and 5th metacarpals is separate occasionally.

MOVEMENTS of intercarpal, carpo-metacarpal, and intermetacarpal joints. Slight gliding movements for the most part. At joint between proximal row and distal row of carpus some flexion, extension and rotation are possible; and at carpo-metacarpal joints of thumb and little finger movement is considerable.

At carpo-metacarpal joint of thumb the movements are: **Flexion,** *i.e.* movement of metacarpal forwards in front of plane of palm, *produced* by flexor pollicis longus and brevis and opponens. **Extension,** by extensors of thumb and abductor pollicis longus. **Adduction,** *i.e.* approximation to index finger, by adductor pollicis. **Abduction,** by abductors longus and brevis. **Opposition** is a combination of (1) flexion, (2) medial rotation (produced by opponens) and (3) adduction, whereby the metacarpal and ball of thumb are carried forwards and medially to overhang hollow of palm, and, when the digits are slightly flexed, the thumb can touch the tips of the fingers in succession. **Circumduction** is a combination of all the movements.

At carpo-metacarpal joint of little finger movement is freer than in those of other fingers. Metacarpal can be opposed by the flexor brevis and opponens drawing it forwards and rotating it laterally towards hollow of palm.

Opposition of thumb enables the flexed digits to grasp a cylindrical object; opposition of thumb and little finger, supplementing flexion of digits, enables the hand to grasp a spherical object.

Metacarpo-Phalangeal Joints.—Synovial; condyloid. Head of metacarpal articulates distally with base of proximal phalanx, and anteriorly with the palmar lig.

Union is by a *capsular lig.* greatly strengthened in front by the *palmar lig.*, and at the sides by *collateral ligs.*

Capsular lig. is attached fairly near the margins of the articular surfaces. Posteriorly it is defective, and its place is taken by the expanded extensor tendon.

Collateral ligaments are strong bands attached to sides of head of metacarpal and to sides of base of phalanx.

Palmar lig., a dense fibrous plate, is the palmar part of capsular lig. greatly thickened. At the sides, it fuses with collateral ligs., and is connected with the deep transverse ligs. of palm. Distally, it is firmly attached to base of phalanx. Proximally, it is loosely connected with palmar surface of the metacarpal immediately above the head. It forms part of the socket and therefore articulates with the front of the head. Its palmar surface also is smooth, and is covered by the flexor tendons and their synovial sheaths.

Deep transverse ligaments of palm are three flat bands that lie between heads of medial four metacarpals, and are attached to the edges of palmar ligaments of the metacarpo-phalangeal joints. Lumbrical muscles and digital vessels and nerves lie on their palmar surfaces; interosseous muscles on their dorsal surfaces.

MOVEMENTS.—**Flexion** by flexors, interossei and lumbricals. **Extension** and **dorsiflexion** by extensors. **Abduction** and **adduction,** from and to middle line of middle finger, by interossei. A combination of the four is **circumduction**. Adduction and abduction of thumb occurs at carpo-metacarpal joint, not at metacarpo phalangeal.

Fingers cannot be abducted when they are fully flexed owing to tension of collateral ligs.; and they cannot remain abducted during process of flexion owing to the line of pull of flexor tendons.

Interphalangeal Joints.—Synovial; hinge.

Capsular, collateral and **palmar ligaments,** as in the metacarpo-phalangeal joints.

MOVEMENTS.—**Flexion,** by flexors; **extension,** by extensors, interossei and lumbricals. Full flexion of both wrist and fingers cannot occur at same time, nor can full extension; because opposing muscles do not stretch sufficiently to allow it. Full flexion of fingers —*i.e.* closing the fist —is always accompanied by dorsiflexion of wrist.

SURFACE-MARKING.—Position of metacarpo-phalangeal and interphalangeal joints on **the back** is immediately distal to the knuckles. On **the front** the position of *metacarpo-phalangeal joint* is about half an inch above the level of the free edge of the web; of *first interphalangeal*, opposite proximal crease; of *second*, on distal side of crease.

JOINTS AND LIGAMENTS OF PELVIS

The **fifth lumbar vertebra** and the **sacrum** are united by :—

1. The lowest parts of *anterior* and *posterior longitudinal ligs.*
2. An *intervertebral disc.*
3. A pair of *lumbo-sacral ligs.* (p. 120).
4. A pair of *capsular ligs.* at the articular processes.
5. A pair of *lig. flava.*
6. An *interspinous lig.*
7. The lower part of the *supraspinous lig.*

The **sacrum** and **coccyx** are united by an *intervertebral disc*, and by *anterior, posterior, lateral* and *intercornual ligaments* (p. 120).

The **vertebral column** is united to each **hip-bone** by the *ilio-lumbar lig., sacro-tuberous* and *sacro-spinous ligs.* and the ligaments of *sacro-iliac* joint.

The **hip-bones** are united to each other by the *pubic symphysis.*

Ilio-Lumbar Lig.—A strong band that radiates from 5th lumbar transverse process to inner lip of iliac crest above posterior part of iliac fossa. Hidden behind psoas major and in front of sacro-spinalis. Upper surface is fused with the anterior and middle layers of the lumbar fascia, and gives origin to quadratus lumborum between them.

Sacro-Tuberous Lig.—Stretches across gap between sacrum and hip-bone ; forms postero-lateral boundary of pelvic outlet and of perineum, and postero-medial boundaries of greater and lesser sciatic foramina.

Broad at both ends, narrow in middle.

Attached *superiorly* to the posterior iliac spines, 3rd, 4th, 5th transverse tubercles of the sacrum and to the side of the coccyx ; *inferiorly* to the medial margin and lower medial impression of the ischial tuberosity, and to the ramus of the ischium by a prolongation of its medial part, called the **falciform process,** whose upper margin is continuous with the lower edge of the obturator fascia.

Sacro-Spinous Lig.—Flat and triangular. Attached by its apex to the ischial spine ; by its base to the side of the lowest piece of the sacrum and the first piece of the coccyx. It lies between the sciatic foramina and completes their boundaries.

Relations of Sacro-Tuberous Lig.—*Dorsal surface* covered by gluteus maximus, part of which arises from it ; long tendon of biceps is partly continuous with it (it represents the proximal end of the tendon cut off by out-growth of ischium). Secondary plexus

formed by posterior primary rami of the upper three sacral nerves lies on it, under cover of gluteus maximus. *Pelvic surface* is in relation to piriformis (part of which arises from it), sacro-spinous ligament and obturator internus.

Coccygeal branch of inferior gluteal artery threads its way through it. It is pierced by perforating cutaneous nerve, by fifth sacral and coccygeal nerves and by branches of coccygeal plexus.

Relations of Sacro-Spinous Lig.—Medial part of **dorsal surface** is blended with sacro-tuberous ligament; lateral part is crossed by pudendal nerve. Internal pudendal vessels lie on its apical attachment. *Pelvic surface* is blended with coccygeus, of which it is a degenerated part. Fifth sacral and coccygeal nerves and branches of coccygeal plexus pierce the ligament.

Greater Sciatic Foramen.—**Bounded** by the margin of greater sciatic notch and by the sacro-spinous and sacro-tuberous ligaments.

Transmits: Piriformis, which almost fills it. Superior gluteal vessels and nerve, *above piriformis*. Six nerves and two sets of vessels, *below piriformis*:—Sciatic, most laterally; nerve to quadratus femoris, hidden in front of sciatic; posterior cutaneous, along medial side of sciatic or on the back of it; inferior gluteal, alongside posterior cutaneous; nerve to obturator internus, half an inch medial to sciatic, on the root of ischial spine; pudendal most medially, on sacro-spinous lig.; internal pudendal vessels, on tip of ischial spine, between pudendal nerve and nerve to obturator internus; inferior gluteal vessels accompany inferior gluteal nerve.

Lesser Sciatic Foramen.—**Bounded** by the margin of lesser sciatic notch and by the two ligaments.

Transmits: Tendon of obturator internus, pudendal nerve, nerve to obturator internus, and internal pudendal vessels.

Sacro-Iliac Joint.—Synovial; but very little movement. Auricular surfaces of sacrum and ilium.

Union is by *anterior, interosseous, short posterior* and *long posterior sacro-iliac ligaments*, and occasional bands within the joint. The anterior and interosseous constitute the capsular lig.

Anterior sacro-iliac lig. is thin. It consists of short fibres that connect the convex margins of the auricular surfaces; its upper part therefore connects the ala of sacrum with the hip-bone, and faces the abdominal cavity; the lower part connects the pelvic surface of sacrum with the hip-bone.

Interosseous sacro-iliac lig. is short and very thick, and is exceedingly strong, as it suspends sacrum and superimposed trunk between hip-bones. Attached to rough areas above and behind the auricular surfaces of sacrum and ilium.

Short posterior sacro-iliac lig. lies on the back of the interosseous lig., under cover of sacrospinalis. It consists of strong bands that pass from the hip-bone to the first and second transverse tubercles of sacrum.

Long posterior sacro-iliac lig. is a nearly vertical band that passes from posterior superior iliac spine (which is opposite the centre of the joint) to the third and fourth transverse tubercles of sacrum. Laterally, it is blended with the upper part of the sacro-tuberous lig.; and it is under cover of gluteus maximus.

RELATIONS.—**Posterior surface** is covered by sacrospinalis and gluteus maximus and the upper part of sacro-tuberous lig.

Abdominal or **antero-superior surface** is covered by psoas major and iliacus; is crossed, under cover of psoas, by ilio-lumbar vessels; obturator nerve is separated from the joint by ilio-lumbar vessels; femoral nerve is separated by fibres of iliacus. Common and ext. iliac veins are separated from the joint by fatty areolar tissue which contains obturator nerve and ilio-lumbar vessels; and common iliac and trunk of internal iliac arteries are further separated by these veins.

Pelvic surface is closely related to internal iliac vein, lumbo-sacral trunk, superior gluteal vessels, first sacral nerve, upper part of piriformis, in that order from above downwards. They cross the joint obliquely, downwards and sidewards. Ant. division of int. iliac art. is separated from joint by int. iliac vein, and post. division by lumbo-sacral trunk; but relations of vessels vary.

Pubic Symphysis.—A secondary cartilaginous joint. Symphyseal surfaces are covered with hyaline cartilage, and united by **fibro-cartilaginous disc** (often cleft in the centre). Disc is covered by weak *superior* and *posterior* and strong *anterior* and *inferior* ligaments attached to margins of symphyseal surfaces and to the disc. *Inferior ligament* rounds off the apex of pubic arch and extends on to inferior pubic rami. *Anterior lig.* is reinforced by interlacing fibres of rectus abdominis and external oblique.

MOVEMENTS and **MECHANISM** of **PELVIC JOINTS.**—Sacro-iliac joint, though synovial, is immovable except a slight rotation. There is a slight yielding at pubic symphysis. During later period of pregnancy ligaments become relaxed, so that sacrum can be driven backwards, and interval between pubic bones widened, to provide more room during parturition.

The tendency of the weight of the trunk to drive sacrum downwards is obviated by strength of interosseous and posterior sacro-iliac ligaments, and by the interlocking of irregularities of auricular surfaces. Weight of trunk falling on anterior part of sacrum tends to drive the base of sacrum downwards and tilt the apex upwards. This is prevented by the sacro-tuberous and sacro-spinous ligaments. Tendency for sides of bony ring of pelvis to give way under the strain is provided against by support received from femora.

Lumbo-sacral joint is very oblique, and the tendency for the last lumbar vertebra to slip into the pelvis under the weight of the body is checked by the strength of intervertebral disc and ilio-lumbar ligaments, and by locking of articular processes.

Sacro-iliac joints, by slight yielding, diminish shocks transmitted to vertebral column, through pelvis, from lower limbs.

JOINTS OF LOWER LIMB

Hip-Joint.—Synovial; ball-and-socket. Head of femur articulates with acetabulum. The rim of acetabulum is completed by a *transverse ligament*, and the cup is slightly deepened by the *acetabular labrum*.

Union is by a *capsular ligament*, reinforced by *ilio-femoral, pubo-femoral* and *ischio-femoral ligaments*, and supplemented by the *ligament of head of femur*.

Transverse ligament of acetabulum bridges across the acetabular notch, which it converts into a foramen for the passage of vessels and nerves into the joint.

Labrum acetabulare is a fibro-cartilaginous ring, triangular on section, attached to rim of acetabulum and transverse lig. The labrum surrounds the head of the femur distal to its maximum diameter ; its surfaces slope so that it narrows the mouth of the acetabulum, and grips the head of the femur more securely.

Capsular ligament is very strong, especially in front

Its *acetabular attachment* is to the bony rim above and behind, to labrum and transverse ligament in front and below. The *femoral attachment* is to the trochanteric line, to upper and lower surfaces of the neck near the trochanters, and to the back of the neck half an inch from trochanteric crest.

Fibres are both longitudinal and circular. Circular fibres form a collar called *zona orbicularis*. They are the deeper fibres, except at the back, where they are more numerous and appear at the surface near the femoral

attachment. Longitudinal fibres are stronger and more numerous. They are most numerous at the surface, where they are massed to form the named ligaments—especially in front. At the femoral attachment some of the deeper fibres are reflected upwards over the surface of the neck as far as the head, forming bundles, called *retinacula*, which are strong enough sometimes to prevent displacement when the neck of femur is broken. They are better marked in young people—before the epiphysis of the head fuses.

Ilio-femoral ligament is the mass of longitudinal fibres in the front of the capsule. It is the strongest ligament in the body—having to sustain the continuous strain put upon it by the trunk when the body is erect. It is triangular in outline. Attached by its apex to lower part of anterior inferior iliac spine; by its base to the trochanteric line. Its middle is usually thinner than its sides, and it may therefore resemble an inverted V or Y.

Pubo-femoral and *ischio-femoral ligaments* are merely the sheets of superficial longitudinal fibres passing obliquely from the pubic and ischial parts of the acetabular rim towards the femoral attachment, and blending with the circular fibres.

Ligament of head of femur.—Flattened and triangular. Lies within joint, surrounded by a tube of synovial membrane. Attached by its apex to pit on head of femur, by bifid base to transverse ligament and margins of acetabular notch. Function doubtful. May be absent.

Synovial membrane lines capsular ligament, covers both surfaces of the labrum, is prolonged over the fat in acetabular fossa, and over ligament of head of femur, enclosing it in tubular sheath. From the femoral attachment of capsule, it is reflected over the neck up to articular margin of head, enclosing neck in a tube; and the retinacula raise it into folds. The folds contain blood-vessels running to the head; therefore if retinacula and folds are torn in fracture, the blood-supply of upper fragment is diminished. Sometimes the membrane communicates with bursa under psoas major through an aperture between ilio-femoral and pubo-femoral bands.

Blood-Vessels from superior and inferior gluteal, medial and lateral circumflex, and obturator. **Nerves** from femoral, obturator and nerve to quadratus femoris.

RELATIONS.—(1) **Immediate:** *Posterior*: Piriformis in the upper part, and lying more on the upper surface near insertion. Obturator internus and gemelli lower down; upper edge of quadratus femoris overlaps it medially, but is below the level of the joint laterally; nerve and vessels to quadratus femoris descend vertically between obturator internus and gemelli and the bone, and then between quadratus and the capsule.

Superior: Gluteus minimus lies on the upper surface.

Anterior: Lateral edge of pectineus overlaps the capsule medially. More laterally there is psoas major tendon, with iliacus gaining partial insertion to its lateral edge; psoas is separated from the capsule by a bursa, but some fibres of iliacus are attached to the capsule. Rectus femoris is lateral to iliacus; its straight head covers the proximal attachment of the ilio-femoral lig.; its reflected head is imbedded in the capsule above acetabulum, under cover of gluteus minimus. Distal lateral part of the ilio-femoral lig., in the angle between rectus femoris and gluteus minimus, is concealed by tensor fasciæ latæ, but is separated from it by fatty areolar tissue which contains the ascending branches of the lateral circumflex vessels, and through this tissue the deep lamina of the ilio-tibial tract reaches the capsule to fuse with it.

Inferior: Obturator ext. lies against the lower surface and turns upwards to insertion, in relation partly to the capsule and partly to the back of the neck of the femur beyond the attachment of the capsule. Medial circumflex vessels, as they pass backwards between psoas and pectineus, are below the joint, and their ascending branches accompany the tendon of obturator externus. Insertion of psoas and iliacus is below the femoral attachment of the lower part of the capsule.

(2) **More Remote:** *Superior*: Gluteus medius covers minimus; branches of superior gluteal vessels and nerve are between them.

Posterior: Sciatic, posterior cutaneous, inferior gluteal nerve and inf. gluteal vessels are separated from the joint by obturator internus and gemelli, but the nerve to obt. internus, and pudendal vessels and nerve, in relation to the ischial spine, are an inch and a half medial to the joint. Gluteus maximus covers all these, and covers quadratus femoris as well.

Anterior: Upper part of tensor fasciæ latæ is separated by rectus and anterior part of gluteus minimus. Sartorius is separated from the joint by rectus femoris, which it crosses, and by iliacus, which it overlaps. Femoral nerve, lying between iliacus and psoas, is separated by fibres of iliacus. Femoral art. and the femoral branch of genito-femoral nerve are separated by psoas. Femoral vein lies partly on pectineus and partly on psoas, and their contiguous margins separate the vein from the joint.

Inferior: Obturator nerve, emerging from the pelvis, is about half an inch medial to the lower part of the joint.

MOVEMENTS OF HIP-JOINT.—Every possible movement, but less extensive in range than in shoulder-joint, as articular cavity is much deeper and ligaments are stronger and not so lax.

Flexion, *produced* by ilio-psoas, rectus femoris, sartorius, pectineus, obturator externus, adductor longus and brevis, and pubic part of adductor magnus, anterior parts of gluteus medius and minimus; *checked* by contact of thigh and abdomen when knee is bent, by tension of hamstrings when knee is extended.

Extension, *produced* by gluteus maximus, hamstrings, ischial part of adductor magnus, and by gravity; *checked* by ilio-femoral lig.

Extension is complete when limb is in straight line with trunk. In erect posture a line dropped from centre of gravity falls behind line drawn between centres of hip-joints. Trunk tends, therefore, to roll backwards, and is prevented by tension of ilio-femoral lig.

Abduction, *produced* by gluteus minimus, medius, upper part of maximus, tensor fasciæ latæ, and sartorius, and, when limb is flexed, by piriformis and obturator internus; *checked* by pubo-femoral and medial part of ilio-femoral ligament.

Adduction, by adductors, pectineus, gracilis, quadratus femoris, lower part of gluteus maximus; *checked* by contact with other limb, but, if thigh is flexed, by lateral part of ilio-femoral ligament.

Circumduction is a combination of above movements.

Lateral rotation, much stronger than medial rotation, *produced* by gluteus maximus, posterior parts of medius and minimus, both obturators and gemelli, piriformis, quadratus femoris, sartorius, pectineus, adductors longus, brevis, magnus, and, when thigh is flexed, by psoas; *checked* by ilio-femoral lig., especially lateral part.

Medial rotation, by ant. parts of gluteus minimus and medius, tensor fasciæ latæ, and, during process of flexion, by ilio-psoas; *checked* by ischio-femoral lig. and tension of opposing muscles.

Knee-Joint.—Synovial; chiefly a hinge-joint, but rotation also occurs. Condyles of femur articulate with condyles of tibia and with patella. The femoral and tibial condyles are partly separated by the *semilunar cartilages*, which are attached to the tibia.

The bones are united by:—(1) An imperfect *capsular lig.* reinforced by fascia lata and expansions from tendons, including the *oblique posterior lig.* from semimembranosus.

(2) *Lig. patellæ* and *lateral* and *medial ligaments*, on the exterior of the joint.

(3) *Cruciate ligaments*, in the interior.

Capsular lig. is deficient anteriorly, being replaced by quadriceps femoris, patella and lig. patellæ.

Its *femoral attachment* is (1) to the sides of the condyles, a quarter of an inch or more above the articular margin,

(2) to the backs of the condyles immediately above the articular margin, and (3) to the intercondylar line.

The *tibial attachment* is (1) to the lower margin of the notch between the condyles, (2) to the backs and sides of the condyles a quarter of an inch or less below the articular margin, and (3) to the fronts, along lines that begin near the articular margins of the sides and run down to the sides of the tubercle.

At the back of the lateral tibial condyle, the capsular ligament is pierced by the tendon of popliteus.

Lig. Patellæ.—The middle and chief part of tendon of insertion of quadriceps femoris. Separated from skin by bursa. About two inches long and one inch broad.

Attached proximally to apex and rough, distal part of the back of patella; distally to smooth, upper part of tubercle of tibia and slightly to rough, lower part.

A mass of fat, called *infrapatellar pad*, separates its deep surface from front of tibia above the tubercle and from the synovial membrane above that. A bursa also separates it from upper part of tibia. That bursa is crescentric, and, when enlarged with inflammation, its horns extend upwards along the sides of lig. patellæ.

Oblique posterior ligament is a broad slip that springs from the tendon of semimembranosus at the back of the medial condyle of tibia; it radiates upwards and laterally towards the back of the lateral femoral condyle, blending with the capsule.

Medial Ligament.—Originally the distal part of tendon of adductor magnus. Strong and flat. Four inches long, half an inch broad. Attached to medial epicondyle immediately below adductor tubercle; to medial surface of tibia for an inch and a half close to medial margin, beginning two inches below upper end of tibia. Fused with capsule, and adherent to medial semilunar cartilage.

Lateral Ligament.—Probably a femoral attachment of peroneus longus originally. A strong, round cord, two inches long. Attached, by its upper end, to the lateral epicondyle above the popliteal groove; by the lower end, to the head of fibula in front of its styloid process. Separated from the capsule by areolar tissue and the inferior lateral genicular nerve and vessels.

Cruciate ligaments cross like the limbs of the letter X. Covered in front and at sides with synovial membrane;

related posteriorly to the capsular ligament, from which they are separated by fat.

Anterior cruciate ligament. Tense in extension. Extends upwards, backwards and sidewards from the anterior part of intercondylar area of tibia to the posterior part of medial surface of lateral condyle of femur.

Posterior cruciate ligament. Tense in flexion. Passes upwards, forwards and medially from the posterior part of intercondylar area to the anterior part of lateral surface of medial condyle of femur.

Semilunar cartilages. — Two curved fibro-cartilages which rest on the peripheral parts of the condyles of tibia.

Lower surfaces are flat; upper surfaces are concave for condyles of femur; both surfaces are originally covered with synovial membrane, which, however, becomes so thin under pressure that it is not recognisable in the adult.

Peripheral margins, thick, convex, attached to capsule; the opposite margins are thin, concave and free. Ends or horns are fibrous, and are attached to tibia.

Medial cartilage.—Nearly semicircular. Wider behind than in front. Attached by *anterior horn* to anterior part of intercondylar area in front of anterior cruciate ligament; by *posterior horn* to posterior part of intercondylar area in front of posterior cruciate ligament.

Its periphery is adherent to the capsule, and therefore to the medial lig. of the knee, which is fused with capsule.

Lateral cartilage.—Nearly circular. Horns attached close together: *anterior horn* to the front of intercondylar eminence behind anterior cruciate ligament and blended with it; *posterior horn* to back of eminence in front of the posterior end of medial cartilage.

Peripheral margin is adherent to the capsular lig., but to a less extent than the medial cartilage is; for popliteus tendon and its bursal sheath separate part of the margin from the capsule.

Attached to tibial intercondylar space, from before backwards, are: (1) anterior end of medial cartilage, (2) anterior cruciate lig., (3) anterior end of lateral cartilage, (4) posterior end of lateral cartilage, (5) posterior end of medial cartilage, (6) posterior cruciate lig.

A slip from posterior border of posterior horn of lateral semilunar cartilage joins posterior cruciate lig., and is attached with it to the medial femoral condyle.

Transverse lig. of knee is a bundle of variable size that connects the anterior margins of the two semilunar cartilages.

The **arcuate lig. of knee** and its *retinaculum* are unimportant. They are variable thickenings in the posterior part of the capsular lig., and are connected with the styloid process of the fibula.

Aponeurotic reinforcements of capsule are :—

(1) **Oblique posterior ligament** (p. 149) blends with the back of the capsular lig., forming, with it, the *posterior lig.* of knee-joint.

(2) Slips of semimembranosus and sartorius to the medial side.

(3) Expansions named the **lateral** and **medial retinacula of patella** spread downwards and backwards from the lower ends of the vasti towards the fronts of tibial condyles and the sides of the femoral condyles.

At the front and sides, these tendinous expansions are covered and fused with fascia lata, which also therefore strengthens the capsule—the ilio-tibial tract contributing specially by a band, called the *fascial patellar retinaculum*, that curves forwards from its lower end to be attached to the patella.

Synovial Membrane.—Lines capsular lig. At the femoral and tibial attachments, it is reflected on to the bone and covers intracapsular part of bone as far as the articular margins, which it overlaps.

At the sides, it is reflected also on to semilunar cartilages, but, in the adult, it begins to thin out and soon disappears.

At the back, in the middle, it is separated from the capsular ligament by the cruciate ligaments. They bulge it forwards into the cavity. It therefore covers their sides and front, but leaves the posterior one in relation to the capsular ligament.

At the front, it is absent from patella. Above patella, it lines the deep surface of quadriceps ; and, at a variable level, it is reflected on to the fat that covers the front of the femur, and it extends down over the fat to overlap the upper edge of patellar surface. Below patella, it covers the deep surface of infrapatellar pad of fat, which separates it from lig. patellæ. From the surface of the pad, it is pinched up to form a wide-based, triangular fold, called *infrapatellar synovial fold*, whose apex is prolonged to be attached to the anterior margin of intercondylar notch, and whose margins are called the *alar folds*.

COMMUNICATIONS.—The cavity communicates by a wide aperture with a large bursa—**suprapatellar bursa**—which lies under cover of quadriceps, and is, in effect, an extension of the synovial membrane ; the cavity may be said therefore to extend almost a hand's breadth above the level of patella. It often communicates,

through holes in the back of the capsule, with the bursæ under the heads of gastrocnemius and the bursa of semimembranosus.

A tube-like pouch of synovial membrane lies along the medial side of the intracapsular part of popliteus and overlaps its edges; the pouch is carried out with the tendon and separates it from the back of the tibial condyle and the back of the tibio-fibular joint, with which it sometimes communicates.

Blood-Supply.—Genicular branches of popliteal; genicular branch of femoral; descending branch of lateral circumflex; recurrent branches of anterior tibial.

Nerves.—Branches of femoral to the three vasti; three branches from medial popliteal and two from lateral popliteal accompany the five popliteal genicular arteries; recurrent branch of lateral popliteal; genicular branch of obturator.

RELATIONS.—Posterior: Popliteal vessels lie on the middle of the posterior ligament and separate the medial popliteal nerve from it; middle genicular vessels and nerve perforate it.

Towards the lateral side, plantaris partly arises from the posterior part of the capsule, and the lateral head of gastrocnemius is partly adherent to the capsule and partly separated by a bursa; lateral popliteal nerve lies between the lateral head and biceps.

Towards the medial side, the medial head of gastrocnemius is separated from the posterior part of the capsule by a bursa; the bursa is prolonged into the interval between the medial head and the semimembranosus tendon where that tendon lies on the capsule medial to gastrocnemius, and the bursa may communicate with the joint through an aperture. Semitendinosus lies on semimembranosus before turning to its insertion into the medial side of the tibia; and gracilis lies on the postero-medial part of the capsule, at the medial side of semitendinosus. Popliteus pierces the posterior part of the capsule below the lateral femoral condyle.

Medial.—Sartorius descends across the posterior part of the medial side of the joint and turns forwards to its insertion. Saphenous nerve and artery descend behind the sartorius, between it and gracilis. Long saphenous vein ascends on the surface of sartorius. In front of sartorius, the joint is subcutaneous.

Gracilis and semitendinosus, inclining forwards to their insertions, lie on the medial lig. below the level of the joint. All three tendons are separated from that ligament by a bursa. The medial lig. (below the level of the joint), covers (1) part of semimembranosus as it lies with its bursa in the groove on the medial tibial condyle; and below that, (2) the medial inferior genicular vessels and nerve.

Lateral.—Biceps, placed far back, covers the lateral lig. of the knee, a bursa intervening, and is split by the lig. longitudinally.

In front of them, the joint is subcutaneous. Under cover of the ligament are: (1) the lateral inferior genicular vessels and nerve; (2) tendon of popliteus, which is partly enclosed in a tube of synovial membrane, and separates the lig. from lateral semilunar cartilage.

Anterior.—Bursæ, small vessels, patellar plexus of nerves.

BURSÆ AROUND KNEE-JOINT.—1. Between the lateral head of gastrocnemius and the capsule of the joint.

2. Under cover of the medial head of gastrocnemius, and between it and semimembranosus.

3. Under cover of and between sartorius, gracilis and semitendinosus, separating them from the medial ligament.

4. Around the tendon of semimembranosus as it lies between the tibia and the medial ligament.

5. Between the tendon of biceps and the lateral ligament.

6. Partly ensheathing the tendon of popliteus.

7. *Patellar bursæ*: (*a*) Between the skin and the distal part of patella. (*b*) Between the skin and lig. patellæ. (*c*) Between the deep fascia and the insertion of quadriceps into the upper border of patella. (*d*) Between the periosteum of patella and some fibres of quadriceps which pass superficial to the patella to join the lig. patellæ. (*e*) Between quadriceps and femur, a little above the level of the joint. (*f*) Between lig. patellæ and tibia.

MOVEMENTS.—Flexion, *produced* by biceps, semitendinosus, semimembranosus, popliteus, gastrocnemius, plantaris, sartorius and gracilis; *checked* by contact of leg and thigh, and partly by tension of lig. patellæ and posterior cruciate lig. Flexion is initiated and accompanied by medial rotation of tibia on femur (or lateral rotation of femur on tibia). The initial rotation is effected by popliteus, which is assisted afterwards by semitendinosus, semimembranosus, sartorius and gracilis. **Extension,** accompanied by and terminating in lateral rotation of tibia on femur, is *produced* by quadriceps extensor; *checked* by tension of posterior part of capsule, of lateral and medial ligaments and of anterior cruciate ligament.

Rotation, apart from that associated with flexion and extension, is most free when knee is flexed at right angles: **Medial rotation,** *produced* by popliteus, semitendinosus, and slightly by semimembranosus, gracilis, sartorius; *checked* by ant. cruciate ligament. **Lateral rotation,** *produced* by biceps, *checked* by the medial lig.

In flexion and extension the femur moves on the tibia and the semilunar cartilages; in rotation the movement is on that plane, and also between the tibia and the cartilages.

Extended position is maintained, in erect posture, by gravity, as a line dropped from centre of gravity of body falls in front of the knees; over-extension is prevented by the lateral, medial, cruciate and posterior ligaments, and also by the tension of the hamstrings. It has been argued that this line falls behind the knees, as well as behind the axis of hip-joints, but that the extended position is

nevertheless maintained, because the knee cannot be flexed without previous or concomitant flexion of hip, which is kept extended by gravity (*see* Hip-joint) ; and as long as the ilio-femoral lig. is tense the lateral rotation of the femur at the knee, which must precede flexion, cannot occur.

The patella is movable when the limb is in the extended position. It is said that while the limb is extended the distal pair of facets on the patella is in contact with the patellar surface of the femur. As flexion proceeds the middle and proximal pairs, successively, are in contact ; and, finally, at full flexion the patellar surface is covered only by quadriceps, and may be felt through it. (The last statement is easily verified.) It is said, further, that the medial vertical facet of patella is always in contact, and at full flexion articulates with a semilunar area on medial condyle at the side and front of the intercondylar notch, while the lateral proximal facet is still slightly in contact with the lateral part of the patellar surface ; and that three facets, therefore, are always in contact, except in extreme flexion.

TIBIO-FIBULAR JOINTS.—Head of fibula is united to lateral condyle of tibia by a synovial joint at which slight gliding movement occurs. Shafts are united by the interosseous membrane. Lateral malleolus is united to distal end of tibia by a strong fibrous joint.

Superior Tibio-Fibular Joint.—Head of fibula articulates with postero-inferior surface of lateral condyle of tibia. The bones are united by a *capsular ligament.*

Capsular ligament is attached near the articular margins. It is strengthened anteriorly and posteriorly by fibres that run downwards and sidewards from tibial condyle to head of fibula. It is related *anteriorly* to fascia and the origins of extensor digitorum longus and peroneus longus ; *posteriorly* to popliteus and its bursa ; *superiorly* to fat under cover of biceps and the lateral lig. of knee. Joint-cavity may communicate, through a hole in the upper part of capsule, with the popliteus bursa, and, through that, with knee.

It is supplied by twigs from the nerve to popliteus and from the recurrent branch of the lateral popliteal nerve.

Interosseous Membrane.—Attached to interosseous borders of tibia and fibula. Connected proximally with capsule of tibio-fibular joint, distally with interosseous tibio-fibular ligament. Wider above than below. Fibres are directed chiefly downwards and sidewards.

It is perforated near upper end by anterior tibial vessels, and near lower end by perforating branches of peroneal vessels. Tibialis posterior and flexor hallucis longus arise from its *posterior surface.* Tibialis anterior, ext. hallucis longus, ext. digitorum longus and

peroneus tertius arise from *anterior surface*; and anterior tibial vessels and nerve lie on it.

Inferior Tibio-Fibular Joint.—The lateral malleolus is bound to the tibia by *interosseous lig.*, *transverse tibio-fibular lig.* and *anterior inferior* and *posterior inferior tibio-fibular ligaments*. The union is very strong, for the stability of the ankle-joint depends on its integrity.

Interosseous Ligament.—Short, thick and very strong. Attached to the floor of the fibular notch of tibia and to the rough triangle above the articular surface of lateral malleolus.

Anterior inferior and **posterior inferior tibio-fibular ligaments** are strong, flat bands that pass downwards and sidewards from the distal end of the tibia to the front and back of the uppermost part of the lateral malleolus, and they conceal the interosseous ligament. Tendon of peroneus tertius crosses the anterior lig. Flexor hallucis longus and peroneus brevis overlap the posterior lig., and the peroneal artery crosses it.

Transverse tibio-fibular ligament is attached along whole length of posterior border of tarsal surface of tibia and to the floor of malleolar fossa of fibula. Superiorly, it is continuous with the posterior inferior lig. Its deep surface is in contact with a facet on the talus between the posterior parts of its upper and lateral surfaces.

Nerve-Supply.—Anterior tibial, and a long filament that descends through the interosseous membrane from the nerve to popliteus.

Ankle-Joint.—Synovial; hinge.

Malleoli and tarsal surface of tibia articulate with talus, the malleoli gripping the talus between them.

Union is by a *capsular ligament* attached near the margins of the articular surfaces, and divided into *anterior*, *posterior*, *lateral* and *medial ligaments*.

The medial lig. is greatly thickened and is specially named the *deltoid lig.*; the lateral is supplemented by the *calcaneo-fibular lig.* and two *talo-fibular ligs.*

Anterior ligament, thin and broad, is attached to the anterior border of the distal end of tibia and to the upper surface of the anterior part of the neck of talus.

Posterior ligament, thin and sometimes defective, is attached proximally to the posterior border of the distal end of tibia and to the transverse tibio-fibular ligament; distally to talus behind its superior articular surface.

Deltoid ligament, on medial side, very strong. Narrow proximally and attached to medial malleolus; broad distally and attached, from before backwards, to tuberosity of navicular, spring ligament, neck of talus, sustentaculum tali, body of talus.

Lateral ligament consists of loose fibres that pass from the margins of the facet on malleolus to the margins of the facet on the lateral surface of talus. It is fused with the talo-fibular ligs., but not with the calcaneo-fibular lig., which is separated by fatty areolar tissue.

Anterior talo-fibular lig., short and flat, extends forwards and medially from the anterior border of the lateral malleolus to the lateral side of the neck of talus.

Calcaneo-fibular lig., long and round, extends from the tip of the lateral malleolus downwards and backwards to the lateral surface of calcaneum about its middle.

Posterior talo-fibular lig. is a strong band that extends horizontally, in a medial direction, from the floor of malleolar fossa of fibula to the posterior tubercle of talus.

Synovial membrane lines capsular lig. The cavity often extends upwards for a short distance between tibia and fibula ; it is closed superiorly by the interosseous lig.

Blood-supply from ant. and post. tibial and peroneal.

Nerves from anterior and posterior tibial.

RELATIONS.—Anterior : From medial to lateral side : tibialis anterior, extensor hallucis longus, anterior tibial vessels becoming dorsales pedis, ant. tibial nerve, extensor digitorum longus and peroneus tertius ; perforating branch of peroneal vessels on lateral malleolus. Medial end of upper band of inferior extensor retinaculum lies obliquely across the joint. More superficially there are :— branches of the musculo-cutaneous nerve ; superficial vessels ; and long saphenous vein and saphenous nerve on medial malleolus.

Medial.—Tibialis posterior lies on the deltoid ligament above the sustentaculum tali, and flexor digitorum longus on the attachment of that ligament to sustentaculum. Flexor retinaculum overlies the tendons.

Posterior.—Tendo calcaneus is separated from the posterior lig. by a wide interval filled with areolar tissue, fat and small vessels. On the medial side of tendo calcaneus, and close to the joint, there are flexor hallucis longus, posterior tibial nerve and vessels, and flexor digitorum longus as it slips off tibialis posterior—named in that order latero-medially. Vessels and nerves are on a slightly more superficial plane than the two flexors, and overlap them ; and all are strapped down by the flexor retinaculum. Tendons of peroneus longus and brevis are on same plane as these, but are lateral to tendo calcaneus and on the posterior surface of the lateral malleolus ; peroneal vessels descend along the medial side of brevis.

Lateral.—As the peroneal tendons pass from the malleolus, the brevis lies on the posterior talo-fibular lig. and separates longus from

it. The tendons are held down by a retinaculum of deep fascia, and have a common synovial sheath. As they turn forwards below the malleolus, they lie on the calcaneo-fibular lig. (brevis above longus), and the common sheath divides to enclose them separately. Peroneus tertius crosses the anterior talo-fibular lig. Termination of peroneal art. anastomoses with its perforating branch on this side of joint. More superficially are the short saphenous vein and the sural nerve.

MOVEMENTS.—Flexion, or dorsiflexion, *produced* by tibialis anterior, peroneus tertius, long extensors; *checked* by posterior talo-fibular, calcaneo-fibular, and posterior part of deltoid ligament, and by locking of bones. **Extension,** or plantar flexion, *i.e.* pointing the toes, *produced* by gastrocnemius, soleus, plantaris, tibialis posterior, peroneus longus and brevis, and long flexors; *checked* by ant. ligament, ant. part of deltoid lig., and ant. talo-fibular lig.

JOINTS OF THE FOOT

Talo-Calcanean Joint.—Gliding and slight rotation.

Talus is united to calcaneum by: (1) a strong *interosseous lig.*; (2) *capsular lig.* of the synovial joint between the facet on the body of talus and the large facet on the upper surface of calcaneum; (3) indirectly by the deltoid and calcaneo-fibular ligs.

Interosseous Lig.—Wide, thick, very strong. Chief bond between the bones. Attached to the floors of the deep grooves on the contiguous surfaces of the bones, and therefore occupies sinus tarsi, and lies between the capsules of talo-calcanean and talo-calcaneo-navicular joints, with both of which it may be fused.

Talo-Calcaneo-Navicular Joint.—Synovial. Gliding and rotation. Head and lower surface of neck of talus are received into a socket formed of (1) navicular bone, (2) spring ligament, (3) calcaneo-navicular part of bifurcated lig., (4) sustentaculum tali and anterior part of upper surface of calcaneum.

Ligaments connected with it are: the *spring* or *plantar calcaneo-navicular*; *dorsal talo-navicular*; calcaneo-navicular part of *bifurcated lig.*; and a thin membrane which completes the capsule posteriorly, and is attached above to the posterior edge of the smaller facet on the lower surface of talus and to the calcaneum below.

Plantar Calcaneo-Navicular Ligament or "Spring" Lig.—Broad and thick. One of the most important in the foot. Attached to the anterior margin of sustentaculum tali and to the plantar surface of navicular.

Head of talus rests on it. Deltoid ligament is attached to its medial edge. Tibialis posterior tendon, with its bursal sheath, covers and supports the greater part of its plantar surface, while flexor hallucis longus tendon is separated from the lateral part of its plantar surface

only by loose areolar tissue, and is crossed there by the tendon of flexor digitorum longus.

Dorsal talo-navicular lig., broad and thin, is attached to the dorsal surfaces of navicular and of the neck of talus. It is covered by tendons of tibialis anterior and long extensors, dorsalis pedis artery, and anterior tibial nerve.

Bifurcated lig.—V- or Y-shaped. Attached by stem to dorsal surface of calcaneum immediately lateral to anterior facet for talus; by medial limb (*calcaneo-navicular part*) to lateral surface of navicular; by lateral limb (*calcaneo-cuboid part*) to medial surface of cuboid.

Calcaneo-Cuboid Joint.—Synovial. Gliding and slight rotation. Ant. surface of calcaneum with post. surface of cuboid.

Articular capsule is strengthened by:—

1. *Calcaneo-cuboid part* of **bifurcated lig.** (*see above*).
2. **Dorsal calcaneo-cuboid ligament,** broad and thin, unites dorsal and lateral surfaces of calcaneum to dorsal surface of cuboid; tendons of peroneus tertius and brevis lie on it.
3. **Short plantar lig.,** broad and thick. Attached to ant. part of plantar surface of calcaneum, and to plantar surface of cuboid behind the ridge. Long plantar lig. covers all but its medial edge.

Long plantar ligament is accessory to calcaneo-cuboid joint, and is of importance in maintaining arch of foot. Attached *posteriorly* to plantar surface of calcaneum over an area about an inch square in front of the lateral and medial tubercles; *anteriorly* to the margins of the groove on cuboid, and by slips to the bases of 2nd, 3rd and 4th metatarsals. It converts the groove on the cuboid into a canal for the tendon of peroneus longus, which it provides with a fibrous sheath. It covers other plantar ligs., and is covered by flexor accessorius, adductor hallucis, flexor digiti minimi brevis, which all arise from it.

Transverse tarsal joint is a term that includes the talo-navicular and calcaneo-cuboid joints. These joints do not communicate with each other; but they lie in almost the same coronal plane, indicated by a line drawn from a point immediately behind the tuberosity of navicular to a point half an inch behind the base of the fifth metatarsal. Inversion and eversion of the foot take place chiefly at this transverse tarsal joint.

Dorsal and plantar ligs. unite navicular to the three cuneiforms. **Dorsal, plantar** and **interosseous ligs.** unite cuboid to navicular and to lateral cuneiform, and the three cuneiform bones to each other.

Tarso-Metatarsal Joints.—The first metatarsal is united to the medial cuneiform by an **articular capsule.** Other metatarsals

are united to the cuneiforms and the cuboid by **dorsal, plantar** and **interosseous ligaments.**

Second metatarsal articulates with the intermediate cuneiform, and, by the sides of its base, with the medial and lateral cuneiforms.

Third metatarsal articulates with the lateral cuneiform.

Fourth and fifth with the cuboid; fourth, by the medial side of its base, with the lateral cuneiform also.

First, third, fourth, fifth tarso-metatarsal joints lie in or near a line drawn between bases of the first and fifth metatarsals; but the second joint is half an inch behind the level of the first.

Intermetatarsal Joints.—Base of first is separate. Bases of the other four articulate with each other by their sides, and are connected by **dorsal, plantar** and **interosseous ligaments.**

SYNOVIAL MEMBRANES.—There are five, and sometimes six, separate synovial cavities in tarsal and tarso-metatarsal joints.

(1) Talo-calcanean. (2) Talo-calcaneo-navicular. (3) Calcaneo-cuboid. (4) First tarso-metatarsal. (5) The other joints have a common membrane, but (6) cubo-metatarsal joint may be separate.

MOVEMENTS.—Gliding movements take place between all tarsal bones, but the most important movements are:—

1. **Inversion,** *i.e.* raising the medial border of the foot so that the sole looks towards the opposite side: *produced* mainly by tibialis anterior and posterior aided by the flexors of the toes.

2. **Eversion,** *i.e.* raising the lateral border of the foot: *produced* mainly by peroneus longus, brevis and tertius, aided by extensor digitorum longus.

The movements take place chiefly at talo-calcanean and transverse tarsal joints. Movements at other joints are very limited.

Metatarso-Phalangeal Joints and **Joints of the Digits.**—Comparable to the corresponding joints of the upper limb, except that (1) *deep transverse ligaments of foot* connect all five digits, instead of only four as in the hand; and (2) toes are abducted and adducted from and to the middle line of the second digit, instead of the third as in the hand.

ARCHES OF THE FOOT

In order that the weight of the body may be better distributed, the foot is raised up into the form of a half dome with longitudinal and transverse arches.

Longitudinal Arch.—Keystone is the talus, which receives the weight of the body.

Posterior pillar is the calcaneum.

Anterior pillar is divided into (*a*) navicular, three

cuneiforms and first three metatarsals medially, and (*b*) cuboid and last two metatarsals laterally.

Transverse arch, or series of arches, comprises all these bones.

Maintenance.—The arches are maintained by :—

1. The muscles and tendons around the foot, especially tibialis posterior and peroneus longus. *This is the chief support of the arches.* The tendon of peroneus longus runs forwards and medially from the lateral to the medial side of the foot ; the tendons of tibialis posterior spread from the medial border forwards and laterally. They therefore brace up both the longitudinal arch and the transverse arch.
2. The form of the bones.
3. All ligaments, especially the spring ligament and the short and long plantar ligaments.
4. Fasciæ, especially plantar aponeurosis.

Functions. — The functions of the arches of the foot are :—

1. To distribute the weight of the body.
2. To give spring and elasticity to the step.
3. To break shocks in running and jumping.
4. To provide a space where the soft parts of the sole may lie free from undue pressure.

MUSCLES AND FASCIÆ

SUPERFICIAL FASCIA is a continuous sheet of areolar tissue that underlies the skin over the whole body and contains fat. Cutaneous vessels and nerves traverse it on their way to and from the skin. Fat is absent from it in (*a*) eyelids, (*g*) penis, (*c*) scrotum, (*d*) labia minora, and (*e*) nipples and areolæ of the breasts. It is very firm and dense on the soles, palms and scalp. Its deeper part is fibrous; and in perineum, lower part of abdomen, and upper part of front of thigh the fibrous and fatty parts are in distinct layers.

DEEP FASCIA is a dense, strong, fibrous, bluish membrane, under superficial fascia. Covers muscles. Attached to subcutaneous bony points and to ligaments of joints. Thickened at some joints, *e.g.*, wrist and ankle, to form retinacula that bind down tendons in their places. Provides attachment for certain muscles. Sends in septa to ensheath muscles, vessels, nerves and glands.

MUSCLES are the means by which movements are brought about. They are the red flesh of the body, and make up nearly a half of the body-weight.

Attachments.—They are attached to bones, cartilages, ligaments, deep fascia and skin. Attachment may be by muscular tissue, but is usually by fibrous tissue called **tendon.** Some tendons are in the form of strong fibrous cords. When the tendinous attachment is in the form of a broad sheet it is called an **aponeurosis.**

Origin and Insertion.—Muscles are attached by at least two ends. These attachments are called origin and insertion. **Origin** is the attachment which remains stationary when the muscle contracts. It is usually the proximal and more extensive attachment. **Insertion** is the attachment which moves when the muscle contracts. Some muscles can act in either direction, the " origin " on some occasions being the attachment that is moved.

Varieties of Action.—Muscles act on all joints which they cross, beginning with the one nearest insertion; and their actions can usually be inferred from their attachments and their relations to the joint. More than one muscle (or group) are implicated in any one movement :—(1) **Prime movers.** (2) **Antagonists**: they must relax to allow prime movers to act; but their relaxation is controlled—they " give " no more than is required. (3) **Synergists** are important collaborators, and are of two kinds—**corrective** and **fixive.**

A prime mover may pass over more than one joint. A **corrective synergist** is an antagonist that contracts to fix the joint which is not to be moved. One's own forearm provides a good example : when flexors close the fist, synergist extensors can be seen contracting to prevent flexion at the wrist. **Fixive muscles** contract to steady the bones from which the prime movers and the correctives arise.

Nerve-Supply and Blood-Supply. — Each muscle is supplied by one or more nerves, which convey motor impulses to it and sensory impressions from it. Each is supplied with blood by numerous branches from neighbouring blood-vessels.

BURSÆ AND SYNOVIAL SHEATHS.—**Bursæ** are fibrous sacs lined with synovial membrane which secretes a viscid liquid called **synovia.** They are found between the skin and subcutaneous bony points, under muscles and tendons that pass over bones or ligaments, and between tendons or muscles. They facilitate movement and lessen friction.

Synovial sheaths resemble bursæ in structure and function. They ensheath long tendons where they are liable to friction.

Some bursæ and synovial sheaths are prolongations of the synovial membranes of joints.

UPPER LIMB

PECTORAL REGION

Landmarks to be Identified.—Acromion ; acromio-clavicular joint ; clavicle. Sternum ; sternal angle ; second costal cartilage ; xiphi-sternal joint ; epigastric fossa ; seventh costal cartilage. Eleventh rib.

Latissimus dorsi and teres major in the posterior fold of axilla ; subscapularis and the lateral margin of scapula in the posterior wall above that. Ribs and serratus anterior in the medial wall. Humerus and coraco-brachialis and biceps in the lateral wall. Pectoralis major in the anterior fold.

Greater tuberosity of humerus under the deltoid on the lateral side of the shoulder. Infraclavicular fossa ; coracoid process. Nipple between the fourth and fifth ribs in a man. Sterno-mastoid in the side of the neck.

Superficial Fascia.—Contains :—1. A moderate quality of *fat.*

2. **Platysma,** a thin sheet of muscle that arises from the skin and deep fascia over pectorialis major and deltoid and passes up over the clavicle into the neck to reach the face.

3. *Cutaneous nerves* and *vessels.*

4. *Mammary gland.*

Cutaneous Nerves.—Supraclavicular ; cutaneous branches of intercostal nerves.

Supraclavicular Nerves.—Lateral, intermediate and medial. Arise from the anterior primary rami of the 3rd and 4th cervical nerves, pierce the deep fascia in the neck, divide into branches which

descend over the three thirds of the clavicle, pierce platysma and supply the skin of shoulder and front of chest down to the level of a line drawn horizontally from the sternal angle.

Anterior cutaneous branches of intercostal nerves are their terminal branches. The upper six (first, however, often absent) emerge from the intercostal spaces close to the sternum, pierce pectoralis major and deep fascia, and divide into small medial branches and larger lateral ones, which supply skin of the *medial* part of front of chest below that horizontal line. The *lateral* part is supplied by the anterior divisions of the **lateral cutaneous branches** of 3-6 intercostal, which curve forwards out of the axilla around the margin of pectoralis major.

Cutaneous Vessels.—Very small. Accompany these nerves. The arteries that accompany the anterior cutaneous nerves are called **perforating arteries.** They come from the **internal mammary,** which descends behind the costal cartilages half an inch from the sternum; those that come through the 2nd, 3rd and 4th spaces are big in women—the 3rd usually the biggest—for they help to supply the mammary gland.

Breast or **Mamma.**—Includes:—Mammary gland; superficial fascia which encloses it; overlying skin with nipple and the coloured patch—areola.

Gland is rudimentary in children and in men.

Enlarges rapidly at puberty in women. Largest during lactation. Atrophies in old age. Extends from second costal cartilage to the sixth, and from the edge of sternum almost to the middle of axilla, and therefore partly on the side of the chest as well as on the front. Lies in the superficial fascia on pectoralis major, serratus anterior and the upper part of the obliquus externus abdominis and its aponeurosis; at the lower border of pectoralis major, a process extends up into axilla as high as the third rib.

Nipple is a little below its middle; and, when the breast is not pendulous, it is opposite 4th intercostal space near the cartilages. Coloured patch around nipple is the *areola of the breast*; it has no hairs around it as in men. Changes from pink to brown in the second month of the first pregnancy and never recovers the pink shade.

The gland is made up of 15-20 lobes divided into lobules. Lobes, large and cleft peripherally, converge upon nipple, and the **lactiferous duct** of each lobe opens on the summit of the nipple. Under the areola, each duct is dilated—*lactiferous sinus.*

No capsule and no common fascial sheath, but lobes have a covering of fibrous tissue and are separated by fibrous strands which pass between them from the skin to the deep fascia. Surface

smooth because the inequalities are filled with fat, which, however, is absent from areola and nipple—in both sexes.

Arteries: from lateral thoracic, intercostals, and the branches of internal mammary. **Veins** end in internal mammary and axillary; a few in external jugular. **Nerves**: from 4th, 5th, 6th intercostals.

Lymph-vessels go to the glands that are nearest to the mamma. They lie—(*a*) between pectoralis major and minor, (*b*) in axilla, (*c*) in root of neck, (*d*) along int. mammary art. in thorax. Disease may be carried from mammary gland to any of these groups.

Lymph-vessels of mammary gland, like those of other parts, communicate freely with neighbouring lymph-vessels. Disease may therefore be carried across to the other side or down into the abdomen.

Deep Fascia.—Pectoral Fascia: Thin. Covers pectoralis major. Attached to clavicle and sternum. Continuous with the fascia of abdomen and the axillary fascia, and with the fascia over deltoid, dipping in as a septum between pectoralis major and deltoid to be connected with the clavi-pectoral fascia.

Part of the *cephalic vein* (on its way from upper arm to axillary vein) lies under the deep fascia at the medial side of that septum; and, alongside it, there are one or two *delto-pectoral lymph-glands*, which receive lymph from the lateral side of shoulder, upper arm and upper part of forearm, and pass it on to glands high up in axilla.

Axillary Fascia.—Dense and felted. Stretches from wall to wall across the floor of axilla, but is drawn up into the hollow of axilla by its close connexion with areolar tissue around vessels and nerves in axilla and with the fascial sheath of pectoralis minor.

Sterno-Clavicular Joint.—*See* p. 128.

Muscles.—Pectoralis major and minor; subclavius; serratus anterior.

Pectoralis major lies superficially on the front of the chest and in the anterior wall of axilla. It is largely covered by the mammary gland, and it is separated from the deltoid by a groove that contains cephalic vein, deltoid branch of acromio-thoracic artery (and vein), and delto-pectoral lymph-glands.

Origin (fleshy): *clavicular part* from anterior surface of medial half or two-thirds of clavicle; *costo-sternal part* from anterior surface of sternum, upper six costal cartilages and aponeurosis of obliquus externus abdominis. Costo-sternal part is twisted, lowest fibres curving upwards behind the upper fibres, so that a *bilaminar tendon* is formed. Clavicular fibres join its anterior lamina.

Insertion: Into the lateral lip of bicipital groove, with

expansions to the capsule of the shoulder-joint and the deep fascia of the upper arm.

Nerves: lateral and medial pectoral. Their fibres come from C. 5, 6, 7; C. 8, T. 1.[1]

It flexes and adducts the arm and rotates it medially. When the arm is fixed, it can raise the ribs and draw the trunk to the arm.

Pectoralis minor lies on the front of the chest and in anterior wall of axilla, under cover of pectoralis major.

Origin (fl.)[2]: 2nd, 3rd, 4th, 5th ribs, near their cartilages (usually omitting 2nd or 5th).

Insertion (tendinous): medial border and upper surface of the anterior half of coracoid process, and into the tendon of coraco-brachialis and biceps.

Nerve: medial pectoral (C. 8; T. 1).

It draws the shoulder downwards and forwards; raises the ribs when the shoulder is fixed.

Subclavius lies between the clavicle and the first rib.

Origin: by tendon, from the junction of first rib and its cartilage, in front of costo-clavicular ligament.

Insertion (fl.): floor of groove on lower surface of clavicle.

Nerve: N. to subclavius, from C. 5, 6.

It draws the clavicle downwards and forwards.

Subclavian vessels lie behind and below it.

Clavi-Pectoral Fascia.—Lies behind the clavicular part of pectoralis major, in front of the first part of the axillary vessels. *Above*, it splits to enclose subclavius and to be attached to the lips of the groove on the clavicle for subclavius. *Below*, it splits to ensheath pectoralis minor, from which it is continued into the axillary fascia. Attached *medially* to the first costal cartilage and the fascia of the first intercostal muscle, *laterally* to coracoid process. Deep surface is connected with the sheath of the axillary vessels.

It is *pierced* by acromio-thoracic artery, cephalic vein and lateral pectoral nerve.

Serratus anterior lies on the side of the chest in the medial wall of axilla. Infero-lateral quadrant of the mammary gland lies on it. First digitation appears, above the clavicle, in the posterior triangle of the neck.

Origin (fl.): by 8 digitations from the upper 8 ribs and the fascia which covers intercostal muscles. First digitation arises from the second rib as well as from the first.

[1] C. Signifies cervical. T. or TH. signifies thoracic.

[2] (fl.) signifies fleshy; (tend.) tendinous; (fl.-tend.) fleshy and tendinous.

Insertion (fl.-tend.) : first digitation into the deep surface of superior angle of scapula ; 2nd, 3rd, 4th into a strip on the deep aspect of medial margin ; 5th, 6th, 7th, 8th converge upon the deep surface of inferior angle.

Nerve : N. to serratus anterior (c. 5, 6, 7).

It draws scapula forwards, in pushing and in blow from shoulder ; after arm has been flexed, *i.e.* when directed horizontally forwards, the serratus rotates scapula so that arm is directed upwards ; and it steadies scapula while trapezius is rotating scapula to direct arm upwards. Elevates middle ribs when scapula is fixed.

Axilla or Armpit

Four walls, base or floor, and apex :

Anterior wall : pectoralis major and minor, clavi-pectoral fascia.

Posterior : subscapularis, teres major, latissimus dorsi. Longer from above downwards than anterior wall ; and terminal parts of axillary artery, etc., have therefore no muscle in front of them.

Medial : upper four or five ribs and intervening spaces, covered by serratus anterior.

Lateral, very narrow : coraco-brachialis, biceps.

Base : axillary fascia. **Apex** leads up into posterior triangle of neck through **cervico-axillary canal,** which is bounded *in front* by clavicle, *behind* by upper border of scapula, *medially* by first rib.

Contents : Axillary vessels and their branches and tributaries. Lower part of brachial plexus and its branches. Nerve to serratus anterior. Intercosto-brachial nerve. Lateral cutaneous branches of third to sixth intercostal nerves. Termination of cephalic vein. Lymph-glands and lymph-vessels. Areolar tissue and fat.

Axillary vessels, brachial plexus and its large branches lie close to the lateral wall of axilla, except at the apex ; and they follow the lateral wall when the arm is moved. In upper part of axilla they are closer to the anterior wall than to the posterior wall.

Relations in Axilla

(*Some of the structures are followed beyond the axilla*)

Axillary vessels and brachial plexus are in a sheath continued over them from the fascia that covers the scalene muscles of the neck.

Axillary Artery.—Begins as a continuation of the subclavian at the outer margin of the first rib, and at once enters the axilla through its apex. It ends by becoming continuous with the brachial at the lower border of teres major tendon. When the arm is dependent, it is slightly arched with the convexity upwards and sidewards.

When the arm is abducted to a right angle, the artery is straightened out and is opposite a line drawn from the middle of the clavicle to the junction of the arm with the lower border of the posterior wall of the axilla.

Pectoralis minor, as it crosses in front of the artery, divides it into three parts—first part (very short) above pectoralis minor, second part behind that muscle, third part below it—third part being longer than the other two parts together.

Relations of 1st Part.— *Anterior*, from skin towards axilla : skin ; superficial fascia, platysma, middle supraclavicular nerves ; deep fascia ; pectoralis major ; lateral pectoral nerve and branches of acromio-thoracic artery ; clavi-pectoral fascia ; cephalic vein ; loop between pectoral nerves.

Lateral and above : lateral and posterior cords of brachial plexus ; lateral pectoral nerve.

Posterior : medial cord of plexus and medial pectoral nerve ; nerve to serratus anterior and the first digitation of the serratus ; contents of first intercostal space.

Medial and below : axillary vein, and medial pectoral nerve passing forwards between artery and vein.

Relations of 2nd Part.— *Anterior* : skin, etc. ; pectoralis major and minor. *Lateral* : lateral cord of plexus. *Posterior* : posterior cord ; behind that, fatty tissue separates it from subscapularis.

Medial : axillary vein ; medial cord between artery and vein.

Relations of 3rd Part.— *Anterior* : skin, fasciæ, and pectoralis major proximally, skin and fasciæ distally ; lateral vena comitans crossing to join the medial vena ; medial root of median nerve, medial cutaneous nerve of forearm ; axillary vein overlaps.

Lateral : median and musculo-cutaneous nerves ; coraco-brachialis.

Posterior : subscapularis, latissimus dorsi, teres major, from above downwards, subscapularis chiefly ; radial nerve between artery and all three muscles ; circumflex nerve between art. and subscapularis.

Medial : axillary vein ; medial vena comitans and ulnar nerve between artery and vein (and medial cutaneous of forearm is medial before it is anterior) ; medial cutaneous nerve of arm on medial side of vein.

Axillary Vein.—Begins at the lower border of teres major as a continuation of the basilic vein ; passes upwards and medially along the medial side of the artery (but overlapping it in front) ; and it ends at the outer border of the first rib by becoming the subclavian. It possesses several valves.

Tributaries.—(1) *Venæ comitantes of branches of axillary artery* (except acromio-thoracic : venæ comitantes of its branches end in cephalic). (2) *Venæ comitantes of brachial artery* are continued along axillary, the lateral one crossing obliquely over the third part, and they join axillary vein at lower border of subscapularis. (3) Upper part of *cephalic vein* pierces the deep fascia at the lower border of pectoralis major, ascends in the groove between pectoralis major and deltoid ; below the clavicle it passes under cover of the clavicular head of pectoralis major, crosses pectoralis minor, and

pierces the clavi-pectoral fascia ; it then crosses in front of the first part of axillary artery and ends in the axillary vein.

Branches of Axillary Artery.—From *first part* : superior thoracic.
From *second part* : acromio-thoracic ; lateral thoracic.
From *third part* : subscapular ; anterior and posterior circumflex.

Superior thoracic artery ramifies over the first intercostal muscle.

Acromio-thoracic art. turns over the upper border of pectoralis minor, piercing clavi-pectoral fascia ; divides into four branches, which diverge from one another—to supply structures of the front of the shoulder, armpit and chest.

Lateral thoracic runs downwards and medially to the infero-lateral border of pectoralis minor, along which it runs to the wall of the thorax ; supplies muscles and the mammary gland.

Subscapular artery, the largest branch. Runs along the lower border of subscapularis to the inferior angle of scapula. In the lower part of its course, the nerve to latissimus dorsi accompanies it. On its way, it gives off the **scapular circumflex** (p. 178).

Anterior humeral circumflex artery leaves the axilla by passing behind coraco-brachialis.

Posterior humeral circumflex artery, much larger than the anterior, arises at the same level, and leaves the axilla by passing backwards through the space below the shoulder-joint.

Nerves in Axilla that do not arise from Brachial Plexus.—(1) **Intercosto-brachial nerve** is the lateral cutaneous branch of the second intercostal. Pierces the second external intercostal muscle ; appears between the digitations of serratus anterior ; stretches across the axilla ; communicates with the medial cutaneous nerve of arm and lateral cutaneous branch of third intercostal, and, with them, gives branches to the skin of the floor of the axilla ; pierces the deep fascia where the lateral wall of axilla joins the arm ; supplies the skin of the dorsal part of the medial side of the upper arm.

(2) **Lateral cutaneous branches of 3rd-6th intercostal nerves** divide, under cover of serratus anterior, into anterior and posterior divisions, which appear through or between the digitations of that muscle, and leave the medial wall of axilla by turning round the borders of pectoralis major and latissimus dorsi respectively ; posterior division of the third sends branches to join the intercosto-brachial.

Brachial Plexus.—Lies partly in the antero-inferior angle of the posterior triangle of neck, partly behind the clavicle, partly in the axilla. It is made up of roots, trunks, divisions, cords and branches.

1. *Roots*—anterior primary rami of 5th, 6th, 7th, 8th cervical, greater part of 1st thoracic, and communications from 4th cervical and 2nd thoracic nerves.
2. *Trunks*—upper, middle and lower.
3. Three anterior and three posterior *divisions*.
4. *Cords*—lateral, medial and posterior.
5. *Branches* spring from the roots and the cords.

Upper trunk is formed by the union of the 5th and 6th cervical and the communication from the 4th. 7th alone forms the **middle**

trunk. 8th cervical and 1st thoracic and the communication from the 2nd form the **lower trunk.**

Each trunk divides into an **anterior** and a **posterior division.**

The three posterior divisions combine to form the **posterior cord.**

The two upper anterior divisions unite to form the **lateral cord.**

The lower anterior division alone forms the **medial cord.**

Lateral cord therefore contains fibres of 5, 6, 7 c. Medial cord, 8 c., 1 TH. Posterior cord, 5, 6, 7, 8 c.; but 1st thoracic contributes few or no fibres to the posterior cord.

The **branches** arise from the roots in the neck and from the cords in the axilla. Each cord, having given off collateral branches, ends by dividing into two terminal branches, opposite the infero-lateral border of pectoralis minor, a finger's breadth below and medial to the tip of the coracoid process, *at the junction of the second and third parts of axillary artery.*

The cords therefore are related to the first and second parts of the artery, and the big nerves to the third part.

Relations in Axilla.—The lower parts of the divisions and the upper parts of the cords are above, behind and lateral to the *first* part of axillary artery; the cords are then arranged around the *second* part according to their names—lateral, medial and posterior. The medial cord is therefore between the axillary vein and the second part of the artery. The *anterior* relations of the plexus are therefore the axillary artery and the structures (skin, etc.) in front of its first and second parts. The *posterior* relations are the uppermost part of serratus anterior and its nerve, a quantity of fat, and the subscapularis muscle.

Branches of Roots of Brachial Plexus.—(1) Branches to muscles of the neck. (2) Four branches to muscles of upper limb:—Suprascapular nerve; nerve to the rhomboids; nerve to subclavius; and nerve to serratus anterior.

The **nerve to serratus anterior** is the only one that enters the axilla. It arises from the 5th, 6th, 7th cervical nerves. Its roots descend into the axilla over the uppermost part of serratus anterior, behind brachial plexus and the first part of axillary artery; and they combine into one stem, which descends over the axillary surface of serratus anterior, supplying that muscle alone.

Branches of Cords of Brachial Plexus.—**Lateral cord** gives off lateral pectoral, and divides into musculo-cutaneous and lateral root of median.

Medial cord gives off medial pectoral, medial cutaneous nerve of arm, medial cutaneous nerve of forearm, and divides into ulnar and medial root of median.

Posterior cord gives off the nerve to latissimus dorsi, and upper and lower subscapular, and divides into circumflex and radial.

Lateral pectoral nerve arises from the lateral cord at its origin; runs forwards, lateral to the first part of the axillary artery; is connected with the medial pectoral by a loop placed in front of the artery; pierces the clavi-pectoral fascia and sinks into the upper part of pectoralis major, to supply the greater part of it.

Musculo-cutaneous nerve, a terminal branch of the lateral cord,

runs downwards between the axillary artery and coraco-brachialis, and leaves the axilla by piercing coraco-brachialis opposite teres major. It gives off the branch to the coraco-brachialis *before* it pierces the muscle.

Median nerve arises from the lateral and medial cords. *Lateral root*, a terminal branch of the lateral cord, lies on the lateral side of the axillary artery; *medial root*, a terminal branch of the medial cord, crosses in front of the artery to join the lateral root. Median nerve descends along the lateral side of the axillary artery, between it and coraco-brachialis. It gives no branches in axilla (or in upper arm).

Medial pectoral nerve arises from the medial cord, passes forwards between the axillary artery and vein, communicates with the lateral pectoral, pierces pectoralis minor, supplying it, and ends in pectoralis major, supplying part of it also.

Medial cutaneous nerve of arm arises from the medial cord; passes behind the axillary vein to reach its medial side; descends along its medial side; pierces the deep fascia to supply the skin of the medial side of upper arm.

Medial cutaneous nerve of forearm arises from the medial cord near its termination; descends in front of the ulnar nerve, and then passes on to the anterior surface of the axillary artery. It gives off no branches in the axilla.

Ulnar nerve, a terminal branch of the medial cord, descends along the medial side of the axillary artery, between it and the vein. It gives no branches in axilla (or in upper arm).

Subscapular nerves arise from the posterior cord. The **upper** passes downwards and backwards, and sinks into the upper part of subscapularis after a very short course; some of its filaments reach the capsule of the shoulder-joint. The **lower** runs downwards and laterally over subscapularis, supplying its lower part, and it ends in teres major.

The **nerve to latissimus dorsi** arises from the posterior cord between the upper and lower subscapulars; runs downwards and backwards, over subscapularis and teres major, to the inferior angle of scapula, where it ends in latissimus dorsi. Its distal part accompanies the subscapular vessels.

Radial nerve, the thickest nerve of the upper limb, is a terminal branch of the posterior cord. It proceeds downwards, behind the axillary artery, in front of subscapularis, latissimus dorsi, and teres major. A few branches arise from it in the axilla: (a) *muscular branches* are given to the long and medial heads of triceps; (b) *posterior cutaneous nerve of arm* runs downwards behind radial nerve and leaves it to supply skin on the back of upper arm.

Circumflex nerve, the other terminal branch of the posterior cord, runs first downwards, between the axillary artery and subscapularis, on the lateral side of the radial nerve; it then leaves the axilla by passing backwards, with the posterior humeral circumflex vessels, below subscapularis and the shoulder-joint. It gives off no branches in the axilla.

Lymph-Glands of Axilla.—*See* p. 459.

PART OF BACK THAT BELONGS TO UPPER LIMB

Certain muscles of upper limb are found in the back from skull to iliac crest.

Landmarks to be Identified.—Acromion; crest of spine of scapula; medial border of scapula and its upper and lower angles. Second, seventh, eighth and twelfth ribs.

Superior nuchal line; external occipital protuberance; ligamentum nuchæ; spines of second and seventh cervical vertebræ; first, third, seventh and twelfth thoracic spines; fourth lumbar spine; second sacral spine; coccyx.

Iliac crest; posterior superior iliac spine.

Superficial Fascia.—Contains a variable quantity of *fat* and the *cutaneous nerves* and *vessels*.

Cutaneous Nerves.—They come from the posterior primary rami of spinal nerves—from their medial divisions in the upper half of the back, and therefore pierce the deep fascia about a thumb's breadth from the median plane; from their lateral divisions in the lower half and therefore emerge about a hand's breadth from the median plane. These cutaneous nerves divide into small medial branches and larger lateral branches, which spread sidewards and downwards over the back.

In the back of the neck they come from the 3rd-6th cervical. On the back of the chest and in the loin, from the twelve thoracic nerves. From the middle of the neck downwards, the skin supplied is increasingly lower than the level of the corresponding spinal nerve-trunk, so that the skin of the loin is supplied by thoracic nerves.

Cutaneous branches come also from the upper three lumbar nerves, but they do not pierce the deep fascia till near the iliac crest, and they descend at once into the gluteal region.

Cutaneous Blood-Vessels.—Small and unnamed. Come from the ascending branch of transverse cervical in the neck, and, lower down, from intercostal and lumbar vessels. They accompany the nerves.

Lymph-Vessels.—From the back of the neck, they pass to deep glands in the front of the neck; from upper part of trunk, to glands in axilla; from lower part, to glands in the groin.

Deep Fascia.—Thin and dense except in the loin, where it is thick, dense and strong, and is called the posterior layer of **lumbar fascia.**

Muscles.—Trapezius and latissimus dorsi, superficially from skull to iliac crest; levator scapulæ and rhomboideus minor and major under cover of trapezius.

Trapezius lies superficially, on the back of the neck and the back of the upper part of the trunk.

Origin, tendinous: medial third of superior nuchal line, external occipital protuberance, ligamentum nuchæ,

spines of 7th cervical and *all* thoracic vertebræ, and from supraspinous ligaments.

Insertion, fleshy and tendinous: posterior border of lateral third of clavicle, encroaching on upper surface; medial margin of acromion; upper lip of scapular crest and tubercle on lower lip.

Nerves: accessory nerve; and branches of anterior primary rami of 3rd and 4th cervical.

Whole muscle braces back shoulder; upper fibres elevate, lower depress. Middle and lower fibres help to rotate scapula in the movement of abducting arm and raising it above head. When shoulder is fixed, upper fibres draw head to that side, and both muscles acting retract head.

Bursa lies between the tendon of the lower part and the smooth area at the medial end of spine of scapula.

Latissimus dorsi lies in the lower part of the back and the lower part of the posterior wall of axilla.

Origin, very broad and chiefly tendinous: from the lower six thoracic spines under cover of trapezius, from lumbar fascia, from iliac crest behind its middle (chiefly fleshy), by small fleshy slips from the lower three or four ribs, and sometimes inferior angle of scapula.

Insertion by flat tendon into the floor of bicipital groove of humerus and into fascia of the upper arm.

Nerve: Nerve to latissimus dorsi from posterior cord of brachial plexus. (Fibres from c. 6, 7, 8.)

It adducts and extends humerus and rotates it medially; when arm is fixed, it can raise lower ribs and assists in drawing trunk forwards and upwards.

It winds round teres major, assisting it to form lower part of posterior wall of axilla; it may be separated from teres major, at insertion, by a bursa.

Triangle of Auscultation.—Bounded by trapezius, latissimus and medial border of scapula. Floor is formed by rhomboideus major, and, when scapula is drawn forwards, by 6th and 7th ribs also—the only part of ribs not covered with muscles.

Levator scapulæ lies at the back of the side of the neck. The muscle is split lengthwise into two parts.

Origin: fleshy and tendinous slips from the upper four cervical transverse processes.

Insertion (fl.-tend.): medial margin of scapula from

upper angle to root of spine—the uppermost fibres of origin being lowest at the insertion.

Nerves: C. 3, 4 directly; C. 5, through the nerve to the rhomboids.

It assists trapezius in raising shoulder and bracing it against weights.

Rhomboideus minor lies in upper part of back under cover of trapezius. **Origin** (fl.-tend.): lig. nuchæ; spines of 7th cervical and 1st thoracic vertebræ. **Insertion**: medial margin of scapula at root of spine.

Rhomboideus major lies in upper part of back immediately below the minor and edge to edge with it.

Origin: second to fifth thoracic spines and supraspinous ligaments.

Insertion: medial margin of scapula from root of spine to inferior angle, lowest fibres directly to scapula, remainder to a fibrous band attached by its ends to root of spine and inferior angle.

Nerve: N. to rhomboids from C. 5.

Rhomboidei retract and rotate scapula.

Inferior Belly of Omo-Hyoid.—A slender slip. Belongs to the neck, not to the back, but is found under cover of trapezius springing from the suprascapular ligament and the upper border of scapula. It runs across the lower part of the posterior triangle of neck and disappears under sternomastoid, where it ends in a tendon which connects it with the superior belly; and that belly ascends to the hyoid bone.

Deeper Nerves and Vessels.—**Nerves to trapezius**—accessory and branches from 3rd and 4th cervical—form a network on the deep surface of trapezius before they enter it—the terminal branch of accessory reaching almost to the lower end of trapezius before it disappears.

Nerve to the rhomboids springs from the back of the anterior ramus of the fifth cervical with the upper root of the nerve to serratus anterior; slants downwards and sidewards in the posterior triangle of neck, and then descends under cover of levator scapulæ and the two rhomboids near the medial margin of scapula, giving branches to these three muscles.

Transverse Cervical Artery.—A branch of the thyro-cervical trunk, which springs from the first part of subclavian. Runs across the posterior triangle of neck to the anterior border of levator scapulæ and divides there into two branches—a superficial and a deep.

Superficial branch of transverse cervical passes superficial to the levator and ramifies on the deep surface of trapezius.

Deep branch of transverse cervical descends deep to (*i.e.* in front

of) levator and the two rhomboids close to scapula along the lateral side of the nerve to the rhomboids. Gives branches to scapular muscles, and to the muscles that cover it, including trapezius.

SCAPULAR REGION

Superficial Fascia.—Contains :—1. A moderate quantity of *fat*.
2. The lower lateral part of *platysma* arising from the skin and deep fascia over the anterior part of deltoid.
3. *Cutaneous nerves* and *vessels*.

Cutaneous Nerves.—At the back, *cutaneous branches from posterior primary rami* of the upper thoracic nerves (p. 171). *Lateral supraclavicular* nerves (p. 162) over the upper half of deltoid. *Upper lateral cutaneous nerve of arm* — a branch of the circumflex nerve—supplies the skin over the lower half of the deltoid. *Filaments from the anterior division of circumflex* come through the deltoid and help to supply the skin over it.

Cutaneous Vessels.—Small, unnamed *arteries* (with *veins*) come through the deep fascia, chiefly from circumflex and acromiothoracic.

Lymph-vessels pass to delto-pectoral glands and glands in axilla.

Deep Fascia.—On the front, it is thin and delicate over subscapularis. On the back, it is dense and strong over teres major and minor and infraspinatus—especially over infraspinatus. Sends in a strong septum between infraspinatus and teres minor to be attached to the back of scapula, and one between the two teres to be attached to its lateral margin. Splits to ensheath deltoid ; dense and strong on the back of deltoid ; less so on the side and front.

Coraco-Acromial Arch.—Formed of coracoid process, coracoacromial lig. (p. 130) and acromion. Overhangs and protects shoulder-joint. Separated from the joint by the subacromial bursa and by tendons—supraspinatus and the upper parts of infraspinatus and subscapularis—which cover the upper part of the capsule of the joint. The arch acts as a second socket for the head of humerus—the subacromial bursa facilitating movement.

Subacromial Bursa.—A large bursa placed under the acromion and the upper part of deltoid and separates them from the tendons on the upper part of the capsule of the shoulder-joint.

Suprascapular and Spino-Glenoid Ligs.—*See* pp. 130, 131.

Acromio-Clavicular Joint and Coraco-Clavicular Ligament.—*See* pp. 129, 130.

Muscles.—1. *Those that connect shoulder-girdle with trunk* : pectoralis minor (p. 165) ; subclavius (p. 165) ; serratus anterior (p. 165) ; trapezius (p. 171) ; levator scapulæ and rhomboids (p. 172) ; inferior belly of omo-hyoid (p. 173). **All to be revised.**

2. *Those that connect shoulder-girdle with humerus* : coracobrachialis (p. 180) ; deltoid ; supraspinatus ; infraspinatus ; teres minor ; teres major ; subscapularis.

Deltoid surrounds shoulder superficially.

Origin (fl.-tend.) corresponds to insertion of trapezius: anterior border of lateral third of clavicle, lateral margin of acromion, lower lip of crest of spine of scapula.

Insertion (tend.): deltoid tuberosity of humerus.

Nerve: circumflex (c. 5, 6).

Whole muscle abducts the arm to a right angle with the trunk; anterior fibres flex and rotate medially; posterior fibres extend and rotate laterally.

STRUCTURES COVERED BY DELTOID.—Anteriorly: Coracoid process, coraco-clavicular ligament, insertion of pectoralis minor; origin of short head of biceps and coraco-brachialis, which separate it from subscapularis; long head of biceps; insertion of pectoralis major.

Laterally: Coraco-acromial ligament; *subacromial bursa* (which separates it from greater tuberosity and tendons of supra- and infra-spinatus); surgical neck and upper part of shaft of humerus, on which the posterior circumflex vessels and circumflex nerve lie.

Posteriorly: Infraspinatus, teres minor and major; quadrilateral space and its contents; long and lateral heads of triceps.

The deltoid is nowhere in contact with capsule of shoulder-joint, but is separated from it by subacromial bursa and the muscles attached to the tuberosities and to the coracoid process.

Supraspinatus lies in supraspinous fossa and on top of capsule of shoulder, under cover of trapezius, coraco-acromial arch and deltoid.

Origin (fl.): walls of supraspinous fossa (except near neck of scapula) and from the fascia which covers it.

Insertion: by tendon into upper impression on greater tuberosity of humerus and into joint-capsule.

Nerve: suprascapular, from c. 5, 6. It abducts arm.

Infraspinatus lies in infraspinous fossa and under cover of deltoid on superior and posterior surface of capsule of shoulder, a *bursa* sometimes intervening.

Origin (fl.): walls of infraspinous fossa (except near neck) and from the fascia which covers it.

Insertion: by tendon into middle impression of greater tuberosity and into joint-capsule.

Nerve: suprascapular.

It extends arm and rotates it laterally.

Teres minor lies along lower border of infraspinatus, and on posterior surface of capsule of shoulder.

Origin (fl.): elongated elevation on dorsal surface of scapula along lateral margin.

Insertion: by tendon into posterior impression on greater tuberosity of humerus and slightly into the capsule of the shoulder-joint; by fleshy fibres into surgical neck and shaft of humerus for nearly an inch.

Nerve: circumflex, from c. 5, 6.

It rotates arm laterally, and adducts and extends it.

Teres major lies in lower border of posterior wall of axilla. Latissimus dorsi, at first behind it, curves below it to lie in front of its insertion, separated by bursa.

Origin (fl.): oval elevation on dorsum of scapula above inferior angle.

Insertion: by tendon into medial lip of bicipital groove of humerus.

Nerve: lower subscapular, from c. 5, 6.

It extends and adducts arm, and rotates it medially.

Subscapularis lies in posterior wall of axilla and on anterior and lower parts of capsule of shoulder-joint, from which it is partly separated, anteriorly, by the *subscapular bursa*, which protrudes from the joint.

Origin (fl.): floor of subscapular fossa, including groove along axillary margin of scapula (but excluding portion near neck and portions occupied by insertion of serratus anterior); also from tendinous septa which pass into its substance from ridges in the fossa.

Insertion: by tendon into lesser tuberosity of humerus; by fleshy fibres into surgical neck and shaft for nearly an inch.

Nerves: upper and lower subscapular, from c. (4), 5, 6, (7).

It adducts arm, and rotates it medially.

Subscapular Bursa.—A large bursa that separates part of subscapularis from the joint-capsule and from the front of the neck of scapula and root of coracoid process. Facilitates the play of subscapularis. Is continuous with the synovial membrane of the joint through a hole in the upper part of the front of the capsular lig.

Bursa of Infraspinatus.—Small. Lies between the tendon of infraspinatus and the back of the capsule. Not always present. When present, it may be continuous with the synovial membrane through a hole in the capsular ligament.

Coraco-Brachialis.—(*See* Muscles of Arm, p. 180.)

Quadrilateral Space.—*Bounded above* by subscapularis, capsule of shoulder-joint, teres minor; *below* by teres major;

laterally by shaft of humerus and lateral head of triceps; *medially* by long head of triceps. *Transmits* circumflex nerve and posterior circumflex vessels. *Covered* posteriorly by deltoid; related anteriorly to coraco-brachialis and biceps, and large vessels and nerves in axilla.

Triangular Space.—*Bounded above* by subscapularis, lateral margin of scapula, teres minor; *below* by teres major; *laterally* by long head of triceps. Scapular circumflex vessels are seen in it.

Deeper Nerves and Vessels.—Subscapular nerves and vessels (pp. 168, 170) and scapular circumflex artery; nerve to latissimus dorsi (p. 170); nerve to the rhomboids and deep branch of transverse cervical artery (p. 173); humeral circumflex vessels and nerve suprascapular nerve and vessels.

Suprascapular Nerve.—Arises from c. 5 and 6 where they unite to form the upper trunk of brachial plexus. Runs downwards and sidewards across the posterior triangle of neck above the brachial plexus, and enters the upper limb by disappearing under cover of trapezius immediately above the clavicle.

It then descends, along with the suprascapular vessels and the inferior belly of omo-hyoid, to the upper border of scapula, where it passes backwards through the suprascapular notch below the suprascapular ligament and enters the supraspinous fossa. There, it supplies supraspinatus and gives a branch to the capsule of shoulder-joint, and then descends through the spino-glenoid notch into infraspinous fossa, where it ends by supplying infraspinatus and giving another branch to the shoulder-joint.

Suprascapular Artery.—Like the transverse cervical, it arises in the root of the neck from the thyro-cervical trunk. It runs behind the clavicle to the posterior angle of the posterior triangle of neck, where it joins the suprascapular nerve; it descends with the nerve, and is distributed with it; but, at the upper border of scapula, it passes over the suprascapular lig. and not below it.

Its *companion veins* may be either above or below the ligament. They end in the external jugular vein.

Circumflex Nerve.—A terminal branch of the posterior cord of brachial plexus. Leaves the axilla at the lower border of subscapularis by passing backwards through the quadrilateral space, whose boundaries are therefore its relations.

While in the space under cover of the deltoid, it sends a branch up to the capsule of shoulder-joint and then splits into an anterior and a posterior division.

Posterior division gives a branch to the teres minor and twigs to the deltoid; it then curves round the posterior border of deltoid at the junction of its middle and lower thirds as the *upper lateral cutaneous nerve of the arm*, and runs forwards, branching, to supply the skin over the distal half of the deltoid.

Anterior division winds forwards round the surgical neck of humerus under cover of deltoid and ends in branches that sink into the deltoid; they supply it and send filaments through it to the overlying skin.

Posterior Circumflex Artery.—Arises from the third part of axillary and accompanies the circumflex nerve and its anterior branch, and has therefore the same relations. Its branches supply the shoulder-joint, and the skin and muscles near it. Its important anastomosis is with the profunda branch of the brachial.

Anterior Circumflex Artery.—Much smaller. Arises from the axillary at the same level, turns sidewards behind coraco-brachialis and the short head of biceps, between them and the surgical neck of humerus, and anastomoses with the posterior circumflex. Gives branches to muscles, sends a branch upwards in the bicipital groove to the shoulder-joint and another downwards in the groove to supply the tendon of pectoralis major.

Scapular Circumflex Artery.—Arises in the axilla from the subscapular, curves backwards round the lower border of subscapularis into the triangular space. It does not pass through the space but leaves it by turning medially between teres minor and the scapula (grooving the bone); and it ramifies on the dorsum of scapula.

Anastomosis around Scapula.—**Deep branch of transverse cervical,** along medial border; **suprascapular,** at upper border and on dorsum; **subscapular,** parallel to lateral border; **scapular circumflex,** on dorsum.

Their branches anastomose freely, and, by that means, the circulation is re-established after the main artery has been ligatured in the root of the neck or in the upper part of axilla, for the subscapular comes from the third part of axillary artery and the suprascapular and transverse cervical are branches of the thyro-cervical trunk, which springs from the first part of subclavian.

UPPER ARM

Landmarks to be Identified.—Tuberosities of humerus; deltoid tuberosity; supracondylar ridges; epicondyles. Coronoid process of ulna; olecranon. Biceps brachii.

Superficial Fascia.—Contains:—1. Variable quantity of *fat.*

2. Small *unnamed arteries* that come from the deep arteries.

3. Veins in greater number—end chiefly in: (*a*) *cephalic vein*, on the lateral side of the prominence made by biceps; (*b*) *basilic vein*, in the groove at the medial side of that prominence as far as the middle of upper arm, where it pierces deep facsia; and (*c*) *median cubital vein*, which connects cephalic with basilic at the bend of elbow.

4. *Lymph-vessels* and a few lymph-glands.

5. Numerous *cutaneous nerves.*

Cephalic Vein.—Ascends from the lateral surface of the forearm and enters the upper arm near the middle of the bend of the elbow, having sent most of its blood to the basilic vein *via* the median cubital. Much diminished, it ascends opposite the lateral surface of biceps, pierces the deep fascia at the lower border of pectoralis major, continues upwards between pectoralis major and deltoid, receives the veins that accompany the branches of acromio-thoracic artery, and pierces the clavi-pectoral fascia to end in the axillary vein (p. 167).

Basilic Vein.—Ascends from the medial surface of the forearm and enters the upper arm in front of the medial epicondyle. Runs upwards opposite the medial margin of biceps to the middle of the upper arm, where it pierces the deep fascia; it then ascends along the medial side of the brachial vessels and ends where the brachial artery begins—at the lower border of teres major—by becoming the axillary vein.

Median Cubital Vein.—Usually wide. Arises from cephalic an inch below the elbow and slants upwards to join basilic an inch above the medial epicondyle. Crosses bicipital aponeurosis, which separates it from brachial artery. Anterior branch of medial cutaneous nerve of forearm descends behind it (sometimes in front). Communicates by a short, wide vein with the veins in cubital fossa.

Two **supratrochlear lymph-glands** lie near the medial side of basilic vein a little above the epicondyle. They receive afferent vessels from the medial side of forearm and send on efferents to accompany the deep lymph-vessels, which run along the deep veins.

Lymph-vessels of upper arm end in the glands in axilla (a few passing through the delto-pectoral glands).

Lateral supraclavicular nerves (p. 162) supply skin over the upper half of deltoid.

Upper lateral cutaneous nerve of arm (p. 177) supplies skin over the lower half.

Lower Lateral Cutaneous Nerve of Arm.—Arises in the back of the upper arm from the radial nerve under cover of the lateral head of triceps; descends through that head; pierces the deep fascia an inch below the deltoid tuberosity; and supplies skin of the front of the upper arm lateral to cephalic vein between the deltoid tuberosity and the elbow.

Intercosto-brachial nerve (p. 168) supplies a variable area on the back of upper arm, and the medial side behind the upper part of brachial artery.

Medial Cutaneous Nerve of Arm.—Arises from the medial cord of brachial plexus. Descends along the medial side of axillary and basilic veins, pierces the deep fascia near the middle of upper arm, and supplies the area on the medial side behind the lower part of brachial artery and the adjoining part of the back.

Medial Cutaneous Nerve of Forearm.—A larger nerve. Also springs from medial cord. Passes from the medial side of axillary artery on to the front of it and the first inch of brachial artery and then along the medial side of brachial artery to the middle of the upper arm. It pierces the deep fascia there and then runs towards the elbow. Gives branches to supply skin in the upper arm between the cephalic and basilic veins. Near the elbow, it divides into an anterior and a posterior branch which descend to supply the skin of the medial side of forearm both front and back; the anterior branch passes behind the medial cubital vein, the posterior branch either behind the medial epicondyle or in front of it.

Posterior Cutaneous Nerve of Arm.—Arises in axilla from radial

nerve. Descends behind the radial nerve; pierces the deep fascia a little below the axilla; crosses backwards over intercosto-brachial nerve, and supplies skin of the back of upper arm from deltoid tuberosity to elbow.

Posterior Cutaneous Nerve of Forearm.—Arises on the back of the humerus under cover of the lateral head of triceps from the radial nerve in company with the lower lateral cutaneous nerve of upper arm. Pierces the deep fascia two or three inches below deltoid tuberosity. Gives a few branches to the lateral part of upper arm and then descends to supply a wide strip of skin on the middle of the back of the forearm from elbow to wrist.

Deep fascia.—Completely invests the upper arm, and is strengthened by expansions from the tendons of latissimus dorsi, pectoralis major and deltoid. It is continuous with fascia of shoulder, axilla and forearm; and it is attached to the olecranon and epicondyles. It gives off septa which separate muscles from each other. Two of these are strong, and are attached to the epicondyles and supracondylar ridges:—

(1) **Medial intermuscular septum,** the larger and stronger, gives origin by its anterior surface to brachialis and pronator teres, by its posterior surface to medial head of triceps. It is pierced by the ulnar nerve, and by the ulnar collateral and supratrochlear vessels.

(2) **Lateral intermuscular septum** gives origin by its anterior surface to brachio-radialis and ext. carpi radialis longus, by its posterior surface to medial and lateral heads of triceps. It is pierced by radial nerve and anterior branches of profunda vessels.

Muscles of Upper Arm.—Coraco-brachialis, biceps and brachialis, on the front; triceps and subanconeus, on the back.

Coraco-brachialis lies in lateral wall of axilla and on medial side of upper arm. Seen as a longitudinal ridge when arm is abducted. Musculo-cutaneous n. pierces it.

Origin (fl.): tip of coracoid process, along with medial margin of short head of biceps.

Insertion (tend.): impression, an inch long, on the middle of medial margin of humerus.

Nerve: musculo-cutaneous (c. 7 or c. 6, 7).

It flexes and adducts arm.

Biceps brachii lies superficially on front of upper arm, where it overlaps brachial vessels and median nerve.

Origin: *Short head*, by tendon from tip of coracoid process, conjoined with lateral margin of coraco-brachialis. Lies in lateral wall of axilla. *Long head*, by long tendon, from supraglenoid tubercle of scapula. It traverses upper part of shoulder-joint, ensheathed in a synovial tube which accompanies it into bicipital groove.

Insertion: into rough, posterior part of tuberosity of radius by tendon (separated from smooth, anterior part by bursa); and into the fascia over pronator teres by a tendinous expansion called *bicipital aponeurosis*. The tendon and aponeurosis are easily felt in the living limb.

Nerve: musculo-cutaneous (from c. 5, 6).

It supinates forearm to the position midway between supination and pronation, and then flexes; flexes upper arm. Its long head steadies the head of humerus in the movements at the shoulder-joint.

Brachialis lies on the front of humerus behind biceps.

Origin (fl.): front of lower two-thirds of shaft of humerus, and from medial intermuscular septum and anterior ligament of elbow. Its upper end divides to clasp the insertion of deltoid.

Insertion (tend.): front of coronoid process and tuberosity of ulna.

Nerves: musculo-cutaneous and radial (c. 5, 6).

It flexes forearm.

Triceps lies on the back of the upper arm.

Origin: 1. *Long head*, by tendon from infraglenoid tubercle of scapula. It lies between teres major and minor; and it separates the quadrilateral and triangular spaces, being their common boundary.

2. *Lateral head* (fl.-tend.), chiefly from the lateral border of the humerus above the spiral groove.

3. *Medial head* (fl.-tend.), from the whole of the back of the humerus between the olecranon fossa and the insertion of teres major, and from the lateral and medial intermuscular septa.

Radial nerve runs downwards and sidewards between long and medial heads to lie in the spiral groove between medial and lateral heads.

Insertion: by tendon into posterior area on upper surface of olecranon, and by expansions into fascia on each side; the tendon is separated by a *bursa* from posterior ligament of elbow.

Nerve: radial (from c. 7, 8).

It extends forearm; long head extends and adducts upper arm.

Subanconeus consists of a few of the deeper fibres of triceps which arise from distal part of posterior surface

of humerus and are inserted into the capsular ligament of the elbow in order to pull it away during extension.

Deeper Vessels and Nerves of Upper Arm.—Brachial artery and its branches; companion veins; part of basilic vein (p. 179); median and ulnar nerves; musculo-cutaneous and radial nerves and their branches.

Brachial Artery.—The continuation of axillary. Begins at the lower border of the tendon of teres major close to the humerus. Runs downwards and slightly laterally, at first medial to humerus and then in front of it. Ends in the cubital fossa, antero-medial to the neck of radius, by dividing into radial and ulnar.

Relations.—Venæ comitantes, one on each side with connecting veins in front of the artery and behind it. Basilic vein runs along the medial side of the upper half of the artery close by the medial vena comitans; but, in the lower half, it is separated by deep fascia.

Ulnar nerve also is close to the medial side of the upper half, but diverges from its lower half. Medial cutaneous nerve of forearm is in front of its first inch and then along its medial side in front of ulnar nerve as far as the middle of the upper arm.

Radial nerve and profunda vessels are behind its first inch. Median nerve, at first lateral, crosses in front of its middle (sometimes behind) and then runs along its medial side.

Biceps is lateral, but the fleshy belly overlaps it and the bicipital aponeurosis crosses in front of it at the elbow, separating it from the medial cubital vein and the anterior branch of medial cutaneous nerve of forearm. Coraco-brachialis is antero-lateral to its upper half, but the insertion of the muscle is behind the middle of the artery.

Most of the artery is therefore near the surface, covered chiefly by skin and fasciæ.

The posterior relations are chiefly muscles: from above downwards—long head of triceps (separated by radial nerve and profunda vessels); medial head of triceps; insertion of coraco-brachialis at its middle; brachialis behind the lower half of the artery.

Branches.—Unnamed branches to *muscles* and *skin* from the lateral side. From the medial side:—profunda; ulnar collateral; nutrient artery to humerus; supratrochlear.

Profunda Brachii Artery.—The largest branch. Springs from the brachial an inch or less below teres major on the front of the long head of triceps. Runs obliquely downwards from medial to lateral side across the back of humerus in its spiral groove in company with radial nerve, first between the long and medial heads of triceps and then under cover of the lateral head between it and the medial head.

Gives *branches to triceps*. Near its origin it sends up a big *ascending branch* to anastomose with posterior circumflex artery. In the spiral groove, it often sends a *nutrient artery* into humerus.

At the lateral side, it ends by dividing into anterior and posterior *descending* branches. *Anterior branch* accompanies radial nerve through the lateral intermuscular septum and descends with the nerve to the front of the elbow. *Posterior branch* descends over the back of that septum to the back of the lateral epicondyle.

Nutrient Artery.—Very small. Arises near the insertion of coraco-brachialis, and enters the humerus very soon.

Ulnar Collateral Artery.—Slender. Arises near coraco-brachialis and runs with the ulnar nerve to the back of the medial side of the elbow.

Supratrochlear Artery.—Wider and shorter. Arises two inches above elbow; runs medially on brachialis behind median nerve; and ends by dividing into two branches, both of which share in the anastomosis around elbow. *Anterior branch* runs down in front of medial epicondyle. *Posterior branch*, larger, pierces the medial intermuscular septum and descends over the back of medial epicondyle.

Since brachial plexus ends at the junction of second and third parts of axillary artery opposite the infero-lateral border of pectoralis minor about a finger's breadth below and medial to the tip of coracoid process, all its terminal branches—median, ulnar, musculo-cutaneous, radial and circumflex—take origin at that level, and all of these are related to the third part of axillary artery in the early part of their course. And all the big nerves can be felt at the medial side of the upper arm near the axilla.

Median Nerve.—Arises from the lateral and medial cords of brachial plexus by two roots—*lateral* and *medial*—and the medial root crosses in front of the third part of axillary artery to join the lateral root. The nerve then descends along the lateral side of third part of axillary artery and the upper half of brachial; crosses brachial (usually in front of it) at the middle of upper arm and runs along its medial side into cubital fossa. Above the elbow, it can be felt in the living limb by the finger pressed backwards at the medial side of biceps and moved sideways.

No branches in axilla or upper arm.

Ulnar Nerve.—Arises from medial cord. Descends along the medial side of axillary artery and upper half of brachial; deviates medially from brachial; passes downwards and backwards through the medial intermuscular septum into the back of upper arm, and then down along the medial head of triceps and across the back of the medial epicondyle into the forearm. At the back of the epicondyle, it can be rolled between the finger and the bone in the living limb.

No branches in axilla or upper arm.

Musculo-Cutaneous Nerve.—Arises from lateral cord. Descends along the lateral side of third part of axillary artery; leaves it to pierce coraco-brachialis opposite teres major; it then descends between biceps and brachialis to end a little above the elbow by piercing the deep fascia at the lateral margin of biceps tendon, where it becomes the *lateral cutaneous nerve of forearm* (p. 186).

Supplies coraco-brachialis before it pierces it, and biceps and the greater part of brachialis as it descends between them. The branch to brachialis sends a filament to the capsule of elbow-joint.

Radial Nerve.—Biggest nerve in upper limb; and, like the median and ulnar nerves, it runs from the axilla to the hand.

Arises from posterior cord and descends behind the third part of axillary artery, between it and the muscles of posterior wall of axilla—subscapularis, latissimus dorsi and teres major.

Enters the upper arm, where it is at first in the medial side of the limb between the long head of triceps and the first inch of brachial artery; there, the artery and the big nerves—radial, median and ulnar—can be felt in the living limb if pressure is made on the medial side of the humerus.

The nerve then passes obliquely across the back of the humerus in the spiral groove, first between the long and medial heads of triceps and then under cover of the lateral head between it and the medial head; but in a thin person it can be felt through the muscles if pressure is made on the back of the limb.

Having reached the lateral side of the limb, it passes forwards through the lateral intermuscular septum and descends through the areolar tissue that separates brachialis from brachio-radialis and extensor carpi radialis longus. At the level of the lateral epicondyle, it gives off the posterior interosseous nerve, and then descends in front of the capsule of the elbow-joint into the forearm.

Branches.—1. **Cutaneous** (pp. 179, 180):—posterior cutaneous nerve of arm; lower lateral cutaneous nerve of arm; posterior cutaneous nerve of forearm; the continuation of the radial nerve into forearm is wholly cutaneous (for back of hand and digits).

2. **Articular** filaments to the capsule of elbow-joint arise as it crosses the joint and are contained also in the branch to brachialis.

3. **Muscular** to:—the three heads of triceps; brachialis; brachio-radialis; extensor carpi radialis longus; anconeus.

Some branches to the long and medial heads of triceps arise in axilla. Others arise in spiral groove, and one of them to the medial head accompanies the ulnar nerve in the distal part of upper arm. The branch to anconeus also arises in the spiral groove, and it descends through the medial head of triceps. The other muscular branches arise in the front of the limb; and the branch to brachialis supplies only its lower lateral part, for nearly the whole muscle is supplied by the musculo-cutaneous.

4. **Posterior interosseous nerve** passes to the back of forearm, supplies muscles there and ends in the wrist-joint and the joints of the carpus.

Cubital Fossa

Triangular hollow on the front of the elbow. **Base:** line between epicondyles. **Lateral boundary:** brachio-radialis. **Medial boundary:** pronator teres. **Apex:** where these muscles cross each other.

Roof: (1) skin; (2) superficial fascia containing the median cubital vein, lateral cutaneous nerve of forearm and anterior branch of medial cutaneous nerve of forearm; (3) deep fascia, which

includes bicipital aponeurosis and is pierced by a vein that connects superficial and deep veins.

Floor: brachialis above and medially; supinator below and laterally.

Contents: brachial, radial and ulnar arteries and their venæ comitantes; median nerve; tendon of biceps; fat.

Tendon of biceps lies laterally, and leaves the space by passing backwards between the muscles of the floor. *Median nerve* lies medially, and leaves between the heads of pronator teres. *Brachial artery* lies between the tendon and the nerve, and ends, anteromedial to the neck of the radius, by dividing into radial and ulnar. *Ulnar artery* passes under cover of pronator teres. *Radial artery* runs to the apex to be overlapped by brachio-radialis.

When the boundaries are pulled apart, other structures, not properly within the fossa, come into view. *Radial nerve* is seen deeply, on the front of the anterior ligament of the elbow between brachialis and extensor carpi radialis longus, and then descending under cover of the brachio-radialis. Immediately above the elbow-joint, it gives off the *posterior interosseous nerve*. That nerve descends over the front of the elbow-joint, supplies extensor carpi radialis brevis and supinator, and then sinks into supinator. *Recurrent branch of radial artery* ascends on supinator, between the radial and posterior interosseous nerves, to anastomose with the anterior branch of profunda, which accompanies the radial nerve. Towards the ulnar side, the *anterior ulnar recurrent artery* ascends over brachialis, under cover of pronator teres, to anastomose with the anterior branch of the supratrochlear artery.

Shoulder-Joint.—*See* p. 131.

FRONT AND MEDIAL SIDE OF FOREARM

Extends from the elbow to the distal crease at wrist.

Landmarks to be Identified in the Living Limb.—Epicondyles of humerus; ulnar nerve behind medial epicondyle. Tendon of biceps. Coronoid process. Pisiform bone and tendon of flexor carpi ulnaris above it. Tendons of palmaris longus and flexor carpi radialis in the middle above the wrist. Anterior border of distal end of radius. Tubercle of scaphoid.

Superficial Fascia.—Contains:—1. Variable quantity of *fat*.

2. Small unnamed *arteries* that come through the deep fascia from the deep arteries.

3. Network of veins in which the chief channels are the *basilic* and *cephalic veins* and sometimes a *median vein*.

4. *Lymph-vessels*.

5. *Cutaneous nerves*.

Cephalic Vein.—Easily seen through the skin in the living limb. Begins on the back of the hand at the radial end of the dorsal venous arch (also easily seen) by the union of that arch and two dorsal digital veins from the thumb. Passes obliquely from back of hand to front of forearm and ascends to the front of the elbow, where it enters the upper arm.

Basilic Vein.—Also easily seen. Begins at the medial end of dorsal venous arch by the union of that arch and the dorsal digital vein from the medial side of little finger. Ascends along the medial side of forearm, often as two vessels that unite below the elbow. Near the elbow, it inclines forwards to enter the upper arm in front of the medial epicondyle.

Median Vein.—Not always present (examine your own forearm). Begins by the union of small unnamed veins at the middle of the front of the wrist and runs up to the cubital fossa. There, it sends a wide branch through the deep fascia to connect it with the venæ comitantes of brachial artery; and then it divides into two:—(*a*) *Median cephalic* runs upwards and laterally in front of lateral cutaneous nerve of forearm and joins the cephalic vein. (*b*) *Median basilic vein* takes the place of the median cubital; it runs upwards and medially across the bicipital aponeurosis opposite the brachial artery, in front of the anterior branch of medial cutaneous nerve of forearm, and joins basilic vein.

Lymph-Vessels.—A few from the medial side end in supra-trochlear glands (p. 179); all the others of forearm ascend through the upper arm to glands in the axilla.

Medial cutaneous nerve of forearm (p. 179), by its anterior branch, supplies skin of medial part of front of forearm.

Lateral Cutaneous Nerve of Forearm.—The continuation of musculo-cutaneous. Begins where that nerve pierces the deep fascia at the lateral side of biceps tendon above the elbow. Passes behind cephalic vein and divides into *anterior* and *posterior branches* which supply the skin on front and back of the lateral part of forearm, the anterior branch reaching the ball of the thumb.

Deep Fascia.—Strong and dense except inferiorly, and strengthened at the medial side superiorly by the bicipital aponeurosis. Continuous with the fascia of upper arm and with the fascia of the wrist, where the deep fascia is greatly thickened to form a strong transverse band called the *flexor retinaculum*. In the upper part, muscles take partial origin from the deep fascia; and it sends in septa among them from which also they take origin.

Muscles of Front of Forearm.—*Superficial*:—Pronator teres, flexor carpi radialis, palmaris longus and flexor carpi ulnaris—in that order from lateral to medial side.

Middle:—Flexor digitorum sublimis.

Deep:—Flexor digitorum profundus, medially; flexor pollicis longus, laterally; and pronator quadratus, behind them above the wrist.

Pronator teres lies obliquely across the upper part of forearm, forming the medial boundary of cubital fossa.

Origin: *Humeral head* (fl.-tend.), chiefly from upper part of front of medial epicondyle. *Ulnar head*, from medial margin of coronoid process by a tendinous slip

which joins the deep surface of the muscle. Median nerve passes between the two heads; ulnar artery is behind both heads.

Insertion (tend.): rough mark on the middle of lateral surface of radius. It is crossed near insertion by radial extensors, brachio-radialis, and radial vessels.

Nerve: median (from c. 6).

It flexes and pronates forearm.

Common Flexor Tendon.—Flexor carpi radialis, palmaris longus, flexor carpi ulnaris, and flexor digitorum sublimis arise partly by a common *tendon* attached to the distal part of the anterior surface of medial epicondyle. They arise also from the investing *fascia* and the *septa* between them.

Flexor carpi radialis.—Along middle of front of forearm.

Origin: chiefly medial epicondyle.

Its tendon is a landmark in the middle of the distal part of the front of forearm. Having reached the hand, it traverses the groove on trapezium, piercing attachment of flexor retinaculum, and is **inserted** chiefly into the front of base of second metacarpal.

Nerve: median (from c. 6).

It flexes and abducts hand; slightly flexes and pronates forearm.

Palmaris longus lies along ulnar side of flexor carpi radialis. Both tendons are clearly seen, side by side, above the wrist.

Origin: chiefly medial epicondyle.

Insertion: by long tendon into apex of palmar aponeurosis and into the flexor retinaculum.

Nerve: median (from c. 7, 8, t. 1).

It flexes wrist, tightens palmar aponeurosis, slightly flexes elbow.

Flexor carpi ulnaris lies along ulnar side of forearm.

Origin: *Humeral head*: chiefly medial epicondyle. *Ulnar head*: by fleshy fibres from the medial side of olecranon; and by a wide aponeurosis from the upper three-fifths of the posterior margin of ulna. Ulnar nerve enters forearm between the two heads.

Insertion: by tendon attached to pisiform and continued from there by two strong bands—*piso-hamate* and *piso-metacarpal ligaments*—to the hook of hamatum and base of fifth metacarpal.

Ulnar vessels and nerve lie under cover of the deep fascia on its radial side in the distal part of forearm.

Nerve: ulnar (from c. 8, t. 1).

Flexor and adductor of wrist; slight flexor of elbow.

Flexor digitorum sublimis is partly hidden between superficial and deep muscles.

Origin: *Humeral head* (tend.), chiefly from medial epicondyle. *Radial head* (fl.-tend.), from upper two-thirds of anterior margin of radius.

Radial vessels cross radial origin; ulnar vessels, at first behind it, come to lie along its ulnar border in distal part of forearm, together with ulnar nerve; median nerve is behind it (and adherent to it), except near wrist, where the nerve curves round its lateral side and comes to lie in front of its tendons behind flexor carpi radialis and palmaris longus. At the wrist the tendons for middle finger and ring-finger lie in front of the other two; and they all lie behind the flexor retinaculum in front of flexor profundus.

Tendons diverge from one another in the palm. Each enters fibrous flexor sheath of a finger; is split to transmit tendon of profundus; and, after partial reunion, it divides again to be **inserted** into the margins of a middle phalanx.

Nerve: median (from c. 7, 8, t. 1).

It flexes middle and proximal phalanges and wrist (and the elbow slightly).

Flexor digitorum profundus lies on the front and medial side of ulna, deep to flexor sublimis and flexor carpi ulnaris.

Origin (fl.): upper two-thirds of anterior and medial surfaces of ulna, including medial sides of coronoid process and olecranon, interosseous membrane. The part that arises from the medial surface of ulna forms the muscular mass felt at the medial side of ulna on back of forearm, and is more easily found on the back, for, there, it is covered only by the aponeurosis of flexor ulnaris.

It ends in four tendons. Each enters fibrous flexor sheath of a finger behind a tendon of sublimis, perforates that tendon, and runs on to **insertion** into the palmar surface of the base of a distal phalanx.

Nerves: anterior interosseous of median (C. 7, 8, T. 1), to lateral half; ulnar (C. 8, T. 1), to medial half.

It flexes all three phalanges and wrist.

Lumbricales are four slender muscles connected with tendons of flexor profundus in palm (*see* p. 200).

Flexor pollicis longus lies on radius, behind sublimis.

Origin (fl.): upper three-fourths of anterior surface of radius. Its tendon passes through carpal tunnel, enters palm, and turns towards thumb, enters fibrous flexor sheath, and is **inserted** into the palmar surface of the base of distal phalanx of thumb.

Nerve: anterior interosseous of median (C. 7, 8, T. 1).

It flexes phalanges, metacarpal, and wrist.

Synovial Sheaths.—**Three synovial sheaths** enclose the flexor tendons at the wrist and extend for an inch or more into the forearm:—One for **flexor carpi radialis,** another for **flexor pollicis longus**; these two ensheath the tendons as far as the insertion. The third encloses **flexor sublimis** and **profundus.** Its medial part is continued to the insertion of the tendons of the little finger. It is prolonged on the tendons of the other three fingers only as far as the middle of the palm. Separate sheaths enclose the distal parts of these tendons. (*See also* p. 200.)

Pronator quadratus lies at distal end of forearm, behind flexor tendons and sheaths, median nerve, radial vessels.

Origin (fl.): distal quarter of anterior surface of ulna.

Insertion (fl.): distal quarter of anterior surface of radius and triangular area on medial side of radius in front of interosseous membrane.

Nerve: anterior interosseous (C. 7, 8, T. 1).

It pronates forearm.

Deep Vessels and Nerves.—Radial and ulnar arteries and their branches; companion veins; radial, ulnar and median nerves, and the posterior interosseous nerve for a short part of its course.

Radial Artery.—A terminal branch of brachial. Narrower than ulnar, but more in line with the brachial. Begins in cubital fossa at the medial side of biceps tendon antero-medial to the neck of the radius. Runs downwards and in a slightly lateral direction to the front of the distal end of radius, where it turns sidewards and backwards and leaves the forearm to reach the back of the hand by passing over the lateral ligament of the wrist-joint under cover of the tendons of abductor pollicis longus and extensor pollicis brevis.

Relations.—A vena comitans on each side. Covered only with skin and fasciæ in cubital fossa between pronator teres and brachio-

radialis. Leaves the fossa through its apex and is overlapped by brachio-radialis for a variable distance below that; then, covered with skin and fasciæ in the distal half or third of forearm between flexor carpi radialis and brachio-radialis. Radial nerve is only a little lateral to it in the middle third of forearm. The artery lies on tendon of biceps, supinator (separated by fat), pronator teres near its insertion, radial head of flexor sublimis, flexor pollicis longus, pronator quadratus and distal end of radius.

Branches in Forearm.—1. Numerous small unnamed *muscular.* 2. Radial recurrent. 3. Superficial palmar. 4. Anterior carpal.

Radial Recurrent.—Arises in cubital fossa. Runs to the front of lateral epicondyle to anastomose with the anterior branch of profunda.

Superficial Palmar.—Arises near the wrist-joint and descends on to the muscles of the ball of the thumb. When small, it ends in branches to them; when bigger, it also forms the lateral part of the superficial palmar arch.

Anterior Carpal.—Very small. Arises near the wrist-joint and runs medially on the front of the distal end of radius.

Ulnar Artery.—The other and wider terminal branch of brachial. Begins in the cubital fossa at the medial side of biceps tendon antero-medial to the neck of the radius. Leaves the cubital fossa almost at once by descending behind pronator teres. Runs downwards and slightly in a medial direction in the upper third of forearm and then straight down to the wrist. At the wrist, it pierces the deep fascia and descends on to the front of the flexor retinaculum, where it ends by dividing into a *deep branch* and the *superficial palmar arch.*

Relations.—A vena comitans on each side. Ulnar nerve, having come from the back of the medial epicondyle, gradually approaches it in the upper third of forearm, and then runs down close along its medial side. Median nerve, at its medial side at its origin, crosses in front of it medio-laterally as they leave the fossa, but is separated by the ulnar head of pronator teres because the nerve passes between the two heads of the muscle. Palmar cutaneous branch of ulnar nerve descends over the anterior surface of the artery in the distal third of forearm.

It lies on brachialis in the cubital fossa, and then on flexor profundus till it passes on to the flexor retinaculum.

In most of its course, it is hidden behind pronator teres, flexor carpi radialis, palmaris longus, and (most of all) flexor sublimis; but in the distal third, it is covered only by skin and fasciæ between sublimis and flexor carpi ulnaris.

Branches.—1. Small, unnamed *muscular.* 2 and 3. Anterior and posterior ulnar recurrent. 4. Common interosseous. 5 and 6. Anterior and posterior carpal.

Recurrent branches arise just below cubital fossa (sometimes by a common stem) and run to the front and back of the medial epicondyle, where the *anterior* anastomoses with the anterior branch

of supratrochlear, and the *posterior* with the posterior branch of supratrochlear and with the ulnar collateral (p. 183).

Anterior carpal, very small, curves backwards round the medial margin of flexor profundus and turns laterally over the front of the distal end of radius to anastomose with the anterior carpal of radial, with which it forms the *anterior carpal arch.*

Posterior carpal, rather bigger, curves backwards above pisiform bone behind flexor carpi ulnaris and reaches the back of the carpus, where it forms part of the *posterior carpal arch.*

Common Interosseous Artery.—Short and wide—the widest branch of ulnar. Arises a little below the recurrents, behind flexor sublimis. Runs downwards and backwards in the fat on the upper end of profundus towards the upper border of the interosseous membrane; and ends near it by dividing into the anterior and posterior interosseous.

Posterior interosseous passes backwards above the membrane to the back of forearm (p. 209).

Anterior interosseous runs downwards over the front of the interosseous membrane between flexor profundus and flexor pollicis longus, behind sublimis, accompanied by venæ comitantes and anterior interosseous nerve. Slips under the upper border of pronator quadratus, pierces the interosseous membrane, and descends in the distal part of the *back* of forearm to the wrist.

Branches.—1. *Muscular.* 2. *Nutrient* to radius and to ulna. 3. *Median*—long and very slender—accompanies the median nerve. 4. *Communicating* branch descends behind pronator quadratus to join the anterior carpal arch.

Posterior Interosseous Nerve.—Arises from the radial a little above the capitulum of humerus and soon leaves the front of the limb. Runs downwards alongside the radial nerve over the front of the capsule of the elbow-joint behind brachio-radialis. Gives a branch to the supinator muscle and another to extensor carpi radialis brevis, and then passes through the supinator to the back of the forearm.

Radial Nerve.—Leaves the front of elbow-joint and enters the forearm.

Runs downwards behind brachio-radialis over the supinator and over the anterior borders of extensor carpi radialis longus and brevis a little lateral to the radial vessels. When it reaches the distal third of forearm, it inclines backwards across extensor longus and escapes from under cover of brachio-radialis. It then descends over abductor pollicis longus and extensor pollicis brevis, pierces the deep fascia and passes on to the extensor retinaculum at the lateral side of the distal end of radius, where it breaks up into diverging branches that supply skin of the lateral two-thirds of the back of the hand and part of the back of corresponding digits.

It gives *articular twigs to the elbow-joint*; but it gives off no other branches in the forearm until it terminates.

At the distal end of radius, it can be rolled under the finger.

Median Nerve.—Passes from the upper arm into the cubital fossa, where it is in the fat behind the deep fascia and bicipital

aponeurosis on the front of brachialis at the medial side of the brachial and ulnar vessels.

Leaving the fossa, it passes between the heads of pronator teres, crossing the ulnar vessels from medial to lateral side but separated from them by the ulnar head of pronator teres.

It then runs downwards through the middle of forearm in company with the median artery, in front of flexor profundus and behind sublimis, adhering closely to the back of sublimis.

About an inch above the distal crease of the wrist, it passes from behind sublimis and curves round its lateral side on to the front of its tendons behind flexor carpi radialis and palmaris longus.

It then descends into the hand immediately behind the flexor retinaculum and ends near its distal border by dividing into two terminal branches—a *lateral* and a *medial*.

Branches in Forearm.—1. **Muscular** branches arise from its medial side in cubital fossa and proceed directly to *four* muscles—pronator teres, flexor carpi radialis, palmaris longus and flexor digitorum sublimis.

2. **Articular** filaments from the muscular branches pass to the capsule of elbow-joint.

3. **Anterior interosseous,** to the three deep muscles and to joints at the wrist.

4. **Palmar cutaneous** arises near the wrist (p. 194).

Anterior Interosseous Nerve.—Arises just after the median nerve has passed between the heads of pronator teres. Inclines backwards with the common interosseous artery to reach interosseous membrane, runs down over it superficial to the anterior interosseous vessels, between flexor profundus and flexor pollicis longus, behind sublimis and pronator quadratus. Ends in **articular** branches to the capsule of the inferior radio-ulnar joint and the anterior ligaments of the wrist-joint and intercarpal joints.

On its way down, it gives **muscular** branches to the three deep muscles—flexor pollicis longus, lateral half of flexor profundus, and the pronator quadratus.

Ulnar Nerve.—Passes from the back of the medial epicondyle on to the medial ligament of elbow-joint; there, it enters the forearm between the humeral and ulnar heads of flexor carpi ulnaris, and, in a thin limb, can be rolled between the finger and the tubercle on the medial margin of coronoid process.

Descends opposite a line drawn from the medial epicondyle to the lateral side of pisiform bone, lying on profundus, hidden by sublimis and flexor carpi ulnaris till it approaches the wrist, where it lies between their tendons close by ulnaris behind fasciæ and skin. Here, it leaves flexor profundus, pierces the deep fascia and enters the hand by passing on to the front of the flexor retinaculum; and it ends on the retinaculum in two terminal branches—*superficial* and *deep*. The ulnar vessels gradually approach the nerve in the upper third of forearm, and then lie close along its lateral side.

Branches in Forearm.—1. **Articular** twigs to the capsule of elbow-joint arise as it lies on the medial ligament between medial epicondyle and olecranon.

2. **Muscular** branch for flexor carpi ulnaris arises at the same place; and a branch to the medial half of flexor profundus arises an inch lower down.

3. **Cutaneous** branches arise in distal third of forearm :—*palmar cutaneous* to medial part of palm; *dorsal cutaneous* to medial part of back of hand and corresponding fingers (pp. 194, 204).

FRONT OF HAND

Hand includes wrist, hand proper (palm and back) and digits. The anatomical wrist or carpus is not the same as the " wrist " of common speech : it is the inch below the distal crease of the wrist; and, on the surface, it is not marked off from the hand proper.

Surface Anatomy.—**Thenar eminence** is the ball of the thumb, and is produced by three of the short muscles of the thumb. **Hypothenar eminence** is the ball of the little finger, and is produced by its three short muscles. The **hollow of the palm** is between and below the eminences. The knob at the upper end of hypothenar eminence is the **pisiform ;** the tendon descending to it is the **flexor carpi ulnaris. Hook of os hamatum** can be felt, by deep pressure, distal to the pisiform and more to the radial side.

Two tendons which descend to the middle of the wrist are **flexor carpi radialis** and **palmaris longus :** palmaris is the medial of the two and may be absent. The tendon which can be felt, and may rise into view on the ulnar side of palmaris when fingers and wrist are flexed, is the **tendon of flexor sublimis** for the **ring-finger ; ulnar vessels** and **nerve** lie between it and flexor carpi ulnaris.

Tubercle of scaphoid is felt above the thenar eminence, in the angle between it and flexor carpi radialis. A line, concave towards the forearm, drawn between the pisiform and the tubercle of scaphoid, indicates the position of the upper margin of the **flexor retinaculum. Crest of trapezium** is felt immediately below the tubercle, and the two may form one prominence, seen and felt best when the hand is dorsiflexed.

Radial artery is felt beating on the front of the distal end of the radius; its **superficial palmar** branch runs across the wrist-joint towards the ulnar side of the ball of the thumb, and may be large enough to be seen beating.

Line of metacarpo-phalangeal joints is nearly opposite the most distal crease on the palm, about half an inch above the crease at the roots of the fingers. The **webs of fingers** are formed by the skin between the phalanges.

First interphalangeal joint is opposite the uppermost of the two or three creases near the middle of each finger. **Second inter-**

phalangeal joint is immediately beyond the creases near the end of the finger.

Superficial Fascia.—Thin and dense over the middle of the palm, and the fat is divided into fine lobules by septa that connect the skin to the deep fascia. It is more fatty and less fibrous near the margins of the palm and on the digits; and at the free ends of the digits it is thickened to form the pulp of the finger-tips.

On the digits, it contains digital vessels and nerves. In the palm it contains:—1. Cutaneous nerves; 2. unnamed cutaneous vessels; 3. palmaris brevis; 4. superficial transverse ligament:—

Terminal twigs of the **lateral cutaneous nerve of forearm** supply skin over the proximal part of the thenar eminence, and twigs from the **radial nerve** supply its radial part.

Palmar cutaneous branch of median nerve arises near wrist, appears between flexor carpi radialis and palmaris longus, pierces the deep fascia immediately above the wrist, crosses superficial to the flexor retinaculum, and supplies skin on the lateral and central parts of the palm.

Palmar cutaneous branch of ulnar nerve arises at a variable point in the distal third of the forearm, descends over the ulnar artery, pierces the deep fascia on the radial side of flexor carpi ulnaris near its insertion, crosses the flexor retinaculum, and supplies skin of the medial part of the palm.

Palmaris Brevis.—**Arises** from the front of the flexor retinaculum and the ulnar margin of the palmar aponeurosis; passes medially, superficial to the terminal branches of the ulnar vessels and nerve, to be **inserted** into the skin on the ulnar border of the hand.

Superficial branch of *ulnar nerve* supplies it.

When the fingers bend, the palmaris brevis raises the skin and fascia into a cushion on the upper part of the hypothenar eminence, and enables the hand to take a firmer grasp.

Superficial transverse ligament of palm lies across the roots of the fingers and in the webs near their free edges. In the living hand, it raises a ridge of skin and deepens the cup of the palm when the fingers are abducted from one another and slightly flexed.

Deep Fascia.—Thin over the thenar and hypothenar eminences. The central part, in the hollow of the hand, is thickened and is called the *palmar aponeurosis*. Deep fascia is greatly thickened opposite the wrist-bones, and is called *flexor retinaculum*. It is thickened over fingers to form the *fibrous flexor sheaths*.

Flexor Retinaculum.—Very thick and strong, and "about the size of a postage stamp". It bridges across the concavity of the carpus, converting it into a canal through which the flexor tendons of the fingers and thumb (with their sheaths) and the median nerve pass into the palm. It is continuous *proximally* with the fascia of the forearm, and *distally* with the palmar aponeurosis. It is attached, *on the ulnar side*, to the pisiform and the hook of os hamatum; *on the radial side*, to the tubercle of scaphoid and the front of the trapezium—including both lips of its groove.

It gives partial insertion to palmaris longus; and partial origin

to a number of muscles:—to abductor brevis, flexor brevis and opponens of the thumb; to flexor brevis and opponens of the little finger; and to palmaris brevis. The origins of these muscles cover most of its palmar surface and distal border.

The *palmar surface* is, further, in relation to: (1) Palmaris longus tendon, descending to its insertion into the retinaculum and into the apex of the palmar aponeurosis; (2) palmar cutaneous branch of median, descending along the radial side of the tendon; (3) palmar cutaneous branch of ulnar, along the ulnar side of the tendon; (4) ulnar vessels and nerve, at the radial side of the pisiform; (5) a band of fascia, called the *superficial part of the retinaculum*, passes from the front of it to the pisiform, bridging across the ulnar nerve and, sometimes, across the ulnar vessels also.

The tendon of flexor carpi radialis, with its synovial sheath, traverses the groove on the front of the trapezium between the attachments of the retinaculum to that bone.

Palmar Aponeurosis.—Protects the vessels, nerves and tendons that lie deep to it. It is triangular in shape.

Apex is attached to the flexor retinaculum, and receives part of the insertion of palmaris longus. **Base** divides, opposite the heads of the metacarpals, into four slips. These are connected with each other by *transverse fibres*; and between the slips the digital vessels and nerves and the lumbricals are seen. A few superficial fibres of each slip run on to be attached to the skin of the creases at the two interphalangeal joints. Remainder divides into two parts, which diverge and pass backwards to be attached to the deep transverse lig. These two diverging parts form an arch beneath which the flexor tendons pass into the fibrous flexor sheath, and the distal edge of the arch is continuous with the proximal end of the fibrous flexor sheath.

The **margins** of the aponeurosis are connected with the fascia over thenar and hypothenar eminences, and they send *septa* backwards to be connected with the fascia that covers the adductor pollicis, the interossei and the deep palmar arch. These septa divide the palm into three compartments: a lateral, occupied by muscles of the thumb; a medial, occupied by hypothenar muscles; an intermediate, occupied by (1) the superficial palmar arch and its branches, (2) branches of the median nerve, (3) the tendons of flexor sublimis and profundus, with their sheaths and the lumbricals.

Fibrous Flexor Sheaths.—Attached to the margins of the proximal and middle phalanges of each finger, and the proximal phalanx of the thumb, and to the margins of the palmar ligaments of the joints of each digit; their distal ends are attached to the terminal phalanges beyond the insertion of the flexor tendons. Together with the phalanges and ligaments, each forms a tube occupied by flexor tendons and their synovial sheaths. Each is dense opposite the phalanges; but it is thin opposite the joints, in order that movements may not be impeded.

The palmar ligaments and deep transverse ligaments, mentioned above, are connected with the joints.

Palmar lig. is a dense fibrous plate which is attached firmly to the front of the base of the proximal phalanx, and loosely to the

metacarpal immediately above its head. Its *dorsal surface* is in contact with the head of the metacarpal and forms part of its socket; its *palmar surface* is grooved by the passage of flexor tendons; its *margins* are connected with the fibrous flexor sheaths and the slips of palmar aponeurosis, with the collateral ligs. of the joint and with the deep transverse lig.

Interphalangeal joints have similar palmar ligaments.

Deep transverse ligament of palm consists of three flat bands that connect the margins of the palmar ligaments of the metacarpo-phalangeal joints of the four fingers. Digital vessels and nerves and lumbrical muscles lie on their *palmar surfaces*, interosseous muscles on their *dorsal surfaces*.

SHORT MUSCLES OF THUMB.—Two groups of these:—

(A) The abductor pollicis brevis, flexor pollicis brevis, and opponens pollicis, which form the thenar eminence and lie on the radial side of flexor pollicis longus tendon. Lateral division of *median nerve* supplies them by fibres derived ultimately from 6th and 7th cervical nerves (and possibly C. 8, T. 1).

(B) The two heads of adductor pollicis, which lie on the ulnar side of flexor pollicis longus tendon. *Deep branch of ulnar* supplies them by fibres derived from C. 8, T. 1.

Abductor Pollicis Brevis.—Superficial, in the radial part of the thenar eminence. It **arises** by fleshy fibres from the tubercle of scaphoid, the crest on the front of the trapezium, and the flexor retinaculum. It is **inserted** by tendon into the radial side of the base of the proximal phalanx of the thumb. It abducts at the carpo-metacarpal joint, and slightly flexes the proximal phalanx.

Flexor Pollicis Brevis.—Superficial, in the ulnar part of the thenar eminence. It **arises** by fleshy and tendinous fibres from the distal border of the flexor retinaculum, and often from the crest of the trapezium. It is **inserted** by tendon into the proximal phalanx in company with the abductor. It flexes the proximal phalanx and the metacarpal.

Opponens Pollicis.—Under cover of the preceding two. It **arises** by fleshy and tendinous fibres from the flexor retinaculum and the crest of the trapezium. It is **inserted** by fleshy and tendinous fibres into the radial border and the radial half of the palmar surface of the metacarpal of the thumb. It flexes the metacarpal and rotates it medially.

Adductor Pollicis.—Lies deeply in the radial half of the palm, and has two fleshy heads between which the radial artery runs medially.

(*a*) **Oblique head arises** from the palmar surfaces of the carpus and base of metacarpus and their ligaments, and from the fibrous sheath of flexor carpi radialis tendon.

(*b*) **Transverse head arises** from the shaft of the third metacarpal and the fascia over the interossei in the second and third spaces.

The heads join each other and are **inserted** by tendon into the ulnar side of the base of the proximal phalanx of the thumb, and often into the radial side of the base of that phalanx by a separate slip which crosses behind the tendon of flexor pollicis longus.

They draw the thumb and its metacarpal towards the palm.

Sesamoid bones are developed in the tendons of insertion of the

adductor and flexor brevis. They replace the palmar ligament of metacarpo-phalangeal joint of the thumb, and articulate with the palmar surface of the head of the metacarpal.

SHORT MUSCLES OF LITTLE FINGER.—The abductor, the flexor and the opponens; and they form the hypothenar eminence. *Deep branch of ulnar nerve* supplies them by fibres derived from C. 8, T. 1.

Abductor Digiti Minimi.—Superficial, in the ulnar part of the hypothenar eminence. It **arises** by fleshy fibres chiefly from the pisiform; and is **inserted** by tendon into the ulnar side of the base of the proximal phalanx of the little finger, which it abducts and slightly flexes.

Flexor Digiti Minimi.—Superficial, in the radial part of the hypothenar eminence, and may be fused with the abductor or the opponens. It **arises** by fleshy and tendinous fibres from the flexor retinaculum and the hook of hamatum, and is **inserted** in common with the abductor.

Opponens Digiti Minimi.—Placed under cover of preceding two. It **arises** by fleshy and tendinous fibres from the flexor retinaculum and the hook of os hamatum; and is **inserted** by fleshy fibres into the ulnar border and the ulnar half of the palmar surface of the fifth metacarpal, which it draws forwards and turns towards the radial side.

Ulnar Artery.—Leaves the anterior surface of flexor profundus at the wrist; passes on to the front of the flexor retinaculum; and ends on it by dividing into a deep and a superficial branch at the level of the distal part of the pisiform bone. The ulnar nerve lies between it and the pisiform; and the artery may be either behind or in front of the superficial slip of the retinaculum.

Superficial branch becomes the superficial palmar arch at once.

Deep branch, in company with the deep branch of ulnar nerve, passes first downwards over the piso-hamate lig., and then backwards and downwards between abductor and flexor digiti minimi, then laterally under cover of the flexor and opponens, or between the two, or through opponens, and joins the ulnar end of the deep palmar arch.

Superficial Palmar Arch.—Formed by the superficial branch of the ulnar artery, and is completed on the radial side by the superficial palmar branch of the radial, or by the princeps pollicis or radialis indicis. It first descends over the piso-hamate lig. and the hook of the os hamatum, and then curves laterally to reach the medial and lower part of the ball of the thumb.

It is accompanied by *venæ comitantes*. **Superficial to it,** there are palmaris brevis, palmar aponeurosis, palmar cutaneous branches of median and ulnar nerves. **Deep to it,** there are the piso-hamate lig., the hook of the os hamatum, the flexor and opponens digiti minimi; digital branches of median nerve; the tendons of flexor digitorum sublimis and profundus, and the lumbricals.

Its course may be mapped out by a line drawn from the radial side of the pisiform towards the ring finger as far as the level of the lower border of the outstretched thumb, then turned sidewards, and

finally a little upwards, to end at the thenar eminence, in line with the radial side of the middle finger.

Branches of Superficial Palmar Arch.—(1) Small branches to skin and neighbouring muscles.

2. **Four palmar digital arteries,** of which the first runs over the flexor digiti minimi to the ulnar side of the little finger. The other three lie in the intervals between long flexor tendons, on the digital nerves and lumbrical muscles, deep to the palmar aponeurosis. Near the web of the fingers, each is joined by a *palmar metacarpal branch* from the deep arch, and by a perforating branch from a dorsal metacarpal, and then divides into two branches which supply contiguous sides of the fingers.

Near the roots of the fingers the arteries cross the nerves, and lie behind them on the sides of the fingers ; they supply the tissues on sides and fronts of fingers, and also on the backs of middle and distal phalanges. They anastomose with small dorsal digital branches of the dorsal metacarpal arteries, and assist them to supply the back of the proximal phalanx ; and terminal branches of the two palmar digital arteries on each finger form arches and plexuses in the bed of the nail and the pulp of the finger.

Median Nerve.—Above the wrist, it curves from the radial side of sublimis tendons on to the front of them ; it then descends behind the flexor retinaculum, enveloped in the synovial sheath ; splits into lateral and medial divisions, which emerge into the palm and send branches downwards behind the superficial palmar arch.

Lateral division gives a branch to supply the three muscles of the thenar eminence, and then divides into three *digital nerves.* Two of the digital nerves run along the ulnar border of flexor pollicis brevis and flexor pollicis longus tendon in front of the adductor, and then separate to pass along the opposite sides of the thumb. The other digital branch descends over the first lumbrical, which it supplies, and runs along the radial side of the index finger.

Medial division divides into two *digital nerves* which descend over the second and third lumbricals, supplying the second always and the third sometimes. They each split into two, and they supply contiguous sides of the index, middle and ring-fingers.

Digital branches of the median nerve supply the sides and front of the thumb, index and middle fingers, and the radial half of the ring-finger ; and also the back of the distal phalanx of the thumb and the middle and distal phalanges of the other two and a half digits. Digital arteries are in front of them in the palm, but are behind them on the sides of the fingers.

Small oval bodies, called *lamellated corpuscles,* are connected with the terminal twigs of nerves on the digits.

The median nerve corresponds to the medial plantar of the foot.

Ulnar Nerve.—Ends, at the ulnar side of the ulnar art., on the flexor retinaculum, close by the lateral side of the pisiform bone under cover of the superficial slip of the retinaculum, by dividing into a superficial and a deep branch.

Superficial branch, passing downwards, slips under cover of the palmaris brevis, and lies first on the piso-hamate ligament and then

on the medial side of the hook of os hamatum near its tip (where it may be rolled by the finger on the hook).

It supplies palmaris brevis; and, while still under its cover, on the hook, it divides into two *digital branches*. One of these accompanies the first digital branch of the superficial arch over flexor brevis, and runs along the ulnar side of the little finger. The other accompanies the digital artery over the fourth lumbrical; communicates with the adjoining digital branch of the median; divides into two branches which run along contiguous sides of the ring-finger and the little finger.

Like the digital branches of the median, they supply the palmar surfaces and sides along the whole length, and the dorsal surfaces over the middle and distal phalanges.

Digital arteries are in front of them in the palm, behind them on the fingers. Lamellated corpuscles are connected with their terminal twigs.

Deep branch runs with the deep branch of the artery—first downwards over the piso-hamate ligament, next backwards between the abductor and flexor, and next in a lateral direction under cover of the flexor and opponens, supplying all three. It then courses sidewards across the palm, deep to the long flexor tendons and lumbricals, on the proximal ends of interossei and on metacarpals near their bases, along the concave or proximal side of the deep palmar arch.

Sends three branches downwards to supply interossei in the spaces between metacarpals of fingers and the third and fourth lumbricals.

Breaks up finally to supply adductor pollicis and the first dorsal and palmar interossei: *i.e.* 14 muscles in all.

Ulnar nerve corresponds to the lateral plantar of the foot.

Tendons of Flexor Digitorum Sublimis.—Lie between the flexor retinaculum and the flexor profundus at the wrist; and those for the middle and ring-fingers are superficial to those for the index and little fingers. Fibres from the radius help to form the tendons to the middle and ring-fingers, but not the other two. In the palm, each tendon runs towards its finger, behind the palmar aponeurosis and superficial arch, in front of the corresponding profundus tendon; and both tendons enter the fibrous flexor sheath opposite the head of the metacarpal. Opposite the proximal phalanx, each sublimis tendon splits to allow profundus tendon to pass through it. Opposite the base of the middle phalanx, the two halves re-unite by their dorsal margins and form a gutter in which the profundus tendon lies; then, after partial decussation, they separate again to be **inserted** into the margins of middle phalanx.

Flexor Digitorum Profundus.—At the wrist, it lies between flexor sublimis and the carpus, on the medial side of flexor pollicis longus. Tendon for index becomes separate some distance above the wrist, and the part of the fleshy belly from which it springs is separable for some distance; this is associated with the more frequent independent use of the index. Tendons for the other three fingers are combined in one flat mass, but separate as they enter the palm.

Tendons give origin to lumbricals in the palm, and run to the fingers, behind the sublimis tendons, in front of the deep palmar arch,

adductor pollicis, interossei and metacarpals. Near the metacarpo-phalangeal joint, each enters the fibrous flexor sheath, passes through the corresponding sublimis tendon opposite the proximal phalanx, and runs on to **insertion** into the palmar surface of the base of the distal phalanx. It flexes the phalanges and the wrist.

Lumbrical Muscles.—Four slender, fusiform muscles which **arise** from the tendons of flexor profundus ; pass downwards between the tendons, deep to digital vessels and nerves ; cross the front of the deep transverse lig. ; end in tendons which pass obliquely backwards on the radial sides of metacarpo-phalangeal joints to be **inserted** mainly into radial sides of extensor tendons of fingers, and partly, by fascial connexion, into the base of the proximal phalanx and the capsule of the joint.

Each flexes the proximal phalanx, since it passes from front to back across the metacarpo-phalangeal joint ; and it extends the other two phalanges, since it is inserted into the extensor tendon.

First arises from the radial side of the tendon to the index. **Second** arises from the radial side of the tendon to the middle finger. **Third** arises from contiguous sides of the tendons for the middle finger and ring-finger. **Fourth** arises from contiguous sides of the tendons for the ring-finger and little finger.

The *median* nerve supplies the first and second on their palmar surface by fibres derived from c. 6 (7)—the *first* being supplied by a twig from the digital branch for the radial side of index, and the *second* from the digital branch for the next cleft. The *deep branch of ulnar* supplies *third* and *fourth* on their dorsal surfaces by fibres derived from c. 8 (t. 1) ; third is sometimes supplied also by the digital branch of the median for the cleft between the middle finger and the ring-finger.

Flexor Pollicis Longus Tendon.—Crosses flexor carpi radialis from lateral to medial side, between it and the wrist-joint ; enters the carpal tunnel ; runs downwards along the radial side of flexor profundus ; enters the palm and turns towards the thumb, crossing the sheath of flexor carpi radialis superficially ; runs between the flexor pollicis brevis and the adductor, enters the fibrous flexor sheath, and is **inserted** into the palmar surface of the base of the distal phalanx of the thumb.

Synovial Sheaths.—Tendons of flexor sublimis and profundus are enclosed in the **common flexor sheath.** It begins in the forearm an inch above the retinaculum. Its medial part is prolonged over the tendons of the little finger as far as their insertion ; but the main part, which envelops the tendons of the other fingers and the proximal parts of the lumbricals, stops at the middle of the palm. A little farther down, the tendons of each of these fingers acquire a new, separate sheath which envelops them as far as their insertion.

Sheath of flexor pollicis longus is separate. It also begins in the forearm an inch above the retinaculum ; and it encloses the tendon as far as its insertion.

Within the fibrous flexor sheath of each digit, near the insertion of a tendon, the synovial sheath is pinched up to form a triangular fold, seen between the tendon and the phalanx when they are pulled

apart. These folds are called **vincula brevia.** At higher levels, slender fibrous cords, with synovial coverings, pass between the tendons and the phalanges. These are called **vincula longa.** Blood-vessels run in the vincula to the tendons.

Synovial sheaths are closed sacs, each having two layers which are continuous with each other. One layer ensheaths the tendon or tendons; the other lines the space in which it lies. On the digits, the sheath lines the fibro-osseous canal and covers the tendons, and the two layers are continuous at the proximal and distal ends, but the connexion between the part on the tendons and that on the phalanges is represented only by the vincula—though in a few instances these form broad sheets like mesenteries. The common sheath of the flexors of the fingers is complicated by the number of tendons. At the wrist, it lines the greater part of the carpal tunnel, and, at the radial side, passes from the carpus and the retinaculum on to the tendons, covering them and dipping in amongst them, and, at the ulnar side, it may be tucked in for a variable distance between the sublimis and profundus groups.

Radial Artery.—Accompanied by venæ comitantes, passes from the back of the hand into the palm through the proximal part of the first intermetacarpal space between the heads of the first dorsal interosseous muscle. In the palm, it runs medially in front of the ulnar head of the first dorsal interosseous muscle, second metacarpal bone and second palmar interosseous muscle, and behind the adductor pollicis. Here, it gives off the *princeps pollicis* and *radialis indicis* arteries, and then passes between the heads of adductor pollicis to become the *deep palmar arch.*

Princeps pollicis artery runs laterally and downwards behind the oblique part of adductor pollicis and flexor pollicis longus; appears between adductor and flexor brevis; divides into two branches which run onwards along the sides of the thumb as its palmar digital arteries.

Radialis indicis artery descends between the transverse head of adductor and the first dorsal interosseous, and along the radial side of the index in company with the digital nerve.

Deep Palmar Arch.—The continuation of the radial artery. Extends from the interval between the transverse and oblique heads of adductor pollicis, across the third and fourth metacarpals immediately below their bases, to reach the base of the fifth, where it is joined by the deep branch of the ulnar. Its level is half an inch higher than the superficial arch. The metacarpals and interossei are behind it. The flexor tendons, their synovial sheath, lumbricals and digital branches of the median nerve are in front of it and separate it from the superficial arch.

Branches.—Recurrent, perforating, palmar metacarpal.

Recurrent branches run upwards over the front of the carpus and wrist-joint, and anastomose with the anterior carpal arch.

Perforating branches pass backwards through the upper parts of the spaces between the metacarpals of the fingers—each between the heads of the corresponding dorsal interosseous muscle—and join the dorsal metacarpal arteries.

Three **palmar metacarpal branches** descend over the interosseous muscles of the medial three spaces, and join digital branches of the superficial arch immediately before their bifurcation.

Interosseous Muscles.—Eight—four palmar and four dorsal.

They are the deepest structures in the palm, and (with the exception of the first dorsal and first palmar) their tendons of insertion pass behind the deep transverse ligaments. Each one (except first palmar) is inserted into the extensor tendon, the base of the proximal phalanx, and the capsule of the metacarpo-phalangeal joint of the finger upon which it acts (compare with lumbricals, p. 200).

Deep branch of ulnar nerve supplies them all by fibres derived from C. 8, T. 1.

The dorsal interossei lie in the intermetacarpal spaces and are seen, therefore, on the back of the hand as well as in the palm.

First palmar interosseous muscle is very slender. Lies between adductor pollicis and first dorsal interosseous. *Arises* from the ulnar side of the base of the thumb metacarpal, and is *inserted* into the ulnar side of the base of the proximal phalanx of the thumb.

The **other three palmar interossei** act on the index, ring and little fingers. Each *arises* by fleshy fibres from the palmar surface of the metacarpal of the finger upon which it acts. **Second** is *inserted* into the ulnar side of the index ; **third,** into the radial side of annularis ; **fourth,** into the radial side of minimus. They adduct these fingers towards the middle finger ; and, besides, each flexes the metacarpo-phalangeal joint and extends interphalangeal joints (cf. lumbricals).

Each **dorsal interosseous** *arises* by two fleshy heads from the adjacent sides of the metacarpals between which it lies. **First** is *inserted* into the radial side of the index ; **second,** into the radial side of medius ; **third,** into the ulnar side of medius ; **fourth,** into the ulnar side of annularis. Like the palmar interossei, each flexes the proximal phalanx and extends the middle and distal phalanges. First and fourth abduct index and annularis from medius. Second and third alternately abduct and adduct medius—*i.e.*, second abducts towards index ; third adducts it to its former position, and, continuing to act, abducts it towards annularis ; and the second then restores it to position.

Each finger, therefore, is provided with an adductor and an abductor. Index, medius and annularis have each two interossei ; minimus has its abductor, and has the fourth palmar interosseous as an adductor.

First dorsal interosseous forms the fleshy mass seen on the back of the hand between the metacarpals of thumb and index ; and its action can be studied readily in the living hand. Radial artery passes between its two heads. Perforating arteries pass between the heads of the others.

Flexor Carpi Radialis Tendon.—As it lies above the wrist, it has the radial artery a little to its radial side, and the median nerve close to its ulnar side, on a deeper plane. It crosses superficial to flexor pollicis longus opposite the wrist-joint, descends over the front of the tubercle of scaphoid, traverses the tunnel formed by the attachment of the flexor retinaculum to both sides of the groove on

the trapezium; and it is **inserted** into the palmar surface of the base of the metacarpal of index, sending a small slip to the base of the third. A prolongation of the retinaculum over it to its insertion is called its *fibrous sheath.*

BACK AND LATERAL SIDE OF FOREARM AND BACK OF HAND

Landmarks to be Identified in the Living Limb.—Epicondyles of humerus. Head of radius; olecranon; posterior border of ulna; styloid process of ulna; head of ulna; dorsal tubercle of radius; styloid process of radius; ridge between lateral and anterior surfaces of distal end of radius. Os triquetrum. Bases of metacarpal bones, felt through the extensor tendons as small, irregular prominences when the hand is bent forwards; metacarpo-phalangeal and interphalangeal joints, immediately *distal to* the knuckles, which are the heads of the metacarpal bones and the heads of the proximal and middle phalanges.

The ridge on the radial border of the wrist, above the ball of the thumb, is produced by the tendons of **abductor pollicis longus** and **extensor pollicis brevis.** When the thumb is abducted and extended a hollow is produced on the radial side of the wrist—the "anatomical snuffbox"—bounded in front by abductor and extensor brevis of thumb, behind by extensor longus of thumb and extensor carpi radialis longus. The scaphoid and trapezium are in its floor. Radial artery crosses it. Branches of the radial nerve can be felt crossing the tendons.

Superficial Fascia.—Contains: 1. A variable quantity of *fat.*

2. Small unnamed *arteries* from the deep arteries.

3. Cutaneous *veins,* drained into the dorsal venous arch and the basilic and cephalic veins.

4. *Lymph-vessels.* 5. *Cutaneous nerves.*

Lymph-vessels pass upwards from the hand and forearm through the upper arm to glands in axilla.

Two **dorsal digital veins** lie along the margins of the back of each digit and are connected by small *venous arches.* Those of the thumb join the beginning of cephalic vein. The radial one of the forefinger joins the dorsal venous arch. The ulnar one of the little finger joins the beginning of basilic vein. The others unite to form three **dorsal metacarpal veins,** which lie in the distal parts of intermetacarpal spaces and end in the dorsal venous arch; they and the arch communicate with the deep veins of the palm by veins that accompany the perforating arteries.

Dorsal venous arch lies across the lower part of the back of the hand. Receives dorsal metacarpal veins and unnamed tributaries. Its ends join the beginnings of the basilic and cephalic veins.

Cutaneous nerves on the back of forearm are: posterior branches of **lateral** and **medial cutaneous nerves of forearm** at the sides; and the **posterior cutaneous nerve of forearm** in the middle (pp. 170, 180, 186).

On the back of the hand and digits, they are: terminal branches

of radial; dorsal branch of ulnar; palmar digital branches of median and ulnar.

Terminal Branches of Radial Nerve.—Begin on the lateral side of the distal end of the radius and spread downwards and backwards to supply the skin of the lateral two-thirds of back of hand and the back of the proximal phalanges of thumb, forefinger, middle finger and radial half of ring-finger.

Dorsal Branch of Ulnar Nerve.—Arises at a varying point in the distal third of front of forearm. Runs downwards at first with the ulnar nerve and then inclines backwards with the posterior carpal branch of ulnar artery over the wrist-joint above pisiform bone behind the flexor carpi ulnaris. It now pierces the deep fascia between flexor and extensor carpi ulnaris, descends over the medial surface of the carpus, and branches to supply skin of the medial part of back of hand and the back of the proximal phalanx of little finger, ring-finger and ulnar half of middle finger—overlapping the distribution of the radial nerve. It may supply only the little finger and half of the ring-finger.

On the medial surface of the wrist, it can be felt and rolled between the finger and os triquetrum.

Palmar digital branches of median and ulnar nerves send branches to supply the skin of the back of the middle and distal phalanges.

Deep Fascia.—Exceedingly thin on the back of the hand, and adherent to the extensor tendons. Dense and strong in the forearm, especially superiorly, where it gives origin to muscles. It sends septa in among the muscles and these also give origin to them and therefore unite the proximal parts of the muscles, each to its neighbours; and it is firmly attached to the posterior border of ulna. At the elbow, it is strengthened by fibres from the tendon of triceps. At the junction with the wrist it is thickened to form the *extensor retinaculum*.

Extensor Retinaculum.—About an inch wide. Much longer than the flexor retinaculum, but not so thick and strong, for dorsiflexion is not so extensive and powerful as flexion, and the extensor tendons are therefore less apt to spring away from the bones. It is higher than the flexor retinaculum, for, though its medial end is in the wrist, its lateral end is in the forearm; it therefore crosses the back of the wrist-joint obliquely. It is crossed near its medial end by the basilic vein, and near its lateral end by the cephalic vein and by the radial nerve and its terminal branches.

Above and *below*, it is continuous with the deep fascia of forearm and hand. Its *lateral end* is on the front of the limb—attached to the ridge between the anterior and lateral surfaces of the distal end of radius. The *medial end* is attached to os triquetrum and the styloid process of ulna.

Besides these connexions, it is attached to the back of the head of ulna and to the ridges on the back of distal end of radius by five septa that spring from its deep surface. These five septa divide the space between it and the bones into *six* compartments which are occupied by tendons and their synovial sheaths. From lateral to medial side, they are :—

1. *Abductor pollicis longus* and *extensor pollicis brevis*, on the lateral surface of radius.

2. *Extensor carpi radialis longus* and *brevis*, in the lateral wide groove on the back of radius.

3. *Extensor pollicis longus*, in the narrow groove at the medial side of dorsal tubercle.

4. *Extensor digitorum* and *extensor indicis*, in the medial wide groove on radius.

5. *Extensor digiti minimi*, between radius and ulna.

6. *Extensor carpi ulnaris*, in the groove between head and styloid process of ulna.

They should be identified in the living limb.

Synovial Sheaths.—Extensor digitorum and extensor indicis are in the same sheath. The other tendons usually have a sheath each, but the tendons in No. 1 may be in the same sheath and so may the tendons in No. 2.

The sheaths begin at the upper border of the retinaculum or just above it. They reach the end of the tendons inserted into metacarpal bones, but only half-way down the hand around those inserted into phalanges.

Muscles of Lateral Side and of Back of Forearm.—*Superficial* :—From lateral to medial side—brachio-radialis, extensor carpi radialis longus and brevis, extensor digitorum, extensor digiti minimi, extensor carpi ulnaris, anconeus—seven in all.

Deep :—Five. From above downwards—supinator, abductor pollicis longus, extensor pollicis brevis and longus, extensor indicis. The three muscles of the thumb become superficial in the lower part of the forearm.

Brachio-radialis lies on radial side of forearm anteriorly and forms the lateral boundary of cubital fossa.

Origin (fl.) : front of upper two-thirds of lateral supracondylar ridge and lateral intermuscular septum.

Insertion: by tendon into upper part of lateral surface of distal end of radius, under cover of tendons of abductor longus and extensor brevis pollicis.

Nerve: radial (c. 5, 6).

It flexes forearm; initiates supination and pronation.

Extensor carpi radialis longus lies on radial border of forearm behind brachio-radialis.

Origin (fl.) : front of lower third of lateral supracondylar ridge and lateral intermuscular septum.

Its tendon is crossed by abductor longus and extensors of thumb, and passes under extensor retinaculum.

Inserted into base of second metacarpal.

Nerve: radial (c. 6, 7).

It extends and abducts hand, and slightly flexes elbow.

Common Extensor Tendon.—Extensores carpi radialis brevis, digitorum, digiti minimi and carpi ulnaris arise partly by a common *tendon* attached to the lower part of the front of lateral epicondyle. They arise also from the investing *fascia* and the *septa* between them.

Extensor carpi radialis brevis lies on radial side and back of forearm. **Origin:** chiefly from lateral epicondyle.

Its tendon runs along ulnar side of longus and is **inserted** into base of third metacarpal.

Nerve: posterior interosseous (c. 6, 7).

It extends and slightly abducts hand.

Extensor digitorum lies on back of forearm towards radial side. **Origin:** chiefly from lateral epicondyle.

Its tendon passes under the extensor retinaculum and divides into four tendons which run to the fingers, and each is **inserted** into bases of middle and distal phalanges.

Nerve: posterior interosseous (c. 6, 7, 8).

It extends phalanges and hand.

Extensor digitorum breaks up into tendons at the distal end of radius. On the back of the hand, the diverging tendons are connected by bands; and the tendon for the little finger may not separate till near the head of the metacarpal.

On the back of the proximal phalanx, each tendon broadens out to form the **extensor expansion,** which is joined at the sides by the tendons of interossei and a lumbrical.

At the distal end of the phalanx it splits into three. Middle piece is inserted into the dorsum of the base of the middle phalanx. The two outlying pieces are composed almost wholly of the tendons of interossei and the lumbrical; they run on, join each other, and are inserted into the dorsum of the base of the distal phalanx.

The tendons take the place of the capsular lig. on the dorsum of metacarpo-phalangeal and interphalangeal joints.

Extensor digiti minimi lies along the middle of the back of forearm, close to the medial margin of extensor digitorum.

Origin: chiefly from lateral epicondyle.

Its tendon passes under the extensor retinaculum between radius and ulna; and it is **inserted** in common with the tendon from extensor digitorum to little finger. The tendon divides into two slips which re-unite at the head of the metacarpal after the tendon from digitorum has joined the radial slip.

Nerve and action: same as preceding muscle.

Extensor carpi ulnaris lies along radial side of posterior margin of ulna. **Origin**: chiefly from lateral epicondyle.

Its tendon passes through the most medial compartment of extensor retinaculum, and is **inserted** into base of 5th metacarpal.

Nerve: posterior interosseous (c. 6, 7, 8).

It extends and adducts hand.

Anconeus.—Small and triangular. Lies on radial part of back of elbow.

Origin (tend.): distal part of back of lateral epicondyle.

Insertion (fl.): lateral surface of olecranon and a triangular area on proximal quarter of posterior surface of the shaft of ulna.

Nerve: radial (c. 7, 8) and, sometimes, posterior interosseous.

It extends forearm.

Supinator surrounds upper third of radius, and forms the infero-lateral part of floor of cubital fossa.

Origin (fl. tend.): supinator crest and the floor of supinator fossa of ulna.

Fibres curve round behind radius and are **inserted** into the back, lateral side and front of its upper third.

Nerve: posterior interosseous (c. 6), which, after supplying it, traverses it and divides it into two laminæ.

Abductor pollicis longus lies *deeply* in middle third of forearm, *superficially* on back and radial side of lower third.

Origin (fl.): uppermost of the three narrow impressions on lateral half of posterior surface of ulna; middle third of posterior surface of radius; interosseous membrane.

It crosses the two radial extensors of the carpus. Its tendon passes through the most lateral compartment of extensor retinaculum over the insertion of brachioradialis; it crosses radial artery and is **inserted** into base of first metacarpal.

Nerve: posterior interosseous (c. 6).

It draws metacarpal of thumb away from palm; extends and abducts hand.

Extensor pollicis brevis lies on dorsal and lateral surfaces of lower third of forearm.

Origin (fl.): upper part of distal third of posterior surface of radius and interosseous membrane.

It lies close along ulnar side of abductor, and its tendon

proceeds over the first metacarpal to be **inserted** into dorsum of base of proximal phalanx of thumb.

Nerve: posterior interosseous (c. 6, 7, 8). It extends proximal phalanx; extends and abducts hand.

Extensor pollicis longus lies *deeply* in back of forearm; *superficially* on back of wrist and thumb.

Origin (fl.): from the middle one of the three impressions on posterior surface of ulna; interosseous membrane.

Its tendon passes through the narrow groove on the back of distal end of radius under the extensor retinaculum, and proceeds to **insertion** into base of distal phalanx.

Nerve: same as brevis.

It extends phalanges and metacarpal of thumb; extends and abducts hand.

Extensor indicis lies *deeply* in lower third of forearm, *superficially* on dorsum of wrist and hand.

Origin (fl.): from the lowest of the three impressions on posterior surface of ulna and from interosseous membrane. Tendon passes under the extensor retinaculum hidden by extensor digitorum; on the back of the hand, it runs along the medial side of the tendon of digitorum for the forefinger, and joins it to form the extensor expansion.

Nerve: same as preceding.

It extends index and hand.

Deeper Nerve and Vessels.—Posterior interosseous nerve; posterior and anterior interosseous arteries; posterior ulnar carpal; radial artery and five of its branches; dorsal carpal arch and its dorsal metacarpal branches; companion veins.

Posterior Interosseous Nerve.—A branch of the radial (p. 191). Passes to the back of forearm by winding round the lateral side of the radius through the substance of the supinator muscle. Emerges from the supinator on the back of the limb a little above the lower border of the muscle, and descends, with the posterior interosseous vessels, across abductor pollicis longus under cover of extensor digitorum. About the middle of the forearm, it leaves these vessels and descends over the back of the interosseous membrane, under cover of extensor pollicis longus and extensor indicis; falls in with the anterior interosseous vessels and passes with them from the interosseous membrane on to the distal end of the radius, where it is under cover of the synovial sheath of extensors digitorum and indicis. While under that sheath, it ends on the back of the wrist-joint by giving branches to the ligaments of that joint and the intercarpal joints and the lower radio-ulnar joint.

Branches.—1. **Articular:** To elbow-joint near its origin and to the joints named on the preceding page.

2. **Muscular:** To all muscles of the back and lateral side of forearm except anconeus, brachio-radialis and extensor carpi radialis longus (they are supplied by the radial). The branches to extensor carpi radialis brevis and supinator arise on the front of the limb; the others on the back. Anconeus may be supplied by the posterior interosseous as well as by the radial.

Posterior Interosseous Artery.—Springs from the common interosseous branch of the ulnar, and reaches the back of the limb by passing backwards above the interosseous membrane, between the membrane and the oblique cord.

It comes into view between supinator and abductor pollicis, where it gives off its *interosseous recurrent branch*; it then descends over abductor and extensor pollicis longus under cover of the superficial muscles, expending itself in *branches to muscles* so that it seldom reaches the wrist. It is medial to the posterior interosseous nerve on the abductor, and, below that, it is separated from the nerve by extensor pollicis longus. Venæ comitantes run with it.

Interosseous recurrent artery runs upwards over supinator under anconeus to the back of the lateral epicondyle and anastomoses with the posterior branch of profunda.

Anterior Interosseous Artery.—Larger than the posterior, appears through the interosseous membrane about two inches above the wrist-joint. Runs with the posterior interosseous nerve to the back of the carpus, where it joins the posterior carpal arch. Venæ comitantes lie alongside it.

Posterior ulnar carpal artery appears from under cover of flexor carpi ulnaris, descends across the ulnar side of the wrist, and, having given a big branch to the hypothenar muscles, it runs laterally under cover of extensor carpi ulnaris to join the posterior radial carpal artery on the distal row of the carpus.

Radial Artery.—At the wrist, it leaves the front of the distal end of the radius and, accompanied by venæ comitantes, curves backwards and downwards round the lateral side of the wrist on to the back to reach the proximal end of the first intermetacarpal space, where it dips between the heads of the first dorsal interosseous muscle and enters the palm.

In this part of its course, it lies on the lateral lig. of the wrist, under cover of abductor pollicis longus and extensor pollicis brevis; then, on the scaphoid and trapezium, where it may be felt pulsating in the "anatomical snuffbox"; then, on the base of the first metacarpal; and, immediately before it leaves the back of the hand, it is crossed by extensor pollicis longus and one or more of the terminal branches of the radial nerve.

Branches of this part.—Dorsales pollicis; dorsalis indicis; posterior radial carpal; first dorsal metacarpal.

Two **dorsales pollicis arteries** run along the first metacarpal to opposite sides of the thumb. **Dorsalis indicis artery** descends over

the first dorsal interosseous muscle and along the radia side of the dorsum of the forefinger.

Posterior radial carpal artery runs medially on the distal row of the carpus deep to extensor tendons. It joins a similar branch of the ulnar to form the **posterior carpal arch.** Two *dorsal metacarpal arteries* spring from the arch, descend over the interosseous muscles in the third and fourth intermetacarpal spaces, and end in small *dorsal digital arteries* on the backs of proximal phalanges.

First dorsal metacarpal artery arises from the radial with the posterior carpal, runs over the second space and ends in the same way.

At the proximal ends of the metacarpal spaces, the metacarpal arteries are joined by *perforating arteries* which have come through the spaces from the deep palmar arch ; and, near the distal ends, they send *perforating arteries* to join the palmar digital arteries.

Joints of Upper Limb.—*See* p. 128.

Anastomosis around Elbow-Joint.—A rich network of anastomosing vessels around the elbow-joint gives branches to the bones, ligaments and synovial membranes of the elbow-joint and superior radio-ulnar joint and to the structures around the joints.

The chief vessels that enter the network are :—1. *Anterior branch of profunda* and *radial recurrent* in front of lateral epicondyle.

2. *Posterior branch of profunda* and *interosseus recurrent* behind it.

3. *Anterior branch of supratrochlear* and *anterior ulnar recurrent* in front of medial epicondyle.

4. *Posterior branch of supratrochlear* and *ulnar collateral* with *posterior ulnar recurrent* behind the medial epicondyle.

LOWER LIMB

FRONT OF THIGH

Landmarks to be Identified.—Pubic arch ; pubic symphysis ; pubic crest ; pubic tubercle. Groove of groin and inguinal lig. ; mid-inguinal point. Iliac crest ; anterior superior iliac spine ; line of sartorius muscle ; tubercle of iliac crest. Greater trochanter ; head of femur ; patellar surface ; patella ; lig. patellæ ; tubercle of tibia ; condyles of tibia and femur ; epicondyles of femur ; adductor tubercle. Tendon of adductor magnus ; vastus medialis near the knee.

Superficial Fascia.—Contains a quantity of fat—most abundant at the medial side. Deepest part is firmer in texture than the rest—more membranous than fatty—and the membranous character is most manifest at the groin, where the deep layer is partly separated from the fatty layer by small vessels and a few lymph-glands ; and both layers are continuous with corresponding layers in the anterior wall of abdomen. The deep layer is loosely attached to the deep fascia by areolar tissue except at the groin. There, the connexion is firm : the deep layer descends from the abdomen and is attached by dense areolar tissue to the deep fascia along a horizontal line that begins at the inguinal lig. (p. 213) a little lateral to the pubic tubercle and extends sidewards for three inches—receding farther and farther from the inguinal lig. since that ligament is oblique.

Contents.—1. *Fat.* 2. Three named arteries (*superficial inguinal*) and numerous small *unnamed arteries* that come through the deep fascia from the deep arteries.

3. *Veins*: *superficial inguinal* and *long saphenous*, and many *unnamed.*

4. *Lymph-glands* and *lymph-vessels.*

5. *Cutaneous nerves.*

Superficial Inguinal Arteries.—Spring from the femoral near the inguinal lig. and supply lymph-glands of the groin and neighbouring skin:—

1. **Superficial external pudendal** comes through the cribriform fascia (p. 213) and divides into branches which run medially across the spermatic cord or the round lig. of uterus to the skin of external genital organs.

2. **Superficial epigastric** comes through the cribriform fascia and runs upwards over the inguinal lig. at the mid-inguinal point to supply skin of the lower part of abdomen.

3. **Superficial circumflex iliac** pierces the deep fascia a little lateral to the saphenous opening (p. 213) and runs towards the iliac crest supplying skin of the groin.

The corresponding **veins** end in the long saphenous vein just before it pierces the cribriform fascia.

Long Saphenous Vein.—Begins on the medial side of the foot, runs up the medial side of the leg and over the back part of the medial side of knee into thigh and then ascends through the fat to the saphenous opening; bends backwards over the lower edge of the opening through the cribriform fascia, pierces the femoral sheath and ends in the femoral vein at once—an inch and a half below the inguinal ligament. Has numerous valves. Communicates with deep veins. Receives many unnamed tributaries before the superficial inguinal veins join it.

Superficial Inguinal Lymph-Glands.—A variable number—about 10. Lie near the upper part of long saphenous vein and in a row just below the attachment of the membranous layer of the superficial fascia. Large, and may therefore be felt in the living limb even when healthy. Receive lymph-vessels from all superficial parts of lower limb and other parts near—abdominal wall, genital organs, perineum—and even from organs in the pelvis; and they send efferent lymph-vessels to deeper glands.

They and the superficial inguinal vessels lie between the layers of superficial fascia.

Cutaneous Nerves.—Terminal part of **ilio-inguinal nerve** escapes from abdominal wall through the superficial inguinal ring (p. 367), and it branches to supply skin of the genital organs and adjacent part of the thigh and pubis.

Femoral branch of genito-femoral nerve lies close to the lateral side of the femoral artery until an inch below inguinal ligament, where it pierces the deep fascia and supplies skin at the middle of the uppermost part of front of thigh—an area about the size of the palm of the hand.

Lateral cutaneous nerve of thigh escapes from abdomen behind

the lateral end of the inguinal lig. and runs straight downwards in a ridge of deep fascia for some distance; and after a run of two inches it divides into two branches:—

The *posterior branch* pierces the deep fascia at once and supplies skin over the greater trochanter and the neighbouring part of gluteal region and thigh. *Anterior branch* runs down another two inches in the fascia and then emerges to descend to the lateral side of patella supplying skin of the front and lateral side of thigh.

Intermediate cutaneous nerve of thigh springs from the femoral nerve an inch below the inguinal ligament and divides into two branches of which the lateral one pierces sartorius. Both pierce the deep fascia two or three inches below inguinal lig. and supply skin of the middle of front of thigh down to the patella.

Medial cutaneous nerve of thigh also springs from the femoral an inch below the inguinal lig. Runs along the medial margin of sartorius (giving twigs to the skin near long saphenous vein), crosses the femoral vessels at the apex of femoral triangle and divides into two branches:—

Anterior branch crosses sartorius, pierces the deep fascia at the junction of the middle and lower thirds of the thigh a little in front of the long saphenous vein, and supplies skin of the front of the lower part of thigh and over patella.

Posterior branch runs along the posterior border of sartorius, pierces the deep fascia near the knee behind sartorius and the saphenous vein, gives a few filaments to the lowest part of the medial side and the back of the thigh, and descends to the skin of the upper part of the medial side of the leg.

Infrapatellar branch of saphenous nerve arises a little above the knee. Pierces the deep fascia at the medial side of the knee and passes downwards and forwards to the skin below the patella. As it crosses the joint it is opposite the medial semilunar cartilage and is encountered in an operation on that cartilage.

Patellar Plexus.—A network of nerves in the fascia in front of patella, lig. patellæ and upper part of tibia. Made of branches of the infrapatellar and of the lateral, medial and intermediate cutaneous nerves.

Deep Fascia.—In the thigh it is called **fascia lata,** and it envelops the whole thigh.

Superiorly, it is attached to the ischial tuberosity, side of pubic arch, body of pubis, inguinal ligament and anterior part of iliac crest; and, at the back, it is continuous with the gluteal fascia, through which it gains attachment to the rest of iliac crest, sacrum, coccyx and sacro-tuberous lig.—thus completing a circle.

Inferiorly, on the front and sides, it is attached to patella, lig. patellæ, tubercle of tibia, capsule of knee-joint, condyles of femur and tibia, and head of fibula; *at the back*, it is continuous with the fascia of the back of the leg.

Very thin on the medial side of thigh; strong over the popliteal fossa, where it is called **popliteal fascia**; and still stronger on the lateral side of thigh, where it is thickened to form the ilio-tibial tract.

Ilio-Tibial Tract.—A long, wide, strong band, attached to the

tubercle of iliac crest, from which it stretches down to the lateral condyle of tibia, capsule of knee and patella. Overlies the anterior part of gluteus medius, greater trochanter, vastus lateralis, the lower lateral part of vastus intermedius, lateral condyle of femur and knee-joint.

Acts as the tendon of two muscles, for *gluteus maximus* is inserted into it posteriorly at the level of greater trochanter and *tensor fasciæ latæ* into it anteriorly below trochanter.

Above gluteus maximus, its anterior border splits to become continuous with the two layers that envelop tensor fasciæ latæ, and its posterior border is continuous with the fascia on gluteus medius. Below gluteus maximus, it is continuous in front and behind with the rest of fascia lata ; and the lateral intermuscular septum springs from its deep surface.

Intermuscular Septa.—Thin fibrous sheets that pass from the deep surface of fascia lata to the back of the femur. They separate the three groups of muscles of the thigh from one another—the *extensors* in front and laterally, associated with *femoral nerve* ; *flexors* or hamstrings behind, with *sciatic nerve* ; and *adductors*, with *obturator nerve*, on the medial side. Secondary septa arise from them, so that every muscle is ensheathed.

Lateral intermuscular septum, much the strongest, stretches from the ilio-tibial tract to linea aspera and lateral supracondylar line. It separates vastus lateralis and intermedius from the short head of biceps ; and some of their fibres arise from it.

Medial intermuscular septum stretches from fascia lata on the medial side of thigh to linea aspera and the medial supracondylar line, fusing with the anterior surfaces of the tendons of adductor magnus and longus. It is continuous superiorly with the *pectineal fascia*, which slopes backwards and sidewards over the front of the pectineus to the back of the femur.

Posterior intermuscular septum, very ill-defined, stretches from fascia lata at the medial side of back of thigh to the back of the femur, covering the posterior surface of adductor magnus and separating it from the hamstring muscles.

Saphenous Opening.—An oval gap in the fascia lata immediately below the medial part of inguinal ligament. An inch and a half long and half an inch wide. Its centre is an inch and a half below and lateral to the pubic tubercle. Its upper, lateral and lower margins run into each other, making one sharply-curved edge called its *falciform margin*. Medially the opening is bounded by the pectineal fascia—a sloping surface rather than a margin. A thin fascia spread over the opening is called the *cribriform fascia* because it is perforated by the long saphenous vein, the superficial epigastric and external pudendal arteries and some lymph-vessels. The femoral vessels (in the femoral sheath) are behind the opening—the vein in full view, the artery behind the lateral margin.

Inguinal Ligament.—Is the thickened lower border of the external oblique aponeurosis (p. 362). Lateral end is fixed to the anterior superior iliac spine. From that point it slopes steeply

downwards and then curves medially to be attached to the pubic tubercle. Fascia lata is attached to its whole length, and by its tension it maintains the downward convexity of the ligament.

The **pectineal part** of the ligament is a triangular expansion from its medial part to the medial inch of the pectineal line. The apex of the triangle is fixed to the pubic tubercle; its base is a free edge closely related to the medial side of the beginning of the femoral sheath; its femoral surface looks downwards and sidewards and gives origin to some fibres of pectineus. (*See also* p. 364.)

Mid-inguinal Point.—A point not at the middle of the inguinal lig. but a point *on the inguinal lig.* equidistant from the pubic symphysis and the anterior superior iliac spine. At this point, the psoas major muscle descends into the thigh behind the ligament, the femoral artery begins behind the ligament, and the superficial epigastric artery ascends into the abdominal wall in front of the ligament, with its vein along its medial side. (*See also* p. 363.)

Muscles of Front of Thigh.—Tensor fasciæ latæ; sartorius; quadriceps femoris; articularis genu; ilio-psoas; pectineus.

Tensor fasciæ latæ lies superficially between the gluteal region and the front of the thigh, and, in a thin person, it can be seen swelling as it contracts. Enclosed between two layers of deep fascia which are continuous with ilio-tibial tract behind and below; the deeper layer sends offshoots to fuse with the tendon of rectus femoris and the capsule of hip-joint.

Origin (fl.) [1]: anterior superior iliac spine and adjoining part of iliac crest.

Insertion: ilio-tibial tract a little below greater trochanter.

Nerve: superior gluteal (fibres from L. 4, 5; S. 1).[2]

It braces ilio-tibial tract; abducts the thigh and rotates it medially.

Sartorius lies superficially on front of thigh and medial side of thigh and knee.

Origin (fl.): anterior superior iliac spine and upper part of the floor of the notch below.

Insertion: by aponeurotic tendon into upper part of medial surface of tibia in front of gracilis and semi-tendinosus (from which it is separated by *bursa*), and by expansions into capsule and medial ligament of knee and fascia of leg.

[1] (fl.) signifies fleshy; (tend.) tendinous; (fl.-tend.) fleshy and tendinous.
[2] L. signifies Lumbar. S. signifies Sacral.

Nerve: femoral (fibres from L. 2, 3).

It flexes tibia and rotates it medially; flexes and abducts thigh and rotates it laterally.

Sartorius is fleshy almost to its lower end, and its fibres are parallel to its edges.

Its upper third is oblique; the rest is nearly vertical except at the lower end, where it sweeps forwards to insertion. The oblique part is the lateral boundary of the femoral triangle and lies on iliacus, rectus femoris and adductor longus. The middle third covers the roof of subsartorial canal and is therefore superficial to the lower half of the femoral vessels. Its lower fleshy part makes a soft vertical elevation far back on the medial side of the knee when the knee is straight; but, when the knee is bent, the muscle slips into the medial boundary of the popliteal fossa and runs straight to its insertion.

Quadriceps femoris is composed of four muscles:—Rectus femoris, vastus lateralis, medialis and intermedius. They all extend leg at knee-joint. Rectus also flexes hip. Each is supplied through *femoral n.* by fibres from L. 3, 4. *Patella* is a sesamoid bone developed in its tendon, and the real insertion of quadriceps is into upper part of tubercle of tibia by means of **lig. patellæ.**

Rectus femoris.—Upper end lies on capsule of hip under sartorius and tensor fasciæ latæ; remainder is superficial, and is separated distally from shaft of femur by a *bursa* which communicates with knee-joint.

Origin: by two tendinous heads: *Straight head* from upper part of anterior inferior iliac spine. *Reflected head* from the floor of the groove above acetabulum; a *bursa* lies under it.

Insertion: by tendon, into upper border of patella.

Vastus lateralis lies on the lateral side of the thigh.

Origin (fl.-tend.): (1) Front of capsule of hip-joint; (2) upper part of trochanteric line; (3) front and lateral side of root of trochanter major; (4) lateral margin of gluteal tuberosity; (5) upper part of lateral lip of linea aspera; (6) lateral intermuscular septum.

Insertion: into the lateral border of the tendon of rectus, into the base and lateral border of patella, and by expansions which blend with the capsule of knee.

A *bursa* lies between it and the part of gluteus maximus inserted into ilio-tibial tract.

Vastus medialis lies on medial side of femur.

Origin (fl.) : (1) lower part of trochanteric line ; (2) spiral line ; (3) linea aspera ; (4) upper two-thirds of medial supracondylar line ; (5) medial intermuscular septum and tendons of adductor longus and magnus.

Insertion : medial border of tendon of rectus, base and medial border of patella, and by expansions into capsule and medial ligament of knee.

Vastus Intermedius.—**Origin** (fl.) : (1) upper two-thirds of anterior and lateral surfaces of shaft of femur; (2) lower part of lateral lip of linea aspera ; (3) upper part of lateral supracondylar line ; (4) lower part of lateral intermuscular septum. **Insertion** : deep surface of tendons of rectus and the other vasti.

It is largely covered by, and adherent to, v. lateralis, and is blended to a variable extent with v. medialis. It covers the upward prolongation of synovial membrane of knee and the *bursa* which lies above the knee.

Articularis Genu.—Small fleshy bundles that **arise** from lower part of front of femur and are **inserted** into synovial membrane of knee. **Nerve** : femoral (L. 3, 4). It draws up synovial membrane during extension of knee.

Ilio-psoas comprises iliacus and psoas major. Their nerve-supply is from L. 2, 3, 4, directly and through femoral. They flex thigh and can rotate it medially during flexion, and rotate it laterally when it is flexed. Psoas flexes vertebral column also. A *bursa* lies between tendon of psoas and capsule of hip-joint.

Iliacus is lateral to psoas, and psoas is between it and pectineus. Femoral artery lies on psoas ; femoral vein lies on contiguous margins of psoas and pectineus ; femoral nerve lies between psoas and iliacus.

Psoas major arises in the abdomen ; and, when it reaches the thigh, it lies : (*a*) in the middle of floor of femoral triangle on the front of the hip-joint ; (*b*) below the hip-joint, at its insertion.

Insertion : by tendon into trochanter minor.

Iliacus also **arises** in the abdomen ; and, when it enters the thigh, it lies first in the most lateral part of the floor of the femoral triangle in front of the hip-joint, and then below the joint.

Insertion (fl.) : into tendon of psoas major, and into lesser trochanter, and the surface below lesser trochanter for an inch.

Pectineus lies in the upper and medial part of the floor of the femoral triangle.

Origin (fl.) : pectineal border and surface of pubis.

Insertion (tend.) : upper half of the line that leads from the back of lesser trochanter to linea aspera.

Nerve : femoral (L. 2, 3).

It flexes and adducts thigh, and rotates it laterally.

Muscles of the medial side of the thigh (p. 233) are encountered in the dissection of the front of thigh—gracilis and the three adductors.

Gracilis is the long, slender muscle that runs from pubis to tibia along the medial side of the thigh.

Adductor longus is the triangular muscle that spreads from pubis to linea aspera medial to pectineus and lower down.

Adductor brevis is hidden behind pectineus and adductor longus.

Adductor magnus is the mass of muscle behind the others, and reaches down to the medial condyle of femur, where its tendon is attached to the adductor tubercle.

Bursæ around knee-joint. *See* p. 153.

FEMORAL TRIANGLE is the hollow in the upper third of front of thigh. **Upper border** or **Base** : inguinal lig. **Lateral border** : sartorius. **Medial border** : medial margin of adductor longus. **Apex** leads into subsartorial canal.

Floor : ilio-psoas laterally ; pectineus medially ; add. longus medial to pectineus and below it ; adductor brevis, occasionally, between pectineus and longus, and on a posterior plane.

Roof : fascia lata and cribriform fascia.

Contents : Femoral sheath, including femoral canal.

Femoral art., with its superficial epigastric and circumflex iliac, external pudendal and profunda branches.

Femoral vein, with its saphenous, profunda, circumflex, and deep external pudendal tributaries.

Femoral nerve and its branches ; lateral cutaneous nerve ; and femoral branch of genito-femoral nerve.

Lymph-glands and lymph-vessels ; and fat.

SUBSARTORIAL CANAL is in the middle third of the medial side of the thigh. Extends from the apex of the femoral triangle to the opening in adductor magnus by which the femoral vessels enter the popliteal fossa.

Boundaries : *antero-lateral*, vastus medialis ; *postero-medial*, add. longus and magnus ; *antero-medial*, fascial bridge that unites v. medialis to add. longus and magnus, and is covered by sartorius.

Contents : femoral vessels ; descending genicular vessels ; saphenous nerve ; nerve to vastus medialis.

Relations in Femoral Triangle and Subsartorial Canal

Deep Inguinal Lymph-Glands.—Three or four small glands that lie along the medial side of the upper part of the femoral vein—one occupying the femoral canal. They drain the deep parts of the limb and of the penis; they receive the efferents of the superficial inguinal glands; and they send their efferents up into the abdomen to the glands around the external iliac artery.

Femoral Branch of Genito-Femoral Nerve.—Enters the femoral triangle on the lateral side of the femoral artery; pierces the deep fascia a little below the inguinal lig., and supplies the skin over the femoral triangle.

Femoral Nerve.—Arises in the abdomen from the second, third, fourth lumbar nerves. Appears at the lateral border of psoas; gives branches to psoas and iliacus in the abdomen; and, descending between them, it enters the femoral triangle from behind the inguinal lig., about half an inch lateral to the femoral artery, and breaks up into branches about an inch below the ligament:—

Muscular branches to pectineus, sartorius, rectus femoris, the three vasti and articularis genu.

Cutaneous branches: intermediate and medial cutaneous (p. 212); saphenous.

Articular branches: none directly, but one of the nerves to rectus femoris sends a branch to the hip-joint, and the nerves to the vasti send filaments down to the knee-joint.

Branch to pectineus runs downwards and medially between psoas and femoral sheath.

Branches to sartorius descend to it, in company with the intermediate cutaneous.

Two **branches to rectus femoris** enter its deep surface, after passing under cover of sartorius.

Branch to vastus lateralis passes under cover of sartorius and rectus femoris, runs in company with the descending branch of the lateral circumflex artery along the anterior border of the muscle, and then enters its deep surface.

Two or three **branches to v. intermedius** pass to it under cover of sartorius and rectus, and one of them sends filaments to articularis genu.

One **branch to v. medialis** enters it high up; another runs along the lateral side of the femoral artery into subsartorial canal and enters the muscle there.

Saphenous Nerve.—Arises from the femoral an inch below the inguinal ligament.

Descends through the femoral triangle lateral to the femoral vessels. Leaves the triangle through its apex and enters the subsartorial canal, where it passes on to the front of the femoral artery.

It leaves the canal by passing from under cover of the distal edge of its fibrous roof, accompanied by the saphenous artery. It sends its infrapatellar branch through the sartorius and deep fascia to the skin over the ligamentum patellæ; and it then emerges from

under cover of sartorius at its posterior border. Pierces the deep fascia at the medial side of the knee between sartorius and gracilis and descends through the medial side of the leg immediately behind the long saphenous vein.

Subsartorial Plexus.—Lies on the fibrous roof of the subsartorial canal under cover of sartorius. Consists of branches from saphenous, medial cutaneous and cutaneous branch of obturator. Supplies neighbouring skin.

Femoral Sheath.—Encloses the first inch and a half of the femoral vessels. It is formed by the fascia transversalis (p. 361) and fascia iliaca (p. 374), which are prolonged over the vessels from ant. and post. abdominal walls, respectively, to form the anterior and posterior walls of the sheath.

Psoas, pectineus, nerve to pectineus, and sometimes profunda artery, are *behind* it. Fascia lata and the cribriform fascia are *in front of* it. It is pierced by the first branches of femoral art. The femoral branch of the genito-femoral nerve lies in the upper part of its lateral wall.

It is funnel-shaped, and is divided by two septa into a lateral compartment for the femoral art., an intermediate for the femoral vein, and a medial compartment called the femoral canal.

Femoral canal lies on pectineus, under cover of the cribriform fascia and upper margin of the saphenous opening. Femoral hernia enters the thigh through it. The canal is funnel-shaped, about half an inch long, and half an inch wide at the mouth of the funnel; and it contains a lymph-gland. Superficial external pudendal vessels sometimes cross in front of it.

Femoral ring is the mouth or upper end of the femoral canal, which opens into abdomen. It is plugged by a pad of fat called the *femoral septum*. Ring is bounded *anteriorly* by the inguinal lig., which separates it from the inguinal canal (p. 367); *medially* by the free edge of the pectineal part of the inguinal lig.; *posteriorly* by the pectineal line and pectineus; *laterally* by the femoral vein.

Inferior epigastric artery (p. 370) lies between the femoral ring and the deep inguinal ring, and its "abnormal" obturator branch, when present, descends across the femoral ring or along its medial side.

A **femoral hernia** descends into the femoral canal and turns forwards through the saphenous opening. Anterior part of the hernia is then pressed upon and retarded by the upper margin of the opening; the posterior part, being pushed onwards, hooks round the margin, and the hernia ascends over the inguinal ligament.

Coverings of the hernia are (1) femoral septum, (2) the lymph-gland, (3) anterior wall of femoral canal, (4) cribriform fascia, (5) superficial fascia, (6) skin.

Femoral Artery. Begins as a continuation of the ext. iliac, behind the inguinal lig., at the **mid-inguinal point**. Descends through the femoral triangle and subsartorial canal, and ends behind the femur at the junction of the middle and lower thirds of the thigh by passing through the opening in adductor magnus and becoming the popliteal artery. Position is indicated by the

upper two-thirds of a line drawn from the mid-inguinal point to the adductor tubercle, when the thigh is slightly flexed, abducted and rotated laterally.

Relations in Femoral Triangle.—Femoral sheath surrounds the upper inch and a half of the artery.

Anterior to it, there are the fasciæ and, at the apex of the triangle, the medial cutaneous nerve.

Lateral to it, there are the femoral nerve and its branches (the nerve being separated by small piece of psoas) and the femoral branch of the genito-femoral nerve in the lateral wall of the sheath.

Posterior to it, there are psoas, pectineus, adductor longus, proximo-distally; nerve to pectineus is between it and psoas; a large mass of fat which contains profunda vessels and part of femoral vein is between it and pectineus; femoral vein is also between it and adductor longus. Profunda art. is first lateral and then posterior.

Femoral vein, though behind the femoral artery in the lower part of the triangle, is *on the medial side* in the upper part, and is the only medial relation of the artery except fat.

Psoas separates the artery from the capsule of the hip-joint and the medial part of the head of the femur. When in front of pectineus, the artery is some distance medial to the femur—opposite the angular interval between its neck and shaft.

Relations in Subsartorial Canal.—*Within the canal*: saphenous nerve is first lateral and then anterior to the artery; nerve to vastus medialis is lateral; femoral vein is posterior, except towards the distal end, where it becomes postero-lateral.

Walls of canal: vastus medialis is antero-lateral to the artery; fibrous roof, subsartorial plexus and sartorius are antero-medial; adductor longus and magnus are postero-medial.

Outside canal: femur is first lateral and then anterior to the artery, and separated only by vastus medialis, which is thin there; profunda vessels are posterior, separated from the femoral vessels by adductor longus.

Branches of Femoral Artery.—Unnamed muscular; superficial inguinal, *i.e.* superficial epigastric, superficial circumflex iliac and superficial external pudendal (p. 211); deep external pudendal; profunda femoris; and, in adductor canal, the descending genicular artery.

Deep external pudendal artery crosses behind or in front of the femoral vein, pierces the femoral sheath, runs medially on pectineus and adductor longus, pierces the deep fascia, and passes deep to the spermatic cord (p. 664) or round lig. of uterus (p. 671) to reach the penis and scrotum or the labium majus.

Descending genicular artery arises near the lower end of the femoral artery, and it at once divides into a **musculo-articular branch**, which enters vastus medialis and runs to the knee in it, and a **saphenous branch**, which passes out of the canal with the saphenous nerve and anastomoses with other articular arteries at the medial side of the knee.

Profunda Femoris Artery.—Arises an inch and a half below the

inguinal lig. from the lateral side of the femoral artery. Curves backwards and medially behind the femoral; leaves the femoral triangle by passing behind the adductor longus; and it ends by piercing adductor magnus as the fourth perforating artery.

In the femoral triangle, iliacus and pectineus are behind it. It is at first lateral to the femoral artery, under cover of skin and fasciæ, and is crossed superficially by the lateral circumflex vein. Afterwards, it is behind the profunda vein, femoral vein, femoral artery, in that order from behind forwards. *See also* p. 235.

Branches of Profunda Femoris.—Large unnamed muscular; lateral and medial circumflex; four perforating arteries (p. 236).

These various branches are the chief supply of the muscles of the thigh. One or both of the circumflex arteries may arise directly from the femoral artery.

Lateral Circumflex Artery.—A large artery. Springs from profunda near its origin; runs laterally on iliacus among the branches of the femoral nerve; passes behind sartorius and rectus femoris, and divides into three branches:

(1) *Ascending branch* runs towards the gluteal surface of ilium along the trochanteric line of femur, under cover of tensor fasciæ latæ; (2) *descending branch* runs along the anterior border of vastus lateralis to the knee; (3) *transverse branch* sinks into vastus lateralis.

Medial Circumflex Artery.—Almost as big as the lateral circumflex, and arises about the same level. Passes backwards through the fat and escapes from femoral triangle between the contiguous margins of psoas and pectineus. *See also* pp. 227, 235.

Profunda Vein.—Lies in front of its artery and ends in the femoral vein in the femoral triangle. Its tributary veins correspond to the branches of the artery, except the circumflex veins; these end in the femoral vein.

Femoral Vein.—The continuation of the popliteal vein. Begins at the opening in adductor magnus; traverses subsartorial canal and femoral triangle; ends by becoming the external iliac vein behind the inguinal lig., where it lies on the contiguous margins of psoas and pectineus. Varying relations to the artery—posterolateral in the lower part of subsartorial canal; directly posterior at the apex of femoral triangle; medial in the upper part of the triangle.

Tributaries.—Long saphenous; profunda; lateral and medial circumflex; deep external pudendal; companion veins of the descending genicular artery. (The companion veins of superficial inguinal arteries end not in the femoral vein but in the long saphenous near its termination.)

Relations of femoral vein.—*See* p. 449.

GLUTEAL REGION

Landmarks to be Identified.—Greater trochanter. Iliac crest; posterior superior iliac spine. Sacrum and coccyx; sacro-tuberous

lig.; ischial tuberosity. Fold of the buttock. Borders of gluteus maximus; gluteal tuberosity.

Superficial Fascia of Gluteal Region.—1. Loaded with *fat*. Tough and stringy over ischial tuberosity.

Contains also: 2. Small *unnamed arteries* that come through the deep fascia from the deep arteries.

3. Corresponding *veins*.
4. *Lymph-vessels*.
5. Numerous *cutaneous nerves*.

Lymph-vessels end in the glands of the groin—superficial inguinal lymph-glands.

Posterior branch of lateral cutaneous nerve of thigh turns downwards and backwards into the lower lateral part of the region.

Lateral cutaneous branch of subcostal nerve (12th thoracic) appears through the deep fascia at the iliac crest immediately in front of the tubercle of crest and descends in the anterior or lateral part of the region as far as the greater trochanter.

Lateral cutaneous branch of ilio-hypogastric appears just behind the tubercle and descends for a like distance.

Cutaneous branches of *posterior primary rami* of the **upper three lumbar nerves** appear a little above the highest point of iliac crest and descend almost to the fold of the buttock.

Cutaneous branches of *posterior primary rami* of the **upper three sacral nerves,** having pierced gluteus maximus, appear through the deep fascia between the posterior superior iliac spine and the coccyx (about an inch apart) and ramify in the medial part of the region.

Perforating cutaneous nerve arises in pelvis from anterior primary rami of s. 2 and 3, perforates sacro-tuberous lig., gluteus maximus and deep fascia about midway between coccyx and ischial tuberosity, and ramifies in the lower medial part of the region.

Two or three *gluteal branches* of **posterior cutaneous nerve of thigh** curve round the middle third of lower border of gluteus maximus, pierce the deep fascia and supply the lower part of the region.

Deep Fascia.—Extends up from the back of the thigh; splits to enclose gluteus maximus; gives partial origin to it, and sends septa into it to divide it into coarse bundles. Above and in front of gluteus maximus, where the fasciæ covers the antero-superior part of gluteus medius, it is greatly thickened and is continuous with the ilio-tibial tract.

Muscles and Ligaments.—Gluteus maximus, medius and minimus; piriformis; obturator internus and two gemelli; quadratus femoris; obturator externus. Sacro-spinous and sacro-tuberous ligs.

Sacro-Tuberous Lig.—A long, strong band, wider at its ends than in the middle. Hidden by the lower medial part of gluteus maximus, part of which arises from it. *Upper end* attached to the posterior iliac spines and to sacrum and coccyx. *Lower end* attached to the lower medial impression on ischial tuberosity. *See also* p. 142.

Sacro-Spinous Lig.—Hidden by gluteus maximus, sacro-tuberous ligament and pudendal nerve. Flat and triangular.

Apex attached to ischial spine, from which it spreads medially to be attached by its *base* to the last piece of sacrum and first piece of coccyx. The part near ischial spine is crossed by the pudendal nerve; the rest of it is under cover of the sacro-tuberous lig. *See also* p. 142.

Gluteus maximus lies superficially. Lower border crosses the fold of the buttock obliquely from above downwards and sidewards. Coarsest and heaviest muscle in the body.

Origin (fl.): (1) upper part of area behind posterior gluteal line of hip-bone; (2) dorsum of sacrum and coccyx; (3) tendon of sacro-spinalis; (4) dorsal surface of sacro-tuberous lig.; (5) fascia which envelops it.

Insertion: lower deep quarter by fleshy fibres into gluteal tuberosity; the rest by an aponeurosis into ilio-tibial tract.

Nerve: inferior gluteal (L. 5, S. 1, 2).

It extends and abducts thigh and rotates it laterally; tightens ilio-tibial tract. Lowest fibres adduct thigh.

Three **bursæ** underlie it: a multilocular one separates its lower border from the hamstring tendons as they arise from ischial tuberosity. The aponeurosis is separated by a large one from greater trochanter, and by another large one from the upper part of vastus lateralis.

STRUCTURES COVERED BY GLUTEUS MAXIMUS.—Medial series: (1) Structures from which it arises; (2) bursa; (3) hamstrings and adductor magnus, at their origin from ischial tuberosity.

Intermediate series: (1) Gluteus medius; (2) superficial branches of superior gluteal vessels; (3) piriformis; (4) sciatic nerve and nerve to quadratus; (5) posterior cutaneous nerve, and (6) inf. gluteal nerve and vessels; (7) nerve to obturator int.; (8) int. pudendal vess.; (9) pudendal nerve; (10) obturator int. and gemelli; (11) quadratus femoris (obturator ext. and ascending branch of medial circumflex art. lie deeply between inf. gemellus and quadratus); (12) transverse branch of medial circumflex vessels; (13) adductor magnus.

Lateral series: (1) Gluteus medius; (2) bursa and greater trochanter; (3) bursa and upper part of vastus lateralis.

Gluteus medius lies in upper and anterior part of the gluteal region—its posterior third being deep to maximus.

Origin (fl.): area on the gluteal surface of the ilium bounded by the middle and posterior gluteal lines and iliac crest; fascia which covers it.

Insertion (tend.): lateral surface of greater trochanter from postero-superior angle to antero-inferior angle.

Nerve: superior gluteal (L. 4, 5, S. 1).

It abducts thigh. Anterior fibres flex and rotate medially; posterior fibres rotate laterally.

A *bursa* lies between it and the anterior part of the lateral surface of the trochanter.

Gluteus minimus lies under cover of medius.

Origin (fl.): gluteal surface of ilium between middle and inferior gluteal lines.

Insertion (tend.): ant. surface of greater trochanter.

Nerve: sup. gluteal (L. 4, 5, S. 1).

Bursa lies between it and the medial part of the front of trochanter.

Same action as medius.

Reflected tendon of rectus femoris is imbedded in the capsule of hip-joint above the rim of acetabulum under cover of gluteus minimus.

Piriformis lies partly in pelvis, partly in gluteal region on upper part of back of hip-joint. It arises within the pelvis, emerges through the greater sciatic foramen, and tapers to form a round tendon which is **inserted** into the upper margin of greater trochanter; near insertion, the tendon spreads out, overlies the tendon of obturator internus and adheres to it.

Nerves: Branches in the pelvis from S. 1, 2, directly.

It abducts flexed thigh; laterally rotates extended thigh.

Obturator internus has a fan-shaped fleshy belly whose fibres arise from the side-wall of the pelvis and converge upon the lesser sciatic foramen to form a tendon. The tendon bends at a right angle, emerges through that foramen, and runs across the back of the hip-joint to be **inserted** into medial surface of greater trochanter; a *bursa* separates the tendon from the floor of the lesser sciatic notch.

Nerve: nerve to obturator internus (from L. 5, S. 1, 2).

Same action as piriformis.

Gemelli supplement obturator int., and lie one above its tendon and one below. They **arise** from the margins of the lesser sciatic notch, and are **inserted** into the tendon of obturator internus and the medial surface of the trochanter. *Superior* is supplied by the nerve to obturator internus, *inferior* by the nerve to quadratus femoris.

Quadratus femoris lies in lowest part of buttock under cover of gluteus maximus.

Origin (fl.-tend.) : lateral margin of ischial tuberosity.

Insertion (fl.-tend.) : into the trochanteric crest and the quadrate tubercle, and into the line that runs downwards from the tubercle.

Nerve: nerve to quadratus femoris (from L. 4, 5, S. 1).

It adducts thigh and rotates it laterally.

Obturator externus arises from the front of the pelvis (p. 234), and winds backwards below the hip-joint to enter the gluteal region, where it passes upwards and in a lateral direction over the back of the neck of the femur under cover of quadratus femoris and tapers to be inserted by tendon into the floor of the trochanteric fossa.

Sciatic Foramina and their contents.—*See* p. 143.

Deep Vessels and Nerves.—Superior and inferior gluteal vessels and nerves; sciatic nerve; N. to quadratus femoris; posterior cutaneous nerve of thigh; N. to obturator internus; internal pudendal vessels; pudendal nerve; terminal branches of medial circumflex artery.

Superior Gluteal Nerve.—Arises in the pelvis from the sacral plexus, escapes through the upper part of the greater sciatic foramen, appears in the gluteal region above piriformis under cover of gluteus maximus, turns laterally between gluteus medius and minimus, and divides at once into two or more branches. *Upper branch* (or branches) sinks into gluteus medius. *Lower branch* runs across the middle of gluteus minimus, gives twigs to both medius and minimus, emerges from between them at their anterior borders under cover of tensor fasciæ latæ, and descends to sink into the tensor at the level of the greater trochanter.

Superior Gluteal Artery.—Arises in the pelvis from the internal iliac (p. 390); accompanied by its veins, it appears in the gluteal region with the nerve, and divides at once into two :—

Superficial division breaks into branches that sink at once into gluteus maximus.

Deep division soon breaks into an upper branch and a lower. The *lower* branch accompanies the lower branch of the nerve. The *upper* branch follows the upper border of gluteus minimus, clinging to the middle gluteal line of the ilium.

Sciatic Nerve.—A terminal branch of sacral plexus. Passes out of the pelvis through the lower part of greater sciatic foramen and appears in the gluteal region below piriformis, enclosed in a sheath of fascia.

It descends through the gluteal region, enters the thigh at the lower border of quadratus femoris, and ends half way down the back of the thigh by dividing into the lateral and medial popliteal nerves.

In gluteal region, it is under cover of gluteus maximus, between ischial tuberosity and greater trochanter, and lies on (1) ischium and nerve to quadratus femoris, (2) obturator internus and gemelli, and (3) quadratus femoris. Medially, it is related to the posterior cutaneous nerve and the inferior gluteal nerve and vessels, all of which, however, may be behind it.

In the thigh, it lies on the back of adductor magnus close to the back of the femur; and it is under cover of the hamstrings—especially the long head of biceps, which is the only one that crosses it.

Branches.—Apart from its terminal branches, which are distributed to muscles, skin and joints from the knee downwards, its only branches are **muscular** to biceps femoris, semitendinosus, semimembranosus and the ischial part of adductor magnus.

These branches arise in the thigh, but a branch that supplies semitendinosus and the long head of biceps may arise in the lower part of the gluteal region.

Ordinarily, the trunk of sciatic nerve gives off none but muscular branches; but, if it does not divide till it reaches the popliteal fossa, two *articular* branches—the lateral genicular—may arise from it instead of from the lateral popliteal.

The branch to the short head of biceps comes from the lateral popliteal half of the nerve; the other branches come from the medial popliteal part. This becomes evident when the nerve divides high up.

Sometimes the nerve divides into its two terminal branches in the pelvis; the medial popliteal then appears below piriformis, but the lateral popliteal pierces the muscle.

Nerve to Quadratus Femoris.—Arises from the sacral plexus and appears in the gluteal region in front of the sciatic nerve and is therefore hidden by it. It descends over the ischium and the capsule of the hip-joint on to the back of obturator externus, where it sinks into the front of quadratus femoris. On its way down it gives a branch to inferior gemellus and another to the back of the capsule of the hip-joint. It is concealed, in turn, by sciatic nerve, obturator internus and gemelli and quadratus femoris.

Posterior Cutaneous Nerve of Thigh.—Lies at the medial side of sciatic nerve or on the back of it, but leaves it when they enter the thigh. (*See* p. 229.)

Inferior Gluteal Nerve.—Arises from the sacral plexus and appears in the gluteal region with the posterior cutaneous in close relation to sciatic nerve. It supplies gluteus maximus alone—breaking into branches that sink into the deep surface of the muscle.

Inferior Gluteal Artery.—A branch of internal iliac. Appears with the nerve, and passes down over the sciatic nerve but soon divides into branches:—

1. Large *muscular* branches, the most constant in position being one that accompanies the nerve to quadratus femoris.

2. *Cutaneous* branches to gluteal region and back of thigh.
3. *Coccygeal* branch threads its way through sacro-tuberous liga-ment to the skin over the back of the coccyx.
4. *Companion artery of sciatic* nerve runs with that nerve for some inches and then sinks into it.

Nerve to Obturator Internus.—Runs a very short course in the gluteal region. It is a branch of the sacral plexus, and appears below piriformis about half an inch medial to the sciatic nerve. Runs downwards under cover of gluteus maximus across the back of the root of the ischial spine, gives a branch to the superior gemellus, and disappears through the lesser sciatic foramen to enter obturator internus on its perineal surface.

Pudendal Nerve.—A terminal branch of sacral plexus distributed in the perineum. It also comes out through the greater sciatic foramen and disappears through the lesser, and is therefore in this region for a very short distance. It is the most medial of the structures that appear below piriformis. It runs down across the back of the sacro-spinous lig. under cover of gluteus maximus and partly hidden by the edge of the sacro-tuberous lig.

Internal Pudendal Artery.—A branch of internal iliac. Runs between the pudendal nerve and the nerve to obturator internus. It accompanies the pudendal nerve to the perineum; and we get only a glimpse of it as it descends across the back of the tip of the ischial spine with a vein on each side of it.

Medial Circumflex Artery.—Disappears from femoral triangle between psoas and pectineus. It then passes backwards, with adductor brevis below it and obturator externus above, and it divides into ascending and transverse branches. **Ascending branch** runs along the lower border of obturator externus to the trochanteric fossa, and is therefore hidden by quadratus femoris. **Transverse branch** appears here between quadratus femoris and the upper edge of adductor magnus and curves down behind the magnus to anastomose with muscular and perforating branches of profunda and with the transverse branch of lateral circumflex.

This last anastomosis is the transverse part of the *cruciate anastomosis* (*crux* = a cross), whose vertical limb is the anastomoses among branches of gluteal, medial circumflex, profunda and popliteal.

BACK OF THIGH

Superficial Fascia.—Contains: 1. A variable quantity of *fat*. 2. Small *blood-vessels* that come through the deep fascia from the deep vessels.
3. *Cutaneous nerves*, which are branches of posterior cutaneous (p. 229); lateral cutaneous (p. 212) and medial cutaneous (p. 212).
4. *Lymph-vessels*, which pass to the glands in the groin.

Deep Fascia.—Thin but fairly strong. No peculiar features.

Muscles.—The hamstrings or flexors—*i.e.* biceps femoris; semi-tendinosus; semimembranosus.

Biceps femoris lies in buttock, back of thigh and in lateral boundary of popliteal fossa.

Origin: *Long head*, by tendon from the medial of the two upper impressions on ischial tuberosity, in company with semitendinosus; many fibres are continuous with sacro-tuberous lig. It crosses sciatic nerve.

Short head (fl.-tend.), chiefly from linea aspera.

Insertion: by tendon (easily felt) chiefly into head of fibula. Lateral lig. of knee splits the tendon of insertion longitudinally and is separated from it by a bursa.

Nerve: sciatic. *Long head* by the medial popliteal part, L. 4, 5, S. 1, 2, 3; *short head* by the lateral popliteal part, L. 5, S. 1, 2.

Both heads flex the leg and rotate it laterally; long head also extends the hip-joint.

Semitendinosus lies in buttock, in back of thigh and in the medial boundary of the popliteal fossa.

Origin (tend.): upper medial impression on ischial tuberosity together with long head of biceps, to which it is joined for three inches.

Insertion: by tendon (felt superficially on medial side of popliteal fossa) chiefly into medial surface of tibia below the condyle, behind and below gracilis and sartorius. *Bursæ* separate it from sartorius and from the medial ligament of the knee.

Nerve: sciatic (medial popliteal part, L. 4, 5, S. 1, 2, 3). It flexes leg and rotates it medially, and extends thigh.

Semimembranosus lies deep to semitendinosus in buttock, in back of thigh and in medial boundary of popliteal fossa.

Origin (tend.): upper lateral impression on ischial tuberosity. Long head of biceps crosses it superficially below its origin.

Insertion: by tendon (felt more deeply than semitendinosus on the medial side of popliteal fossa) into (1) the groove on the back of the medial condyle of tibia, (2) capsule of knee (oblique posterior lig.) and (3) fascia over popliteus. A *bursa* lies under it at insertion, and another between it and medial head of gastrocnemius.

Nerve: sciatic (medial popliteal part, L. 4, 5, S. 1, 2, 3). Same actions as semitendinosus.

Deep Nerves and Vessels.—Sciatic nerve (p. 225); per-

forating and muscular branches of profunda femoris artery (p. 235); muscular branches of popliteal artery (p. 231); corresponding veins; posterior cutaneous nerve of thigh.

Posterior Cutaneous Nerve of Thigh.—Long and slender. Arises from the sacral plexus, escapes from the pelvis through the lower part of the greater sciatic foramen and enters the gluteal region below piriformis in company with the inferior gluteal nerve at the medial side of the sciatic nerve or on the back of it, and descends in the gluteal region under cover of gluteus maximus on the back of the sciatic nerve or along its medial border. In the lower part of the gluteal region, it leaves the sciatic nerve, and, having escaped from under gluteus maximus, it runs down the middle of the back of thigh immediately under the deep fascia, lying first on the long head of biceps (which separates it from the sciatic nerve) and then on the fat in the popliteal fossa. It pierces the deep fascia at the back of the knee and descends in the superficial fascia to the middle of the calf of the leg.

Branches.—1. Two or three gluteal branches supply skin of the lower part of the buttock (p. 222).

2. A *perineal branch* arises in the gluteal region, runs medially across the back of the hamstrings just below the ischial tuberosity, and then runs forwards in the perineum to the skin of genital organs.

3. Small branches pierce the deep fascia to supply skin on the back and medial side of thigh.

4. The terminal part supplies the skin of the upper half of the back of the leg.

Popliteal Fossa

Is the space behind the lower part of the femur, the knee-joint and the upper part of the tibia. A hollow when the knee is bent, but its contents bulge slightly when the knee is straight. It is diamond-shaped in outline with the vertical diameter longer than the transverse. The **hamstrings** bound its upper part. Its lower part is bounded by the two heads of **gastrocnemius**—*i.e.* a large muscle that lies superficially in the calf—and by **plantaris** which lies under gastrocnemius and has a small fleshy belly at the knee and a very long, slender tendon in the leg. The **popliteus** muscle lies in the lower part of the floor of the fossa. It is a muscle whose tendon of origin is within the knee-joint and whose fleshy part spreads out to cover and to be inserted into the uppermost part of the back of the shaft of the tibia.

Landmarks to be Identified in the Living Limb.—Condyles of femur; condyles of tibia; head of fibula. Lateral ligament of knee;

tendon of biceps; posterior part of ilio-tibial tract. Tendons of semitendinosus, semimembranosus and gracilis. Heads of gastrocnemius.

Superficial Fascia.—Contains: 1. A small quantity of *fat.*
2. Small unnamed *blood-vessels.*
3. Branches and terminal part of *posterior cutaneous nerve of thigh.*
4. Posterior branch of *medial cutaneous nerve of thigh.*
5. *Sural communicating nerve* (p. 232).
6. Upper part of the *short saphenous vein* (p. 245).

Deep Fascia.—Is the **popliteal fascia.** Strengthened by transverse fibres. Adherent to the tendons in the boundaries.

Boundaries, Roof, Floor and Contents of Popliteal Fossa

Boundaries.—*Superior*: biceps on the lateral side; semitendinosus and semimembranosus on the medial side—reinforced by sartorius and gracilis when the knee is bent.

Inferior: lateral head of gastrocnemius and plantaris on the lateral side; medial head of gastrocnemius on the medial side.

Roof: popliteal fascia, pierced by the posterior cutaneous nerve and the short saphenous vein.

Floor: popliteal surface of femur, posterior ligament of knee, popliteus and its fascia.

Contents: Popliteal artery and its branches.
Popliteal vein and its tributaries, including short saphenous.
Lateral and medial popliteal nerves and their branches.
Posterior cutaneous nerve of the thigh.
Genicular branch of obturator nerve.
Lymph-glands and fat.

Relations in Popliteal Fossa

Popliteal Artery.—The continuation of the femoral at the opening in adductor magnus, at the upper part of the medial boundary of the fossa. It runs downwards between the condyles of femur, and leaves the fossa at its distal angle to end at the distal border of popliteus by dividing into anterior and posterior tibial.

Branches, besides its terminals: muscular, cutaneous and five genicular to the knee-joint—two medial, two lateral and one middle.

Popliteal Vein.—Begins at the distal border of popliteus, medial to the artery, by the union of the venæ comitantes of the anterior and posterior tibial arteries. It passes behind the artery to lie posterolateral to it at the opening in adductor magnus, where it becomes the femoral vein.

Tributaries: short saphenous vein and the veins that accompany the branches of the artery.

Medial Popliteal Nerve.—A terminal branch of sciatic. Enters the fossa at the upper angle. At first lateral to the popliteal vessels, it crosses behind them, and leaves the fossa at its distal angle, medial

to both vessels, and it ends at the distal border of the popliteus by becoming the *posterior tibial.*

Branches: 1. *Sural nerve.* 2. Three *genicular branches.* 3. *Muscular branches* to both heads of gastrocnemius, plantaris, soleus and popliteus; the branches to soleus and popliteus arise when the nerve is medial to the popliteal artery, and they cross behind the artery.

Relations of the group (artery, vein, nerve):—*Anterior*: floor of fossa—femur, posterior lig. of knee and popliteus. The artery is next the floor, but separated by fat, especially in its upper part.

Posterior: posterior cutaneous nerve of thigh, deep fascia, short saphenous vein; and both heads of gastrocnemius overlap.

Medial: medial boundary of fossa (semimembranosus overlapping the vessels); and medial condyle.

Lateral: lateral boundary of fossa, lateral condyle and lateral popliteal nerve.

Muscular branches of popliteal artery supply muscles of the calf and of the back of the thigh, and they anastomose with muscular and perforating branches of profunda.

Cutaneous twigs spring from the muscular branches.

The **genicular branches** accompany the genicular nerves, and anastomose with one another and with other arteries around the knee.

Short saphenous vein begins at the dorsal venous arch of the foot, ascends through the superficial fascia over the back of the lateral malleolus and calf of leg, pierces the popliteal fascia below the middle of the fossa, and ends in the popliteal vein.

Branches of Medial Popliteal Nerve.—Muscular branches pass directly to the muscles —*gastrocnemius, plantaris, soleus, popliteus*— except the *nerve to popliteus*, which, after crossing the popliteal artery, descends and turns round the distal border of popliteus to enter its deep or anterior surface. At the lower border of popliteus, this nerve gives off a long filament which supplies the superior tibio-fibular joint and the interosseous membrane, and descends through that membrane to the inferior tibio-fibular joint.

Sural nerve arises from the medial popliteal about the middle of the fossa, and leaves it at its distal angle, under cover of the deep fascia; taking the short saphenous vein as its guide, it ends at the little toe.

Three **genicular nerves** arise from the medial popliteal in the upper part of the fossa, and, accompanied by genicular vessels, they help to supply the ligaments and synovial membrane of the knee-joint:—

Superior medial genicular nerve curves medially and forwards above the medial femoral condyle under cover of semimembranosus and semitendinosus; it then pierces the posterior intermuscular septum, passes between the femur and the tendon of adductor magnus, and sinks into vastus medialis, and, through it, into the supero-medial part of the joint.

Inferior medial genicular nerve is the largest nerve of the knee-joint and the one most easily found. It runs downwards and

medially over the back of the joint, along the upper border of the popliteus, under cover of the medial head of gastrocnemius. It then curves forwards below the medial condyle of the tibia, between the tibia and the medial ligament of the knee. Finally, it inclines upwards into the infero-medial part of the joint.

The *middle genicular nerve* is short and very slender. It pierces the posterior ligament to gain the interior of the knee, where it supplies the cruciate ligaments and their synovial covering.

Lateral Popliteal Nerve.—A terminal branch of sciatic. Enters the fossa at its upper angle from under cover of biceps. Runs along the medial side of biceps and leaves the fossa at its lateral angle. Crosses plantaris, lateral head of gastrocnemius, tendon of popliteus, lateral genicular nerve and vessels, and lies between the tendon of biceps and gastrocnemius on the origin of soleus at the back of the head of the fibula. Runs downwards and forwards to enter the substance of peroneus longus on the lateral side of the neck of the fibula, where it gives off its recurrent genicular branch and then divides into musculo-cutaneous and anterior tibial nerves.

It is very superficial, and is easily felt where it lies on the lateral head of gastrocnemius opposite the back of the lateral condyle of the femur, and, again, where it lies on soleus at the back of the head of the fibula.

Branches of Lateral Popliteal Nerve in Popliteal Fossa.—

Muscular : none.

Sural communicating nerve arises from the lateral popliteal in the upper part of the fossa, passes superficial to the lateral head of gastrocnemius, pierces the deep fascia, and descends to join the sural nerve in the lower part of the leg.

Lateral cutaneous nerve of calf arises from the lateral popliteal nerve on the lateral head of gastrocnemius, pierces the deep fascia almost at once, and supplies skin of the lateral side of the upper third of the leg on both back and front.

Three **genicular nerves** arise from the lateral popliteal, and, accompanied by genicular vessels, they help to supply ligaments and synovial membrane of the knee-joint. Only two of them arise in the fossa—superior and inferior lateral.

Superior lateral genicular nerve arises in the uppermost part of the fossa (or above the fossa). It runs downwards and laterally, under cover of biceps, above the lateral femoral condyle ; and it pierces the lateral intermuscular septum and vastus intermedius to supply the supero-lateral part of the joint.

Inferior lateral genicular nerve is very slender. It arises with the superior nerve, and accompanies the lateral popliteal nerve to the lateral angle of the fossa, and onwards over the lateral head of gastrocnemius. It then curves forwards, under cover of biceps and the lateral ligament of the knee to reach the infero-lateral part of the joint.

Recurrent genicular nerve arises in the peroneus longus from the end of the lateral popliteal. (*See* p. 243.)

Posterior Cutaneous Nerve of Thigh.—Enters the fossa at the

upper angle, under cover of the deep fascia ; sends a branch through the deep fascia of the upper part of the fossa ; pierces the deep fascia itself about the middle of the fossa, and supplies skin of the upper part of the calf of the leg.

Genicular Branch of Obturator Nerve.—So slender that it is seldom found. It emerges from the substance of adductor magnus, and runs downwards, closely applied to the medial side of the popliteal artery, to end in the capsule of the knee.

The **lymph-glands** are alongside the popliteal vein and the terminal part of the short saphenous vein. They receive lymph from the deep parts of the leg and pass it on to the deep inguinal glands.

MEDIAL SIDE OF THIGH

Superficial and deep fasciæ are described with the FRONT OF THIGH (pp. 210, 212).

Muscles.—Pectineus (p. 217). Gracilis. Three adductors. Obturator externus.

Gracilis runs superficially along the medial side of thigh and knee.

Origin (tend.) : margin of pubic symphysis and medial margin of inferior ramus of pubis.

Insertion : by long tendon, into medial surface of tibia below the condyle, behind and below the sartorius (from which it is separated by a bursa), above and in front of semitendinosus.

A *bursa* common to it and semitendinosus separates it from the medial ligament of the knee.

Nerve : obturator (L. 2, 3, 4).

It adducts thigh, flexes tibia and rotates it medially.

Adductor longus lies in medial and distal part of floor of femoral triangle, and in floor of subsartorial canal.

Origin : by rounded tendon, which is easily palpable, from the femoral surface of the body of the pubis in the angle between symphysis and crest.

Insertion (tend.) : lower two-thirds of linea aspera.

Nerve : obturator (L. 2, 3).

It adducts and flexes thigh, and rotates it laterally.

Adductor Brevis.—**Origin** (fl.) : femoral surface of body and inferior ramus of pubis, below longus, between gracilis and obturator externus.

Insertion (fl.-tend.) : lower two-thirds of the line which descends from the back of lesser trochanter to linea aspera ; and upper part of linea aspera.

In front of adductor brevis there are pectineus, adductor longus, profunda vessels and anterior division of obturator nerve. Adductor magnus and posterior division of obturator nerve are *behind* it. Ilio-psoas, obturator externus and medial circumflex vessels are related to *supero-lateral* border. First and second perforating branches of profunda vessels pierce it at *insertion*.

Nerve: obturator (L. 3, 4).

Same action as longus.

Adductor magnus lies between the flexors and the other adductors, and its tendon can be felt above the adductor tubercle behind the bulge made by vastus medialis.

Origin (fl.): lower lateral impression on ischial tuberosity, margin of ramus of ischium, femoral surface of inferior pubic ramus between brevis and obturator externus.

Insertion (tend.): (1) back of femur medial to gluteal tuberosity; (2) linea aspera; (3) medial supracondylar line; (4) adductor tubercle.

Attachment to supracondylar line is interrupted by an opening for the passage of femoral vessels. Posterior border is the part that arises from ischial tuberosity and is inserted into adductor tubercle by a strong, round tendon, some of whose fibres run into the medial ligament of knee. Upper part of pubic portion is sometimes a separate muscle called *adductor minimus*.

Nerves: obturator (L. 3, 4); sciatic (medial popliteal part) (L. 4, 5, S. 1).

It adducts and rotates thigh laterally. Ischial part extends hip; pubic part flexes it.

Obturator externus lies deeply, on front of pelvis, and passes below and behind neck of femur.

Origin (fl.): infero-medial half of outer surface of obturator membrane and the bone adjoining.

Insertion (tend.): floor of trochanteric fossa.

Nerve: obturator (L. 3, 4).

Rotates thigh laterally and flexes it.

Nerves and Vessels of Medial Side of Thigh.—Obturator nerve and vessels; profunda femoris vessels and their branches and tributaries; accessory obturator nerve when present (p. 381).

Obturator Nerve.—Arises in the abdomen from the second, third and fourth lumbar nerves. Descends into the pelvis, runs along its

side-wall, and passes into the thigh through the anterior part of the obturator foramen. As it does so, it divides into two branches which encounter the upper edge of the obturator externus at once.

Anterior division passes over obturator externus and runs downwards in front of obturator externus and adductor brevis, behind pectineus and adductor longus, and it ends as a filament to the femoral artery.

Branches: An **articular** filament to the hip-joint is the first branch, and it passes through the acetabular notch.

Muscular branches to adductor longus and brevis and to gracilis.

A *cutaneous* branch is sometimes sent to the subsartorial plexus and thence to the skin of the medial side of the thigh.

A *vascular* branch to the femoral artery.

Posterior division gives a branch to obturator externus and then passes through the muscle near its upper border to descend in front of the muscle on to the front of adductor magnus, first behind pectineus and then behind adductor brevis—the brevis being between the two divisions of the nerve.

Branches: **Muscular** to obturator externus and adductor magnus.

Articular to the knee-joint by means of a very slender filament that traverses adductor magnus near linea aspera and then descends along the popliteal artery to the back of the knee-joint.

Obturator Artery.—Arises in the pelvis from the internal iliac. Accompanies the nerve through the obturator foramen, and divides into two branches which form a circle around the margins of the obturator membrane. Branches are given to *muscles*, and an *acetabular branch* is sent into the hip-joint through the acetabular notch.

Obturator vein is formed by the union of veins that accompany the branches of the artery. It enters the pelvis through the obturator foramen and ends in the internal iliac vein.

Profunda Femoris Artery.—Arises from the lateral side of the femoral artery an inch and a half below the inguinal ligament, and passes downwards with a curve that brings it behind the femoral artery (*see* p. 221); and it leaves the femoral triangle by passing through its floor between pectineus and adductor longus. It then descends behind adductor longus, between it and magnus, close to the femur; and, greatly reduced by the number of large muscular branches which it gives off, it ends as the *fourth perforating artery*, which pierces adductor magnus at once.

Branches.—Large unnamed muscular; lateral circumflex (p. 221); medial circumflex; four perforating.

Medial Circumflex Artery.—Arises in the femoral triangle from the profunda near its origin (may arise from femoral). Passes backwards through a mass of fat behind the femoral vessels and leaves the triangle between psoas and pectineus.

It continues to pass backwards below obturator externus and above adductor brevis and then ends by dividing into *ascending* and *transverse* branches, seen in the gluteal region (p. 227). Before it ends it gives off *muscular* branches, and it sends an *acetabular*

branch through the acetabular notch and along the ligament of head of femur to the femur.

Perforating Arteries.—Four perforating arteries are given off after profunda has left the femoral triangle. They cling to the femur, and pierce the muscles and the lateral intermuscular septum to end in vastus lateralis. The second gives a *nutrient artery* to the femur; the others may do so also.

First pierces adductor brevis and magnus and gluteus maximus. **Second** pierces brevis and magnus and the short head of biceps. **Third** and **fourth** pierce adductor magnus and the short head of biceps.

Profunda Femoris Vein.—Begins as the fourth perforating vein, runs upwards in front of profunda artery and joins the femoral vein in the femoral triangle. Adductor longus is in front of the profunda vessels and separates them from the femoral vessels.

Its *tributaries* correspond to the branches of the profunda artery —except the circumflex veins. It does not reach high enough to receive them; and they join the big vein nearest to them—the femoral.

Hip-joint.—*See* p. 145.

FRONT AND LATERAL SIDE OF LEG AND DORSUM OF FOOT

Landmarks to be Identified in the Living Limb.—Head, neck and shaft of fibula. Condyles and tubercle of tibia; anterior and medial borders and medial surface of shaft of tibia.

And the following parts:—

The back of one **malleolus** is in the same plane as the back of the other. The lateral malleolus, however, does not reach so far forward as the medial one, but it reaches a lower level. There may be a subcutaneous *bursa* on each malleolus.

Tuberosity of navicular bone, an important landmark, is the prominence on the medial side of the foot an inch or more in front of and below the medial malleolus, at the level of the lip of the shoe.

Head, *shaft* and *base* of the **first metatarsal bone** are readily felt along the medial side of the foot. The bone felt on the medial side between its base and the tuberosity of navicular is the **medial cuneiform.**

The **fifth metatarsal bone** is felt along the lateral side. Its head, articulating with the proximal phalanx, makes a variable prominence behind the root of the little toe—at the widest part of the foot and much farther back than the first metatarso-phalangeal joint. When the foot is shod, this prominence is apt to be mistaken for the **tuberosity** of the base of fifth metatarsal, but the tuberosity is felt about midway between the little toe and the point of the heel.

The **cuboid** is behind the fifth and fourth metatarsal bones, and its lateral surface, which is small, is hidden in the depression on the margin of the foot behind the tuberosity of the fifth metatarsal. The articulation between cuboid and calcaneum—the lateral part

of the **transverse tarsal joint**—is therefore about half an inch behind that tuberosity. The medial part of that joint is immediately behind the tuberosity of navicular.

The tendons stand out when the living foot is dorsiflexed, and the **inferior extensor retinaculum** may then be felt in the depression below the ankle-joint. The thickest and most medial tendon is *tibialis anterior* descending to the medial side of the medial cuneiform. **Extensor hallucis longus** is immediately lateral to it; and, still more laterally, the **extensor digitorum longus** and **peroneus tertius** are seen. The swelling in front of the lateral malleolus, lateral to the extensor tendons, is the fleshy belly of **extensor digitorum brevis** and its tendons may be seen passing obliquely towards the medial four toes.

The **talus** is hidden below the tibia between the malleoli. But when the foot is plantar-flexed (*i.e.* the toes pointed) and inverted, its *head* is the knob felt beneath the extensor tendons antero-medial to the lateral malleolus, and its *body* may make a prominence near the ankle-joint close to the medial side of the lateral malleolus.

The *lateral surface* of **calcaneum** is nearly all subcutaneous and is the wide surface below the lateral malleolus between the point of the heel and the transverse tarsal joint; its *peroneal tubercle* (when present) is a little eminence felt about a finger's breadth below the lateral malleolus, between the tendons of peroneus longus and brevis; these two tendons may be felt (and even seen) slanting forwards and downwards from the back of the lateral malleolus over the calcaneum.

Superficial Fascia.—Contains: 1. A moderate quantity of *fat*.

2. Small *unnamed arteries* which come through the deep fascia from the deep arteries and are accompanied by small veins.

3. *Dorsal digital arteries* (p. 243).

4. *Dorsal digital veins*.

5. *Dorsal venous arch*.

6. Distal parts of both *saphenous veins*.

7. *Lymph-vessels*, which extend up through the leg and thigh to the superficial inguinal lymph-glands.

8. Parts of seven *nerves* to the skin.

Infrapatellar branch of **saphenous nerve** supplies skin of the uppermost part of front of leg; and the *terminal part* of the saphenous nerve supplies the hinder half of the medial side of foot.

Lateral cutaneous nerve of calf supplies skin of the upper third of leg below the infrapatellar nerve.

The medial and lateral cutaneous branches of **musculo-cutaneous nerve** supply skin (*a*) of leg below that, (*b*) of dorsum of foot, (*c*) medial side of foot and of big toe, and (*d*) contiguous side of second, third, fourth and fifth toes.

A terminal branch of **anterior tibial nerve** supplies the contiguous sides of the first and second toes.

The **sural nerve** descends behind the lateral malleolus and runs forwards supplying the lateral side of the foot and of the little toe.

Only the proximal parts of the dorsum of the digits are supplied

by these nerves. The distal parts are supplied by twigs that curve upwards from the plantar nerves—from **medial plantar nerve** to the medial three and a half toes, from **lateral plantar nerve** to the other one and a half.

Dorsal venous arch may be seen in the living foot. It lies across the foot near the toes, and receives the *dorsal digital veins* and unnamed veins of the dorsum of foot.

Short saphenous vein is formed by the union of a dorsal vein of little toe and the lateral end of the arch. It runs backwards along the lateral border of the foot with the sural nerve and bends upwards *behind* the lateral malleolus to enter the back of the leg.

Long saphenous vein, much wider, is formed by the medial end of the arch and a dorsal vein from the big toe; it passes upwards *in front of* the medial malleolus, and slants across the lower part of the shaft of the tibia to reach its medial border, along which it ascends to reach the thigh.

Deep Fascia.—Envelops the leg. Attached to the lig. patellæ and the subcutaneous bones at the knee. Blends with the periosteum of the medial surface of the tibia and the triangular subcutaneous surface of the fibula.

Intermuscular Septa.—The deep fascia sends in septa among the muscles of the leg, and the muscles take partial origin from them.

The two strongest septa on the front and lateral side of the leg are named:—**Anterior intermuscular septum** is attached to the anterior border of fibula and separates extensor digitorum longus and peroneus tertius from peroneus longus and brevis. **Posterior intermuscular septum** is attached to the posterior border of fibula and separates these two peroneal muscles from two muscles in the back of the leg—soleus and flexor hallucis longus.

Near the knee the deep fascia is strengthened by expansions from the tendons of sartorius, gracilis, semitendinosus and biceps; and it gives partial origin to the underlying muscles.

Lower down, it is thinner (and exceedingly thin on the dorsum of foot) except where thickened to form bands, called *retinacula*, which strap down the tendons and hold them in place when the muscles contract, and also help to bind together the bones to which they are attached:—

Superior Extensor Retinaculum.—Attached to the anterior borders of tibia and fibula immediately above the ankle-joint. About an inch in depth. Often not clearly defined from adjoining deep fascia. Holds down the extensors and peroneus tertius and tibialis anterior. A septum cuts off a compartment for the tibialis anterior, which alone has a *synovial sheath* at that level.

Inferior Extensor Retinaculum.—Distal to the ankle-joint. More important than the superior retinaculum. Occasionally X-shaped; usually shaped like a Y placed transversely ≻. *Stem* of the Y is attached to the anterior part of upper surface of calcaneum, and a great part of extensor digitorum brevis arises from it. *Proximal limb* is attached to the medial malleolus; *distal limb* blends with the deep fascia on the medial side of the foot, and can be traced

into the sole. The inferior retinaculum is continuous proximally and distally with deep fascia but is well defined.

It straps down :—(1) tibialis anterior ; (2) extensor hallucis longus ; (3) dorsalis pedis vessels and anterior tibial nerve ; (4) extensor digitorum longus and peroneus tertius—named from medial to lateral side—and these structures occupy four separate compartments.

The compartment for the vessels and nerve is deep to the retinaculum ; but the retinaculum splits to form the compartments for the tendons, and the deeper layer is adherent to the periosteum and ligaments of the tarsal bones. The compartments for tendons are lined with their synovial sheaths—that for extensor digitorum and peroneus in the stem of the Y, the other two in both of its limbs. The superficial layer is very thin over tibialis anterior.

Superior Peroneal Retinaculum.—Holds the tendons of peroneus longus and brevis against the back of the lateral malleolus. It is attached to the margins of the back of the malleolus, and, medially, it is connected also with the calcaneum and a layer of fascia placed deeply in the back of the leg. It is lined with a single synovial sheath which encloses both tendons.

Inferior Peroneal Retinaculum.—Straps these two peroneal tendons to the lateral side of the calcaneum. It is attached to calcaneum below the tendons and passes up over them to be attached to the anterior part of the upper surface of calcaneum, where it is partly continuous with the stem of the inferior extensor retinaculum. A septum attached to calcaneum between the tendons divides it into two compartments. The synovial sheath behind the malleolus divides to line each compartment and enclose the tendons separately.

The peroneal retinacula are not so clearly marked off from adjoining fascia as the other retinacula are.

Muscles.—*On front of leg and dorsum of foot* : tibialis anterior ; extensor hallucis longus ; extensor digitorum longus ; peroneus tertius. *On dorsum of foot* : extensor digitorum brevis. *On lateral side of leg* : peroneus longus and brevis.

Tibialis anterior lies immediately lateral to the tibia.

Origin (fl.) : chiefly from the upper two-thirds of the lateral surface of the shaft of the tibia and from the interosseous membrane.

Its tendon passes downwards, forwards and medially through both extensor retinacula and over the ankle-joint and tarsus to be inserted into the medial surface of medial cuneiform near the sole and into the base of first metatarsal.

Nerve : anterior tibial (L. 4, 5, S. 1).

It dorsiflexes and inverts the foot.

Extensor digitorum longus lies lateral to tibialis ant.

Origin (fl.) : chiefly from the upper two-thirds of the anterior surface of fibula.

Insertion: middle and distal phalanges of the lateral four toes.

The tendon descends behind the superior extensor retinaculum, crosses the ankle-joint, passes through the stem of the inferior retinaculum and divides there into four tendons, which run to the lesser four toes.

On the dorsum of the first phalanx, each tendon spreads out to form an **extensor expansion**, which splits into three. The *middle* part steps across the joint to be inserted into the base of the middle phalanx ; the two *collateral* parts unite and run on to the base of the distal phalanx. On the second, third and fourth toes, the expansion is joined by the tendons of two interossei and one lumbrical muscle and a tendon of extensor brevis. On the little toe, it is joined by one interosseous and one lumbrical.

The tendons replace or fuse with the capsular ligaments on the dorsum of the metatarso-phalangeal and inter-phalangeal joints.

Nerve: anterior tibial (L. 4, 5, S. 1).

It extends toes and dorsiflexes foot.

Peroneus tertius is continuous with ext. dig. longus.

Origin (fl.) : distal third of anterior surface of fibula.

Tendon passes through the stem of the inferior extensor retinaculum in same synovial sheath as ext. dig. longus, and is **inserted** into dorsum of base of 5th metatarsal.

Nerve: anterior tibial (L. 4, 5, S. 1).

It everts and dorsiflexes foot.

Extensor hallucis longus lies between tibialis ant. and ext. dig. longus, and is partly hidden by them.

Origin (fl.) : middle three-fifths of ant. surface of fibula.

Crosses anterior tibial vessels and nerve either above the superior extensor retinaculum or behind it ; and its tendon crosses the ankle-joint close by the lateral side of tibialis anterior, pierces the inferior retinaculum, and runs forwards over the tarsus, first metatarsal bone and proximal phalanx of the big toe to be inserted into the dorsum of the base of the distal phalanx.

Nerve: anterior tibial (L. 4, 5, S. 1).

It extends the big toe and dorsiflexes the foot.

Extensor digitorum brevis lies on the lateral part of the

dorsum of foot partly under cover of the tendons of extensor digitorum longus and peroneus tertius.

Arises chiefly from the stem of the inferior extensor retinaculum and also from the calcaneum.

Divides into four fleshy bellies which run obliquely forwards and medially beneath the tendons of extensor longus and end in four tendons for the *medial* four toes.

The tendon for the big toe (*extensor hallucis brevis*) crosses either the first dorsal metatarsal artery or the dorsalis pedis artery (as that artery dips towards the sole).

It is **inserted** independently into the dorsum of the base of the proximal phalanx of the big toe; and it extends the metatarso-phalangeal joint.

The other three tendons join the extensor expansions; and they assist in extending the metatarso-phalangeal and interphalangeal joints.

Nerve: lateral branch of anterior tibial (L. 4, 5, S. 1).

Peroneus longus lies superficially in front of the calf.

Origin (fl.): chiefly from upper two-thirds of lateral surface of fibula.

Tendon lies behind the brevis on the back of lateral malleolus, and below brevis on the lateral surface of calcaneum. It traverses the groove on the plantar surface of cuboid; and is **inserted** into the lateral side of the base of first metatarsal and medial cuneiform near the sole (compare insertion of tibialis anterior).

Nerve: musculo-cutaneous (L. 4, 5, S. 1).

It everts the foot and extends or plantar-flexes it.

Peroneus brevis lies deep to longus, and in front of it.

Origin (fl.): distal two-thirds of lateral surface of fibula.

Tendon passes downwards over the back of lateral malleolus and forwards over the lateral surface of calcaneum to be **inserted** into the lateral side of the tuberosity on the base of fifth metatarsal bone.

Nerve and **actions**: same as longus.

Synovial Sheaths of Tendons.—Each synovial sheath has two layers—one within the other like a bicycle-tube doubled into itself. The inner layer ensheaths the tendon or tendons; the outer layer lines the walls of the tunnel or space traversed by the tendon. But, unlike the invaginated bicycle-tube, the two layers are continuous with each other at both ends, and the space between them is therefore closed. This space is occupied by synovia exuded by the layers

of the sheath; the synovia lubricates the layers and lessens the friction as the tendon moves.

Sheath of tibialis anterior begins at the upper border of the superior extensor retinaculum and extends almost to the insertion of the tendon. It may be interrupted at the ankle and begin afresh.

Sheath of extensor hallucis longus begins between the retinacula and reaches the proximal phalanx.

The **sheath of extensor digitorum longus and peroneus tertius** reaches from the lower border of the superior retinaculum to the middle of the dorsum of the foot.

The **peroneal sheath** begins two inches above the tip of malleolus and at first envelops both tendons. It divides on the lateral surface of the calcaneum, and each reaches almost to the insertion, but the sheath of longus may be interrupted as it enters the sole.

Deep Vessels and Nerves.—Anterior tibial and dorsalis pedis vessels and their branches and tributaries; perforating branch of peroneal artery and its vein; terminal branches of lateral popliteal nerve—recurrent genicular, anterior tibial and musculo-cutaneous.

Anterior Tibial Artery.—A terminal branch of popliteal. Arises in the back of the leg at the lower border of popliteus opposite the tubercle of the tibia. Passes forwards through a hole in the interosseous membrane close to the neck of the fibula, descends over the front of the interosseous membrane, passes on to the lower end of the tibia and ends at the ankle-joint midway between the malleoli by becoming the dorsalis pedis.

Venæ comitantes lie alongside it, and the anterior tibial nerve is a close companion. They are all at first deeply placed and hidden by the muscles, but near the ankle they are near the surface between the two long extensors.

Branches.—Muscular at intervals; circumflex fibular; posterior and anterior recurrent; lateral and medial malleolar.

Circumflex fibular and *posterior recurrent* arise in the back of the leg (p. 250).

Anterior tibial recurrent arises in the upper part of the front of the leg and accompanies the recurrent genicular nerve.

Lateral and medial malleolar arise near the ankle and ramify over the malleoli.

Dorsalis Pedis Artery.—Begins on the front of the ankle-joint midway between the malleoli, and, with companion veins and the anterior tibial nerve, it runs forwards on the tarsus along the lateral side of extensor hallucis longus to the *proximal* end of the first intermetatarsal space. At that point, it dips downwards between the two heads of the first dorsal interosseous muscle into the sole, where it forms the medial end of the plantar arterial arch.

Branches.—Tarsal; arcuate; first dorsal metatarsal; and, in the sole, first plantar metatarsal (p. 256).

Tarsal arteries are small arteries to the medial side of the foot,

and a larger branch that arises at the navicular bone and runs laterally under the extensor digitorum longus and brevis.

Arcuate artery arises near the bases of the metatarsals and runs laterally near or on them below the extensor tendons. It sends three *dorsal metatarsal arteries* forwards over the interosseous muscles in the lateral three spaces, and they send *dorsal digital arteries* to the smaller toes.

First dorsal metatarsal artery arises as dorsalis pedis begins to dip; it runs forwards over the first interosseous muscle and divides into *dorsal digital arteries* for both sides of the big toe and the medial side of the second toe.

Perforating Branch of Peroneal Artery.—Small. Arises from the peroneal in the back of the leg, perforates the interosseous membrane about two inches above the ankle-joint and descends to anastomose with lateral malleolar and tarsal arteries.

The lateral popliteal nerve passes from behind the head of the fibula on to the lateral side of its neck and ends there between the bone and peroneus longus by giving off the recurrent genicular nerve and then dividing into the anterior tibial and musculocutaneous.

Recurrent genicular nerve passes obliquely upwards through extensor digitorum longus and tibialis anterior to the capsule of the knee-joint; on its way it gives a branch to tibialis anterior and sends one to the superior tibio-fibular joint.

Anterior Tibial Nerve.—Enters the front of the leg by piercing the anterior intermuscular septum and extensor digitorum longus. Runs downwards over the interosseous membrane hidden between tibialis anterior and extensor hallucis. Passes on to the lower end of the tibia where it is more superficial—behind the superior retinaculum—and, having been crossed from lateral to medial side by extensor hallucis, it lies between hallucis and digitorum. It is first lateral to the artery (since they enter the front of the leg from opposite sides of the fibula) and next on the front of the artery and then lateral to the artery again.

Enters the foot at the ankle-joint midway between the malleoli, and ends beneath the inferior retinaculum by dividing into a lateral and a medial terminal branch.

Branches.—**Muscular:** to tibialis anterior, extensor hallucis longus, extensor digitorum longus and peroneus tertius; and, by means of its lateral terminal branch, to extensor digitorum brevis.

Filaments, which may be sensory, can sometimes be traced from the medial terminal branch to the first dorsal interosseous muscle and from the lateral terminal to the second muscle.

Articular: to ankle-joint; and, from the terminal branches, to *tarsal joints* and *joints of big toe.*

Cutaneous: by medial terminal, to contiguous sides of big toe and second toe.

Lateral terminal branch disappears under extensor digitorum brevis; supplies it and tarsal joints.

Medial terminal branch runs forwards along the medial side of the medial tendon of extensor digitorum longus and usually lateral to dorsalis pedis, over the tarsus and on to the first dorsal interosseous muscle, pierces the deep fascia on that muscle and divides to supply the skin of the first cleft. On its way it gives branches to tarsal joints, and the tarso-metatarsal and other joints of the big toe and second toe.

Musculo-Cutaneous Nerve.—Like the anterior tibial, a terminal branch of the lateral popliteal, and begins on the lateral side of the neck of the fibula under cover of peroneus longus. Descends through peroneus longus till it reaches the upper end of peroneus brevis, and runs for a short distance between brevis and longus. It then slips down over the anterior border of brevis and lies in the groove between it and extensor digitorum under cover of the deep fascia. Reaching the distal third of the leg, it pierces the deep fascia and very soon divides into a lateral and a medial terminal branch. They descend through the leg into the dorsum of foot, and through it, under the dorsal venous arch, to the toes.

Branches.—**Muscular :** to peroneus longus and brevis as it descends through longus.

Cutaneous : by its terminal branches, to the lower part of the front of the leg, dorsum of foot and most of the toes.

Lateral terminal branch supplies lower part of leg, intermediate part of dorsum of foot, fifth and fourth toes and half of the third.

Medial branch supplies lower part of leg, medial part of dorsum of foot, adjacent sides of third and second toes and the medial half of the big toe.

BACK OF LEG

Landmarks to be Identified in the Living Limb.—Condyles of femur and tibia ; head of fibula ; anterior and medial borders of tibia. Gastrocnemius and soleus; tendo calcaneus. Backs of malleoli. Pulse of posterior tibial artery. Lateral and medial tubercles of calcaneum ; sustentaculum tali, which is the bony resistance felt a thumb's breadth directly below the medial malleolus.

Superficial Fascia.—Contains : 1. A moderate quantity of *fat.*

2. Lateral and medial *calcanean vessels* (pp. 250, 255) ; and small *unnamed arteries* that come through the deep fascia from the deep arteries and are accompanied by *unnamed veins* which connect the deep veins with the saphenous veins.

3. Long and short *saphenous veins.*

4. *Lymph-vessels.*

5. Several *cutaneous nerves.*

Superficial **lymph-vessels** mostly pass obliquely to the front and ascend to the superficial inguinal glands, but some accompany the short saphenous vein, and, like the lymph-vessels of the deeper parts

of the calf, they end in the popliteal glands, which send their efferent vessels to the deep inguinal glands.

Short Saphenous Vein.—Begins by the union of the lateral end of the dorsal venous arch with the lateral dorsal digital vein of the little toe. Runs backwards along the lateral side of the foot and upwards *behind* the lateral malleolus; makes for the middle line of the calf and ascends in that line to the lower part of the popliteal fossa, where it pierces the deep fascia and ends in the popliteal vein. It has nearly a dozen valves.

Long Saphenous Vein.—Has over a dozen valves. Longest vein in the body. Begins by the union of the medial end of dorsal venous arch with the medial dorsal digital vein of big toe. Passes backwards to the medial malleolus, and upwards *in front of* it; then obliquely over the distal third of medial surface of tibia to its medial border and onwards to the medial side of the knee, far back. From the knee, it ascends obliquely to the saphenous opening, bends backwards over its lower edge through the cribriform fascia, pierces the lowest part of the femoral sheath and ends at once in the femoral vein, an inch and a half below the inguinal ligament.

It is connected with the short saphenous vein and with the deep veins; numerous unnamed tributaries enter it; and, near its termination, it receives the three superficial inguinal veins—superficial epigastric, superficial external pudendal and superficial circumflex iliac.

Saphenous Nerve.—Pierces the deep fascia far back at the medial side of the knee and descends close to the long saphenous vein, either behind or in front of it, first along medial border of tibia, then across distal third of tibia and then in front of the medial malleolus, to end at the middle of the medial side of the foot.

Supplies skin of the medial side of leg and foot.

Sural Nerve.—Arises in the popliteal fossa from the medial popliteal and leaves the fossa through its lower angle. Descends between the heads of gastrocnemius under the deep fascia, which separates it from the short saphenous vein. Pierces the deep fascia about half-way down the leg and runs alongside the short saphenous vein, first downwards to the back of the lateral malleolus and then forwards below the malleolus and along the lateral margin of the foot to the lateral side of the little toe. At the malleolus the nerve and the vein lie on the peroneal retinaculum.

Supplies skin of lower lateral part of back of leg, lateral part of dorsum of foot and lateral side of little toe, and sends a branch to the lateral terminal branch of musculo-cutaneous to help in the supply of the sides of the fifth and fourth toes.

Sural Communicating Nerve.—Arises from the lateral popliteal just above the lateral angle of the popliteal fossa. Leaves the fossa by passing on to the lateral head of gastrocnemius. Pierces the deep fascia about an inch lower down, and descends to join the sural nerve two inches above the heel, supplying skin of lateral part of back of leg before doing so.

Lateral Cutaneous Nerve of Calf.—Arises from the lateral popliteal as it lies on the lateral head of gastrocnemius at the lateral

angle of the popliteal fossa. Pierces the deep fascia almost at once, and supplies skin of the lateral side of the upper third of the leg both on the back and the front.

Posterior Cutaneous Nerve of Thigh (p. 229).—Pierces the popliteal fascia and descends alongside the short saphenous vein, supplying skin as far as the middle of the calf. The saphenous vein is accompanied therefore by this nerve in the upper half of the leg and by the sural nerve in the rest of its course.

Posterior Branch of **Medial Cutaneous Nerve of Thigh** (p. 212).—Pierces the deep fascia a little above the knee behind the long saphenous vein and descends to supply skin of the medial part of the back of the upper third of the leg.

Medial Calcanean Nerves.—From posterior tibial (p. 249). Supply skin of the back and lower surface of the heel.

Deep Fascia.—Includes the investing fascia and two strong septa set in the coronal plane among the muscles.

Investing deep fascia is thin in the upper part of the back of the leg, thicker in the lower part especially behind the malleoli, where it is strengthened to form the superior peroneal retinaculum (p. 239) and the flexor retinaculum.

Flexor Retinaculum.—A strong, thick, wide band, formed partly by the investing fascia but chiefly by the lower part of the first septum.

Passes downwards and backwards from the medial border of the back of the medial malleolus to the medial side of the medial tubercle of calcaneum. Bridges the interval over the back of malleolus, the hinder part of the medial side of talus and the medial side of calcaneum between tendo calcaneus and sustentaculum tali. Straps down the tendons and nerves and vessels on their way from the back of the leg to the sole of the foot.

These structures lie in this order from above downwards or from medial to lateral side: tibialis posterior; flexor digitorum longus; posterior tibial artery and its terminal branches with companion veins; posterior tibial nerve and its terminal branches; flexor hallucis longus. Septa pass from the retinaculum to the bones and divide the underlying space into four compartments—one for each tendon and one for the vessels and nerves. The compartments or tunnels for the tendons are lined with their synovial sheaths.

Proximally, the retinaculum is continuous with the investing fascia and the first septum (being parts of them). Distally, its margin is continuous with the deep fascia of the sole and gives origin to a great part of abductor hallucis. Near the calcaneum, it is pierced by the medial calcanean nerves and vessels.

Fascial Septa of Back of Leg.—**First fascial septum** stretches from the medial border of tibia to the posterior border of fibula, deep to the soleus; and it covers the flexors of the toes and the posterior tibial nerve and vessels.

Superiorly, it is attached to the soleal line of the tibia, and to the back of the fibula below the origin of soleus; but, in the middle, between the bones, it is continuous with the fascia that covers

popliteus and is pierced from behind forwards by the popliteal vessels. The fascia over the popliteus is largely formed by an expansion from the tendon of semimembranosus. The lower margin of the opening made by the vessels is thickened to form an arch over their most distal part, and some fibres of soleus arise from the arch.

Inferiorly, in the middle, the septum is lost in the fatty tissue under tendo calcaneus, but at the sides it is continued into the flexor retinaculum and superior peroneal retinaculum.

Second fascial septum covers tibialis posterior and separates it from the flexors of the toes, and it gives partial origin to all of them. It fuses superiorly with the interosseous membrane and inferiorly with the first septum.

Muscles of Back of Leg. — *Superficial*: gastrocnemius; plantaris; soleus. *Deep*: popliteus; flexor digitorum longus; flexor hallucis longus; tibialis posterior.

Gastrocnemius and soleus are **inserted** by a common tendon, called **tendo calcaneus** (seen above heel), into the middle area of posterior surface of calcaneum. The tendon is separated from upper area by a *bursa*, and from bones of leg and from ankle-joint by a wide interval filled with fatty areolar tissue. There may be a subcutaneous bursa between the skin and the back of the tendo.

They are plantar-flexors of the foot; gastrocnemius also flexes the knee.

Gastrocnemius lies superficially in calf. Its two heads form distal boundaries of popliteal fossa and lie on post. part of capsule of knee; medial head is partly separated from capsule by a *bursa*, which may communicate with the joint and with *bursa* between semimembranosus and gastrocnemius. *Bursa* deep to lateral head is less common. There may be a sesamoid bone in lateral head.

Origin (tend.): *Lateral head*: upper part of lateral surface of lateral condyle. *Medial head*: rough mark on popliteal surface of femur above the medial condyle.

Nerve: medial popliteal (S. 1, 2).

Soleus lies largely under cover of gastrocnemius.

Origin (fl.-tend.): back of head and upper third of shaft of fibula; soleal line and middle third of medial border of tibia.

Nerves: medial popliteal and post. tibial (L. 5, S. 1, 2).

Plantaris.—Sometimes absent. Lies between gastrocnemius and soleus.

Origin (fl.): popliteal surface above lateral condyle.

Insertion: by tendon (the longest in body and capable of great transverse stretching) usually into medial tubercle of calcaneum.

Nerve: medial popliteal (L. 4, 5, S. 1).

Same action as gastrocnemius.

Popliteus lies in distal part of floor of popliteal fossa.

Origin: by tendon, from ant. end of popliteal groove on lateral surface of lateral condyle of femur. Tendon lies within fibrous capsule of knee, between capsule and lateral semilunar cartilage, opposite lateral lig. of knee, and separated from the cartilage by a sheath derived from the synovial membrane of knee. It lies in popliteal groove only in extreme flexion; lies on its distal edge during extension.

Pierces the posterior part of the capsule of knee, becomes fleshy, and spreads out to be **inserted** into the soleal line of tibia and into the surface above that.

Nerve: medial popliteal (L. 4, 5, S. 1).

It flexes leg and rotates it medially.

Flexor digitorum longus lies in tibial part of back of leg, and its tendon is in sole of foot.

Origin (fl.): upper two-thirds of the area medial to the vertical line on the back of tibia.

Tendon passes on to the back of tibialis posterior above the malleolus, and crosses tibialis to lie on its lateral side on most medial part of back of ankle-joint under cover of the flexor retinaculum. Runs forwards superficial to the edge of sustentaculum tali and enters the sole, where it divides into four tendons. These tendons pass to the lateral four toes, and each is **inserted** into the plantar surface of the base of the distal phalanx (p. 253).

Nerve: posterior tibial (L. 5, S. 1).

It flexes toes, and is a plantar-flexor of the foot.

Flexor hallucis longus lies in fibular part of back of leg and its tendon is in sole of foot.

Origin (fl.): Distal two-thirds of posterior surface of fibula.

Tendon crosses the back of the ankle-joint opposite tendo calcaneus to enter the groove on the back of the talus; it then passes through the most lateral compartment of flexor retinaculum and enters the sole, where it runs forwards to be **inserted** into the plantar surface of

the base of the distal phalanx of the big toe. As it enters the sole it lies in the groove on the lower surface of the sustentaculum tali.

Nerve: posterior tibial (L. 5, S. 1, 2).

It flexes big toe and plantar-flexes foot.

Tibialis posterior is the deepest muscle in back of leg.

Origin (fl.) : Posterior surface of fibula in front of medial crest ; upper two-thirds of back of tibia, lateral to the vertical line ; interosseous membrane.

Tendon passes on to the back of the medial malleolus and through the uppermost or most medial compartment of the flexor retinaculum, and on to the deltoid ligament just above the sustentaculum tali. It then enters the sole, where it is inserted chiefly into tuberosity of navicular and medial cuneiform ; by slips also into all other tarsals except talus, and into bases of 2nd, 3rd and 4th metatarsals.

Nerve: posterior tibial (L. 5, S. 1).

It inverts and plantar-flexes the foot.

Synovial sheaths of tendons begin an inch above the retinaculum. They accompany tibialis posterior and flexor hallucis almost to insertion, and digitorum to the middle of the sole (p. 254).

Deep Vessels and Nerves.—End of popliteal artery (p. 230) ; beginning of anterior tibial artery and two of its branches ; posterior tibial artery and its branches, especially the peroneal ; corresponding veins ; posterior tibial nerve and its branches.

Posterior Tibial Nerve.—The continuation of medial popliteal. Begins at the lower border of popliteus, descends under cover of the first fascial septum and ends under cover of the flexor retinaculum about midway between calcaneum and medial malleolus by dividing into lateral and medial plantar.

It is medial to the first inch of the posterior tibial artery but crosses behind the artery at the origin of its peroneal branch to run along its lateral side.

It is covered by soleus and fascia except its lowest part, which is covered only by fascia including the retinaculum. It lies, in succession, on the septum that covers tibialis posterior, on flexor digitorum, on the lower end of tibia and on the ankle-joint.

Branches.—**Muscular** : To tibialis posterior, flexor digitorum longus, flexor hallucis longus, deep part of soleus.

Articular : To ankle-joint.

Cutaneous : *Medial calcanean*—two or three—which pierce the flexor retinaculum and supply skin of the back and lower surface of the heel.

Anterior Tibial Artery.—A terminal branch of popliteal. Leaves the back of the leg almost at once by piercing the interosseous membrane, but, before doing so, it gives off two branches :—

Circumflex fibular artery curves round the neck of fibula supplying muscles and skin.

Posterior tibial recurrent artery runs up in front of popliteus to the knee-joint.

Posterior Tibial Artery.—The other and larger terminal branch of the popliteal. Begins at the lower border of popliteus. Accompanied by *venæ comitantes*, it runs along the nerve and ends slightly lower than the nerve under the retinaculum by dividing into lateral and medial plantar.

Branches.—1. *Muscular* and *cutaneous* at intervals. 2. *Nutrient artery to tibia* arises high up.

3. *Peroneal.* 4. *Communicating branch* arises an inch above calcaneum and passes transversely behind flexor hallucis (or in front of it) to join the peroneal.

5. *Medial calcanean* accompany the nerves. 6. Terminal branches.

Peroneal Artery.—A large artery. Arises from posterior tibial about an inch below popliteus, at the point where the posterior tibial nerve crosses the artery. Accompanied by *venæ comitantes*, it runs downwards and laterally over tibialis posterior in front of soleus to reach the fibula, and then along the fibula on the interosseous membrane in front of flexor hallucis. Escapes from hallucis near the ankle joint, descends across the inferior tibio-fibular joint and the ankle-joint medial to the peroneal tendons, pierces the deep fascia and ends by dividing into the *lateral calcanean arteries*.

Branches.—1. *Muscular* at intervals. 2. *Nutrient artery to fibula* arises at the middle of the leg. 3. *Perforating branch* pierces the lowest part of the interosseous membrane to gain the front (p. 243). 4. *Lateral calcanean*, which branch over the lateral surface of calcaneum.

SOLE OF FOOT

Landmarks to be Identified in the Living Foot.—Lateral and medial tubercles of calcaneum. Flexor retinaculum. Sustentaculum tali ; tuberosity of navicular bone ; medial cuneiform bone ; first metatarsal bone. Fifth metatarsal bone and its tuberosity.

The *ball of the foot* is the swelling that underlies the metatarso-phalangeal joints. Its medial part is the **ball of the big toe** and is the biggest part owing to the large size of the first joint and to the two sesamoid bones that replace the plantar ligament of that joint.

Superficial Fascia.—Traversed by fibrous bands that divide the fat into lobules. It is thickened on the heel, the ball of foot, and the pulp of toes. On the toes it contains digital vessels and nerves ; in the sole it contains vessels and nerves from various sources, and the superficial transverse ligament :—

Medial calcanean nerve arises from the posterior tibial nerve as it lies under cover of the flexor retinaculum; it pierces the retinaculum as several branches which turn laterally and ramify over the back and the sole of the heel. They are accompanied by the **medial calcanean branches** of the posterior tibial and lateral plantar arteries.

Sural nerve (p. 245) gives branches to the sole as well as to the dorsum of the foot. And, on the medial side, some branches come from the **saphenous nerve.**

Medial and **lateral plantar nerves** and **arteries** send cutaneous branches to the intermediate part of the sole.

Superficial transverse ligament lies across the roots of the toes and in the webs near their free edges, on the plantar side of digital vessels and nerves.

Deep Fascia.—Medial and lateral parts cover the abductors and short flexors of the big toe and little toe, and are thin, except along the lateral border of the foot, where a strong band extends from the lateral tubercle of calcaneum to the base of the fifth metatarsal. This band is a remnant of *extensor ossis metatarsi digiti quinti.*

The intermediate part of the deep fascia is called the plantar aponeurosis.

Plantar Aponeurosis.—Covers flexor digitorum brevis, is very dense and strong, and assists in preserving the arch of the foot. It is triangular in outline.

Apex is attached to the medial tubercle of calcaneum.

Base divides into five slips connected with each other by *transverse fibres* (cf. palm, in which the palmar aponeurosis divides into four slips). A few superficial fibres of each slip run on to the skin of the creases of the toes; but the main part divides into two bands. These bands diverge and pass upwards to be attached to the deep transverse ligaments; and their anterior edges are continuous with the proximal end of the fibrous flexor sheath.

From the two **margins** of the aponeurosis, *septa* pass upwards into sole over the sides of the flexor digitorum brevis and separate it from the abductors of the big toe and little toe; they fuse with the fascia that covers the upper surfaces of these three muscles; and these muscles take partial origin from them and from the fascia that covers their superficial surface.

Fibrous Flexor Sheaths.—*Deep fascia on the toes* is thickened to form them. They are attached:—(1) To the margins of the proximal phalanx of the big toe and the margins of the proximal and middle phalanges of the other toes; (2) to the margins of the plantar ligaments of the joints; and (3) to the plantar surfaces of the distal phalanges beyond the insertion of flexor tendons. Together with the phalanges and the ligaments, they form tubes occupied by the flexor tendons and their synovial sheaths. They are firm and dense opposite the phalanges; but they are thin opposite the joints, so that movements of the joints are not interfered with.

Plantar ligaments and the deep transverse ligs., mentioned above, are connected with joints.

Plantar ligament, a dense fibrous plate, is attached firmly to the plantar surface of the base of the proximal phalanx, but only loosely

to the metatarsal, behind its head. Its *upper surface* is in contact with the head of the metatarsal and forms part of its socket. Its *plantar surface* is covered by flexor tendons. Its *margins* are connected with the fibrous flexor sheath, with slips of the plantar aponeurosis, with the collateral ligaments of the joint and with the deep transverse ligaments.

Interphalangeal joints have similar plantar ligaments.

Deep transverse ligaments of the sole are four flat bands that connect the margins of the plantar ligaments of the metatarsophalangeal joints (cf. hand, in which there are only three bands). Digital vessels and nerves, and lumbricals, lie on their *plantar* surfaces; interosseous muscles on their *dorsal* surfaces.

As the tendons of flexor digitorum longus, flexor hallucis longus and tibialis posterior, and the posterior tibial vessels and nerve pass from the leg towards the sole, they are bound down by a thickening of deep fascia of the leg called *flexor retinaculum*. (*See* p. 246.)

Muscles and Tendons.—These are arranged in four layers.

First Layer of Muscles of Sole of Foot.—Abductor hallucis, flexor digitorum brevis, abductor digiti minimi.

Abductor hallucis covers the long tendons as they enter sole, and lies along the medial side of the sole.

It **arises** by tendinous and fleshy fibres chiefly from the flexor retinaculum and the medial tubercle of calcaneum; and is **inserted** by tendon into the medial side of the base of the proximal phalanx of the big toe.

It abducts and flexes the big toe. *Medial plantar nerve* supplies it by fibres derived from the fifth lumbar and first sacral nerves.

Flexor digitorum brevis arises by fleshy and tendinous fibres from the medial tubercle of calcaneum, and divides into four bellies for the lateral four toes.

Each belly becomes a tendon which enters the fibrous flexor sheath opposite the head of the metatarsal, on the plantar surface of the long flexor tendon, and it splits opposite the proximal phalanx to allow the long flexor to pass through it. The halves re-unite above the long flexor, and, after partial decussation, separate to be **inserted** into the margins of the middle phalanx.

It flexes the middle and proximal phalanges. *Medial plantar nerve* supplies it by fibres from L. 5, S. 1.

Abductor digiti minimi arises by fleshy and tendinous fibres from the medial tubercle of calcaneum under cover of flexor digitorum brevis, and from the lateral tubercle. It is **inserted** by tendon into the lateral side of the base of the proximal phalanx of the little toe, and often also into the base of the fifth metatarsal.

It abducts and flexes the little toe. *Lateral plantar nerve* supplies it by fibres from S. 1, 2.

Second Layer of Muscles of Sole of Foot.—Flexor hallucis longus, flexor digitorum longus with flexor accessorius and four lumbricals.

Flexor digitorum longus tendon, after entering the sole, crosses superficial to the tendon of hallucis and obtains from it a slip which usually passes into the tendons for the second and third toes. The tendon receives also the insertion of flexor accessorius ; and it divides into four tendons for the lateral four toes.

The tendons give origin to lumbrical muscles ; and each enters a fibrous flexor sheath, enclosed with the corresponding tendon of flexor brevis in a synovial sheath ; it perforates that tendon opposite the proximal phalanx, and runs on to **insertion** into the plantar surface of the base of the distal phalanx.

Superficial to it, in succession from above the ankle-joint to the fibrous flexor sheath, are :—(1) flexor retinaculum, (2) abductor hallucis, (3) medial plantar vessels and nerve, (4) flexor digitorum brevis.

Deep to it are :—(1) tibialis posterior, (2) ankle-joint, (3) edge of sustentaculum tali, (4) flexor hallucis longus, (5) sheath of peroneus longus, (6) adductor hallucis.

Flexor digitorum accessorius lies deep to the posterior part of flexor digitorum brevis.

It **arises** :—(1) from the long plantar lig. (part of which it covers), and also by (2) a tendinous head from the lateral edge of the plantar surface of calcaneum, (3) a fleshy head from the medial surface of calcaneum.

It is **inserted** into the tendon of flexor digitorum longus.

It changes the oblique direction of the pull of that tendon into one in line with the long axis of the foot ; and, by contracting independently, it can flex the distal phalanges without the stability of the ankle-joint being impaired—*e.g.*, walking over a slippery surface.

Lateral plantar nerve supplies it by fibres from S. 1, 2.

Lumbrical Muscles.—Four slender muscular bellies. Smaller than those of hand.

Their tendons pass upwards and forwards on the medial sides of the metatarso-phalangeal joints of the lateral four toes ; each is **inserted** into the extensor tendon, and it is connected by fascia with the base of the proximal phalanx and the capsule of the joint.

Each flexes the proximal phalanx, since it passes from below upwards over the joint ; and it extends the middle and distal phalanges, since it is inserted into the extensor tendon.

First arises from the medial side of the tendon of the long flexor for the second toe, and is supplied by the second digital branch of the *medial plantar nerve* (fibres ultimately from L. 5, S. 1).

Second, third and **fourth** arise from contiguous sides of the four tendons of flexor longus, and are supplied on their dorsal surfaces by the deep branch of the *lateral plantar nerve* (fibres ultimately from S. 1, 2).

Flexor hallucis longus tendon, after entering the sole, is crossed superficially by flexor digitorum longus, and gives it a slip which goes usually into tendons for second and third toes. It is **inserted** into the plantar surface of the base of the distal phalanx of the big toe.

Superficial to it, from above the ankle-joint to the flexor fibrous sheath, are : (1) flexor retinaculum and (2) lateral plantar vessels

and nerve; (3) abductor hallucis, (4) medial plantar vessels and nerve, and (5) flexor digitorum longus; (6) flexor digitorum brevis, overlapping; (7) deep fascia.

Deep to it there are:—(1) distal end of tibia, (2) ankle-joint, (3) posterior surface of talus, (4) plantar surface of sustentaculum tali, (5) lateral part of plantar calcaneo-navicular lig. or spring lig., (6) plantar surface of navicular bone and the ligaments attached to that bone, (7) flexor hallucis brevis. [It grooves (1), (3) and (4).]

Synovial Sheaths.—The **sheath of flexor hallucis longus** begins an inch above the flexor retinaculum and reaches almost to the insertion.

The **sheath of flexor digitorum longus** begins at the same place and reaches the middle of the metatarsus. New sheaths—one for each of the lateral four digits—begin there. Each encloses a tendon of flexor brevis as well as a tendon of longus, and reaches the insertion of longus. But the sheath for the little toe may be a continuation of the lateral part of the main sheath.

On the digits, each sheath lines the tube formed by the phalanges and the fibrous flexor sheath.

Between the phalanges and the tendons at their insertion, the synovial sheaths are pinched up to form triangular folds called *vincula brevia*. Farther back, slender fibrous cords (with synovial coverings) pass between the phalanges and the tendons. These are called *vincula longa*. Blood-vessels run in the vincula to the tendons.

Third Layer of Muscles of Sole of Foot.—Flexor hallucis brevis, adductor hallucis, flexor digiti minimi brevis.

Flexor hallucis brevis lies along the plantar surface of the first metatarsal.

It **arises** by tendon from the medial part of the plantar surface of cuboid and from the slips of the tendon of tibialis posterior to the lateral and intermediate cuneiforms. It divides into two parts. The *medial part* is **inserted,** in company with abductor, into the medial side of the base of the proximal phalanx of the hallux; and the *lateral part* is **inserted,** together with adductor, into the lateral side of the same. Sesamoid bones are developed in the tendons of insertion; these bones replace the plantar ligament and articulate with the plantar surface of the head of the first metatarsal.

First digital branch of the *medial plantar nerve* supplies it by fibres from L. 5, S. 1. It flexes the big toe.

Adductor hallucis arises by two heads, and they are **inserted** together, by tendon, into the lateral side of the base of the proximal phalanx.

Oblique head **arises** by fleshy and tendinous fibres from the fibrous sheath of peroneus longus and the plantar surface of the bases of the second, third and fourth metatarsals. It adducts and flexes the big toe.

Transverse head **arises** by fleshy fibres from the lateral four plantar ligaments of the metatarso-phalangeal joints at their metatarsal

attachments, and from the plantar surface of the deep transverse ligs.; it draws all the toes together.

Deep branch of the *lateral plantar nerve* supplies both heads by fibres from s. 1, 2.

Flexor digiti minimi brevis lies along the plantar surface of the fifth metatarsal. It **arises** by fleshy and tendinous fibres from the fibrous sheath of peroneus longus and from the plantar surface of the base of the fifth metatarsal; and is **inserted** by tendon into the lateral side of the base of the proximal phalanx of the little toe, along with the abductor.

Superficial branch of *lateral plantar nerve* supplies it by fibres from s. 1, 2.

Medial Plantar Nerve.—The larger terminal branch of the posterior tibial. Arises under cover of the flexor retinaculum; proceeds forwards under cover of abductor hallucis, and then between it and flexor digitorum brevis, under cover of the deep fascia. It lies on the plantar surface of flexor accessorius, the tendons of the long flexors and flexor hallucis brevis.

Divides into four *digital branches* which supply the skin of the medial three and a half toes—plantar surface and sides, and also dorsal surface except the proximal phalanx.

First supplies the medial side of the foot and the big toe **second** supplies the sides of the first cleft; **third** and **fourth** run, superficial to flexor digitorum brevis tendons, to the second and third clefts.

Small branches are given to the skin of the medial part of the sole.

The medial plantar nerve supplies four muscles: *abductor hallucis* and *flexor digitorum brevis* from its trunk; *flexor hallucis brevis* from its first digital branch; *first lumbrical* from its second digital branch. It corresponds to the median nerve in the palm.

Medial Plantar Artery.—The smaller terminal branch of the posterior tibial. Begins under cover of flexor retinaculum or at its distal border; accompanies the medial plantar nerve. Ends by joining the *plantar digital artery* of the medial side of the hallux.

Gives off muscular and cutaneous branches, and may give branches to accompany some or all of the digital branches of the nerve. It is accompanied by venæ comitantes.

Lateral Plantar Artery.—Begins at the same point as the medial artery. Runs laterally and forwards to the interval between flexor digitorum brevis and abductor digiti minimi. At the base of the fifth metatarsal it turns medially across the sole as the *plantar arch*; and it ends at the base of the first metatarsal.

Branches.—Muscular; cutaneous; and *medial calcanean*, which pierce the flexor retinaculum or the abductor hallucis to reach the back and the sole of the heel.

Relations.—It is accompanied by venæ comitantes and by the lateral plantar nerve, which lies on its medial or concave side. *On its plantar surface*, there are abductor hallucis, flexor digitorum brevis and deep fascia. *On its deep surface*, there are flexor hallucis longus, flexor accessorius and long plantar ligament; and the peroneus longus tendon and flexor digiti minimi brevis, in the interval between flexor digitorum brevis and abductor digiti minimi.

Plantar Arch.—Is the continuation of the lateral plantar artery, and is completed medially by the dorsalis pedis at the *proximal*, i.e. *posterior*, end of the first intermetatarsal space. It is accompanied by venæ comitantes and the deep branch of the lateral plantar nerve. *Deep*, i.e. *dorsal, to it* are the bases of the second, third and fourth metatarsals and the proximal ends of the interosseous muscles. *On its plantar side* are the oblique head of adductor hallucis, flexor digitorum longus, and lumbricals; and, superficial to these, the flexor digitorum brevis.

Branches.—(1) **Articular** to tarsal joints.

(2) *Plantar digital artery* to the fibular side of the little toe.

(3) The **posterior perforating,** which pass upwards through the proximal parts of the lateral three intermetatarsal spaces to join the dorsal metatarsal arteries.

(4) Three **plantar metatarsal arteries** from the plantar arch run forwards on the plantar surfaces of interossei, and dorsal to the transverse head of adductor, to reach the clefts between the lateral four toes, and divide into *plantar digital arteries* for the sides of the clefts. Each metatarsal artery sends an *anterior perforating artery* upwards to join a dorsal metatarsal; and the medial two plantar metatarsal arteries may be joined by digital branches of the medial plantar artery.

On the digits the arteries lie dorsal to the nerves and supply the plantar surfaces and sides, form plexuses and arches in the pulp of the toes, anastomose with the dorsal digital arteries, and supply the dorsal surfaces of the middle and distal phalanges.

Dorsalis pedis artery dips down into the sole through the proximal end of the first intermetatarsal space and joins the plantar arch. At the point of junction, it gives off the **first plantar metatarsal artery,** which runs to the first cleft and divides into *plantar digital arteries* for both sides of the big toe and the medial side of the second toe.

Lateral Plantar Nerve.—The smaller terminal branch of the posterior tibial. Arises under cover of the flexor retinaculum; accompanies the lateral plantar artery, and has the same relations.

Its **trunk** supplies flexor accessorius and abductor digiti minimi and the skin of the sole; and at the base of the fifth metatarsal it divides into superficial and deep branches.

Superficial branch divides into two branches: The *medial* supplies the skin of the fourth cleft and communicates with the branch of the medial plantar to the third cleft. The *lateral* supplies flexor digiti minimi brevis, the third plantar and the fourth dorsal interosseous, the skin of the sole and the skin of the lateral side of the little toe.

The digital twigs therefore supply the skin of the little toe and half of the fourth—on the sole and the sides, and also on the dorsum except the first phalanx.

Deep branch accompanies the plantar arch on its concave or posterior side; ends in the oblique head of adductor hallucis; sends *branches* to the remaining interossei, to the transverse head of adductor, and to the second, third and fourth lumbricals—the branch to the second lumbrical passing above the transverse head and turning downwards and backwards to the lumbrical.

Fourth Layer of Muscles of Sole of Foot.—Interossei, and tendons of tibialis posterior and peroneus longus.

Interosseous Muscles.—7 in number—3 plantar and 4 dorsal.

Their tendons pass above the deep transverse ligs., and each is **inserted** into the base of a first phalanx, the capsule of a metatarso-phalangeal joint, and, very slightly, into the extensor tendon of the toe upon which it acts (compare with lumbricals p. 253).

Dorsal interossei lie between metatarsals, and are seen on the dorsum of the foot as well as in the sole.

Lateral plantar nerve supplies them all by fibres derived from s. 1, 2—the third plantar and fourth dorsal through its superficial branch, the rest through its deep branch.

Plantar interossei arise from the plantar surfaces of the third, fourth and fifth metatarsals, and are **inserted** on the tibial sides of the third, fourth and fifth toes. They flex the proximal phalanges, extend the middle and distal phalanges slightly (cf. lumbricals), and adduct these toes towards the second toe.

Dorsal interossei arise from adjacent sides of the metatarsals between which they lie. The *first* is **inserted** into the tibial side of the second toe; the *second*, *third* and *fourth* into the fibular sides of the second, third and fourth toes. They flex the proximal phalanges, and extend the middle and distal phalanges slightly. *Third* and *fourth* abduct the third and fourth toes from the second. *First* and *second* alternately abduct and adduct the second toe, *i.e.* the *first* abducts it towards the hallux; *second* adducts it to its former position, and, continuing to act, abducts it towards the third toe, and it is adducted to its former position by the *first*.

Each toe, therefore, has its abductor and adductor. Hallux has its special abductor and adductor; the second, third and fourth toes have two interossei each; and the fifth toe has its special abductor and has the third plantar interosseous as an adductor.

Tibialis posterior tendon, as it passes to its insertion, is *under cover of* the flexor retinaculum and cutaneous vessels; and flexor digitorum longus is superficial to it above the ankle-joint. *Deep to it* there are (1) the back of the medial malleolus, (2) the deltoid lig. immediately above the sustentaculum tali, and (3) the spring lig., which separates it from the head of the talus. A sesamoid fibro-cartilage or bone is developed in it as it crosses the spring lig.

It is **inserted** chiefly into the tubercle of navicular and the medial cuneiform; by small slips also into the plantar surfaces of the sustentaculum tali, the intermediate and lateral cuneiforms, the floor of the groove on the cuboid (*i.e.* all tarsals except talus), and into the bases of the second, third and fourth metatarsals. A synovial sheath surrounds it from its main insertion to a point an inch above the flexor retinaculum.

As the peroneal tendons lie on the back of the lateral malleolus, brevis is next the bone, and both are strapped down by a single *retinaculum* of deep fascia. When they leave malleolus and cross the calcaneo-fibular ligament to lie on the lateral surface of the calcaneum, the brevis is above longus; and the retinaculum, by means of a septum between them, binds them down separately.

Peroneus brevis runs on to its insertion into the base of the fifth metatarsal (p. 241).

Peroneus longus turns round the lateral side of the cuboid, passes medially and forwards—first in the groove on the plantar surface of the cuboid, and then below the lateral and intermediate cuneiforms, crossing below the slips from tibialis posterior.

It is **inserted** into the lateral side of the base of the first metatarsal and medial cuneiform, near the sole (cf. tibialis anterior).

A sesamoid bone, developed in the tendon as it enters the sole, plays on a facet on the cuboid.

As the tendon lies in the groove of the cuboid, the long plantar ligament, crossing it, holds it in place and forms its fibrous "sheath". Oblique head of adductor hallucis and the flexor digiti minimi brevis arise from that sheath.

Synovial sheath of the peronei, at first single, becomes double on the lateral surface of the calcaneum, and may follow both to their insertions, or that of longus may be interrupted at the cuboid and start afresh.

Joints of Lower Limb.—*See* p. 145.

HEAD, NECK AND BACK

SCALP AND TEMPLE

Landmarks to be Identified in the Living Head.—Glabella; supra-orbital margin and notch; zygomatic process of frontal bone; eyebrow; superciliary arch; frontal eminence. Parietal eminence. External occipital protuberance; superior nuchal line; highest nuchal line. Mastoid temporal bone and mastoid process; supramastoid crest; temporal line. Frontal process of zygomatic bone; zygomatic arch.

SCALP extends from the eyebrows to the nuchal lines, and from one temporal line to the other. On the top of the head, its layers are: (1) skin; (2) superficial fascia; (3) epicranial aponeurosis; (4) loose areolar tissue; (5) periosteum, called there the pericranium.

In the frontal and occipital regions the aponeurosis is replaced by the fleshy bellies of occipito-frontalis.

TEMPLE extends from the temporal line to the zygomatic arch. In this region, the skull is covered by: (1) skin; (2) superficial fascia; (3) extrinsic muscles of auricle and a thin fascia continuous with the margin of the epicranial aponeurosis; (4) temporal fascia; (5) temporal muscle and deep temporal vessels and nerves; (6) periosteum or pericranium.

Superficial Fascia.—*In scalp*: Contains a small quantity of fat and the vessels and nerves. In the middle part, it is very firm, fibrous and dense and is so closely adherent to the skin and to the epicranial aponeurosis that the three of them form one layer in a

round-flap. It is less fibrous and is looser at the back and the front of the head over the fleshy bellies of occipito-frontalis.

In temple: Contains fat and vessels and nerves, but is much less fibrous and is so much looser that the skin moves separately and easily. The deeper part is, however, a thin, strong membrane that extends down over the temporal fascia from the edge of the epicranial aponeurosis to the zygomatic arch and in which the extrinsic muscles of the auricle are imbedded.

Deep Fascia.—*In scalp*, it is very thin over the fleshy bellies, and it is fused with the aponeurosis. *In temple*, it is the strong, dense **temporal fascia** that covers the temporal muscle and is attached to the boundaries of the temporal fossa (p. 303).

Muscles.—Upper and lateral part of orbicularis oculi, which surrounds the opening of the orbit (p. 263); occipito-frontalis; extrinsic muscles of auricle; temporalis (p. 303).

Occipito-Frontalis.—A wide, thin tendinous sheet, called the *epicranial aponeurosis*, situated on the top of the skull, connects a pair of flat, fleshy bellies on the front of the head with another pair on the back.

Occipital bellies are small and separate. Each arises from the lateral two-thirds of the superior nuchal line.

Supplied by posterior auricular branch of facial nerve.

Frontal bellies are longer and wider and are united at the median plane; they are attached to the skin of the forehead, mingling with orbicularis oculi; and, alongside the median plane, they send down a pair of small slips, called **procerus** muscles, to the skin of the upper part of the nose.

Supplied by temporal branches of facial nerve.

The muscle raises the eyebrows and wrinkles the skin of the forehead; the two pairs of bellies, acting alternately, move the scalp backwards and forwards. Procerus wrinkles the skin of the nose.

Epicranial aponeurosis is continuous, anteriorly, with the frontal bellies; posteriorly, it is partly continuous with the occipital bellies, but, in the interval between them, it is loosely attached to the external occipital protuberance and the highest nuchal lines. Its lateral edge is adherent to pericranium at the temporal line, but it also sends a thin membrane down over the temporal fascia to the zygomatic arch.

Extrinsic Muscles of Auricle.—**Auricularis posterior** extends from the mastoid temporal bone to the back of the root of the auricle. Supplied by posterior auricular of facial.

Auricularis superior extends from the margin of the epicranial aponeurosis to the top of the root of the auricle. Supplied by temporal and posterior auricular branches of facial.

Auricularis anterior extends from the lateral extension of the

epicranial aponeurosis to the front of the root of the auricle. Supplied by temporal of facial.

AURICLE.—A thin, crumpled plate of yellow fibro-cartilage covered with thin skin. Placed on the side of the head nearer the back than the front and at the level of the eye and the nose.

Principal parts are : **concha**—the "well of the ear" ; the external auditory meatus begins at the bottom of it and passes medially into the skull. **Helix,** the rim, begins in the concha and ends at the **lobule,** which is soft because the cartilage does not extend into it, being replaced there by fatty fibrous tissue. **Tragus,** the lid that overlaps the anterior part of the concha.

At the bottom of the concha, the cartilage is continuous with the tube of fibro-cartilage which is the skeleton of the lateral third of the adult external meatus and is the skeleton of the whole meatus in an infant. The tube is incomplete above and in front, being replaced there by fibrous tissue ; and fibrous tissue binds it firmly to the end of the bony part of the adult meatus and to the bone around the tympanic membrane in an infant.

Nerve-Supply.—Skin of the upper two-thirds of lateral surface of the auricle is suppield by the *auriculo-temporal nerve* ; of upper third of medial surface by the *lesser occipital nerve. Great auricular nerve* supplies both surfaces of the lower part.

Nerves of Scalp and Temple.—10 on each side : 4 sensory and 1 motor, mainly in front of the auricle ; 4 sensory and 1 motor, mainly behind it.

In front of the auricle :—*Sensory* : supratrochlear, supra-orbital, zygomatico-temporal, auriculo-temporal.

Motor : temporal branches of facial.

Behind the auricle :—*Sensory* : great auricular, lesser occipital, greater occipital, third occipital.

Motor : posterior auricular branch of facial.

All the nerves communicate with their neighbours on the scalp.

Supratrochlear nerve, a terminal of the frontal branch of the ophthalmic (pp. 59, 70). Emerges from the orbit half an inch from the median plane ; gives a branch to the upper eyelid ; turns upwards, pierces the frontal belly of occipito-frontalis, and supplies the skin of the forehead alongside the median plane.

Supra-orbital nerve, the other terminal branch of the frontal. Emerges from the orbit through the supra-orbital notch, turns upwards, divides into *medial* and *lateral branches*, which pierce the frontal belly and the aponeurosis, respectively, and supply skin of forehead and scalp as far back as the vertex.

Zygomatico-temporal nerve, a terminal of the zygomatic branch of the maxillary nerve (p. 266). Pierces the temporal fascia behind the frontal process of the zygomatic bone, and supplies a small area of skin in the anterior part of the temple.

Auriculo-temporal nerve, a branch of the mandibular (pp. 307, 308). Ascends over the posterior root of the zygoma, immediately in front of the auricle, in company with the superficial temporal

rtery; gives branches to the auricle, meatus, and tympanic nembrane; and divides into branches which supply the skin of he side of the head almost as far as the vertex.

Temporal branches of facial nerve emerge from the upper part of he parotid gland, run upwards and forwards over the zygomatic rch, and supply auricularis anterior and superior, the frontal belly f occipito-frontalis, and the upper part of orbicularis oculi.

Great auricular nerve, from anterior primary rami of 2nd and rd cervical nerves, ascends on sterno-mastoid, pierces the deep ascia, gives branches to the skin of the neck, to the face and the ower part of auricle, and **mastoid branches** to the skin in the mastoid egion.

Lesser occipital nerve, from the anterior primary ramus of c. 2, scends first along the posterior border of sterno-mastoid, and then n its surface; pierces the deep fascia, and gives branches to the kin of the neck, to the upper part of the cranial surface of the uricle, and to the skin of the back of the head behind the auricle.

Greater occipital nerve is the medial division of the posterior rimary ramus of c. 2. It enters the scalp by piercing trapezius nd the deep fascia at the superior nuchal line, about an inch from he external occipital protuberance; supplies a large area of skin n the back of the head as far up as the crown.

Third occipital nerve arises from the medial division of the posterior rimary ramus of c. 3. It pierces trapezius and the deep fascia to upply the skin of the uppermost part of the back of the neck and he skin over the protuberance.

Posterior auricular nerve, a branch of the facial, turns upwards etween the mastoid process and external auditory meatus, and is istributed to auricularis posterior and the occipital belly of ccipito-frontalis.

Arteries of Scalp and Temple.—Five on each side, and they nastomose freely with each other and with those of the opposite de.

They are—the supratrochlear, supra-orbital, and superficial emporal, in front of the auricle; the posterior auricular and ccipital, behind the auricle.

Supratrochlear and **supra-orbital arteries** arise in the orbit from he ophthalmic branch of the internal carotid, and accompany the upratrochlear and supra-orbital nerves.

Superficial temporal artery arises, as a terminal branch of the xternal carotid, behind the neck of the mandible. After giving ff *parotid, anterior auricular, transverse facial,* and *middle temporal* ranches it ascends over the posterior root of the zygoma, immediately in front of the auricle, in company with the auriculo-temporal erve. Gives off a small *zygomatic branch,* and then, at a variable oint above the zygoma (about an inch), it ends by dividing into *nterior* and *posterior branches.* These branches run towards the ontal and parietal eminences, supplying the constituents of the mple and scalp; the anterior branch is very sinuous, and can e seen pulsating.

The *zygomatic artery* runs forwards between two layers of temporal fascia along the upper border of the zygomatic arch.

The *middle temporal artery* arises just below the zygoma. It ascends over the posterior root close to the bone, and at once sinks through the temporal fascia and muscle to ascend in a vertical groove on the squamous temporal bone directly above the external meatus. (*See also* p. 303.)

Posterior auricular artery, a branch of the external carotid, escapes from under cover of the parotid gland and ascends behind the root of the auricle, with the posterior auricular nerve, and gives branches to sterno-mastoid, auricle, and scalp near the auricle.

Occipital artery, also a branch of the external carotid, enters the scalp by piercing trapezius and the deep fascia at their attachment to the superior nuchal line, close to the lateral side of the greater occipital nerve. Breaks up into branches which supply the greater part of the back of the scalp; one of these sends a *meningeal* branch through the parietal foramen to the dura mater.

Veins of Scalp and Temple.—Form a plexus drained by trunks which correspond to the arteries :—

Supratrochlear and **supra-orbital veins** drain the forehead, communicate with ophthalmic veins, and unite to form the commencement of the anterior facial vein.

Superficial temporal vein drains the greater part of the side of the head; joins the *middle temporal vein* above the zygoma to form the *posterior facial*, which descends in front of the auricle and the superficial temporal artery into the parotid gland.

Posterior auricular vein drains the posterior parts of the temporal and parietal regions; descends behind the auricle, and passes on to the sterno-mastoid; below the parotid gland, it joins the posterior division of the posterior facial vein to form the external jugular.

Occipital veins drain the occipital and posterior parietal regions; pierce trapezius, but, instead of accompanying the occipital artery farther, they end in the plexus in the suboccipital space, and that plexus is drained by the vertebral and deep cervical veins.

The *emissary vein* which passes through the parietal foramen connects the superior sagittal sinus with the veins of the posterior parietal region; and the *emissary vein* which passes through the mastoid foramen connects the sigmoid sinus with an occipital vein.

Lymph-Vessels of Scalp and Temple.—Those from the back of the head end in **occipital glands,** which lie on the occipital attachment of trapezius. Those from the posterior part of the side of the head, *i.e.* behind the level of the auricle, end in **mastoid glands,** which lie on the mastoid insertion of sterno-mastoid. Those from the temple and anterior part of the scalp end in **parotid glands** on the surface of the parotid salivary gland.

Efferents from all these glands end in the **superficial cervical glands** that lie along the external jugular vein, and in those **deep cervical glands** that lie along the carotid sheath down to the level of the thyroid cartilage.

FACE

Face extends from ear to ear and from the point of the chin to the roots of the hair; face and scalp therefore overlap.

Landmarks to be Identified in the Living Body.—Frontal eminence; glabella; eyebrow; superciliary arch; supra-orbital margin and notch; zygomatic process of frontal bone. Zygomatic bone and its frontal process. Infra-orbital foramen; frontal process of maxilla. Nasal bone; ala and vestibule of nose. Philtrum of upper lip; vestibule of mouth; frenulum of lip. Body of mandible and its oblique line; mental foramen; angle of mandible; ramus of mandible; masseter; head and neck of mandible. Tubercle of root of zygoma.

Skin.—Fairly thick. Very vascular; and wounds therefore bleed freely but heal quickly. Easily stretched—making plastic operations possible. Very elastic because the facial muscles are inserted into it; wounds therefore tend to gape.

Superficial Fascia.—Contains the *nerves* and *vessels*; and the *muscles* pass through it to be inserted into the skin. Contains also a variable quantity of *fat*—usually more abundant in women than in men. Fat is absent from the eyelids; but in the posterior part of the cheek there is a great accumulation called the *buccal pad* of fat.

Buccal Pad.—A mass of fat encapsuled in fibrous tissue that lies on the buccinator muscle partly in the soft part of the cheek and partly tucked in under masseter and ramus of mandible—between them and buccinator. It helps the cheek to resist atmospheric pressure during sucking, and is therefore very big relatively in an infant. The chubbiness of a child's cheek is chiefly due to the pad. It is pierced by parotid duct, buccal nerves and small vessels.

Deep Fascia.—A negligible film over most of the muscles. But, posteriorly:—1. The **parotid fascia**—thick and strong—ensheaths parotid gland and covers masseter, and is connected with the zygomatic arch above and fascia of the neck below.

2. The **bucco-pharyngeal fascia**—a thin sheet which covers the constrictor muscles of the pharynx—extends forwards from the pharynx to clothe the buccinator.

Muscles.—Are arranged in groups around the eye, nose and mouth. The term "facial muscles" or "muscles of expression" includes also occipito-frontalis and the muscles of the auricle; and they are all supplied by the facial nerve.

Muscle around the Eye.—**Orbicularis oculi** lies in and around the eyelids, in the form of loops, *attached* medially to the medial palpebral lig. and adjoining bone, but with no bony attachment laterally.

The *lacrimal part* consists of a thin sheet that springs from the fascial sheath of the lacrimal sac (p. 271) and the bone behind the sac; it curves forwards round the superficial surface of the sac, and divides to pass into the eyelids.

Orbicularis closes the eyelids; it also draws them medially, pushing the lacrimal secretion towards the puncta (p. 269). The part in the eyelids and the part beyond them can each act independently —*e.g.*, to close the eyelids; to protect the eyes without closing the eyelids. The lacrimal part widens the lacrimal sac and the openings of lacrimal canaliculi into it. The whole muscle contracts firmly before a sudden bright light, an expected blow, and during strong expiratory efforts.

Some fibres conveyed to orbicularis by the facial nerve are said to arise in the nucleus of the oculomotor nerve, in order that eyelids and eyeball may move in harmony.

Corrugator supercilii is a part of orbicularis that **arises** from medial end of superciliary arch and is **inserted** into skin of eyebrows. It produces a vertical furrow in skin of middle of forehead.

Muscles of Nose.—**Procerus** (p. 259). **Compressor naris arises** from maxilla above subnasal fossa and ends in an aponeurosis which joins its fellow on dorsum of nose. **Dilatores naris**: two small slips placed on lateral margin of nostril. **Depressor alæ nasi** extends from subnasal fossa to ala and septum of nose.

Levator labii superioris alæque nasi (*see below*).

Muscles around Mouth.—**Orbicularis oris** occupies the lips. Its own proper fibres radiate from different points—septum of nose, subnasal fossæ, mandible at the sides of the symphysis. But it is very largely made up of the muscles that converge on the mouth.

It closes and purses lips. Various movements of the lips can be produced by contraction of different portions of the muscle.

Some fibres conveyed to it by the facial nerve are said to arise in the nucleus of the hypoglossal nerve in order that lips and tongue may move in harmony.

Levator labii superioris alæque nasi passes from the lower part of frontal process of maxilla into ala of nose as well as into lip.

Levator labii superioris: from maxilla above infra-orbital foramen; into the upper lip.

Zygomaticus minor is an occasional slip that drops from orbicularis oculi into the upper lip.

Levator anguli oris: from maxilla below infra-orbital foramen; into skin of angle of mouth.

Zygomaticus major: from zygomatic bone; into skin of angle.

Risorius may be inseparable from platysma; arises from fascia over masseter and passes to the skin of the angle of the mouth.

Depressor anguli oris: from oblique line of mandible; into skin of angle.

Depressor abii inferioris: from front of body of mandible ; into lower lip.

Mentalis downwards from incisor fossa of mandible into skin of chin.

Platysma arises from the skin and fasciæ which cover upper parts of deltoid and pectoralis major ; ascends over clavicle ; lies in superficial fascia on lower part of posterior triangle of the neck and upper part of anterior triangle ; is **inserted** into body of mandible, skin of lower part of face and lips, mingling with oral muscles. The most anterior fibres decussate with their fellows below the chin.

Buccinator arises from pterygo-mandibular lig. and from lateral surfaces of maxilla and mandible opposite sockets of molar teeth. It mingles with other muscles at angle of mouth. Middle fibres decussate—upper ones descending to lower lip, lower ones ascending to upper lip.

It flattens cheek against gums and teeth, and prevents food from accumulating in vestibule of mouth during mastication.

Deep surface is lined with mucous membrane of cheek. *Superficial surface* is clothed with bucco-pharyngeal fascia ; covered posteriorly by buccal pad of fat, which separates it from masseter, ramus of mandible and temporalis, and covered anteriorly by superficial fascia containing facial artery, anterior facial vein, buccal nerve and vessels, buccal branches of facial nerve, zygomaticus major, and risorius.

Pierced by parotid duct and twigs from buccal nerve to the mucous membrane.

Nerves of Face.—Three sources :—

1. Terminal branches of **facial**, to muscles.
2. Facial branch of **great auricular,** to skin over lower part of parotid and masseter.
3. Branches of the three divisions of **trigeminal,** to the rest of the skin, to the mucous membrane of cheeks, lips and external nose, and to conjunctiva.

The nerves communicate freely and make an intricate interlacement of motor and sensory nerves in the face.

Terminal Branches of Facial Nerve.—Arise in parotid gland and radiate from its ends and anterior border.

1. **Temporal** branches.—*See* p. 261.
2. **Zygomatic** branches appear at the anterior border of parotid gland above its duct and supply muscles of nose and muscles between eye and mouth.
3. **Buccal** branches emerge below parotid duct and supply buccinator and muscles at the side of the mouth.
4. **Mandibular** branch emerges a little above the lower border of mandible and supplies muscles of chin and lower lip.
5. **Cervical** branch emerges through the lower end of parotid

gland and curves forwards below mandible between platysma and the deep fascia. Supplies platysma and sends a spray of fine branches upwards to help to supply the muscles of the lower lip. These branches are cut in a submandibular operation, with consequent partial paralysis of lower lip.

Branches of Trigeminal Nerve in the Face.—The three divisions of trigeminal are the *ophthalmic*, *maxillary* and *mandibular*. They arise in the cranial cavity from the **trigeminal ganglion.**

Ophthalmic nerve divides into three branches—**frontal, lacrimal** and **naso-ciliary**—which pass out of cranial cavity into orbit through the superior orbital fissure.

Their branches which reach the skin are the external nasal, infratrochlear, supratrochlear (p. 260), supra-orbital (p. 260) and the palpebral branch of the lacrimal nerve.

External nasal nerve supplies skin of the lower half of nose. It comes from the anterior ethmoidal branch of naso-ciliary. The anterior ethmoidal passes from the orbit into the anterior cranial fossa and thence down into the nose. The external nasal is its terminal branch, and it emerges between the nasal bone and the upper cartilage of the nose.

Infratrochlear nerve, a branch of naso-ciliary, leaves the orbit *above* the medial angle of eye, gives branches to both eyelids and supplies skin of the upper half of nose.

Palpebral branch of lacrimal descends into the lateral part of upper eyelid.

Maxillary nerve leaves the cranial cavity through foramen rotundum, passes through pterygo-palatine fossa and pterygo-maxillary fissure, and ends at the inferior orbital fissure by changing its name to infra-orbital; its last branch before doing so is the zygomatic; and the nerves through which the maxillary nerve supplies skin are the terminal branches of infra-orbital and zygomatic.

Infra-orbital nerve runs forwards through the infra-orbital groove and canal in the floor of the orbit, appears in the face through the infra-orbital foramen under cover of orbicularis oculi and levator labii superioris, and divides there into three sets of terminal branches—*palpebral* to lower eyelid, *nasal* to skin of the side of the nose, and *labial* to skin between eye and mouth and to mucous membrane of upper lip. These branches communicate with one another and with branches of the facial nerve, forming a network called the **infra-orbital plexus.**

Zygomatic nerve passes through inferior orbital fissure into orbit, enters zygomatic bone and divides in it into *zygomatico-temporal* (p. 260) and *zygomatico-facial*, which emerges through the front of zygomatic bone a little below the lateral margin of orbit and supplies skin over the bony part of the cheek.

Mandibular nerve descends from cranial cavity through foramen ovale into the infratemporal fossa and soon ends by dividing into branches. The cutaneous nerves derived from it are the auriculo-temporal (p. 260), buccal and mental.

Buccal nerve appears in the face from under cover of masseter and runs downwards and forwards over buccinator near the mandible. Its branches supply skin of the soft part of the cheek; and some pierce buccinator to supply mucous membrane (p. 308).

The inferior dental branch of mandibular enters the mandible to supply teeth but gives off also the **mental nerve,** which emerges from the mandible through the mental foramen and supplies skin and mucous membrane of the lower part of the face from the front of masseter to the median plane.

Arteries of Face.—Very numerous. Anastomose freely.

1. Facial artery and its branches.
2. Transverse facial artery.
3. Arteries that accompany the cutaneous branches of trigeminal nerve and receive the same names—supratrochlear, mental, etc. Some of these come from the ophthalmic branch of internal carotid; others from branches of external carotid.

Transverse Facial Artery.—A small vessel. Arises from superficial temporal near its origin and runs forwards to the cheek over masseter near the zygomatic arch.

Facial Artery.—The chief artery. A branch of external carotid. Enters the face by piercing the deep fascia of the neck at the lower border of mandible close to the antero-inferior angle of masseter. Runs sinuously upwards and forwards in front of the anterior facial vein, passing within half an inch of the angle of the mouth. Ends in small branches to muscles and skin near the medial angle of the eye.

Lies on mandible, buccinator and levator anguli oris, and *in* the substance of levator labii superioris alæque nasi. *Covered by* platysma, risorius, zygomaticus major and levator labii superioris.

Small *branches* pass backwards from it, and larger ones forwards to the chin, lips and nose.

Veins of Face.—Form a network among the fat and the muscles. The network is drained by veins that accompany the arteries and end in the pterygoid plexus and in the ophthalmic, maxillary, posterior facial and common facial veins.

Anterior Facial Vein.—The companion of the facial artery and the biggest of the veins. Begins at the medial angle of the eye by the union of supratrochlear and supra-orbital. Runs downwards and backwards, receiving tributaries that correspond to the branches of the artery. At first a little behind the artery and separated from it by the levators of the upper lip and zygomaticus minor, and then close behind the artery. Crosses the lower anterior angle of masseter and pierces the deep fascia at the lower border of mandible. In the

neck, it crosses the submandibular gland and joins the anterior division of posterior facial below the angle of mandible to form the common facial vein, which ends in the internal jugular.

As it crosses buccinator it communicates with the pterygoid plexus by the **deep facial vein,** which passes backwards under cover of masseter and ramus of mandible.

Lymph-Vessels.—Those from the upper part of face—above the level of root of nose—end in glands imbedded in the lateral surface of parotid gland. Those from the median part of lower lip and chin run down to submental glands. Those from the rest of the face go to submandibular lymph-glands.

Mucous Glands.—**Labial** and **buccal glands,** small and numerous, lie in the submucous coat of lips and cheeks. Their ducts pierce the mucous membrane to open into the vestibule of mouth.

Molar glands, four or five, lie on the bucco-pharyngeal fascia around the parotid duct. Their ducts pierce the fascia, buccinator and mucous membrane to open into the vestibule of the mouth.

External Nose

Lined internally with **mucous membrane,** except above the *nostrils*, where the *vestibule* is lined with **skin.**

Skeleton.—*Upper part*, bony and rigid—**nasal bone** and **frontal process of maxilla.** *Lower part*, yielding—cartilages and fibrous tissue. **Upper nasal cartilage,** triangular. Upper border is attached to the bones ; lower border to the lower cartilage ; anterior border is partly fused with the anterior edge of the cartilage of the septum, but the lower part is separated by a narrow cleft from the septal cartilage. **Lower nasal cartilage** is an oval plate in front of the ala, and its medial part is bent into the septum at the point of the nose. **Small cartilages of ala** are little islets in the fibro-fatty tissue of the ala.

Muscles.—*See* p. 264.

Superficial Fascia.—Very little fat. Loose over the bones so that the skin can move easily, but in the lower part it binds the skin to the cartilages and the aponeurosis on the dorsum (p. 264).

Eyelids and Visible Part of Eye

The *white* of the eye is the **sclera ;** it is made of dense white fibrous tissue, and is the posterior five-sixths of the outer case of the eyeball, but only the front part is visible. The *coloured part* of the eye is the **iris,** made of muscles, vessels and pigmented cells, seen through a circular window of dense transparent fibrous tissue called the **cornea,** which is the rest of the outer case. The round hole in the centre of the iris is the **pupil**—so named from the reflection of oneself in miniature seen in it (*pupilla* = an orphan child). The pupil is black because the interior of the eye is dark unless lit up by reflected light.

The visible part of the sclera is covered with a thin, moist, transparent membrane called the **conjunctiva.** At the roots of the eyelids, the conjunctiva is reflected off the sclera on to the lids and lines them. The angle of reflexion is called the **fornix conjunctivæ** (*fornix* = an arch).

At the medial corner of the eye, the space between the eyelids is called the **lacus lacrimalis.** On the floor of that lake there is a little, reddish, uneven body called the **lacrimal caruncle,** made of modified skin and skin-glands; and, lateral to the caruncle, the conjunctiva on the sclera is pinched up to form a small, vertical fold called the **plica semilunaris.**

One can see all these parts, except the fornices, by looking in a mirror. The lower fornix can be seen if the lower lid is turned inside out; but the upper lid is bigger, and the fornix is therefore deeper and cannot be seen even when the lid is everted.

Eyelids or Palpebræ.—Movable curtains attached to the margins of the orbital opening for the protection of the eye. Upper lid is the bigger and more movable.

Free edge of each lid is flat, and the cilia or **eyelashes** grow from the anterior margin of that edge—except in the boundary of the lacus, where the edge is rounded and eyelashes are absent.

At the point where eyelashes cease, there is a little eminence called the **lacrimal papilla**; and on it a black speck called **punctum lacrimale.** The punctum is the beginning of a very slender tube—**lacrimal canaliculus**—which runs medially in the edge of the lid and carries lacrimal secretion to the lacrimal sac. The punctum is in contact with the eyeball in order to take in the secretion: evert the lid slightly to see it.

Palpebral fissure is a little below the pupil when the lids are shut. When open, the lids overlap the cornea slightly both above and below.

The layers of each eyelid are:—

1. Skin. Very thin and without visible hairs except the eyelashes.
2. Superficial fascia. Has no fat but contains the palpebral part of orbicularis oculi.
3. Palpebral fascia and a plate of dense fibrous tissue called the *tarsus* that stiffens the lid; and, in the upper lid, an expanded tendon—the tendon of levator palpebræ superioris.
4. Conjunctiva.

Other structures associated with the lids are two palpebral ligaments and the tarsal and ciliary glands.

The **tarsus** is near the free edge of the lid. The upper is the bigger and can be pinched up between finger and thumb.

Inferior palpebral fascia is a narrow sheet that attaches the lower tarsus to the inferior margin of orbit.

Superior palpebral fascia, much wider. Extends downwards from the upper margin of orbit in front of the tendon of levator palpebræ superioris; fuses with the anterior lamella of the tendon. With

that lamella, it is attached to the front of the upper tarsus. It is pierced by the nerves and vessels that come out of the orbit to supply the forehead and the upper lid.

Superior and inferior fascia, together, are called the **orbital septum.** At the medial angle of the eye, they are continuous with each other behind the lacrimal sac. At the lateral angle, they are continuous with each other in front of the lateral palpebral lig.

Tendon of levator palpebræ superioris divides into three lamellæ. The *anterior* one is inserted, with the palpebral fascia, into the front of the tarsus and also sends fibres through orbicularis to the skin; the *middle* one into the upper edge of the tarsus; and the *posterior* one into the superior fornix conjunctivæ.

Lateral palpebral lig. is a short band that connects the lateral ends of the tarsi with a little tubercle on the zygomatic bone just within the orbital margin.

Medial palpebral lig., longer and thicker, stretches from the frontal process of maxilla across the front of the lacrimal sac to the medial ends of the tarsi. May be felt through the skin at the medial angle of the eye, and may raise a ridge of skin if one draws the eyelids gently sidewards to put it on the stretch. Gives origin to part of the orbicularis oculi.

Tarsal glands are slender sebaceous glands imbedded in the backs of the tarsi, and open on the edge of the lid behind the eyelashes. Evert the lid: they can then be seen through the conjunctiva as yellow streaks.

Ciliary glands are minute, modified sweat-glands placed behind the roots of the eyelashes; they open close to the eyelashes. Inflammation of one of them gives rise to a "stye".

Nerves and Vessels of Eyelids.—Nerves.—*Motor* to orbicularis from the temporal and zygomatic branches of facial; to levator from oculomotor. *Sensory* from infra-orbital, infratrochlear, supratrochlear, supra-orbital and palpebral branch of lacrimal.

Arteries.—From infra-orbital and from ophthalmic and its lacrimal branch.

Veins.—End in the infra-orbital, anterior facial and supratrochlear.

Lymph-vessels.—End in parotid and submandibular lymph-glands.

Lacrimal Apparatus

1. Lacrimal gland and its ducts.
2. Conjunctiva, which is a closed sac when eyelids are shut.
3. Lacrimal puncta and lacrimal canaliculi (p. 269).
4. Lacrimal sac and naso-lacrimal duct with its lacrimal fold.

Lacrimal Gland.—About the size of a bean. Closely applied to the roof of orbit above and lateral to the anterior part of eyeball (*see* p. 71). Its **ducts,** about a dozen, pierce the conjunctiva of upper lid near superior fornix. The lacrimal secretion flows down and is pushed medially by the movements of the eyelids; and it moistens the front of the eye and the deep surface of the lids. Most

of it evaporates; the remainder is drained off by the canaliculi. When excessive, the excess overflows as *tears*.

Some **accessory lacrimal glands** lie near the fornices, and become active enough to keep the lids and eye moist when the lacrimal gland is extirpated.

Lacrimal Sac.—Like a test-tube turned upside down, but in size it is like the top half-inch of a "programme" pencil. It lies behind the medial palpebral lig. in the lacrimal fossa on the medial wall of orbit just within the orbital margin, and is separated only by thin bone from the posterior part of the atrium of the middle meatus of the nose. At the antero-medial corner of the floor of the orbit, it is continuous with the naso-lacrimal duct.

Naso-Lacrimal Duct.—Half an inch long and as wide as the sac. Descends through the naso-lacrimal canal to open into the anterior part of the inferior meatus of the nose about an inch and a half behind the posterior margin of the nostril. The **lacrimal fold** of mucous membrane is pinched up at the medial margin of the opening and acts as a flap-valve to prevent secretions of the nose from being driven up into the duct.

POSTERIOR TRIANGLE OF NECK

Landmarks.—The thirds of the clavicle. Sterno-mastoid; mastoid temporal bone and its mastoid process; superior nuchal line.

Boundaries of Triangle.—Sterno-mastoid; upper part of trapezius; intermediate third of clavicle (the base). The apex is at the superior nuchal line.

Roof.—Superficial fascia and its contents; deep fascia, containing the accessory nerve in a tunnel.

Floor.—Muscles covered with deep fascia. From above downwards—semispinalis capitis, splenius capitis, levator scapulæ, scalenus medius, and, sometimes, serratus anterior.

Only a small part of the upper end of **semispinalis** appears in the floor at the apex; and splenius is sometimes wide enough to exclude it.

A considerable part of **splenius capitis** is seen as it sweeps upwards and forwards from the lower cervical spines to the mastoid temporal and superior nuchal line; and a considerable part of **levator scapulæ** is seen slanting downwards and backwards from the upper four cervical transverse processes to the medial border of scapula.

A great part of **scalenus medius** also is seen as its fibres converge upon the upper surface of the posterior part of the first rib from all cervical transverse processes.

As the posterior part of the first rib is above the level of the clavicle, the first digitation of **serratus anterior** may appear in the posterior corner of the triangle—especially on the right side, because the muscle is usually bigger on that side.

Another muscle—**scalenus anterior**—not usually in the triangle, for sterno-mastoid covers it—may be seen if sterno-mastoid is

narrow. It springs from the 3rd, 4th, 5th and 6th cervical transverse processes and, descending in front of the roots of the brachial plexus and second part of subclavian artery, tapers to be inserted into the upper surface of the first rib between the subclavian artery and vein. The phrenic nerve runs downwards over its anterior surface (between the muscle and its fascia), gradually crossing it from lateral to medial border.

Superficial Fascia of Posterior Triangle.—Contains: 1. Only a moderate quantity of fat even in stout people, for fat gathers chiefly under the deep fascia in this region.

2. A portion of **platysma** at the lower part of the triangle.

3. **Supraclavicular nerves** under cover of platysma.

4. Small **unnamed arteries** which come through the deep fascia from the deep arteries—occipital, transverse cervical and suprascapular.

5. **Veins**—some of which accompany these unnamed arteries and some end directly in the external jugular.

6. **Lymph-vessels,** which pierce the deep fascia and end in glands above the clavicle.

Deep Fascia.—More than one layer. A layer clothes the muscles of the floor; and the part of it that covers scalenus medius contributes to the posterior wall of the axillary sheath. A very definite sheet covers the front of scalenus anterior, and its superficial part sends a thin, ill-defined sheet over the front of the brachial plexus and third part of subclavian artery.

The *deep fascia of the roof* is well-defined below, but ill-defined above, where, in thin bodies, it may be fused with the deep fascia of the floor In front and behind, it splits to become continuous with the fasciæ that cover both surfaces of sterno-mastoid and trapezius; and it is tunnelled by the accessory nerve.

For about an inch above the clavicle it is split into two layers. The first layer is attached to the upper surface of the clavicle. The second layer slips down behind the clavicle to fuse with the fascia on the back of subclavius; as it extends upwards to join the first layer it adheres to the fascia around the inferior belly of omo-hyoid and holds that belly down when the superior belly contracts and tends to pull it up.

The space that separates the second layer from the first layer and from the clavicle contains a portion of the external jugular vein, the terminal part of transverse cervical veins and the suprascapular artery and veins.

The fascia of the roof is pierced by the supraclavicular nerves, external jugular vein, lymph-vessels and unnamed blood-vessels.

Contents and their Position.—**Occipital artery** crosses the apex. **Cutaneous branches of cervical plexus** appear at and above the middle of the posterior border of sterno-mastoid, and they disperse—some upwards and some forwards out of the triangle, and some downwards in the triangle.

Branches to **levator scapulæ** and **trapezius** (from 3rd and 4th

cervical) appear about the middle of sterno-mastoid. Those to levator soon end in it; those to trapezius run downwards and backwards across the middle of the triangle.

Brachial plexus and the four *named branches of its roots* are in the lower part of the triangle.

Transverse cervical vessels cross the upper part of the plexus.

Third part of **subclavian artery,** passing steeply downwards and sidewards, is in front of the lower trunk of the plexus and then behind the clavicle.

Subclavian vein, behind clavicle, in front of the artery and rather lower.

Suprascapular vessels, behind clavicle, in front of subclavian artery.

External jugular vein descends in front of the plexus and the arteries.

Inferior belly of omo-hyoid, also superficial to the plexus, runs obliquely upwards and forwards in the lower part of the triangle.

Fatty areolar tissue, throughout; and **lymph-glands,** chiefly near the blood-vessels in the lower part of the triangle.

Accessory nerve, after it is disentangled from the deep fascia of the roof, slants downwards and backwards across the middle of the triangle.

Relations in Posterior Triangle of Neck

Some of the structures are followed beyond the triangle.

Inferior belly of omo-hyoid arises from the suprascapular lig. and upper border of scapula. Runs upwards and forwards in the fat below trapezius and above subscapularis and serratus anterior and appears in the posterior angle of posterior triangle. Passes forwards and upwards a little above the clavicle, under the deep fascia, across transverse cervical vessels, brachial plexus and nerve to subclavius, and disappears under sterno-mastoid. There, it crosses scalenus anterior and ends in a tendon common to it and the superior belly. The **tendon** lies under sterno-mastoid on internal jugular at the level of cricoid cartilage; and the superior belly runs upwards from it to the hyoid bone.

The **nerve** of inferior belly comes from ansa hypoglossi and runs along the back of the tendon into the deep surface of the belly.

Subclavian Artery.—Its **third part** begins at the lateral margin of scalenus anterior opposite the posterior border of sterno-mastoid, a finger's breadth above the clavicle; passes downwards and sidewards and ends at the outer margin of the first rib by becoming the axillary artery opposite the lower border of the middle of the clavicle.

Usually no branch arises from the third part, but occasionally it gives off a *descending scapular artery* which takes the place of the deep branch of the transverse cervical.

Anterior to it, as it lies in the triangle, there are: 1. Skin.

2. Superficial fascia containing platysma and supraclavicular nerves.

3. First layer of deep fascia.
4. Ext. jugular vein and the terminal parts of the transverse cervical and suprascapular veins (forming a plexus).
5. Second layer of deep fascia.
6. The nerve to subclavius.
7. A third layer of deep fascia, continuous with that which covers scalenus anterior and the prevertebral muscles.

The terminal part of the artery lies below the triangle; and the clavicle, subclavius and suprascapular artery are in front of it. Subclavian vein is anterior, but at a lower level.

Posterior to it there is scalenus medius, separated by the first thoracic nerve or by the lower trunk of the brachial plexus.

Below it are the first rib, and, at the medial part of the artery, the pleura; and both rib and pleura are also behind the artery.

Transverse Cervical Artery.—Arises from the thyro-cervical trunk near the medial margin of scalenus anterior. Passes sidewards and upwards—across scalenus anterior and phrenic nerve, upper trunks of brachial plexus, nerve to subclavius, suprascapular nerve and scalenus medius—to the anterior border of levator scapulæ. There, under cover of the anterior border of trapezius, it divides into superficial and deep branches. As the artery enters the posterior triangle, it is crossed by the inferior belly of omo-hyoid.

Superficial branch ramifies on the deep surface of trapezius.

Deep branch descends, under cover of levator scapulæ and the rhomboids, along the medial margin of the scapula, lateral to and close to the nerve to the rhomboids. Its place may be taken by the descending scapular branch from the third part of subclavian.

Suprascapular Artery.—Arises from the thyro-cervical trunk. Passes sidewards, downwards and backwards, along the root of the neck—first deep to sterno-mastoid, next behind the clavicle, and then descends under trapezius to the scapula.

Relations in the Neck.—While deep to the sterno-mastoid, it crosses scalenus anterior and the phrenic nerve; and, as it passes from under cover of sterno-mastoid, it is crossed by ext. jugular vein. While behind the clavicle, it runs superficial to the nerve to subclavius, third part of subclavian artery, brachial plexus and scalenus medius. At the lower posterior angle of the posterior triangle, it joins the suprascapular nerve and omo-hyoid and enters the upper limb (p. 177).

Transverse cervical and *suprascapular veins* end in the external jugular; one or two suprascapular veins accompany the artery closely, and another lies a little higher.

Subclavian Vein.—Short and wide. Begins as the continuation of axillary at the outer border of first rib. Ends behind clavicle about an inch from sterno-clavicular joint by joining internal jugular to form the innominate. Right vein ends at the medial margin of scalenus anterior and corresponds therefore to the third and second parts of the artery. Left vein reaches a little farther and ends on the pleura below the first part of the artery.

The vein lies on the first rib in front of the artery, separated from the second part by scalenus anterior; and it is at a lower level than

the artery owing to the slope of the rib. Anterior relations are subclavius muscle and its nerve and the clavicle.

One *tributary*—external jugular. One *valve*—placed on the distal side of the entrance of external jugular.

External Jugular Vein.—Begins at a variable point on the sterno-mastoid below or behind the lower end of parotid gland, by the union of the posterior auricular with the posterior division of the posterior facial, which emerges from parotid gland.

It descends almost vertically on the deep fascia which covers sterno-mastoid, crossing the muscle obliquely, under cover of platysma, and either superficial or deep to the anterior cutaneous nerve of the neck. At the posterior border of sterno-mastoid, an inch above the clavicle, it pierces the first layer of deep fascia, crosses the third part of the subclavian artery and the suprascapular artery, pierces the second layer of fascia, and ends behind the clavicle in the subclavian vein.

It has a valve at its termination, and another at a higher level.

It communicates with the int. jugular by a branch which turns round the anterior border of sterno-mastoid into carotid triangle.

Between the two layers of fascia, the anterior jugular and transverse cervical and suprascapular veins join it, and form with it a plexus in front of the subclavian artery.

The first layer of deep fascia adheres to the walls of the vein as the vein passes through it.

Cervical plexus, formed by the anterior primary rami of the upper four cervical nerves, lies on the scalenus medius under cover of the internal jugular vein and the upper half of sterno-mastoid. Its four cutaneous branches have therefore to escape from the sterno-mastoid, and they do so a little above the middle of its posterior border. They are :—*lesser occipital* ; *great auricular* ; *anterior cutaneous nerve of neck* ; *supraclavicular*.

Lesser Occipital Nerve.—Arises from the second cervical. Runs upwards along the posterior border of sterno-mastoid, turns on to its superficial surface ; pierces the deep fascia, and is distributed to the skin of the neck, the skin over the occipital bone and mastoid temporal, and the upper part of the cranial surface of the auricle ; it communicates with the greater occipital and great auricular.

Great Auricular Nerve.—Arises from the second and third cervical. Turns round sterno-mastoid ; ascends on its superficial surface, parallel to and behind ext. jugular vein, giving small branches to the skin of the neck ; pierces the deep fascia and divides into mastoid, auricular and facial branches.

Mastoid branches supply the skin over the mastoid region.

Auricular branches supply the lower two-thirds of the cranial surface of the auricle and lower third of its lateral surface ; both these communicate with the lesser occipital and posterior auricular.

Facial branches supply the skin that covers the lower parts of the parotid gland and masseter ; and they send branches into the parotid to communicate with the terminal branches of the facial nerve.

Anterior Cutaneous Nerve of Neck.—Arises from the second

and third cervical. Turns forwards across sterno-mastoid, about its middle. Pierces the deep fascia, runs forwards under cover of platysma, either superficial or deep to the ext. jugular vein, and divides into the two branches which supply the skin of the anterior triangle of neck; the upper branch communicates with the cervical branch of the facial.

Supraclavicular Nerves—lateral, intermediate and **medial.**—Are branches of a common trunk which arises from the junction of the third and fourth cervical nerves. It appears at the posterior border of sterno-mastoid below the other superficial nerves, and soon breaks up into its branches.

They descend through the lower part of posterior triangle, supplying the overlying skin. They pierce the deep fascia at varying points; run downwards over the clavicle and pass through the platysma to supply the skin of the chest and the shoulder down to the level of a horizontal line drawn from the sternal angle.

The medial branches cross sterno-mastoid and the sternal third of the clavicle; the intermediate branches cross the middle of the clavicle, and one or more of them may pass through the clavicle; the lateral branches cross trapezius and the acromial third of the clavicle.

Two **branches to levator scapulæ** from 3rd and 4th cervical appear a little above the middle of sterno-mastoid, run downwards and backwards, and soon enter the muscle.

Two **branches to trapezius** from 3rd and 4th cervical appear about the same place and run downwards and backwards across the triangle to trapezius. One of them may be thick enough to be mistaken for the accessory nerve; but they lie deep in the fat on levator scapulæ.

Accessory Nerve.—Generally counted among the contents of the triangle but is really in its roof.

Accessory nerve is the 11th cranial nerve, which arises partly inside the cranial cavity from the brain and partly from the spinal cord.

The part encountered here supplies sterno-mastoid and trapezius. It arises from the cord, ascends through foramen magnum to unite with the cranial part. Leaves it again as they pass through the jugular foramen, and descends along the front of internal jugular vein till it is midway between the mastoid process and the angle of mandible.

It then inclines backwards across internal jugular, pierces sterno-mastoid (supplying it), appears a little above the middle of its posterior border, runs downwards and backwards through a tunnel in the deep fascia of the roof of the triangle, disappears under trapezius about two inches above the clavicle and ramifies on its deep surface, supplying it.

As it emerges from sterno-mastoid, the lesser occipital hooks round it. As it runs towards trapezius it is parallel to the other nerves to trapezius and to the fibres of levator scapulæ, but it is separated from them by fat.

Brachial Plexus.—Lies partly in the antero-inferior part of the posterior triangle, partly behind the clavicle, and partly in the axilla. It has roots, trunks, divisions, cords and branches.

Its **roots are the nerves that form it, *i.e.* the anterior primary**

rami of 5, 6, 7, 8 cervical, greater part of 1 thoracic, and small contributions from 4 c. and 2 t.

Fifth cervical nerve receives a communication from the fourth, and combines with sixth to form the **upper trunk.** Seventh cervical alone forms the **middle trunk.** First thoracic nerve receives a communication from the second, gives off the first intercostal nerve, and combines with eighth cervical to form the **lower trunk.**

Each trunk splits into an **anterior** and a **posterior division.**

The upper two anterior divisions unite to form the **lateral cord.** Lower anterior division forms the **medial cord.** All three posterior divisions unite to form the **posterior cord.**

Relations of Brachial Plexus.—*Posterior to it,* there are scalenus medius and the roots of the nerve to serratus anterior.

Above clavicle, its *superficial* relations are:—1. Skin.

2. Superficial fascia, platysma, supraclavicular nerves.

3. First layer of deep fascia.

4. Transverse cervical and suprascapular and external jugular veins.

5. Second layer of deep fascia.

6. Inferior belly of omo-hyoid.

7. Transverse cervical art., and nerve to subclavius.

8. A third layer of deep fascia (*see* p. 272).

9. Third part of subclavian artery.

Behind clavicle and subclavius, the lowest part of the subclavian artery and the suprascapular artery are anterior.

Branches.—Its *roots* receive communicating branches and give off muscular branches. The other branches arise from the *cords* in the axilla.

Branches of Roots.—Communicating.—*Grey rami communicantes*—from middle cervical ganglion to 5th and 6th cervical nerves; from inferior ganglion to 7th and 8th; from first thoracic ganglion to 1st thoracic nerve.

Muscular Branches.—I. Root of phrenic nerve from 5th.

II. Twigs to scaleni and longus cervicis.

III. Nerve to rhomboids; nerve to subclavius; suprascapular nerve; nerve to serratus anterior.

Nerve to Rhomboids.—Arises from the back of the 5th cervical, pierces scalenus medius, passes under cover of levator scapulæ, and descends along the medial margin of the scapula under cover of levator scapulæ and rhomboideus minor and major, and supplies all three.

Nerve to Subclavius.—Arises from 5th, or 5th and 6th cervical nerves at their junction. It descends near the lateral margin of scalenus anterior, and sometimes sends a branch on to its anterior surface to join the phrenic; this takes the place of the root of the phrenic from the 5th. The brachial plexus and subclavian vessels are *behind* it. Omo-hyoid, transverse cervical and suprascapular vessels and clavicle are *in front of* it.

Suprascapular Nerve.—Arises from 5th and 6th cervical nerves at their junction, and runs obliquely downwards, sidewards and backwards, on scalenus medius, just above and lateral to the brachial plexus. It is crossed superficially by the transverse cervical vessels.

At the postero-inferior angle of the posterior triangle it passes deep to omo-hyoid and joins the suprascapular artery, which it accompanies to the upper border of the scapula. It passes beneath the suprascapular lig. through the notch, and supplies supraspinatus and infraspinatus and the shoulder-joint.

Nerve to Serratus Anterior.—Arises by three roots from the backs of the 5th, 6th, 7th cervical nerves. Roots from 5th and 6th pierce scalenus medius; root from 7th crosses it superficially. They leave scalenus and pass over the first digitation of serratus anterior; unite to form one stem, which descends along the axillary surface of serratus, supplying that muscle. The roots of the nerve are hidden behind the brachial plexus.

Sterno-Clavicular Joint.—*See* p. 128.

THE BACK

Landmarks and Superficial Fascia.—*See* p. 171.

Deep Fascia.—More than one layer:—

(1) A dense, investing layer covers trapezius and latissimus dorsi, and extends from the nuchal line to the iliac crest. *Laterally*, it is continuous with the investing layer in neck, with the fascia of the shoulder (being also attached to clavicle and spine of scapula), and with the fascia of the axilla and the side and front of the abdomen. *Medially*, from above downwards, it is attached to lig. nuchæ, thoracic supraspinous ligaments and the posterior layer of the lumbar fascia.

(2) A loose layer lines the deep surface of trapezius and latissimus, envelops the rhomboids and levator scapulæ, and covers the serratus posterior muscles and splenius.

(3) A strong, dense layer covers sacro-spinalis and its extensions, and stretches from the sacrum to the deeper fascial septa in the back of the neck. *On the thorax*, it stretches from the vertebral spines to the angles of the ribs, and is partly replaced inferiorly by serratus posterior inferior. *In the loin*, it is greatly thickened and forms the posterior layer of lumbar fascia.

Lumbar Fascia.—Posterior, middle and anterior layers.

Posterior Layer.—Very thick and strong. Covers sacro-spinalis in the loin. Continues upwards over it on to the back of chest, and downwards over it to be attached to iliac crest and sacrum. Attached medially to vertebral spines. Laterally, it fuses with the middle layer at the lateral border of sacro-spinalis.

Middle layer stretches from the last rib to the iliac crest and the ilio-lumbar lig. Covers the back of quadratus lumborum and separates it from the lateral part of sacro-spinalis, except infero-laterally, where it separates quadratus from latissimus dorsi. Medially, it is attached to the tips of the lumbar transverse processes. Laterally,

it fuses with the anterior layer at the lateral border of quadratus to form a band that stretches between iliac crest and last rib, and gives partial origin to transversus and obliquus internus abdominis.

Anterior layer stretches from the last rib to the iliac crest and the ilio-lumbar lig. Covers the front of quadratus lumborum and separates its medial part from psoas major. Attached medially to the fronts of the lumbar transverse processes near their tips. Upper part is fused with the lateral arcuate ligament of the diaphragm.

Ligamentum Nuchæ.—A thin, triangular, fibrous sheet set between the muscles of the two sides of the back of the neck. Attached by its base to the external occipital crest; by its *apex* to 7th cervical spine; by the *anterior border* to the other cervical spines. *Posterior border* is a free edge that stretches from 7th cervical spine to the external occipital protuberance, and gives origin to parts of trapezius, splenius and rhomboideus minor.

Muscles.—*Are arranged in layers. The more important muscles will be considered first. The arrangement into layers and the attachments of the other muscles will be described later.*

Trapezius (p. 171); latissimus dorsi (p. 172); levator scapulæ (p. 172); rhomboidei (p. 173). All considered under Upper Limb.

Serratus posterior superior, very thin, lies under the rhomboidei.
Origin (tend.): last cervical and upper three thoracic spines.
Insertion (fl.-tend.): second to fifth ribs, in front of their angles.
Nerves: second, third and fourth intercostals.
It elevates ribs in forced inspiration.

Serratus posterior inferior, also very thin. Lies under cover of latissimus dorsi.
Origin (tend.): last two thoracic and first two lumbar spines.
Insertion (fl.): lower four ribs, in front of their angles.
Nerves: 9th, 10th, 11th intercostals and the subcostal.
It fixes the lower ribs when the diaphragm contracts; and it draws them backwards in forced inspiration.

Splenius.—A long, wide strap of muscle. Lies in the back of the neck and of the upper part of the trunk. First, under cover of trapezius and rhomboidei; next, partly superficial in the floor of the posterior triangle of the neck and partly under cover of levator scapulæ; finally, under cover of sterno-mastoid.

Origin (tend.): lower half of lig. nuchæ, last cervical and upper six thoracic spines and supraspinous ligaments.

Insertion (tend.): *Splenius capitis* into mastoid temporal bone and lateral third of superior nuchal line. *Splenius cervicis* (which is hidden under levator scapulæ) into the transverse processes of the upper two to four cervical vertebræ behind the origin of levator scapulæ.

Nerves: posterior primary rami of 4th to 8th cervical nerves.

Muscles of both sides acting extend the head and neck; one

muscle acting bends the head and neck to that side and turns the face towards that side.

Sacro-Spinalis.—Is the mass of muscle that lies in the small of the back. It begins on the back of the sacrum and extends upwards through the loin on to the back of the chest, where it divides into three columns which will be described later.

Longissimus Capitis.—A long, slender muscle that lies near the backs of the transverse processes between splenius and semispinalis capitis.

Arises chiefly from the upper 6 thoracic transverse processes.

Inserted into mastoid process under cover of splenius.

Both muscles acting extend the head; one acting alone bends the head to that side, and turns the face towards that side.

Semispinalis Capitis.—Thick and powerful. Lies along the median plane in the back of the neck and upper part of trunk, under cover of trapezius and splenius. **Origin**: same as longissimus capitis.

Inserted into the medial half of the area between superior and inferior nuchal lines (fl.).

Both muscles acting extend the head: one acting alone bend the head to that side, and turns the face to the opposite side.

Semispinalis Cervicis.—A thick mass. Lies under cover of semispinalis capitis, and has the same **origin** (tend.). **Inserted** chiefly into 2nd cervical spine, but also into 3rd, 4th, 5th (fl.-tend.).

The posterior primary rami lie on its surface.

Both muscles acting bend the neck backwards. One acting alone rotates the neck.

Levatores Costarum.—Twelve small, fan-shaped muscles that belong to the thorax, but are found in the deepest part of the back.

Arise from 7th cervical transverse process and upper 11 thoracic transverse processes and radiate to the ribs medial to their angles.

Each is supplied by the nearest intercostal nerve.

Suboccipital Muscles.—Two recti and two obliqui. Lie deep in the uppermost part of the back of the neck, under cover of splenius and semispinalis capitis.

Supplied by the posterior primary ramus of first cervical nerve.

Obliquus Capitis Inferior.—**Origin** (tend.-fl.): spine of axis. **Insertion** (fl.-tend.): transverse process of atlas.

It turns the face to the same side.

Obliquus Capitis Superior.—**Origin** (fl.-tend.): transverse process of atlas.

Insertion (fl.): lateral part of the space between nuchal lines.

Its direction is backwards and slightly upwards. Bends the head backwards and to the same side.

Rectus Capitis Posterior Major.—**Origin** (tend.): spine of axis. **Insertion** (fl.): lateral part of the space between the inferior nuchal line and foramen magnum.

Both acting extend the head. One acting alone turns the face to the same side.

Rectus Capitis Posterior Minor.—Fan-shaped and very small. Lies medial to major and partly under cover of it.

Origin (tend.): tubercle on the posterior arch of atlas.

Insertion (fl.): medial part of the space between the inferior nuchal line and foramen magnum. Tilts the head backwards.

Suboccipital Triangle.—Placed deeply at the uppermost part of the back of the neck.

Boundaries: Obliquus inferior, infero-laterally; obliquus superior, supero-laterally; rectus major, supero-medially.

Roof: Splenius capitis, laterally; semispinalis capitis, medially. Greater occipital nerve crosses the triangle, superficially, under cover of semispinalisc apitis.

Floor: Posterior arch of atlas; and, when the boundaries are separated, the ligaments which unite that arch to the posterior margin of the foramen magnum and to the lamina of the axis.

Contents: 1. Vertebral artery on the posterior arch of atlas.

2. Posterior primary ramus of the first cervical nerve, emerging from below the artery and dividing to supply adjacent muscles.

3. The suboccipital plexus of veins.

4. Fat and tough fibrous tissue.

VERTEBRAL ARTERY.—A branch of the first part of subclavian. Has four parts:—*First* in the root of the neck; *second* in the foramina of the transverse processes of the upper six cervical vertebræ; *third* in the suboccipital region; *fourth* in the cranial cavity.

Third Part of Vertebral Artery.—Begins at the foramen of the transverse process of atlas medial to rectus lateralis and lateral to the anterior primary ramus of the first cervical nerve.

Passes backwards and medially behind the superior articular surface of atlas, enters the groove on the posterior arch of atlas, runs medially in it above the posterior primary ramus of the first cervical nerve, turns forwards below the lateral part of the lower border of the posterior atlanto-occipital membrane (p. 122) and becomes the fourth part, which pierces the dura mater and arachnoid and ascends into the posterior cranial fossa. The third part gives small branches to muscles.

Occipital Artery.—Is immediately above the suboccipital triangle in the second part of its course.

Arises in the front of the neck from external carotid and runs along the posterior belly of the digastric muscle to disappear under that belly and the mastoid process at the lateral side of rectus lateralis.

Its **second part** appears in the back of the neck by emerging from under cover of mastoid process and the insertion of longissimus capitis; curves backwards and upwards in a shallow groove on

the skull, under cover of splenius capitis and sterno-mastoid—lying first on obliquus superior and then on semispinalis capitis. As it lies on semispinalis, it passes from under sterno-mastoid, crosses the apex of the posterior triangle and slips under trapezius. Almost at once, it pierces trapezius and the deep fascia at their attachment to the superior nuchal line, an inch lateral to occipital protuberance, and becomes the **third part,** which ascends, branching, through the superficial fascia of the back of the head (p. 262).

Occipital Veins.—No vein of any size runs with the second part, for the veins that accompany the third part end in the suboccipital plexus.

Branches.—Second part, as it lies on obliquus superior, gives off:—

1. A **mastoid branch,** which enters the mastoid foramen and supplies bone and dura mater.

2. Muscular branches, the biggest being the **descending branch,** which ramifies on both surfaces of semispinalis capitis and anastomoses with the deep cervical artery.

Deep Cervical Artery.—A branch of the costo-cervical trunk, which springs from the second part of subclavian. It arises at the neck of the first rib. Passes backwards below the seventh cervical transverse process, above the rib, the first thoracic transverse process and the eighth cervical nerve, and ascends in the back of the neck between semispinalis capitis and semispinalis cervicis.

Deep cervical vein, much wider than the artery, begins in the suboccipital plexus and runs alongside the artery to the front of the neck to end in the vertebral vein.

Suboccipital Plexus of Veins.—Lies on the boundaries of the suboccipital triangle and in the triangle amidst the fatty fascia that conceals the vertebral artery. It receives the occipital veins, posterior condylar emissary vein, veins from muscles around it and veins from networks inside vertebral canal. It is drained by the deep cervical vein and the plexus around the second part of the vertebral artery.

Posterior Primary Ramus of First Cervical Nerve.—Does not divide into lateral and medial branches like other posterior rami, and usually has no separate cutaneous branch.

It springs from the nerve-trunk on the posterior arch of atlas near the lateral mass, and passes backwards between the arch and the vertebral artery and onwards through the fat and fascia till it is near the roof of the triangle. It then divides into radiating branches:—to both recti and both oblique muscles and semispinalis capitis. The branch to rectus minor may pierce the major to reach the minor. A communicating branch from the branch to inferior oblique joins the greater occipital and may contain cutaneous fibres. Occasionally a separate cutaneous filament passes between splenius and semispinalis capitis and accompanies the occipital artery to the back of the head.

Greater Occipital Nerve.—Has some motor fibres for semispinalis capitis but is mainly a cutaneous nerve—the thickest in the body. It is the medial branch of the posterior primary ramus of the second cervical nerve. Arises under cover of obliquus inferior and appears at the middle of the lower border of that muscle. Runs upwards and medially across the suboccipital triangle under semispinalis capitis; pierces that muscle and passes upwards between it and trapezius; pierces trapezius and the deep fascia at their attachment to the superior nuchal line, medial to the occipital artery, an inch from the protuberance; and ramifies in the superficial fascia of the back of the head.

Third Occipital Nerve.—Comes from the medial branch of the posterior ramus of c. 3. Crosses the medial corner of suboccipital triangle, pierces semispinalis, trapezius and deep fascia to supply skin of the nape of the neck and over the occipital protuberance.

LAYERS OF MUSCLES IN THE BACK.—1. Trapezius and latissimus dorsi (pp. 171, 172).

2. Levator scapulæ, rhomboids, serratus posterior superior and inferior, and splenius (pp. 172, 173, 279).

3. Sacro-spinalis and semispinalis and their divisions.

4. Multifidus, rotatores, interspinal, intertransverse, suboccipital.

Sacro-spinalis.—**Arises** by a thick wide tendon from iliac crest, posterior sacro-iliac ligs., transverse and spinous tubercles of sacrum, all lumbar spines and the lower two thoracic spines.

Divides into three columns which lie in the groove between thoracic spines and the angles of the ribs—**spinalis** medially, **ilio-costo-cervicalis** laterally, and **longissimus** between them and each of these is further divided into overlapping columns named according to their attachment (which is by tendinous slips) :—

Ilio-costo-cervicalis divides into *ilio-costalis*, *costalis* and *costo-cervicalis*.

Longissimus into *longissimus thoracis*, *L. cervicis* and *L. capitis*.

Spinalis into *spinalis thoracis*, *S. cervicis* and *S. capitis*.

Ilio-costalis arises from iliac crest through the common tendon, and is **inserted** into the lower 6 ribs. **Costalis arises** from the lower 6 ribs medial to ilio-costalis, and is **inserted** into the upper 6 ribs. **Costo-cervicalis arises** from the upper 6 ribs medial to costalis, and is **inserted** into the 4th, 5th and 6th cervical transverse processes.

Longissimus thoracis arises, through the common tendon, from the sacrum and lower lumbar spines, and is **inserted** into lumbar transverse and accessory processes, all thoracic transverse processes and the lower 10 ribs. **L. cervicis arises** from the upper 6 thoracic transverse processes medial to L. thoracis, and is **inserted** into 2nd-6th cervical transverse processes. **L. capitis arises** from the upper 6 thoracic transverse processes with L. cervicis and from articular processes of the lower 4 cervical vertebræ, and is **inserted** into mastoid process (*see also* p. 280).

Spinalis thoracis arises, through the common tendon, from the upper 2 lumbar and lower 2 thoracic spines and by fleshy fibres from the tendons of longissimus thoracis, and is **inserted** into the upper 6 thoracic spines. **Spinalis cervicis**—not always present—**arises** from the upper 2 thoracic spines and last cervical spine, and is **inserted** into the upper 3 cervical spines. **Spinalis capitis** is fused with the medial part of semispinalis capitis.

Semispinalis is divided into semispinalis thoracis, S. cervicis and S. capitis (p. 280).

Semispinalis thoracis is deep to spinalis, and is attached by tendinous slips. **Arises** from the lower 6 thoracic transverse processes. **Inserted** into the upper 4 thoracic spines and lower 2 cervical spines.

Multifidus is a long succession of fleshy and tendinous slips that lie on laminæ from sacrum to axis. **Arises** from the back of sacrum between spinous and transverse tubercles and from the overlying part of the tendon of sacro-spinalis, from lumbar mamillary processes and thoracic transverse processes and from articular processes of the lower 4 cervical vertebræ. Slips pass obliquely upwards to be **inserted** into spines from the lower lumbar to the second cervical.

Rotatores.—11 on each side, deep to multifidus. Each **arises** from a thoracic transverse process and is **inserted** into the lamina immediately above (fl.-tend.).

Interspinales connect spinous processes.

Intertransversales connect transverse processes.

7 pairs on each side in *cervical* region, connected with anterior and posterior tubercles (the first anterior is usually absent, for the anterior tubercles of atlas and axis are absorbed). Anterior primary ramus of a cervical nerve passes out between each pair. Rectus capitis anterior and lateralis are homologous with anterior and posterior intertransverse.

Ill-developed in *thoracic* region.

Arranged in pairs in *lumbar* region—the **lateral** connects the transverse processes; the **medial** connects mamillary process of one vertebra with accessory process of vertebra above.

Suboccipital Muscles.—*See* p. 280.

Nerve-Supply of Muscles of Back.—Trapezius by *accessory* and *anterior primary rami* of C. 3 and 4. Latissimus dorsi, levator scapulæ, the rhomboids, serrati, intertransverse and levatores costarum by *anterior primary rami*. All the others by *posterior primary rami*.

Action of Muscles of Back.—Those whose actions have not been given above, raise the flexed trunk to the erect posture, maintain it there, and may bend it backwards. When muscles of one side act they bend the trunk and the head to that side; and those which run obliquely upwards and medially rotate them towards the opposite side; those which run upwards and laterally

(few in number) rotate towards the same side. But their actions as antagonists, fixation-muscles and synergists are as important as their actions as prime movers (p. 161).

Nerves of the Back.—Are the posterior primary rami of spinal nerves. Nearly all of them arise in intervertebral foramina and pass backwards between transverse processes. Those that do not do so are the first cervical, all the sacral and the coccygeal. The first cervical is above the posterior arch of atlas (p. 282). The upper four sacral emerge through the posterior sacral foramina. The fifth sacral and the coccygeal emerge through the lower end of the sacral canal.

Except c. 1, s. 4 and 5 and the coccygeal, each divides into a lateral and a medial branch. In the *upper half* of the body, the **medial** branches supply muscles and skin, the **lateral** branches supply muscles only. In the *lower half* of the body, *vice versa*. Cutaneous branches pierce to deep fascia therefore only an inch from the median plane in the upper half of the trunk and nearly four inches in the lower half.

Cervical Posterior Rami.—**First** does not divide (*see* p. 282). Other cervical posterior rami pass backwards behind the vertebral artery and the posterior intertransverse muscles.

Second pierces the posterior atlanto-axial membrane (together with the anterior ramus) close to the postero-medial side of the atlanto-axial synovial joint, under cover of obliquus inferior. Its lateral branch receives communicating branches from the first and third, and supplies muscles. Medial branch is the *greater occipital nerve* (pp. 261, 283).

Third, fourth, fifth and **sixth** have small *lateral* branches for muscles. Their *medial* branches run between semispinalis cervicis and capitis; unite with one another and with the second to form a looped plexus; supply muscles and send cutaneous branches to the skin of the whole of the back of the neck—the cutaneous branch of the third being called the *third occipital nerve* (p. 283).

Seventh and **eighth** send both of their branches to muscles; and the medial branches are deep to semispinalis cervicis.

Thoracic Posterior Rami.—Supply muscles and skin of the back. Medial branches of upper six and lateral branches of lower six are cutaneous as well as motor. Before reaching the skin they descend for a distance, increasing from above downwards, till the skin of the loin is supplied by lower thoracic nerves.

Lumbar Posterior Rami.—Upper three:—Medial branches, to multifidus. Lateral branches supply sacro-spinalis and then pierce the lumbar fascia near the highest point of the iliac crest, and supply skin of the gluteal region.

Lower two supply muscles only. Lowest communicates with the first sacral.

Sacral Posterior Rami.—Upper three :—Medial branches, to multifidus. Lateral branches form loops joined by communications from 5th lumbar and 4th sacral. Branches from the primary loops form a secondary plexus on the sacro-tuberous ligament, from which terminal filaments are distributed to sacro-spinalis, and pierce gluteus maximus to supply the skin over the back of the sacrum and adjoining part of the gluteal region.

Lower two do not divide.

Coccygeal Posterior Ramus.—Does not divide. It assists the lower two sacral to form loops which supply skin over the coccyx.

Blood-Vessels of the Back.—**Superficial branch** of **transverse cervical artery** ramifies on the deep surface of trapezius in both *cervical* and *thoracic regions*, and is accompanied by its **vein.**

In cervical region.—**Occipital, deep cervical** and third part of **vertebral** artery (pp. 281, 282) and small muscular branches from the second and third parts of vertebral ; and associated **veins.**

In thoracic and lumbar regions.—Posterior branches of **intercostal** and **lumbar** arteries accompany posterior primary rami and are distributed with them to muscles and skin. They supply bones also ; and they send *spinal* branches into the vertebral canal. Accompanying **veins** receive tributaries from muscles, skin and bones, from the contents of vertebral canal and from the posterior vertebral venous plexus ; and they end in intercostal veins.

In sacral region.—The vessels are branches of **lateral sacral** arteries that come out of the sacral canal through the posterior sacral foramina (accompanied by veins), and also branches and tributaries of **gluteal vessels.**

Posterior external vertebral venous plexus is a network on the back of the vertebral arches. Drains blood from muscles, skin, ligaments and bones, and passes it on to vertebral, intercostal, lumbar and lateral sacral veins.

Contents of Vertebral Canal and Intervertebral Foramina

Vertebral canal contains :—1. Structures in extradural space.
2. Spinal membranes and cerebro-spinal fluid.
3. Spinal cord and its vessels (p. 542).
4. Roots of spinal nerves and their sheaths.

Extradural Space.—The interval that separates the walls of the vertebral canal from the dura mater—*i.e.* the outermost of the three membranes or meninges which surround the spinal cord. It is filled with a meshwork of areolar tissue which encloses semiliquid fat and blood-vessels on their way to supply the walls of the vertebral canal and all the structures within the canal.

The arteries are very small and are called **spinal arteries.** They enter through the intervertebral foramina; and they are derived from the vertebral, ascending cervical and deep cervical in the neck, from the posterior branches of the intercostal and lumbar arteries, and from the lateral sacral arteries.

The **spinal veins** are much larger and more numerous than the arteries, and they include the veins on the outside of the vertebral column. Those in the extradural space form networks called *internal vertebral venous plexuses*. They communicate with the posterior external vertebral plexus, with the suboccipital plexus and with the cranial venous sinuses near the foramen magnum. They are drained chiefly by *intervertebral veins* that pass out through the intervertebral foramina to end in tributaries of the vertebral, intercostal, lumbar and lateral sacral veins—the blood from the spinal cord passing chiefly to the vertebral and intercostal veins.

The longitudinal channels in the internal vertebral plexuses are two pairs of **vertebral sinuses—anterior** and **posterior.** The posterior pair are on the deep surface of the laminæ. The anterior pair lie on the back of the vertebral bodies along the edges of the posterior longitudinal ligament, and are connected by cross-branches that lie between that ligament and the bone; their biggest tributaries are short, wide veins—*basi-vertebral veins*—that come out through the back of the vertebral bodies and join these cross-branches.

The veins of the spinal cord are described with the cord—p. 545.

The spinal veins on the outside of the backbone are an *anterior external vertebral plexus* on the front, and a *posterior external vertebral plexus*—made of larger veins—around the vertebral arches and the processes. Their drainage is like that of the internal plexuses.

MENINGES OF SPINAL CORD.—The cord is surrounded by three tubular, fibrous membranes or meninges named from without inwards *dura mater*, *arachnoid mater* and *pia mater*, and they are continuous with the corresponding membranes of the brain.

Dura and **arachnoid mater** invest the cord very loosely, and, while the cord ends at the upper part of the second lumbar vertebra, they extend much farther down—ending blindly at the second sacral vertebra, at the level of the dimple above the buttock that marks the position of the posterior superior iliac spine. The interval between them is called the **subdural space** and is a mere

capillary interval that contains only enough lymph to keep the surfaces moist.

Subarachnoid space, between arachnoid and pia, is wide and is filled with a clear liquid called subarachnoid fluid or *cerebro-spinal fluid* ; the space and the fluid extend to the lower end of the arachnoid tube.

Pia mater is the membrane in which the blood-vessels ramify before they enter the spinal cord. It is therefore an adherent covering, and, as a tube, it consequently extends no farther than the cord does ; but, from its lower end, some of its fibres are prolonged downwards as a slender, glistening, fibrous thread, called the **filum terminale,** which pierces the lower ends of the arachnoid and dural tubes and runs on to fuse with the periosteum of the back of the coccyx.

On each side of the spinal cord, there is a longitudinal ridge of pia mater called the **ligamentum denticulatum** because pointed processes stand out from its free edge. The points of these " teeth " push their way through the arachnoid to be attached to the dura mater ; by means of them the cord is slung in the middle of the arachno-dural tube.

And, on the front, the pia mater is folded into the anterior median fissure of the cord and lines the sides of the fissure. The two layers of the fold are more or less adherent to each other ; and at the surface, between the lips of the fissure, these adherent layers are thickened to form a slender, shining band called the **linea splendens.**

Spinal **dura mater,** dense and strong, is continuous only with the inner layer of the cranial dura ; the veins in the extradural space are therefore in the same morphological plane as the cranial venous sinuses. The dural tube is adherent to the margins of foramen magnum and to the back of the bodies of the second and third cervical vertebræ ; and it is connected by loose fibrous bands with the posterior longitudinal ligament near its upper and lower ends.

The **arachnoid mater,** thin and transparent, made of very fine fibrous tissue, is connected with the pia mater on each side by the teeth of the lig. denticulatum, and, posteriorly, by a weak, incomplete median *subarachnoid septum.*

The **pia mater** is thicker than the pia mater of the brain, as it is strengthened superficially by longitudinal fibres. **Lig. denticulatum** has 21 teeth. The uppermost tooth is at the foramen magnum between the vertebral artery and the accessory nerve ; the lowest is at the level of the first lumbar vertebra. Lig. denticulatum and linea splendens are both continued into the **filum terminale ;** and

the filum drags off sheaths of arachnoid and dura as it pierces them.

Spinal Nerves and their Roots.—31 pairs of nerves are attached to the spinal cord—8 cervical, 12 thoracic, 5 lumbar, 5 sacral and 1 coccygeal.

The cord is divisible, therefore, into five regions—cervical, etc.—but these do not lie opposite corresponding regions of the vertebral column, for the cord is much shorter than the column. Note that there are 8 cervical nerves though there are only 7 cervical vertebræ; and only the first coccygeal vertebra has a nerve. The upper seven cervical nerves escape from the vertebral canal above the corresponding vertebræ; the eighth below the seventh vertebra. Below that, each nerve leaves the vertebral column *below* the corresponding vertebra.

Each nerve is attached to the cord by two bundles of nerve-fibres called its roots—an anterior and a posterior.

The **anterior root** is composed of *motor fibres* that arise in the spinal cord and emerge through its anterior surface. The **posterior root** is made of *sensory fibres*; and it has a ganglion on it—the **spinal ganglion.** The sensory fibres arise in the ganglion, and, while still in the ganglion, each splits into a central branch and a peripheral branch. **Peripheral branches** run on in the nerve. The **central branches** run towards the cord and form the posterior root; they enter the back of the cord; and some end in the cord and some in the medulla oblongata—*i.e.* the lowest division of the brain.

Immediately beyond the ganglion, the two roots unite in order to mingle the motor and sensory fibres. By their union, they form the **spinal nerve-trunk**; and, almost at once, the nerve-trunk divides into an **anterior** and a **posterior primary ramus,** each of which contains both motor and sensory fibres; but, before it divides, it sends a tiny *meningeal branch* to the spinal cord and its membranes and vessels.

The roots of a nerve unite in the intervertebral foramen through which the nerve leaves the backbone. The roots of the upper cervical nerves are therefore short and horizontal, but, owing to the disparity in length of spinal cord and backbone, the others have farther and farther to travel before they reach their vertebræ. The lumbar,

sacral and coccygeal nerve-roots are therefore very long and run vertically. Below the cord they form a loose bundle known as the **cauda equina** from its resemblance to the tail of a horse; and the filum terminale is in the middle of this bundle.

The **posterior roots** are thicker than the anterior roots except the first cervical, whose posterior root and spinal ganglion are either small or absent. They enter the cord in linear order through the floor of a narrow, shallow groove on the back of the cord; but the fibres of each **anterior root** come out irregularly over a fairly wide strip on the front.

The **lig. denticulatum** is about midway between the two rows of roots; and, in the cervical region, the *spinal roots* of the **accessory nerve** (11th cranial) also are between them, immediately behind the lig. denticulatum.

The nerve-roots pierce the meninges and drag off separate **sheaths** that enclose offshoots of the subarachnoid and subdural spaces. The **pial sheath** fits each root closely; the **arachnoid sheath** is loose; and both extend only as far as the dura. The **dural sheath** is a strong tube, and the sheaths of the two roots extend as far as the spinal ganglion, where they unite into one sheath; this sheath encloses the nerve-trunk, is adherent to the walls of the intervertebral foramen, and is continuous with the fibrous sheaths (*epineurium*) of the primary rami.

The **anterior primary rami** are thicker than the **posterior rami,** except the first and second cervical.

Nearly every **spinal ganglion** and **nerve-trunk** lie in an intervertebral foramen. The exceptions are:—First and second cervical, which lie above and below the posterior arch of the atlas; sacral ganglia, which lie in the sacral canal; and the coccygeal ganglion, which is within the tube of dura mater.

An **intervertebral foramen** contains:—1. The ends of the roots of a nerve, the spinal ganglion, the nerve-trunk, and the beginning of the primary rami. 2. A spinal artery. 3. An intervertebral vein.

Contents of Cranial Cavity and Orbit.—*See* pp. 48, 64.

ANTERIOR PART OF NECK

is the part bounded by mandible, manubrium sterni and the right and left sterno-mastoid. It is divided by the median plane into a right and a left symmetrical, triangular half—the *anterior triangle of the neck.*

Landmarks to be Identified.—Mastoid process. Body and angle of mandible. Hyoid bone; thyroid and cricoid cartilages; trachea and isthmus of thyroid gland. Manubrium sterni; sterno-clavicular

joint; medial third of clavicle; sterno-mastoid. First, fourth and sixth cervical transverse processes.

Superficial Fascia.—Contains: 1. A variable quantity of *fat*, which tends to accumulate greatly below the chin in stout people.

2. A great part of *platysma* (p. 265).

3. *Cervical branch of facial nerve* (p. 265) curving forwards below the mandible under cover of platysma and supplying it.

4. The branches of *anterior cutaneous nerve of neck* (p. 275) piercing platysma and spreading up and down to supply skin.

5. *Anterior jugular vein.*

6. Small *unnamed arteries* that come from deeper arteries through the deep fascia; and *veins* which partly accompany the arteries and partly form a network drained by the anterior jugular.

7. *Lymph-vessels* partly pass to glands that lie along the anterior and external jugular veins and partly pierce the deep fascia to end in deep glands.

8. *Lymph-glands*:—(*a*) A few on sterno-mastoid alongside external jugular vein receive lymph from adjoining skin and from parotid lymph-glands, and pass it on to deep glands. (*b*) A few alongside anterior jugular vein receives lymph from skin and sends it to deep glands. (*c*) Three or four *submental lymph-glands* lie between the hyoid bone and the chin, and may be palpable even when healthy. They receive lymph from the median part of chin and lower lip, lower incisors and gums, anterior part of floor of mouth and tip of tongue; and they send it to deep glands.

Anterior Jugular Vein.—Begins below the chin by the union of small unnamed veins, and it descends near the median plane. An inch above the sternum, it pierces the first layer of deep fascia, bends abruptly sidewards and runs deep to sterno-mastoid just above the clavicle, across sterno-thyroid, sterno-hyoid and scalenus anterior; and it ends in the external jugular at the posterior border of sterno-mastoid.

Receives small unnamed veins. And at the point where it bends it is connected with its fellow by a wide, transverse channel called the **jugular arch,** which lies between two layers of deep fascia above manubrium.

Deep Fascia.—More than one layer. The **investing fascia** splits to enclose sterno-mastoid. Anteriorly it is continuous, without interruption, with the fascia of the opposite side, except that it adheres to the greater horn and body of hyoid bone. Superiorly, as it passes from the hyoid bone to be attached to the mandible, it splits to enclose the digastric muscle and submandibular salivary gland; and, behind the mandible, it extends up to the skull ensheathing the parotid gland.

Below the level of the cricoid cartilage, it splits into two layers which are attached to the front and back of manubrium. **Supra-sternal space** is the interval between these layers. It contains fat,

jugular arch, interclavicular ligament and the sternal heads of the sterno-mastoids.

Pretracheal fascia covers the front and sides of the trachea and ensheaths the thyroid gland. Attached superiorly to thyroid and cricoid cartilages. Passes into thorax with the trachea, and, at the lower end of trachea, it fuses with the back of the upper part of pericardium.

Muscles.—Sterno-mastoid; infrahyoid muscles (omo-hyoid, sterno-hyoid, sterno-thyroid and thyro-hyoid); levator glandulæ thyreoideæ; crico-thyroid; constrictors of pharynx; digastric; stylo-hyoid; mylo-hyoid; hyo-glossus.

Sterno-Cleido-Mastoideus.—Sterno-mastoid forms oblique elevation on side of neck, extending from manubrium to mastoid process, between triangles of neck.

Origin: *Sternal head* (tend.): upper lateral part of the front of manubrium sterni. *Clavicular head* (fl.-tend.): upper surface of medial third of clavicle.

Insertion (fl.-tend.): lateral surface of mastoid temporal and lateral third of superior nuchal line of occipital.

Nerve: accessory and a branch from the anterior primary ramus of c. 2.

Both muscles acting flex neck and extend head, or they elevate anterior wall of chest. One acting flexes head, bends it to that side and turns face towards opposite side.

Superficial surface is in relation to: platysma; ext. jugular vein; lesser occipital and great auricular nerves, anterior cutaneous nerve of the neck and medial supraclavicular nerves; lymph-glands. Overlapped by parotid gland.

Deep surface is in relation to a large number of structures in the neck.

Accessory nerve pierces it. One branch of occipital artery enters with the nerve, and another a little lower. A branch of superior thyroid enters at the level of cricoid cartilage, and one from suprascapular near clavicle.

Infrahyoid Muscles.—Attached to thyroid cartilage and hyoid bone and move them. Thyro hyoid is supplied through the *thyro-hyoid branch of hypoglossal* by fibres from the anterior primary ramus of the first cervical. The others are supplied through *ansa hypoglossi* by fibres from c. 1, 2 and 3.

Sterno-thyroid, a long, wide, thin ribbon, is in the lower part of front of neck and overlies thyroid gland.

Arises (fl.) from the back of manubrium and first

costal cartilage and is **inserted** (fl.) into the oblique line of thyroid cartilage.

Thyro-hyoid, of equal width, continues the direction of sterno-thyroid and lies on thyroid cartilage and thyro-hyoid membrane.

Arises (fl.) from oblique line of thyroid and is **inserted** (fl.-tend.) into the lower border of body and greater horn of hyoid bone.

Sterno-hyoid lies on sterno-thyroid and thyro-hyoid; and it is narrower.

Being superficial to sterno-thyroid its **origin** (fl.) is higher—from the back of manubrium and sternal end of clavicle. **Insertion** (fl.-tend.): medial half of lower border of body of hyoid bone.

Its lower part is hidden by sterno-mastoid; its upper part is under the fascia.

Omo-Hyoid.—Two bellies and an intervening tendon.

Tendon lies on internal jugular vein opposite cricoid cartilage and is held in place by fascia that spreads down from the muscle to the back of manubrium, clavicle and first costal cartilage.

Inferior belly (p. 273) ends in the tendon.

Superior belly springs from the tendon and ascends almost vertically along the lateral side of sterno-hyoid over sterno-thyroid and thyro-hyoid to be **inserted** into the lateral part of lower border of body of hyoid bone (fl.).

Its beginning is under sterno-mastoid; but most of it is covered only with fasciæ and skin.

Levator glandulæ thyreoideæ is an occasional slender slip that extends from the left half of the isthmus of thyroid gland to the hyoid bone.

Crico-thyroid, a muscle of the larynx, and very small. Passes from the anterior part of the cricoid cartilage upwards and backwards to the thyroid cartilage. Largely hidden by sterno hyoid and sterno-thyroid, but part of it is under the fascia medial to them.

Inferior constrictor of pharynx, a wide sheet, hidden by the infrahyoid muscles and the contents of carotid triangle. Curves backwards in the wall of the pharynx from the side of the larynx.

Middle constrictor, a fan-shaped sheet, also hidden by the contents of carotid triangle. Curves backwards radiating in the wall of the pharynx from the horns of the hyoid bone.

Superior constrictor sweeps backwards in the upper part of wall of pharynx from the medial pterygoid plate, pterygo-mandibular lig. and mylo-hyoid line of mandible.

Digastricus (p. 313) has an anterior and a posterior belly united by a round tendon.

Tendon lies on hyo-glossus just above the hyoid bone; it is bound to the bone by a sling-like pulley of fascia through which the tendon moves backwards and forwards.

Anterior belly arises from the lower border of mandible close to symphysis menti, and passes backwards, sidewards and downwards tapering to join the tendon; covered only with skin and fasciæ.

Posterior belly arises from the floor of the mastoid notch; slants forwards and downwards, overlapped by the parotid gland and angle of mandible; tapers to join the tendon.

Stylo-hyoid (p. 314), a slender slip, runs along the upper border of posterior belly of digastric from styloid process to hyoid bone.

Mylo-hyoid (p. 314), a wide sheet in the floor of the mouth. Arises from mylo-hyoid line of mandible and curves medially, downwards and forwards to be inserted partly into the body of the hyoid bone but chiefly into the **mylo-hyoid raphe**—a slender tendinous band that passes from symphysis menti to the body of hyoid bone and sews the edges of the two mylo-hyoids together (*raphe* = a seam). Mylo-hyoid muscle is largely hidden by mandible, submandibular gland and anterior belly of digastric, but the raphe and the part of the muscle medial to anterior belly are covered only with skin and fasciæ.

Hyo-glossus (p. 315), a four-sided sheet. Passes from hyoid bone to the side of the tongue. Hidden by mandible, submandibular gland, digastric and mylo-hyoid, but its lower posterior part appears in carotid triangle between hyoid bone and the end of posterior belly of digastric.

Median Region of Front of Neck

A strip an inch wide between chin and sternum. The parts to be examined in it are as follows:—

1. **Superficial fascia** containing **submental lymph-glands, anterior jugular vein** (p. 291), fibres of **platysma** decussating beneath the chin, and terminations of branches of **anterior cutaneous nerve of neck.**

2. **Deep fascia** and the **suprasternal space** with its contents (p. 291).

3. Hyoid bone, thyroid cartilage, cricoid cartilage, rings of trachea.

4. **Submental Triangle.**—Base is the hyoid bone, and each side is the anterior belly of digastric. **Floor** or upper boundary is the mylo-hyoid raphe and medial part of both mylo-hyoids. Submental lymph-glands are in the superficial fascia or between it and the deep fascia on mylo-hyoids.

5. Deep to Mylo-Hyoid—*i.e.* above it—**Suprahyoid branch** of lingual artery anastomosing with its fellow just above hyoid bone. **Genio-hyoid muscle** passing from mandible to hyoid bone alongside median plane just above mylo-hyoid. **Genio-glossus muscle**, radiating from mandible into the tongue, above genio-hyoid.

6. The medial edges of **thyro-hyoid, sterno-thyroid** and **sterno-hyoid** of the two sides, bounding a median elliptical space in which the remaining structures are found.

7. **Median thyro-hyoid lig.** passes from the upper border of the thyroid cartilage upwards behind the body of hyoid bone to its *upper* border. **Hyoid bursa** between the lig. and the back of the bone. **Infrahyoid branch** of superior thyroid artery anastomosing with its fellow on the lig. just below hyoid bone. A *pad of fat* separates the back of the lig. from **epiglottis.**

8. **Crico-thyroid lig.** stretches up from the arch of cricoid cartilage to thyroid cartilage, with **crico-thyroid branch** of superior thyroid artery anastomosing with its fellow on the surface of the lig., and **crico-thyroid muscle** on each side of it. The back of the lig. is covered with **mucous membrane** of larynx. Crico-thyroid interval and lig. are very small in children.

9. **Isthmus of thyroid gland** on 2nd, 3rd and 4th rings of trachea, with anastomosing branches of thyroid arteries (and veins) on its surface. A little nipple on the left half of its upper border is the **pyramidal lobe** of thyroid, and *levator glandulæ thyreoideæ* (when present) runs down to it from the hyoid bone.

10. **Pretracheal fascia** covers trachea and ensheaths the isthmus. **Inferior thyroid veins,** from isthmus and lower parts of the lobes of thyroid gland, pierce the fascia and run downwards in front of the trachea to the innominate veins in the thorax.

11. Upper part of remains of **thymus** in front of pretracheal fascia below the isthmus.

12. In some bodies, the **innominate artery** and, in front of it, the **left innominate vein** may both be high enough up to be seen in the root of the neck between trachea and thymus.

Anterior Triangle of Neck

Bounded by sterno-mastoid, lower border of mandible and median plane.

Divided into 4 triangles—half of submental triangle and the digastric, carotid and muscular triangles.

Digastric Triangle. Bounded by lower border of mandible and the bellies of digastric, the posterior belly being aided by stylo-hyoid. **Floor :** mylo-hyoid in front and hyo-glossus behind.

Contents.– 1. **Submandibular salivary gland** almost fills it and overlaps digastric.

2. **Anterior facial vein** pierces the deep fascia at the lower border of mandible, slants backwards across the posterior part of the gland and unites with the anterior branch of posterior facial vein to form the common facial, which ends in internal jugular.

3. Four or five **submandibular lymph-glands** lie in a row between the salivary gland and lower border of mandible. They receive lymph from various parts :—(*a*) walls of anterior part of cavity of nose ; (*b*) palate ; (*c*) gums and teeth except lower incisors ; (*d*) floor

of mouth, except its anterior part; (*e*) anterior part of tongue, except its tip; (*f*) sublingual and submandibular salivary glands; (*g*) side and front of face below the level of root of nose, except median part of lower lip and chin. They send their efferents to deep glands alongside carotid sheath.

4. **Facial artery** appears in front of anterior facial vein, between the salivary gland and lower border of mandible and between two of the lymph-glands. Bending upwards, it pierces the deep fascia to enter the face. Before it does so, it gives off the **submental artery,** which runs forwards under cover of the gland to accompany the mylo-hyoid nerve.

5. **Mylo-hyoid nerve** passes from mylo-hyoid groove of mandible on to the surface of mylo-hyoid muscle under cover of the gland and runs forwards branching to supply mylo-hyoid and anterior belly of digastric.

6. **Tendon of digastric** and its pulley lie on hyo-glossus just above hyoid bone.

7. A little higher, the **hypoglossal nerve** runs forwards over hyo-glossus under cover of the submandibular salivary gland. A small vein from the tongue may lie above it, but the **chief vein from the tongue** runs backwards below it.

Muscular Triangle.—**Bounded** by sterno-mastoid, superior belly of omo-hyoid and the median plane. Besides small vessels and areolar tissue, its only contents are the sterno-hyoid, sterno-thyroid and thyro-hyoid; and they may be regarded as its **floor.**

Carotid Triangle.—**Bounded** by sterno-mastoid, superior belly of omo-hyoid, and posterior belly of digastric (with stylo-hyoid).

Floor: *Anteriorly,* parts of thyro-hyoideus, hyoid bone and hyo-glossus. *Posteriorly,* middle and inferior constrictors and the thyro-hyoid membrane in the gap between them.

Contents (after sterno-mastoid has been pulled back).—

1. **Internal jugular vein,** descending vertically—the largest and most lateral of the contents of the carotid triangle. While in the triangle, it communicates with external jugular, and it receives pharyngeal, common facial and lingual veins.

2. **Common carotid artery,** in the lower part of the triangle, along the medial side of internal jugular, between it and the pharynx. Ends at the level of the upper border of thyroid cartilage by dividing into external and internal carotid.

3. **Internal carotid** ascends over the constrictors, in line with common carotid, along the medial side of the internal jugular vein.

4. **Vagus nerve,** between the posterior parts of the vein and the carotids, accompanied by its own superior cardiac branch and the superior cardiac branch of the sympathetic trunk.

5. **Carotid sheath** of fascia, around these vessels and the vagus.

6. **Sympathetic trunk,** imbedded in the wall of the sheath behind the carotid arteries.

7. Chains of **lymph-glands** on the sheath and at its sides, especially the lateral side. They drain lymph from all parts of head and upper

part of neck partly directly and partly through glands higher up ; and they pass it on to glands in the root of the neck whose efferents give rise to the **jugular lymph-trunk** (p. 456).

8. **Accessory nerve,** accompanied by a branch of occipital artery and surrounded by lymph-glands, runs downwards and backwards across internal jugular in the upper corner of the triangle.

9. **Carotid body** is in the angle between the roots of internal and external carotid.

10. **External carotid artery** ascends over the side of the pharynx antero-medial to internal carotid. Gives off five of its eight branches in the triangle—ascending pharyngeal, superior thyroid, lingual, facial and occipital.

11. **Ascending pharyngeal,** a small artery, arises from external carotid near its root and runs upwards between internal carotid and pharynx.

12. Two or three **pharyngeal veins** from the plexus on the side of the pharynx cross behind internal carotid to end in internal jugular.

13. **Superior thyroid artery** also arises near the root of the external carotid. Curves downwards and forwards in the fat on the side of the pharynx and disappears under omo-hyoid.

Gives off three branches in the triangle :—(*a*) **Infrahyoid artery** passes over thyro-hyoid membrane to the hyoid bone and runs along its lower border under thyro-hyoideus. (*b*) **Superior laryngeal artery** passes on to the membrane and pierces it under the posterior border of thyro-hyoideus. (*c*) **Sterno-mastoid artery** runs along the upper border of omo-hyoid across the common carotid to sink into sterno-mastoid.

14. **Superior thyroid vein** emerges from under sterno-thyroid and omo-hyoid and either runs with the sterno-mastoid artery to the internal jugular or ascends alongside its own artery to end in the common facial.

15. **Lingual artery** arises behind the tip of greater horn of hyoid, runs forwards over the middle constrictor and disappears under hyo-glossus. Just above the tip, it makes a bend convex upwards ; and, before it disappears, it sends the **suprahyoid artery** forwards along the upper border of hyoid bone superficial to hyo-glossus.

16. **Lingual vein** is formed at the posterior border of hyo glossus by the union of the companion veins of lingual artery and of hypoglossal nerve. Runs backwards across external and internal carotids and ends either in internal jugular or in common facial.

17. **Facial artery** arises immediately above the lingual and disappears almost at once by passing upwards under the posterior belly of digastric.

18. **Common facial vein** begins in carotid triangle near digastric, below the angle of mandible, by the union of anterior facial and anterior division of posterior facial. Very variable in size and direction. May pass backwards at once across the hypoglossal nerve, the root of the lingual artery and the two carotids to join internal jugular, or may descend some distance superficial to the carotids and join internal jugular in the lower part of the triangle. Usually sends a communication down to anterior jugular beneath

sterno-mastoid, and that branch may carry away most of its blood.

19. **Occipital artery** arises from the back of external carotid opposite the facial or a little higher. Runs backwards and upwards along the lower border of the posterior belly or under cover of it—crossing internal carotid, hypoglossal nerve, internal jugular and accessory nerve—and disappears under the mastoid process at the upper corner of the carotid triangle.

Gives off: (*a*) a **sterno-mastoid artery** as it crosses hypoglossal nerve; and, as it crosses internal jugular, *another* **sterno-mastoid artery** of more importance because it accompanies the accessory nerve and is a guide to the nerve; and (*b*) a **meningeal artery,** which runs up along the internal jugular vein to reach dura mater through the jugular foramen.

20. **Superior laryngeal nerve** arises from vagus near the base of the skull, descends over the side of the pharynx hidden under the carotid arteries. It divides into external and internal laryngeal at a variable point which may be above the level of the carotid triangle.

21. **Internal laryngeal nerve** runs downwards and forwards over the side of the pharynx, emerges from under cover of the two carotid arteries near the tip of the hyoid bone, passes on to thyro-hyoid membrane and joins superior laryngeal artery.

22. **External laryngeal nerve,** much more slender, emerges a little lower, and descends obliquely in the fat on the side of the pharynx, deep to superior thyroid artery, and disappears under omo-hyoid with that artery.

23. **Hypoglossal nerve** appears at the lower border of posterior belly of digastric between internal carotid and internal jugular. Curves forwards close to the posterior belly across both carotids and the bend of lingual artery, and disappears under posterior belly again to enter digastric triangle.

Gives off: (*a*), as it enters the triangle, the **descendens hypoglossi,** which runs downwards over internal and common carotids to end in the ansa hypoglossi below the triangle; and (*b*), as it crosses lingual artery, the **nerve to thyro-hyoid,** which runs downwards and forwards to that muscle.

24. **Descendens cervicalis** arises behind internal jugular from the anterior primary rami of c. 2 and 3. The two roots run forwards and downwards over the lateral side of internal jugular (sometimes medial side) and unite into one stem which descends over internal jugular to the lower angle of the triangle and then passes on to common carotid to end in the ansa.

[The nerve to thyro-hyoid and the descendens hypoglossi are made of fibres that come into the hypoglossal from the anterior ramus of the first cervical. Descendens cervicalis springs from 2nd and 3rd cervical. **Ansa hypoglossi** is a loop (*ansa* = a loop) formed by the descendens nerves and is therefore made of fibres from c. 1, 2, 3. It lies on the common carotid at the level of cricoid cartilage; and its branches supply sterno-thyroid, sterno-hyoid and both bellies of omo-hyoid.]

PAROTID AND MASSETERIC REGION

The posterior part of the lower part of the face, in front of auricle below zygomatic arch and below auricle as far as the angle of mandible and even lower.

Landmarks to be Identified.—Sterno-mastoid. Posterior belly of digastric. Mastoid process, external auditory meatus, zygomatic arch. Mandible—head, neck, coronoid process, ramus and angle.

Superficial Fascia.—Is part of the superficial fascia of the face. Contains: 1. Small unnamed blood-vessels.

2. Cutaneous nerves—facial branch of great auricular over the lower half of the region, and branches that come through the parotid gland from auriculo-temporal over the upper half.

Deep Fascia.—Extends up from the neck to ensheath the parotid gland. The part on the superficial surface of the gland is thick and spreads forwards over the masseter; it is attached superiorly to the zygomatic arch, and posteriorly to the external auditory meatus. The deeper part is thinner and is attached superiorly to the tympanic plate. It adheres also to the styloid process and the posterior border of mandible, and the part between those two bones is thickened to form the **stylo-mandibular lig.**, which separates the lower part of the parotid gland from the submandibular gland and the medial pterygoid muscle.

Muscles.—Upper fibres of platysma (p. 265); origin of risorius (p. 264); masseter.

Masseter lies on ramus of mandible; easily felt when jaws are clenched.

Origin (fl.-tend.): lower border and deep surface of zygomatic arch.

Insertion (fl.-tend.): lateral surface of ramus and coronoid process of mandible.

Nerve: mandibular, through masseteric branch.

Raises mandible; superficial fibres also protrude, and deep fibres retract after protrusion.

Transverse facial vessels, parotid duct, branches of facial nerve lie on its lateral surface. Parotid gland overlaps it posteriorly. Facial artery can be felt beating on mandible at its anterior border; and anterior facial vein is behind the artery. Note that it does not cover head and neck of mandible, and that its upper part reaches farther forward than the ramus—overlapping the buccal pad of fat and buccinator.

Parotid Gland and Duct

Parotid Gland.—Largest of the salivary glands. About the size of a hen's egg, but very uneven in order to fit into the hollow below

the external ear behind the mandible. Superficially, it extends upwards to the zygomatic arch immediately in front of the auricle, downwards over the posterior belly of digastric beyond the angle of mandible to overlap carotid triangle, backwards to overlap sterno-mastoid, and forwards to overlap masseter. The upper part of the masseteric overlap may be isolated and is then called the **accessory parotid gland.**

Two ends—upper and lower. Three surfaces—lateral, antero-medial and postero-medial.

Upper end—really a concave surface—grasps the lower surface of external auditory meatus (cartilaginous part of meatus and lateral part of bony part), and its anterior margin is wedged between the meatus and the mandibular joint. Temporal branches of facial nerve, posterior facial vein, superficial temporal artery and auriculo-temporal nerve are all found in the superficial fascia just above the upper end.

Lower end, wedged between sterno-mastoid and angle of mandible, overlaps carotid sheath. Cervical branch of facial nerve and the two divisions of posterior facial vein emerge through it.

Lateral surface, nearly flat, has some lymph-glands imbedded in it, and is related to fasciæ and structures in the superficial fascia.

Antero-medial surface, concave, clasps the posterior parts of masseter and medial pterygoid and the ramus of mandible sandwiched between the muscles. Its lower part is separated by the stylo-mandibular lig. from the submandibular gland and medial pterygoid muscle. Posterior facial vein enters the upper part, and external carotid emerges through it—or, if the carotid ends within the gland, its terminal branches (maxillary and superficial temporal) emerge.

Anterior border, between the lateral and antero-medial surfaces, lies on masseter. Several structures escape from the gland at this border :—parotid duct ; the transverse facial vessels and the zygomatic branches of facial nerve above the duct ; the buccal and mandibular branches of facial nerve below the duct.

Postero-medial surface is very uneven. Related to mastoid process and sterno-mastoid ; more deeply, to posterior belly, stylo-hyoid and posterior auricular artery ; more deeply still—near the side of the pharynx—to styloid process, stylo-pharyngeus, carotid sheath and the last four cranial nerves. External carotid enters the gland through the lower part of this surface between the digastric and styloid impressions, and the facial nerve enters between these impressions higher up.

Structures within Parotid Gland.—1. Small lymph-glands.
2. External carotid artery.
3. Posterior facial vein, superficial to the artery.
4. Facial nerve and its terminal branches.

5. Communications to facial nerve from great auricular and auriculo-temporal.

The artery and vein are really in a deep groove, but, since the walls of the groove are pressed together, the vessels are, in effect, within the gland. Examine these structures further:—

External carotid artery ascends from under cover of digastric and stylo-hyoid and comes into relation with the postero-medial surface of parotid; gives off the posterior auricular artery, and enters the gland; passes through the gland, from postero-medial surface to antero-medial surface, to reach the back of the neck of mandible, where it divides into maxillary and superficial temporal; but it may be still within the gland at that point, and then its terminal branches emerge from the gland behind the neck of the mandible.

Posterior auricular artery runs upwards and backwards, deep to parotid, along the upper border of the posterior belly of digastric.

Maxillary artery passes forwards under cover of mandible, dragging a process of the gland with it.

Superficial temporal gives off transverse facial and appears at upper end of parotid, in front of auricle. *Transverse facial artery* appears at the anterior border of the gland above the duct.

Posterior facial vein descends over zygoma in front of the superficial temporal artery; slips under cover of parotid; receives transverse facial and maxillary veins; descends through parotid, superficial to external carotid; splits into two divisions which end in the common facial and external jugular veins.

Auriculo-temporal nerve runs laterally, behind mandibular joint, above parotid, and appears in front of the auricle behind the superficial temporal artery.

Facial Nerve.—7th cranial nerve. Emerges at the lower border of pons, pierces pia mater, passes with the auditory nerve into the internal auditory meatus, pierces arachnoid and dura mater, and enters the temporal bone through a foramen at the bottom or lateral end of the meatus.

In the temporal bone, it runs its course in a canal—first in a lateral direction above the vestibule of internal ear, next backwards in the upper part of the medial wall of the middle ear, and then downwards behind the middle ear to emerge from the skull at the stylo-mastoid foramen opposite the lower part of the external auditory meatus.

Immediately after its escape from the skull it gives off:—(*a*) the *posterior auricular nerve* (p. 261), and (*b*) a branch that divides to supply the *stylo-hyoid* and *posterior belly of digastric*. The facial nerve then curves forwards round the lateral side of internal jugular vein and styloid process and enters the parotid on its postero-medial surface between impressions for styloid and digastric.

In the gland, it breaks up into branches which are joined by branches from auriculo-temporal and great auricular, and radiate towards the ends and anterior border of the gland—usually passing superficial to the posterior facial vein, but some of the branches may pass between the vein and the external carotid. *Temporal* branches appear at the upper end of parotid gland; *zygomatic, buccal* and

mandibular branches appear at the anterior border *cervical* branch emerges at the lower end.

Vessels and Nerves of Parotid Gland.—**Lymph-vessels** pass to lymph-glands inside it and on its surface, and thence to glands alongside external and internal jugular veins.

Nerves: *sensory*, from great auricular and auriculo-temporal; *secretory*, 9th cranial (*via* tympanic branch—tympanic plexus—lesser superficial petrosal—otic ganglion—communicating branch to auriculo-temporal); *vasomotor*, from sympathetic plexus around external carotid.

Arteries and **veins** from and to neighbouring vessels.

Parotid Duct.—Formed by the union of the ducts of the gland-lobules. Appears at the anterior border of the gland at the level of the lobule of the auricle. Runs forwards over the anterior part of masseter between the zygomatic and buccal branches of facial nerve, below the accessory parotid. Bends sharply round the anterior border of masseter and pierces the buccal pad of fat, bucco-pharyngeal fascia, buccinator and the mucous membrane to open into the vestibule of the mouth opposite the second upper molar tooth. As it pierces the bucco-pharyngeal fascia, the molar mucous glands (p. 268) surround it.

TEMPORAL AND INFRATEMPORAL REGIONS

Study the skull carefully before attempting to revise these regions.

Landmarks to be Identified in the Living Body.—Temporal line; zygomatic process of frontal bone; frontal process of zygomatic bone; zygomatic arch; tubercle of root of zygoma. Ramus of mandible and its processes; angle of mandible; masseter. Supra-mastoid crest.

Superficial Fascia.—Below zygomatic arch—*see* p. 299.

In temporal region it contains:—1. A variable quantity of loose *fat*.

2. In its deeper part, a membranous sheet that extends down from the epicranial aponeurosis to the zygomatic arch and has auricular muscles imbedded in it—**auricularis superior** above the auricle and **auricularis anterior** in front of it.

3. Lateral bundles of **orbicularis oculi,** in the anterior part.

4. **Zygomatico-temporal nerve,** in the anterior part.

5. **Temporal branches of facial nerve,** in the lower and anterior part.

6. **Auriculo-temporal nerve,** in front of the auricle and branching upwards.

7. Filaments of **lesser occipital nerve** reach the posterior part above the auricle.

8. **Superficial temporal artery,** in front of the auricle and sending

its terminal branches towards the frontal and parietal eminences (p. 261).

9. **Superficial temporal veins** accompany the branches of the artery and unite with **middle temporal vein** (from the substance of temporalis) an inch above zygoma to form **posterior facial vein,** which descends along superficial temporal artery in front of the auricle.

10. Small **zygomatico-temporal vessels** (from the lacrimal) accompany the nerve.

11. **Lymph-vessels** descend from the anterior part of the temporal region to glands on the parotid, and from the posterior part to glands on the insertion of sterno-mastoid.

Deep Fascia.—Below zygomatic arch :—(1) Parotid fascia (p. 299). (2) Under cover of the ramus of mandible, fascia ensheaths the pterygoid muscles and the vessels and nerves, and covers tensor palati.

In the temporal region, it is the **temporal fascia.** Dense, strong and glistening. Covers the temporal muscle and give origin to its superficial fibres. Attached to the margins of the temporal fossa. The part immediately above zygomatic arch is split into two layers which enclose fat and the zygomatic branch of superficial temporal artery with its companion vein. First layer is attached to the upper edge of zygomatic arch; deeper layer slips down to line the deep surface of the uppermost part of masseter.

Muscles.—Temporal; lateral and medial pterygoid; tensor palati. (Temporalis, pterygoidei and masseter are the 4 "muscles of mastication"—all supplied by branches of the mandibular division of trigeminal nerve.)

Temporalis.—**Origin** (fl.) : floor of temporal fossa; temporal fascia.

Insertion (tend.-fl.) : borders and medial surface of coronoid process; anterior border of ramus of mandible.

Nerves : deep temporal branches of mandibular.

Raises mandible; posterior fibres retract after protrusion.

The **anterior and posterior deep temporal nerves,** clinging to the bone, come from the infratemporal fossa into the lower, anterior part of temporal fossa and sink into the deep surface of the muscle.

Middle temporal artery arises from superficial temporal below the zygoma, climbs up over the root of zygoma in front of the auricle and at once pierces temporal fascia and slips under or pierces the lowest part of temporalis to ascend in a groove on the floor of temporal fossa above the external meatus.

The lower part of the temporal muscle is under cover of the zygomatic arch and masseter. The buccal branch of mandibular nerve often pierces it.

Lateral Pterygoid.—In upper part of infratemporal fossa.

Origin.—*Upper head* (fl.-tend.) : infratemporal crest and infratemporal surface of greater wing of sphenoid. *Lower head* : lateral surface of lateral pterygoid plate.

Insertion (tend.-fl.) : front of neck of mandible and of capsule of mandibular joint.

Nerve : a pterygoid branch of mandibular.

Protrudes mandible and pulls it towards opposite side ; the right and left muscles act alternately in chewing.

Superficial to it are masseter, ramus and coronoid process of mandible, tendon of temporalis, maxillary artery, and superficial head of pterygoideus medialis.

Deep to it are deep head of medial pterygoid, mandibular nerve and its branches, middle meningeal artery, spheno-mandibular ligament, and, often, maxillary artery.

Masseteric and deep temporal nerves appear at its upper border, and the lingual and inferior dental nerves at its lower border. Buccal nerve and maxillary artery pass between its two heads.

It is surrounded by the pterygoid plexus of veins.

Medial Pterygoid.—In anterior part of infratemporal fossa.

Origin.—*Superficial head* (tend.) : Small. Chiefly from maxillary tuberosity. *Deep head* (fl.-tend.): Large. Chiefly from medial surface of lateral pterygoid plate.

Insertion (fl.-tend.) : Medial surface of angle and ramus of mandible behind the mylo-hyoid groove.

Nerve : a pterygoid branch of mandibular.

Elevates mandible ; protrudes and pulls it to opposite side—aiding the lateral pterygoid in chewing.

Superficial to it are ramus of mandible, pterygoideus lateralis, lingual and inferior dental nerves, maxillary and inferior dental vessels, spheno-mandibular ligament.

Deep to it are tensor and levator palati, superior constrictor ; stylo-glossus, stylo-pharyngeus, tonsillar and ascending palatine branches of facial artery, and the loop of that artery itself ; sub-mandibular gland ; stylo-hyoid and posterior belly of digastric at the angle of mandible.

Tensor Palati.—Really a muscle of the pharynx and palate—lying in the side-wall of the uppermost part of pharynx ; but it is also part of the medial wall of infratemporal fossa.

Small, thin, flat ; triangular in outline. **Arises,** by its base, from spine of sphenoid, lateral surface of pharyngo-tympanic tube and floor of scaphoid fossa.

Fibres converge on the lower end of the medial pterygoid plate and become a slender tendon. Tendon bends at a right angle, passes medially in a groove on the lower surface of the root of the pterygoid hamulus into the soft palate, where it spreads out to be **inserted** into the palatine aponeurosis and palatine crest.

Nerve : mandibular, by fibres that pass through the otic ganglion.

The *lateral surface* of the muscle is covered by the medial pterygoid, mandibular nerve, otic ganglion and middle meningeal vessels.

Its *medial surface* is related to the pharyngo-tympanic tube, to the uppermost origin of superior constrictor and to the pharyngobasilar fascia, where that fascia fills the gap between the skull and the upper edge of the constrictor.

A *bursa* eases the friction between its tendon and the hamulus.

Infratemporal Fossa

Boundaries.—*Lateral* : Ramus and coronoid process of mandible, covered by masseter and receiving the insertion of temporalis.

Anterior : The back of the maxilla, with dental foramina in its surface, and ending inferiorly as the maxillary tuberosity.

Posterior : Tympanic plate and styloid process.

Superior (roof) : Infratemporal surface of greater wing of sphenoid and infratemporal surface of squamous temporal.

Medial : Pterygoid process; tubercle of palatine bone wedged between its lower part and maxilla ; and, behind the pterygoid process, muscles of upper part of side of pharynx—tensor palati, levator palati (p. 617) behind the tensor, and superior constrictor below them.

Communications.—*With temporal fossa*, through the wide gap bounded by zygomatic arch ; *with orbit*, through inferior orbital fissure ; *with pterygo-palatine fossa*, through pterygo-maxillary fissure ; *with cranial cavity*, through foramen ovale and foramen spinosum in the greater wing of sphenoid.

Contents.—1. Fat and the pterygoid muscles.
2. Spheno-mandibular ligament.
3. Maxillary artery and its branches.
4. Pterygoid plexus of veins.
5. Mandibular nerve and its branches.
6. Otic ganglion and its roots and branches.
7. Chorda tympani nerve.
8. A small part of maxillary nerve and two of its branches—zygomatic and posterior superior dental.
9. The mandibular joint may be included.

The fossa is exposed by the removal of :—(1) superficial structures ; (2) parotid gland, masseter and zygomatic arch ; (3) ramus and coronoid process of mandible and the lower part of temporalis.

When that has been done, little is seen but fat and the mandibular joint. When the fat and fascia are removed, we see :

(*a*) The *lateral pterygoid* (p. 304), in the upper part of the space.

(*b*) The lower part of *medial pterygoid* (p. 304) and the lower part of the *spheno-mandibular lig.*, below the lateral pterygoid.

(*c*) The *vessels* and *nerves* related to these muscles.

(*d*) A part of *superior constrictor*, deeply, behind the medial pterygoid.

(*e*) The *maxillary nerve*, in the upper anterior part of the space.

Spheno-Mandibular Lig. — A thin ribbon. Extends from spine of sphenoid to the lower margin of mandibular foramen. At first hidden on the medial side of the lateral pterygoid, it appears at the lower border of that muscle and passes on to the lateral surface of the medial pterygoid. (*See also* p. 125.)

Maxillary Artery.—One of the two terminal branches of external carotid. Begins behind the neck of the mandible either in the parotid gland or between the gland and the bone.

First part passes forwards (accompanied by the vein or veins) across the medial side of neck of mandible, first in the fat on the side of the pharynx and then on spheno-mandibular ligament and inferior dental nerve ; and reaches the lower border of the lateral pterygoid.

Second part passes forwards and upwards over the lower head of lateral pterygoid across the medial side of temporalis tendon and coronoid process.

Third part turns medially between the two heads of lateral pterygoid and passes through the pterygo-maxillary fissure into the pterygo-palatine fossa, to end there in numerous branches.

[Second part sometimes passes deep to the lower head of lateral pterygoid across the lingual nerve and deep head of medial pterygoid, and re-appears between the heads of lateral pterygoid before it becomes the third part and passes through the fissure.]

Branches.—Very numerous—*see* p. 426. The most important branches are the middle meningeal and inferior dental.

Middle Meningeal Artery.—Arises from the first part at the lower border of the lateral pterygoid and ascends through the fat on the side of the pharynx to the foramen spinosum, through which it enters the skull (*see* p. 55). It is medial to the lateral pterygoid ; lateral at first to the spheno-mandibular lig. and then to tensor palati, which separates it from the pharyngo-tympanic tube ; and it is postero-lateral to the mandibular nerve. The two roots of the auriculo-temporal nerve embrace it as they pass backwards.

Inferior Dental Artery.—Supplies the teeth and gums of the lower jaw. It also arises from the first part of maxillary at the lower border of lateral pterygoid. Runs down between the ramus of mandible and spheno-mandibular lig., behind the inferior dental nerve and enters the mandibular foramen with the nerve. (*See also* p. 427.)

Pterygoid Plexus of Veins.—A network around the lateral pterygoid muscle formed by the veins that correspond to the branches of the maxillary artery.

It communicates :—1. With cavernous sinus by emissary veins

that pass through foramen ovale or through the sphenoidal emissary foramen when it is present.

2. With the pharyngeal plexus.

3. With the inferior ophthalmic vein through the inferior orbital fissure.

4. With the anterior facial vein by the *deep facial vein*, which passes backwards to the plexus through the fat that separates buccinator from masseter and ramus of mandible.

Maxillary Vein.—Short and wide. Drains the blood from the plexus. Arises from the plexus at the lower border of lateral pterygoid, passes backwards alongside the first part of the artery, and ends in the posterior facial vein. Sometimes there are two maxillary veins alongside the artery.

Mandibular Nerve.—The third and thickest division of trigeminal. Arises in the middle cranial fossa from the trigeminal ganglion, descends at once through foramen ovale into infratemporal fossa, is joined in the foramen by the motor root of trigeminal, and divides into an anterior and a posterior division about a quarter of an inch below the foramen.

The nerve and its divisions are hidden in the fat and fibrous tissue at the medial side of the lateral pterygoid ; the branches begin, therefore, under cover of the muscle, but most of them escape from it.

The **undivided trunk** is medial to the lateral pterygoid, behind the medial pterygoid, in front of the middle meningeal vessels and close to the lateral side of tensor palati, which separates it from the pharyngo-tympanic tube. Gives off nervus spinosus and the branch to the medial pterygoid.

The **anterior division** contains nearly all the motor fibres. Breaks up almost at once into :—two deep temporal nerves ; nerve to masseter ; nerve to lateral pterygoid ; and the buccal nerve, which carries away all the sensory fibres of the anterior division.

The **posterior division** gives off the two roots of auriculo-temporal nerve and then divides into lingual and inferior dental. The only motor fibres of the posterior division are carried away by the mylohyoid branch of the inferior dental.

Nervus spinosus, a mere filament, passes through foramen spinosum to supply dura mater and send a branch to the mucous membrane of the middle ear.

Nerve to medial pterygoid arises from the medial side of the trunk and passes forwards into the upper part of the medial pterygoid. The *otic ganglion* is bound to it at its origin and receives a root from it.

Deep temporal nerves, *anterior* and *posterior*, pass laterally above the lateral pterygoid and then upwards to sink into the deep surface of temporalis. They cling to the bone—in the roof of infratemporal fossa, and across the infratemporal crest on to the floor of the temporal fossa.

Nerve to masseter crosses above the lateral pterygoid farther back ; passes through the mandibular notch between temporalis and the mandibular joint ; gives one or two branches to the capsule

of the joint; and then sinks into the upper part of masseter near its posterior border.

Nerve to lateral pterygoid accompanies the buccal nerve to the interval between the two heads of the muscle, and leaves it to enter the muscle.

Buccal Nerve.—The longest and thickest branch of the anterior division. Appears between the heads of lateral pterygoid. Runs downwards and forwards over the lower head and across the superficial head of the medial pterygoid on to buccinator near its lower border. It is under cover of masseter, coronoid process and either in the substance of temporalis or closely applied to its deep surface parallel to its fasciculi. Escapes from under masseter, communicates with buccal branches of the facial, sends branches through the fat and risorius to skin of the cheek, and branches through buccinator to the mucuous membrane of the cheek.

Note that it is a sensory nerve and *does not supply motor fibres to the buccinator*: that muscle is supplied by buccal branches of the facial; it is paralysed in facial palsy, and food then slips from between the teeth into the vestibule of the mouth.

In many bodies, a branch arises from the buccal between the heads of lateral pterygoid and runs up over the upper head into the temporal muscle. It may be an additional branch to temporalis or may replace the anterior deep temporal.

Auriculo-Temporal Nerve.—Arises from the posterior division of the mandibular nerve by two roots. They pass backwards, embracing the middle meningeal artery, and unite into a single stem which runs backwards under cover of the lateral pterygoid and between the neck of mandible and spheno-mandibular ligament. It then turns sidewards and upwards behind the mandibular joint under cover of the parotid gland; appears at the upper end of the gland; crosses the posterior root of zygoma between the superficial temporal artery and the root of the auricle; and enters the temple (p. 260).

Communications.—Its roots receive branches from the otic ganglion which convey secretory fibres of the glosso-pharyngeal nerve to the parotid gland. On the side of the head it communicates with other sensory nerves and with temporal branches of facial.

Branches.—1. To the back of the mandibular joint.

2. Thick branches enter parotid gland to supply it and the skin over its upper part, and to join branches of the facial nerve.

3. Branches to the upper part of lateral surface of the auricle, and branches which pass between the bone and cartilage of the front of the meatus to supply the skin that lines the upper part of the meatus and the upper part of the tympanic membrane.

4. Terminal branches to skin of the side of the head.

Inferior Dental Nerve.—The thickest branch of mandibular. Arises from the posterior division between lateral pterygoid and tensor palati. Passes from tensor on to medial pterygoid, appears at the lower border of the lateral pterygoid and runs downwards and slightly forwards over medial pterygoid and spheno-mandibular ligament under the ramus of mandible and disappears through the

mandibular foramen to traverse the mandibular canal in the substance of the ramus and body of the mandible. The inferior dental vessels descend behind it, and the lingual nerve in front of it.

Branches.—Mylo-hyoid; mental; and branches to the teeth and gums of lower jaw.

Mylo-hyoid nerve arises a little above the mandibular foramen, pierces the spheno-mandibular lig. in company with the mylo-hyoid branch of inferior dental artery and its companion vein. The nerve and vessels run in the mylo-hyoid groove of mandible held in place by a prolongation of spheno-mandibular lig. which bridges the groove and separates them from pterygoideus medialis. The vessels reach little or no farther than the groove, but the nerve passes on to the superficial surface of the mylo-hyoid muscle, where it is accompanied by submental vessels; and it branches to supply the mylo-hyoid and the anterior belly of digastric.

Mental nerve arises in the mandibular canal, emerges through the mental foramen with mental branches of inferior dental vessels, and supplies skin of chin and skin and mucous membrane of lower lip.

Lingual Nerve.—Almost as thick as the inferior dental nerve. Begins between the lateral pterygoid and tensor palati but passes at once on to the lateral surface of the medial pterygoid and runs downwards and forwards over it, in front of the inferior dental nerve, gradually crossing the muscle from its posterior to its anterior border, under cover of first the lateral pterygoid and next the ramus of mandible. From medial pterygoid, it passes on to the lowest part of superior constrictor close to its origin from the posterior end of mylo-hyoid line, and then, at once, on to stylo-glossus in the fat below the mucous membrane of the mouth opposite the root of the last lower molar tooth; and there it enters the submandibular region, which it traverses on its way to reach the mucous membrane of the anterior two-thirds of the tongue (p. 319). It conveys ordinary sensory fibres to the mucous membrane and also fibres of taste brought into it by chorda tympani.

Chorda Tympani.—A branch of the facial. Arises as the facial descends behind the middle ear. Traverses the middle ear or tympanic cavity (hence its name) from behind forwards, opposite the upper part of the tympanic membrane. Appears on the lower surface of the skull through the medial end of the squamo-tympanic fissure. Passes downwards and forwards in a groove on the medial side of the spine of the sphenoid, and onwards over the lateral surface of tensor palati, deep to the middle meningeal vessels, the roots of auriculo-temporal nerve and the inferior dental nerve; and it enters the lingual nerve an inch or less below the skull. It receives a branch from the otic ganglion.

Otic Ganglion.—A mere pin-head. Lies on the origin of the nerve to the medial pterygoid between mandibular nerve and tensor palati.

Roots.—*Motor*: from mandibular through the nerve to medial pterygoid. *Sympathetic*: from the plexus around middle meningeal

artery. *Secretory* (parasympathetic): from glosso-pharyngeal and possibly *sensory* from facial, both through lesser superficial petrosal.

Branches.—*Secretory* fibres to auriculo-temporal for parotid gland are the only fibres relayed in it. *Motor* fibres from mandibular pass through it to tensor palati and tensor tympani. *Communicating* branches connect it with chorda tympani and the nerve of pterygoid canal.

Mandibular Joint.—*See* p. 123.

Pterygo-Palatine Fossa.—*See* p. 37.

Maxillary Nerve and Maxillary Sinus

Maxillary Nerve.—The second division of trigeminal. Arises from the trigeminal ganglion. Runs forwards between the two layers of dura mater along the lower border of the cavernous venous sinus, separated only by the outer layer of dura and thin bone from the lining of the sphenoidal air-sinus; and leaves the middle cranial fossa through foramen rotundum. Enters the upper part of the pterygo-palatine fossa; bends laterally out of it through the pterygo-maxillary fissure into the upper anterior part of the infratemporal fossa. Leaves that fossa almost at once by passing forwards into the inferior orbital fissure, where it becomes the infra-orbital nerve.

Branches.—Meningeal, ganglionic, posterior superior dental, and zygomatic.

The **meningeal branch** is very small; it arises in the cranial cavity and supplies the dura mater near the trigeminal ganglion.

Two ganglionic branches arise in the pterygo-palatine fossa and descend at once into the spheno-palatine ganglion.

Posterior superior dental nerve arises in the infratemporal fossa. It divides into two branches which run down over the back of the maxilla, give branches to the mucous membrane of the upper part of the vestibule of the mouth, and perforate the maxilla to supply the molar and premolar teeth, and to give branches to the mucous lining of the maxillary sinus.

Zygomatic nerve also arises in the infratemporal fossa. It enters the orbit through the lateral end of inferior orbital fissure, pierces the periosteum, runs forwards between it and the bone of the side-wall of orbit, and enters the substance of the zygomatic bone through the zygomatic foramen. In the bone, it divides into two branches which escape through foramina that bear their names—*zygomatico-facial* through the front of zygomatic bone to supply skin of the bony part of the cheek; *zygomatico-temporal* through its temporal surface to supply skin of the anterior part of the temple. The zygomatic nerve may divide in the orbit; its two terminal branches then enter the bone separately.

The zygomatic nerve sends a filament to join the lacrimal nerve. This contains secretory fibres for the lacrimal gland. These fibres were relayed in the spheno-palatine ganglion from the greater super-

ficial petrosal, ascended from the ganglion by a ganglionic branch to the maxillary nerve, and thence into zygomatic.

The zygomatic and infra-orbital nerves are included among the contents of the orbit, and they differ from the other contents in that they are outside the periosteum that lines the orbit.

Infra-orbital Nerve.—The continuation of maxillary. Begins at the middle of the inferior orbital fissure, runs straight forwards in the infra-orbital groove and canal and emerges through the infra-orbital foramen into the face, where it ends by dividing into palpebral, nasal and labial branches (p. 266).

In the groove and canal, it is in the floor of the orbit and, at the same time, in the roof of the maxillary sinus ; it is accompanied by the infra-orbital branch of the third part of the maxillary artery and the companion vein ; and it gives off the anterior superior dental nerve.

Anterior superior dental nerve supplies the incisor and canine teeth, and on its way to them it gives branches to the mucous membrane of the maxillary sinus and antero-inferior part of the cavity of the nose. Its course is in a sinuous canal, first forwards in the roof of maxillary sinus, then downwards and medially in the anterior wall of the sinus, then downwards towards the teeth, and medially towards the front of the floor of the nose.

Spheno-Palatine Ganglion.—Lies below the maxillary nerve, in the upper part of pterygo-palatine fossa, opposite the spheno-palatine foramen, surrounded by fat and by the branches of the third part of the maxillary artery (and their companion veins) which accompany the pharyngeal, palatine and spheno-palatine branches of the ganglion. The ganglion is suspended from the maxillary nerve by the ganglionic branches. But only a few fibres of these branches enter the ganglion; most of them pass over it into the palatine and spheno-palatine branches of the ganglion.

The ganglion has *roots* and *branches*.

Roots.—Sensory : *ganglionic branches* of maxillary.

Secretory : *greater superficial petrosal* branch of facial.

Sympathetic : *deep petrosal branch* from internal carotid plexus.

The petrosal nerves unite in foramen lacerum to form the *nerve of pterygoid canal*, which runs forwards through that canal and joins the ganglion.

The only fibres relayed in the ganglion are the secretory fibres for the lacrimal gland brought by the greater superficial petrosal. The other fibres of the roots pass without interruption through the ganglion into its branches.

Branches.—**Orbital,** 2 or 3 slender filaments, pass through inferior orbital fissure to supply periosteum of orbit and lacrimal gland.

Short spheno-palatine pass through spheno-palatine foramen to the mucous membrane of the upper and posterior part of the nasal cavity, chiefly on the lateral wall.

Long spheno-palatine passes through spheno-palatine foramen, crosses the roof of the nasal cavity, descends along the septum to the palate, enters the roof of the mouth through a median incisive

foramen; supplies mucous membrane of nose, gums and hard palate.

Greater palatine descends through greater palatine canal, giving off *nasal* branches to the lower and posterior part of nose; ends by supplying soft and hard palate and gums. *Lesser palatine* spring from greater palatine and descend through the lesser canals and supply soft palate, uvula and tonsil; the medial one passes above the tendon of the tensor palati to enter the palate.

Pharyngeal passes backwards through the palatino-vaginal canal to the mucous membrane of roof of nose and pharynx.

Maxillary Sinus.—Largest of the air-sinuses, and the first to appear. Though a mere groove on medial side of maxilla at birth, yet it had begun to appear in 4th month of intra-uterine life.

In the adult, it occupies the whole body of maxilla.

Relations.—Is *below* orbit; *lateral to* lower half of nasal cavity; *in front of* pterygo-palatine and infratemporal fossæ; *above* molar and premolar teeth.

Deepest part of the floor is opposite the first molar and the second premolar; and is nearly half an inch below the level of the floor of the nose. Infra-orbital nerve and vessels lie in its roof; their branches to incisor and canine teeth descend in its antero-lateral wall. Nerves and vessels to premolar and molar teeth run in the lower part of its posterior and lateral walls.

Opening is in the **uppermost** part of the medial wall, and it leads into lower or posterior part of hiatus semilunaris of middle meatus.

SUBMANDIBULAR REGION

The region under cover of the body of mandible and between it and hyoid bone. Its lower part includes the structures in the submental and digastric triangles (pp. 294, 295); and it contains the structures related to the mylo-hyoid and hyo-glossus muscles.

Landmarks.—Hyoid bone. Symphysis menti; body and angle of mandible. Mastoid process.

Superficial Fascia.—Contains:—

1. *Fat* (sometimes in great quantity).
2. The beginning of *anterior jugular vein* (p. 291).
3. Filaments from the *anterior cutaneous nerve of the neck* (p. 275).
4. *Platysma* (p. 265).
5. *Cervical branch of facial nerve* (p. 265).
6. *Submental lymph-glands* (p. 291).
7. *Lymph-vessels* (p. 291).

Deep Fascia.—Extends from hyoid bone to mandible. At the submental triangle, it is in one layer, which covers the mylo-hyoid in the floor of the triangle. Lateral to that, it splits to enclose the

digastric muscle and submandibular gland. The first layer passes over them to be attached to the lower border of mandible. The second layer clothes their deep surface and also covers the mylo-hyoid and hyo-glossus muscles, and is attached to the mylo-hyoid line of mandible. Two surfaces of the submandibular gland are thus covered with fascia, but the surface related to the mandible—the lateral surface—is bare. Immediately above the hyoid bone, a part of the fascia is thickened and modified to form a fascial pulley which binds the tendon of digastric to the hyoid bone and through which the tendon can glide backwards and forwards.

Muscles.—Digastric ; stylo-hyoid ; mylo-hyoid ; genio-hyoid ; genio-glossus ; hyo-glossus ; stylo-glossus.

Digastricus.—Has an anterior belly and a posterior belly united end to end by a tendon.

Tendon lies on hyo-glossus just above hyoid bone, to which it is bound by a sling of deep fascia.

Anterior belly lies on the lower surface of mylo-hyoid, below the chin, and can be felt through the skin and fasciæ. **Arises** by fleshy fibres from the lower border of mandible close to the symphysis and is **inserted** into the common tendon.

Nerve : mylo-hyoid, from inferior dental branch of mandibular.

Posterior belly stretches from the mastoid process towards the hyoid bone and is overlapped by the angle of the mandible. **Arises** by fleshy fibres from the floor of the mastoid notch under cover of the mastoid process and tapers to be **inserted** into the common tendon.

Nerve : facial.

When both bellies contract, they raise the hyoid bone —during swallowing. When one belly contracts, the other becomes its insertion and the tendon is drawn through the pulley. Anterior belly tilts the head back ; posterior belly pulls down the mandible.

Chief Relations of Posterior Belly.—*Superficial* :—First, the mastoid process and the muscles attached to it, especially sterno-mastoid ; next, parotid gland and then the angle of the mandible and medial pterygoid ; beyond that, skin and fasciæ, but it is over-lapped by submandibular gland and crossed by anterior facial vein.

Stylo-hyoid runs downwards and forwards along its *upper border* and the posterior auricular artery upwards and backwards along that border.

Deep :—From origin to insertion—rectus capitis lateralis ; internal jugular ; 9th, 10th, 11th and 12th cranial nerves ; internal carotid ; stylo-pharyngeus ; external carotid ; facial artery ; side-

wall of pharynx; hyo-glossus, with hypoglossal nerve and veins from the tongue on its surface.

Occipital artery runs upwards and backwards along the *lower border*, or under cover of it. The hypoglossal nerve downwards and forwards along that border, thus having a triple relation to the belly—first deep, then below, and then deep again.

Stylo-Hyoid.—A slender slip. Arises (fl.-tend.) from the styloid process near its root. Runs along the upper border of posterior belly; is split by the digastric tendon; and re-unites to be inserted (fl.-tend.) into the hyoid bone at the junction of the body and greater horn.

Nerve: facial.

Draws hyoid bone upwards and backwards during swallowing.

Mylo-Hyoid.—Thin, wide sheet; slopes medially and downwards from origin to insertion and forms, with its fellow, a diaphragm across the floor of the mouth.

Arises by fleshy and tendinous fibres from the mylo-hyoid line of mandible. Most posterior fibres are inserted into the body of hyoid bone, and the rest of it into the tendinous *raphe* which extends from the symphysis menti to the hyoid bone.

Nerve: mylo-hyoid branch of inferior dental.

It raises the hyoid bone and tongue during swallowing.

Relations.—*Superficial*: Anterior belly of digastric crosses it obliquely. Submandibular salivary gland lies on it, postero-lateral to the anterior belly; and submental lymph-glands lie on its fascia near the median plane. Mylo-hyoid nerve and submental vessels run downwards and medially over it. Mandible, submandibular lymph-glands, deep fascia, cervical branch of facial nerve and platysma are more superficial still.

Deep: Genio-hyoid, alongside the median plane; genio-glossus, behind and above genio-hyoid. Anterior part of hyo-glossus is between genio-glossus and the posterior part of mylo-hyoid. Sublingual gland lies between mylo-hyoid and the upper, anterior part of genio-glossus. Lingual nerve, submandibular duct and the deep part of the submandibular gland, the hypoglossal nerve with its vena comitans and the principal vein of the tongue are between mylo-hyoid and hyo-glossus, in that order from above downwards. Sublingual artery runs to the sublingual gland between mylo-hyoid and genio-glossus, below the level of lingual nerve. Mucous membrane of mouth covers the deep surface of mylo-hyoid, near its origin, posteriorly.

Genio-Hyoid.—Lies behind chin, between mylo-hyoid and genio-glossus, in apposition with its fellow.

Origin (fl.-tend.): lower genial tubercle.

Insertion (fl.): body of hyoid bone.
Nerve: hypoglossal by fibres from c. 1.
Draws hyoid bone forwards and upwards.

Extrinsic Muscles of Tongue.—Palato-glossus (p. 618), genio-glossus, stylo-glossus, hyo-glossus.

The last three are found in the submandibular region, and they are supplied by the *hypoglossal nerve.*

Genio-Glossus.—Fan-shaped. Apex at origin. In apposition with its fellow. Lateral surface in relation to mylo-hyoid, hyo-glossus, stylo-glossus and sublingual gland. Genio-hyoid lies along lower border; mucous membrane of mouth covers its upper border.

Arises from upper genial tubercle (fl.-tend.) and radiates into tongue from the back of it to its tip.

Posterior or lower fibres protrude tongue; anterior depress. Whole of both muscles acting depresses tongue during suction.

Stylo-Glossus.—Slender. Arises (fl.-tend.) from the styloid process at its tip and from the stylo-hyoid lig. Passes forwards and downwards in the fat between the medial pterygoid and superior constrictor to be **inserted** (fl.) into the side of the tongue in its whole length, interlacing posteriorly with the insertion of hyo-glossus.

Draws the tongue upwards and backwards during swallowing.

Hyo-Glossus.—A four-sided sheet that lies under cover of the submandibular gland, mylo-hyoid muscle and the posterior half of the body of mandible.

Arises (fl.) from the hyoid bone—a small part of its body and almost the whole of the greater horn. Passes upwards to be **inserted** (fl.) into the posterior half or more of the side of the tongue.

Depresses the tongue to produce a cavity in the mouth in sucking.

Relations.—*Superficial*: Mylo-hyoid anteriorly, submandibular gland posteriorly, stylo-hyoid and the tendon of digastric on its postero-inferior part. Stylo-glossus interlaces with it at their insertion into the tongue, and they are covered with the mucous membrane of the mouth. Below that, there is the lingual nerve, with the submandibular ganglion suspended from it; then, the deep part of the submandibular gland and the duct; still lower, the hypoglossal nerve with its vena comitans, and the principal vein of the tongue below that; and the suprahyoid branch of lingual artery at the origin of the muscle.

Deep to it are: the genio-glossus anteriorly, fat and fascia of pharyngeal wall posteriorly, and the origin of middle constrictor inferiorly; and also the glosso-pharyngeal nerve, stylo-hyoid lig. and lingual artery with its venæ comitantes.

The glosso-pharyngeal nerve is running forwards and upwards between hyo-glossus and the pharyngeal wall into the back part of the tongue.

The stylo-hyoid ligament, downwards and forwards, between the same two, to reach the lesser horn of hyoid.

The lingual artery, first running forwards between hyo-glossus and middle constrictor near the hyoid bone, and then upwards on genio-glossus along the anterior border of hyo-glossus; its dorsales linguæ branches spring from the horizontal part and run up between hyo-glossus and genio-glossus to the dorsum of the tongue.

Stylo-Hyoid Ligament.—Extends downwards and forwards from the tip of the styloid process to the lesser horn of the hyoid bone.

May be indistinguishable from the fascia around it. May be a strong, definite band which contains muscle-fibres. May be partly chondrified or even ossified, in which case it may be mistaken for a foreign body in the wall of the pharynx.

Stylo-glossus and the stylo-mandibular lig. have a partial attachment to the front of its upper part, and the middle constrictor to the back of its lower part.

Lies on the superior constrictor and the fascial wall of pharynx. 9th nerve crosses deep to it; ascending palatine art. crosses either deep or superficial. It is under cover of the parotid gland, medial pterygoid, submandibular gland and hyo-glossus; the facial and lingual arteries cross it superficially. If a dorsalis linguæ arises early, it passes deep to the ligament.

It is derived from the fibrous sheath around the hyoid arch (p. 692), and corresponds to the *epihyal* of lower animals.

The three **principal salivary glands** are the parotid (p. 299), submandibular and sublingual. The submandibular and sublingual glands are in this region.

Submandibular Gland.—Lies partly under cover of the mandible and pterygoideus medialis, and partly between the mandible and the hyoid bone, overlapping the bellies of digastric.

It has three surfaces—lateral, medial and infero-lateral. It is enclosed in two layers of fascia which extend from the greater horn of the hyoid bone—the one to the lower border of the mandible, covering the infero-lateral surface; the other to the mylo-hyoid line, covering the medial surface. The lateral surface is without fascial covering. The posterior end of the gland is separated from the parotid gland by the stylo-mandibular ligament.

Infero-lateral surface is covered by platysma and the deep fascia. Cervical branch of facial nerve crosses it, from behind forwards, under cover of platysma; anterior facial vein crosses its posterior part, from above downwards, under cover of the deep fascia. Submandibular lymph-glands lie on the upper part of this surface, along the lower border of the mandible.

Lateral surface lies against the mandible and the lower part of pterygoideus medialis. Facial artery, having emerged from the groove on the posterior end of the gland, turns downwards and forwards, between the lateral surface of gland and pterygoideus medialis, to reach the lower border of the mandible.

Medial surface lies on mylo-hyoid anteriorly, pharynx posteriorly, and hyo-glossus in the middle; and it overlaps the digastric inferiorly. Between it and mylo-hyoid there are the mylo-hyoid nerve and branches of the submental vessels. Between it and hyo-glossus, from above downwards, there are stylo-glossus and lingual nerve, submandibular ganglion, hypoglossal nerve with its vena comitans and the chief vein of the tongue. The constituents of the pharynx to which it is related are the superior constrictor and the fascia in the gap between the superior and middle constrictors; the most posterior part of the gland may overlap stylo-glossus superiorly, stylo-pharyngeus posteriorly. The stylo-hyoid lig. and the glosso-pharyngeal nerve are between it and the fascial wall of the pharynx—the nerve crossing deep to the ligament.

Facial artery ascends in a deep groove on the posterior end of the gland.

Upper border of the part that lies on hyo-glossus is in relation with the mucous membrane of the mouth.

Deep part of gland is a flat, oblong prolongation forwards from the medial surface of the gland. It lies under cover of mylo-hyoid, on hyo-glossus and genio-glossus. It accompanies the duct, which is medial to it.

Arteries: Branches of facial and of its submental branch.

Lymph-vessels end in lymph-glands in the carotid triangle.

Nerves: Through submandibular ganglion, from the lingual and chorda tympani and the sympathetic plexus around the facial artery.

Submandibular Duct.—Formed by the union of the ductules of the lobules of the gland. Emerges from the medial surface of the gland; accompanies the deep part of the gland under cover of mylo-hyoid; passes deep to the sublingual gland to open into the mouth on the sublingual papilla at the side of the frenulum linguæ.

Hyo-glossus and genio-glossus are medial to the duct. Hypoglossal nerve is below it. Lingual nerve, at first above it, crosses it superficially at the anterior border of hyo-glossus, and then turns upwards, deep to it and the sublingual gland.

Sublingual Gland.—Lies under the sublingual fold in the floor of the mouth, where it can be felt by the tip of the down-turned tongue. It is almond-shaped, and about an inch and a half long. It has no fascial sheath.

Its *upper border* is covered with the mucous membrane of the floor of the mouth, which it bulges upwards as a ridge called the sublingual fold; its *lower border* rests on mylo-hyoid.

Its *lateral surface* is in contact with the floor of the sublingual fossa of mandible, *i.e.* near the symphysis, above the mylo-hyoid line. Its *medial surface* lies against genio-glossus (the lingual nerve and submandibular duct intervening) and near its upper border it

may be in contact with its fellow, above the level of genio-glossus.

Its **ducts,** 8 to 20 in number, open on the sublingual fold.

Arteries, from lingual and submental.

Lymph-vessels end in glands below the mandible.

Nerves, from lingual nerve and submandibular ganglion.

Blood-Vessels in the Submandibular Region:—

1. Cervical part of the facial artery and its branches.
2. Lingual artery and its branches.
3. Parts of anterior facial and anterior jugular veins (pp. 267, 291).
4. The veins of the tongue.

Facial Artery.—Arises from the front of the external carotid in the carotid triangle. Proceeds almost vertically upwards under cover of the posterior belly of digastric, stylo-hyoid and the angle of mandible. Above stylo-hyoid, it is enveloped in a deep groove on the medial part of the posterior end of the submandibular gland. As it ascends, the middle and superior constrictors are deep to it—the superior constrictor separating it from the tonsil.

It emerges from the groove in the posterior part of the submandibular gland and then runs downwards and forwards, between pterygoideus medialis and the lateral surface of the gland, to the lower border of the mandible, where it turns upwards, pierces the deep fascia and enters the face at the anterior border of masseter.

Branches in neck : asc. palatine, tonsillar, glandular, submental.

Ascending palatine artery ascends between pterygoideus medialis and superior constrictor, and between stylo-glossus and stylo-pharyngeus ; and it reaches the base of the skull at the apex of the petrous temporal bone. There, it pierces the pharyngo-basilar fascia above the superior constrictor, and then runs downwards along levator palati to the soft palate.

Tonsillar artery ascends between the medial pterygoid and stylo-glossus, turns medially, pierces superior constrictor and enters the tonsil.

Glandular branches supply the submandibular gland.

Submental artery arises after the facial emerges from the groove in the submandibular gland, runs forwards between the upper part of the gland and the mandible, slips over the upper border of the gland to join the mylo-hyoid nerve, and it accompanies the nerve on the surface of mylo-hyoid. Its branches supply the submandibular gland and the muscles and skin near it.

Lingual Artery.—Arises from the front of the external carotid, below the facial, opposite the tip of the greater horn of hyoid bone.

First part runs forwards and ends at the posterior border of hyo-glossus. It lies in the carotid triangle between the investing deep fascia and the fascia on the middle constrictor. There, it forms a loop, convex upwards, above the greater horn of hyoid, below the posterior belly of digastric ; and the loop is crossed superficially by the hypoglossal nerve.

Second part runs forwards along the upper border of the hyoid bone, lying on the middle constrictor and genio-glossus, under

cover of hyo-glossus. It crosses the stylo-hyoid lig., superficially, near the lesser horn of hyoid bone.

Third part runs upwards, between genio-glossus and the anterior border of hyo-glossus, to reach the tongue. It is under cover of mylo-hyoid. It is crossed superficially by branches of the hypoglossal nerve, and, at its termination, by the lingual nerve and submandibular duct.

Fourth part is called the **deep artery of the tongue.** It runs forwards to the tip of the tongue, having the inferior longitudinal inferior muscle above and lateral to it, the deep vein and the mucous membrane of the inferior surface of the tongue below it, and genio-glossus medial to it.

Branches.—Suprahyoid artery from its first part; dorsales linguæ from the second part; sublingual from the third part.

Suprahyoid artery runs along the upper border of the hyoid bone, superficial to hyo-glossus.

Dorsales linguæ, two or more, run upwards, between hyo-glossus and genio-glossus, to the pharyngeal part of the dorsum of the tongue and to the tonsil.

Sublingual artery runs upwards and forwards, between mylo-hyoid and genio-glossus, below the level of the submandibular duct and lingual nerve, to reach the sublingual gland.

Veins of Tongue.—**Venæ comitantes** accompany the lingual artery. A **vena comitans** accompanies the hypoglossal nerve.

The **deep vein** is the largest vein. It lies in the lower part of the free part of the tongue and can be seen through the mucous membrane; from the tongue, it descends over the genio-glossus on to the hyo-glossus and runs backwards across it, usually below the hypoglossal nerve.

These all unite at the posterior border of hyo-glossus to form the **lingual vein,** which ends in the common facial vein, or runs across the external and internal carotid arteries to end in the internal jugular vein.

Nerves in Submandibular Region.—(1) Mylo-hyoid; (2) lingual, with submandibular ganglion; (3) hypoglossal; (4) glosso-pharyngeal.

Mylo-Hyoid Nerve.—A branch of inferior dental. Leaves the infratemporal fossa (p. 309) and enters the submandibular region by passing from between the mandible and medial pterygoid and out of the mylo-hyoid groove on to the superficial surface of the mylo-hyoid muscle under cover of the submandibular gland, where it breaks up into branches to supply the mylo-hyoid and the anterior belly of digastric.

Lingual Nerve.—Leaves the infratemporal fossa by passing from between the mandible and pterygoideus medialis, and crossing over the attachment of superior constrictor to the posterior end of the mylo-hyoid line, under cover of the mucous membrane behind the last molar tooth.

It enters the submandibular space by crossing stylo-glossus

superficially, at the side of the tongue, deep to the submandibular gland; and it runs forwards, close to the tongue, between mylo-hyoid and hyo-glossus, below the mucous membrane, above the submandibular ganglion and duct. At the anterior border of hyo-glossus it crosses the duct superficially from above downwards, and runs onwards between the sublingual gland and genio-glossus.

Under cover of the sublingual gland it crosses deep to the submandibular duct, from below upwards; and its terminal branches proceed, under cover of the mucous membrane, as far as the tip of the tongue.

Branches.—*In the infratemporal region* it receives the chorda tympani and communicates with the inferior dental.

In the submandibular region it:—1. Sends communicating branches to the hypoglossal along the anterior border of hyo-glossus.

2. Gives communicating branches to the submandibular ganglion, and receives one from it.

3. Gives branches to the sublingual gland, mucous membrane of gums, floor of mouth and anterior two-thirds of tongue.

Submandibular Ganglion.—Suspended by communicating branches from the lingual nerve. It lies on hyo-glossus, under cover of the submandibular gland, above the origin of its duct.

Roots: *sympathetic*, from the plexus around the facial artery; *sensory*, from the lingual; *secretory*, from chorda tympani through the lingual.

Branches: to submandibular gland and duct; to mucous membrane of mouth; to sublingual gland and tongue (through its communicating branch to the lingual).

Most of the fibres of the roots pass, without interruption, through the ganglion into its branches. The only ones relayed are the secretory fibres for the submandibular and sublingual glands which are conveyed to the ganglion from the facial nerve by chorda tympani.

Hypoglossal Nerve.—Having crossed the carotids and the loop of the lingual artery, it leaves the carotid triangle by disappearing under cover of the posterior belly of digastric and stylo-hyoid, between them and hyo-glossus.

In the submandibular region, the nerve, accompanied by a small vein, passes forwards, first between the submandibular gland and hyo-glossus, and then between mylo-hyoid and hyo-glossus. Having crossed hyo-glossus it sinks through the substance of genio-glossus to supply all the intrinsic muscles of the tongue.

While in the submandibular space it supplies genio-hyoid, and all extrinsic muscles of tongue, except palato-glossus, namely, stylo-glossus, hyo-glossus, genio-glossus.

Its branch to genio-hyoid and its branches given off in carotid triangle to the infrahyoid muscles are derived from the first cervical nerve.

Glosso-Pharyngeal Nerve.—When it enters the submandibular region, it runs forwards over the superior constrictor and the fascial wall of the pharynx, disappears under hyo-glossus, and breaks up

into branches distributed chiefly to the tonsil and the mucous membrane of the posterior third of the tongue.

On its way to hyo-glossus, it is under cover of the submandibular gland, and is crossed superficially by the facial artery and stylo-hyoid ligament.

DEEP PARTS OF NECK

Muscles.—Stylo-pharyngeus ; scalene ; rectus capitis lateralis ; prevertebral.

Stylo-Pharyngeus.—Long and slender. Upper part lies deeply in the hollow between mandible and mastoid process, where it arises by fleshy and tendinous fibres from the styloid process near its root.

Passes downwards and slightly forwards between the external and internal carotids on to the side of the pharynx. Descends over superior constrictor, slips into the wall of the pharynx between superior and middle constrictors, and is joined by palato-pharyngeus ; and it then passes downwards between the mucous membrane and the lower two constrictors.

It is **inserted** by fleshy fibres mostly into the posterior border of the thyroid cartilage, but some fibres mingle with the constrictors.

Nerve : Glosso-pharyngeal, by a special branch.

It elevates the larynx and pharynx during speaking and swallowing.

Scalenus anterior lies under cover of sterno-mastoid.

Origin (fl.-tend.) : anterior tubercles of 3rd, 4th, 5th, 6th cervical transverse processes.

Insertion (tend.-fl.) : scalene tubercle and adjoining ridge on upper surface of first rib, between subclavian artery and vein.

Nerves : anterior primary rami of c. 4, 5, 6, 7, directly.

Bends neck to that side, and both muscles acting flex the neck slightly. Steadies the rib in inspiration.

Anterior surface is in relation to sterno-mastoid, int. jugular vein, ant. jugular vein, subclavian vein, thoracic duct, inferior belly of omo-hyoid and its nerve, suprascapular and transverse cervical arteries, ascending cervical artery and phrenic nerve.

The fascia on the front of scalenus anterior is a very definite layer ; the phrenic nerve is between the muscle and that fascia ; the other structures are superficial to the fascia.

Posterior surface is related to scalenus medius, roots of brachial plexus, subclavian art. and cervical pleura.

Scalenus medius lies in the floor of posterior triangle.

Origin (fl.-tend.): posterior tubercles of 1-7 cervical transverse processes (occasionally omitting 1 or 7).

Insertion (fl.-tend.): upper surface of first rib between groove for subclavian artery and tubercle of rib.

Nerves: anterior primary rami of c. 3-7 directly.

Bends the neck to that side. Steadies the rib in inspiration.

Cervical and brachial plexuses and subclavian art. lie on **anterior surface**; and it is crossed by omo-hyoid, transverse cervical vessels, suprascapular vessels and nerve and lowest root of the nerve to serratus anterior. Levator scapulæ and scalenus posterior lie **lateral** and **posterior** to it. It is pierced by the nerve to rhomboids and the upper two roots of the nerve to serratus anterior.

Slip from atlas is medial to the first slip of levator scapulæ, which is large and overlaps the scalene slip anteriorly and joins the other slips low down; next three slips of scalenus are in front of the origin of levator scapulæ; lower part is in front of scalenus posterior.

Scalenus posterior lies behind the medius and is frequently blended with it.

Origin (fl.-tend.): posterior tubercles of 4th, 5th, 6th cervical transverse processes.

Insertion (tend.): upper border of second rib behind the tubercle for serratus anterior.

Nerves: anterior primary rami of c. 5, 6, 7.

Elevates second rib; bends the neck to that side.

Rectus Capitis Lateralis.—**Origin** (fl.-tend.): upper surface of transverse process of atlas. **Insertion** (fl.-tend.): lower surface of jugular process of occipital bone. **Nerve**: ant. ramus of c. 1.

It bends head to that side.

It is homologous with the posterior intertransverse muscles.

Anterior surface is related to internal jugular vein and the last four cranial nerves at base of skull. *Posterior* surface is covered by obliquus superior. *Lateral* to it are occipital artery and posterior belly of digastric. *Medial* to it are vertebral vessels and anterior ramus of first cervical nerve and atlanto-occipital joint.

Prevertebral Muscles.—Longus cervicis, longus capitis, rectus capitis anterior.

Longus cervicis lies on the front of the cervical and upper thoracic vertebræ and the front of the head of the first rib, extending from the anterior tubercle of atlas to the body of the third thoracic vertebra; attached by tendinous slips to the vertebral bodies, cervical transverse processes and the anterior tubercle of atlas.

Nerves: ant. rami of c. 3-8. Bends and rotates neck to same side.

Longus capitis lies on the front of the upper cervical vertebræ.

Origin (tend.): anterior tubercles of 3rd, 4th, 5th, 6th cervical transverse processes (*compare with* scalenus anterior).
Insertion (fl.-tend.): lower surface of basi-occipital, anterior and lateral to pharyngeal tubercle.
Nerves: ant. primary rami of c. 1-4.
Flexes head; turns face to the same side.
Rectus capitis anterior lies behind and lateral to longus capitis.
Origin (fl.-tend.): anterior surface of lateral mass of atlas.
Insertion (fl.-tend.): lower surface of basi-occiput in front of condyle.
Nerve: ant. primary ramus of c. 1.
Flexes the head.

Deep Fascia of the Neck.—The deep fascia comprises not only the *investing layer*, which envelops the neck as a whole and splits to enclose sterno-mastoid and trapezius, but also the septa which arise from its deep surface (especially from the layer under sterno-mastoid) and pass inwards and divide to cover and ensheath the deep muscles, the glands, the pharynx, trachea and œsophagus and the large vessels and nerves.

The **investing fascia** is a continuous envelope attached *superiorly* to the external occipital protuberance, superior nuchal line, mastoid temporal, and body of mandible; and it is prolonged upwards to ensheath the parotid gland.

It splits into two layers to enclose the sterno-mastoid and trapezius. In front of and behind sterno-mastoid, it forms the roofs of the anterior and posterior triangles of neck. The two layers are fused over the upper and larger parts of the triangles.

Over the lowest part of the posterior triangle, the layers remain separate; the first layer is attached to the upper surface of clavicle, and the second layer fuses with the fascia on the back of subclavius. They enclose the suprascapular vessels, the lower part of external jugular vein and the terminal part of the transverse cervical veins; and the deeper layer is connected superiorly with the fascia of omo-hyoid and binds it down.

Lower parts of the layers remain separate above sternum also (*suprasternal space*); attached to the front and back of the upper part of manubrium; enclose the jugular arch, interclavicular ligament, fatty areolar tissue and sometimes a lymph-gland.

At the median plane in front, the fasciæ of opposite sides are continuous, and are attached only to the body and greater horn of the hyoid bone. At back of neck, the fascia is attached to lig. nuchæ at the median plane; inferiorly, it is continuous with the fascia of the back medially, and is attached to the spine of scapula laterally.

The principal sheets and sheaths derived from the septa are:—prevertebral fascia; pretracheal fascia; bucco-pharyngeal fascia; carotid sheath; and suprapleural membrane.

Prevertebral fascia covers longus cervicis, longus capitis, and rectus capitis anterior and lateralis. It is continuous, *laterally*, over the scaleni, with the fascia on the floor of the posterior triangle. Attached *superiorly* to styloid process, jugular process and basilar portion of occipital. *Inferiorly* it is continued down into the thorax in front of longus cervicis.

Pretracheal fascia extends across between the deep surfaces of the sterno-mastoids, covers the front and sides of the trachea, and splits to enclose the thyroid gland. *Above*, it is fixed to the cricoid and thyroid cartilages. *Below*, it is continued downwards over the trachea to be connected with the back of the upper part of the pericardium.

Bucco-pharyngeal fascia covers buccinator and the constrictors of pharynx. Opposite the sides of pharynx, it is connected with prevertebral fascia, but between these lateral attachments it is separated from the prevertebral fascia by the **retropharyngeal space,** which contains loose areolar tissue and some retropharyngeal lymph-glands.

Carotid sheath is the tube of fascia that encloses the common and internal carotid arteries, the internal jugular vein and the vagus. Connected with prevertebral and pretracheal fasciæ. Sympathetic trunk is imbedded in its posterior wall; descendens hypoglossi in its anterior wall. Descendens cervicalis n., cervical branches of vagus, and the tributaries of the internal jugular vein pierce it.

Suprapleural membrane springs from the seventh cervical transverse process and fans out over the top and front of the cervical pleura to be attached to the inner border of the first rib, separating the pleura from the muscles, vessels and nerves in the root of the neck.

Fascia which invests the scalene muscles, subclavian vessels and brachial nerves, is carried down into the axilla to form the axillary sheath.

Viscera in the Neck.—Submandibular gland (p. 316); thymus; thyroid gland and parathyroid glands; trachea; œsophagus; apex of lung and cervical pleura.

Thymus.—A ductless gland. Degenerated into fat and fibrous tissue in the adult. Has a pair of finger-like lobes that lie side by side in front of the pericardium and big vessels in the thorax; but their uppermost parts are in the root of the neck in front of the trachea. (*See also* pp. 602, 676.)

Thyroid Gland.—A ductless gland. Lies in the lower part of the front of the neck, clasping the trachea and overlapping the sides of the larynx. Ensheathed in pretracheal fascia, which binds it to the oblique line of thyroid cartilage and the arch of cricoid cartilage, so that it moves up and down with the larynx. Has a fibrous capsule; and between the capsule and the sheath there are networks of

anastomosing arteries and veins. Varies in size, and always relatively bigger in women and children than in men. (*See also* p. 677.)

Has a *right* and a *left lobe* united across the front of the trachea by an *isthmus*.

Isthmus—half an inch wide, and three-quarters of an inch deep—unites the lower part of the lobes and lies on the 2nd, 3rd and 4th rings of the trachea, covered with skin and fasciæ. **Pyramidal lobe** is a little nipple that juts upwards from the upper border of the left half of the isthmus, and is connected with the hyoid bone by *levator glandulæ thyreoideæ*, or by a fibrous band. Along the upper border of the isthmus there is an anastomosis between opposite thyroid arteries.

Lobe, on each side, reaches up to the insertion of sterno-thyroid into the oblique line of the thyroid cartilage (the attachment of the muscle preventing the gland from reaching higher) and down to the 6th ring of the trachea—near the medial end of the clavicle.

Piriform in shape, apex upwards; two inches long, an inch and a quarter broad, three-quarters of an inch thick.

Related *medially* to the thyroid cartilage, crico-thyroid muscle, external laryngeal nerve, cricoid cartilage, trachea; and, farther back, to inferior constrictor, œsophagus and recurrent laryngeal nerve. Related *posteriorly* to common carotid, inferior thyroid artery and longus cervicis. Covered *superficially* by sterno-thyroid, sterno-hyoid, omo-hyoid, and their nerves from the ansa hypoglossi; and these muscles are overlapped by sterno-mastoid.

Arteries.—*Superior thyroid* from external carotid (p. 338). *Inferior thyroid* from thyro-cervical trunk of first part of subclavian (p. 333). Occasional *thyreoidea ima* from innominate.

Veins.—Three pairs—superior, middle and inferior.

Superior thyroid vein comes from the upper part of the gland, emerges from under sterno-thyroid and omo-hyoid, crosses the common carotid in the carotid triangle and enters the internal jugular vein; or it runs up along the superior thyroid artery and ends in the common facial vein.

Middle thyroid vein, wide and very short, comes from the lower lateral part of the lobe, crosses the common carotid and ends in the internal jugular under cover of sterno-thyroid.

Inferior thyroid veins come from the isthmus and the lower medial part of the lobe, descend in front of the trachea, pierce pre-tracheal fascia behind the thymus, and end in the innominate veins immediately below the inlet of thorax.

Nerves, from cervical sympathetic ganglia, accompany the arteries to the thyroid gland.

Lymph-vessels end in deep cervical glands and in the small glands on the front and sides of the larynx and trachea.

Parathyroid Glands.—Two pairs of lens-shaped ductless glands, each about the size of a small pea. Imbedded in the back of the capsule of the thyroid gland—the *inferior* near its lower end and the *superior* about its middle. Each is supplied by a branch of the inferior thyroid artery. (*See also* p. 677.)

Trachea.—Continuous with the larynx. Begins opposite the sixth cervical vertebra immediately below cricoid cartilage, to which it is attached by a fibrous ring—*crico-tracheal lig.* Ends in thorax opposite the sternal angle by dividing into the right and left bronchi.

An inch wide and 4 or 5 inches long—half in the neck and half in the thorax.

Kept open by 15 horseshoe-shaped bars of cartilage which make its front and sides rounded. Flat behind, where these " tracheal rings " are replaced by the *trachealis muscle*, which contracts from below upwards and draws the ends of the horseshoes closer together —narrowing the tube in coughing.

Passes downwards and slightly backwards (in the median plane), receding from the surface as it approaches the sternum.

Relations in Neck.—Superficial to it are the deep fascia of neck ; suprasternal space and its contents (especially the jugular arch) ; sterno-hyoids and sterno-thyroids ; isthmus of thyroid gland on 2nd, 3rd and 4th rings ; pyramidal lobe and anastomosis between superior thyroid vessels, above isthmus. Below the isthmus, the trachea is some distance from the surface, and the near relations are the thymus, inf. thyroid veins, occasional thyreoidea ima artery, pretracheal fascia and lymph-glands.

Lateral to it there are :—the lobe of thyroid gland, down to the 5th or 6th ring ; innominate and common carotid arteries on the right side, common carotid on the left side ; pleura and lung on each side some distance away, at the root of the neck.

Posterior to it are the œsophagus and longus cervicis muscles, and the recurrent laryngeal nerve on each side, in the groove between the margins of trachea and œsophagus.

Œsophagus.—A muscular tube, about an inch wide, flattened from before backwards so that the lumen is a mere slit.

Begins as a continuation of the pharynx at the same level as the trachea—sixth vertebra and lower border of cricoid cartilage. Ends in the stomach.

Relations in Neck.—It passes downwards and slightly backwards, rather more of it on the left of median plane than on the right, *in front of* the backbone, and overlapping both the longus cervicis muscles, immediately *behind* the trachea and recurrent nerves, and protruding a little to left side of trachea.

On its right side there are pleura and lung, at the root of the neck ; thyroid gland and common carotid artery, higher up. At the inlet of thorax, the left common carotid is anterior to its *left border*, and the thoracic duct and left subclavian artery and pleura are *on its left side*. Higher up, the common carotid is on its left side, and both are overlapped by the thyroid gland.

Cervical Pleura and Apex of Lung.—The summit of the lung is on the front of the neck of the first rib ; but, owing to the obliquity of the rib, this is at the level of a point about an inch above the medial third of the clavicle. The term " apex of the lung " includes all the part above the level of the anterior part of the rib ; and it

is therefore in the root of the neck behind and above the medial third of the clavicle.

The cervical pleura is that part of the parietal pleura which is above the level of the anterior part of the first rib—covering the apex of the lung and ending, therefore, at the neck of the rib.

Relations of Cervical Pleura and Apex of Lung

IMMEDIATE RELATIONS.—Cervical pleura is supported *inferiorly* by *lung* and separates it from the structures mentioned below.

Suprapleural membrane, spreading from 7th c. transverse process to inner margin of first rib, is the closest relation of pleura anteriorly and laterally. *Scalenus medius* protects and bounds it laterally, and *scalenus anterior* antero-laterally.

Vessels.—*Subclavian art.* arches laterally across the front of pleura, below summit; left artery ascends on medial side before doing so.

Int. mammary descends from it, *vertebral art.* and *thyro-cervical trunk* ascend from it, all on the front of pleura; *costo-cervical trunk* runs up to summit and its *sup. intercostal branch* turns downwards behind the summit, between it and the neck of the first rib.

Innominate art. is antero-medial and is separated by fatty areolar tissue.

Int. jugular vein descends in front of pleura and subclavian art.; *vertebral vein* is behind jugular. *First posterior intercostal vein* arches forwards over apex of pleura and joins vertebral, or runs down between pleura and subclavian art. to join innominate. *Subclavian vein* is separated from pleura by scalenus anterior, but the left vein ends on pleura, medial to scalenus. *Innominate vein* is below subclavian art.; and between vein and pleura are phrenic n. and int. mammary art.; the right vein passes over rounded ant. margin of upper part of pleura and lung on to their medial surface.

Thoracic duct ascends into neck between œsophagus and medial surface of left pleura, arches laterally behind carotid sheath at a higher level than pleura, turns downwards in front of subclavian art. and pleura, lateral to int. jugular, to join innominate vein.

Nerves.—*Vagus* and *cervical cardiac branches* of vagus and of sympathetic descend medial to int. jugular, on the front of pleura, and pass on to its medial side. *Phrenic nerve* descends obliquely on the front of pleura behind innominate vein, and turns over blunted ant. border of pleura on to medial surface; on right side it crosses int. mammary art. *Ansa subclavia* loops round subclavian art. medial to int. jugular, in front of pleura; on right side the *recurrent laryngeal n.* also hooks round.

Sympathetic trunk and *first thoracic n.* are behind the summit, on the front of the neck of the first rib, the nerve being lateral to the trunk; and, between them, there are sup. intercostal art. and first posterior intercostal vein.

Viscera.—*Trachea* and *œsophagus* are medial to each apex, separated from it by fatty areolar tissue in which there are:—on right side, vagus and cardiac nerves; on left side, the phrenic, vagus, cardiac nerves, carotid and subclavian arteries and thoracic duct. *Lymph-glands* lie in relation to vessels on all sides.

More Remote Relations of Cervical Pleura.—Medial third of *clavicle, subclavius, sterno-mastoid, sterno-hyoid* and *sterno-thyroid.* These conceal cervical pleura and the structures in front of it. *Ant. jugular vein* runs laterally immediately above clavicle, between sterno-mastoid and the other two sternal muscles.

Relations of Structures at Inlet of Thorax

Inlet of thorax belongs to both neck and thorax.

It is bounded by the first thoracic vertebra posteriorly, first rib and its cartilage on each side, manubrium sterni anteriorly.

Owing to the obliquity of the inlet, structures which enter or leave the thorax, at the anterior part of the inlet, do so at the level of the lower border of the body of the second thoracic vertebra; and the lower part of their cervical course is, therefore, opposite the first two thoracic vertebræ.

CERVICAL PLEURA, with underlying apex of **LUNG,** occupies the lateral part on each side, and is roofed over by the *supra-pleural membrane.* With the exception of the internal mammary artery and the vessels and nerves in relation to the neck of the first rib, the other structures occupy the interval between the two pleuræ.

MUSCLES.—Longus cervicis, on each side, is ascending on the bodies of the vertebræ, covered with **prevertebral fascia.**

Sterno-thyroid is ascending from the back of the manubrium and first cartilage. **Sterno-hyoid** is ascending from the manubrium, superficial to sterno-thyroid. (Its clavicular origin is above the inlet of thorax.)

VISCERA.—Trachea is descending in the median plane behind these sternal muscles, separated from them by **thymus,** and by **pretracheal fascia,** which clothes its front and sides.

Œsophagus is behind the trachea, separating it from the prevertebral fascia and longus cervicis muscles; it protrudes a little to the left of the trachea.

VESSELS.—Innominate artery is passing upwards and to the right, from behind the manubrium to the back of the right sterno-clavicular joint, posterior to sterno-hyoid, sterno-thyroid, thymus and left innominate vein; as it enters the neck it passes off the front of the trachea on to its right side.

Left common carotid artery is passing upwards and slightly to the left, from behind the manubrium to the back of the left sterno-clavicular joint, posterior to the muscles, thymus and left innominate vein; as it enters the neck, it slips off the front of trachea on to its left side, and lies in front of the left margin of the œsophagus.

The ascending part of the **left subclavian artery** is behind and to the left of the common carotid; it lies in a groove on the medial surface of the pleura and lung, and passes from the left side of the trachea to the left side of the œsophagus.

Internal mammary artery is entering the thorax behind the first costal cartilage, in front of the pleura. Its *vein* ends in the innominate at the inlet of the thorax. **Pericardiaco-phrenic branch**

of internal mammary artery accompanies the phrenic nerve into the thorax ; its *vein* ends in the internal mammary vein.

Superior intercostal artery is descending over the front of the neck of the first rib, behind the apex of the pleura, between the sympathetic trunk medially and the first thoracic nerve laterally. *First posterior intercostal vein* ascends to the root of the neck along one or other side of it.

Thyreoidea ima artery, when present, ascends from the innominate artery, on the anterior surface of the trachea, to reach the isthmus of the thyroid gland.

Inferior thyroid veins are descending over the trachea, and pierce the pretracheal fascia to end in the innominates.

Right innominate vein is descending behind the first cartilage, on the right side of the innominate artery, in a groove on the medial surface of the right pleura and lung, with the phrenic nerve and accompanying artery between it and the pleura.

Left innominate vein, having passed downwards and to the right, behind the clavicle, sterno-clavicular joint and sterno-hyoid and sterno-thyroid muscles, and in front of the pleura, internal mammary artery, phrenic and vagus nerves and ascending part of subclavian artery, now enters the thorax in front of the left common carotid ; and then, in the thorax, it passes to the right and slightly downwards, behind the thymus and the muscles, in front of the carotid and innominate arteries and the trachea, near the upper border of the manubrium ; and ends opposite the first right cartilage by joining the right vein to form superior vena cava, behind the anterior edge of the right pleura and lung.

Thoracic duct is ascending along the left border of œsophagus, between it and the pleura.

Right and left mediastinal lymph-trunks are ascending along the borders of the œsophagus.

Numerous *lymph-glands* lie in relation to the various vessels.

NERVES.—Right phrenic nerve, having crossed the internal mammary artery latero-medially, slips over the rounded upper part of the anterior border of the pleura and lung, from their anterior surface on to their medial surface, accompanied by the pericardiaco-phrenic artery, and enters the thorax between the innominate vein and the pleura, a little behind the first costal cartilage.

Left phrenic nerve, having descended medial to the internal mammary artery, behind the innominate vein, passes off the anterior surface of pleura on to its medial surface, and it enters the thorax as it emerges from behind the innominate vein. It is accompanied by the pericardiaco-phrenic artery, and lies in the interval between the carotid and subclavian arteries, but is as yet behind and to the left of the vagus, which it crosses after it enters the thorax.

Right vagus is passing downwards and medially, postero-lateral to the innominate artery, medial to the pleura, to reach the side of the trachea.

Left vagus is descending in the fat on the left side of the trachea, between the left common carotid and the ascending part of the subclavian artery, and has pleura in relation to its lateral side.

Left recurrent laryngeal nerve is ascending in the groove between the œsophagus and trachea. (Right recurrent laryngeal nerve arises above the level of the inlet, and one or both nerves may be on the side of the trachea instead of in the groove.)

Cervical cardiac branches of vagus and sympathetic are descending in company with the vagus. *Cardiac branches of right recurrent laryngeal nerve* are descending on the side of the trachea.

Sympathetic trunk is in front of the neck of the first rib, behind the apex of the pleura; and here the inferior cervical ganglion is often fused with the first thoracic ganglion.

Anterior primary ramus of the **first thoracic nerve** is passing obliquely sidewards and upwards, behind the pleura, across the anterior surface of the junction of neck and shaft of first rib, to join the brachial plexus, and is giving off the first intercostal nerve.

Deep Vessels of Neck

Innominate artery; subclavian artery and its branches; common carotid; internal carotid; external carotid and its branches.

Internal jugular vein and its tributaries; subclavian vein; innominate vein and its cervical tributaries.

Innominate Artery.—Arises from the arch of aorta opposite the centre of the manubrium on the front of the trachea. Extends upwards and to the right, out of the thorax into the neck, passing from the front of the trachea to its right side, and from behind the manubrium and left innominate vein to the back of the sterno-clavicular joint. It ends behind the upper border of that joint by dividing into right common carotid and subclavian arteries.

Relations in Neck.—Anterior to it are thymus, sterno-thyroid, sterno-hyoid, sterno-clavicular joint, in that order from behind forwards.

Trachea is *medial to it*; right innominate vein is *lateral*.

Posterior to it some fatty areolar tissue separates it from longus cervicis, and sometimes from pleura and lung. The vagus is first lateral and then on a posterior plane as it enters the thorax and approaches the side of the trachea.

The two terminal branches are its only branches, except the occasional **thyreoidea ima artery,** which arises near its root and runs upwards over the trachea to the isthmus of the thyroid gland.

Right Subclavian Artery.—Arches laterally from the sterno-clavicular joint to the outer border of the first rib, where it ends by becoming the axillary artery. It crosses the front of the cervical pleura below its summit, separated from it by the suprapleural membrane, and then lies across the upper surface of the first rib. Scalenus anterior descends in front of the artery and divides it into three parts.

First part extends from its origin as far as scalenus anterior.

Relations of first part.— Anterior: (1) skin and superficial fascia, with medial supraclavicular nerves and platysma; (2) deep fascia; (3) sterno-mastoid; (4) the anterior jugular vein, under cover of

sterno-mastoid ; then, (5) the sterno-hyoid and -thyroid. Deep to these, and close to the artery, there are : (6) the internal jugular vein ; (7) vertebral vein, behind internal jugular ; (8) vagus, medial to internal jugular vein ; (9) a nerve cord from the middle cervical ganglion descends in front of the subclavian artery medial to the vagus, and turns upwards behind the artery to join the inferior cervical ganglion ; the loop so formed is the *ansa subclavia* ; (10) common carotid is in front of the subclavian at its origin.

Posterior and *inferior* : lung, pleura, suprapleural membrane, and, near its origin, the recurrent laryngeal nerve and ansa subclavia ; and, more laterally, the first intercostal vein sometimes. Cervical cardiac branches of the vagus and sympathetic descend either in front of the artery or behind it.

Second part is behind scalenus anterior ; it is the highest part of the arch—half an inch above the clavicle near the posterior border of sterno-mastoid.

Anterior to it : scalenus anterior, in front of which, from above downwards, are transverse cervical and suprascapular arteries, ant. jugular and subclavian veins, the subclavian vein being below the level of its artery ; phrenic nerve descends between the arteries and scalenus anterior, which separates the nerve from the second part of the right subclavian ; sterno-mastoid covers all these, and, beyond it, fasciæ and skin.

Posterior and *inferior* are suprapleural membrane, pleura and lung.

Third Part.—(*See* Posterior Triangle of Neck, p. 273.)

Left Subclavian Artery.—Springs from the aortic arch at the left side of the trachea opposite the middle of the left margin of manubrium. Passes upwards and enters the neck, postero-lateral to the common carotid, opposite the sterno-clavicular joint. Ascends in the neck opposite the joint to the level of its upper border, and then arches across the pleura and first rib like the right artery ; and, like the right artery, it is divided into three parts by the scalenus anterior.

Relations.—While the **first part** is still ascending opposite the joint, it lies in a groove on the medial surface of the pleura and lung, at the left side of the œsophagus, with the thoracic duct *behind* it, the left recurrent laryngeal nerve *medial* to it, the common carotid *antero-medial* to it, the vagus nerve, internal jugular and innominate veins *in front of* it. Cervical cardiac branches of the vagus and sympathetic are either anterior or posterior to it.

As it arches laterally, its relations are like those of the right artery, with these exceptions :—the recurrent nerve does not hook round it ; the phrenic nerve and thoracic duct descend across the front of it at the lateral side of the internal jugular vein.

Note that the thoracic duct arches from behind the ascending part to the front of the transverse part.

Second part of artery has the same relations as on the right side, except that the phrenic nerve passes off scalenus anterior before it reaches the level of the subclavian artery, and is therefore an anterior relation not of the second part but of the first part.

Branches of Subclavian Artery.—Vertebral, internal mammary, thyro-cervical trunk—from the *first part.* Costo-cervical trunk from the *second part.*

Vertebral Artery.—Arises from the subclavian artery and ends in the cranial cavity. It is divided into four parts. All parts are surrounded by a plexus of nerves derived from the inferior cervical ganglion of the sympathetic trunk; and all parts are placed deeply out of danger—second and fourth parts protected by bone also—for some of the branches of the fourth part supply the medulla oblongata, which is the part of the brain most essential to life.

First part springs from upper surface of the first part of the subclavian artery about half an inch from the medial margin of scalenus anterior. Passes upwards in the root of the neck deeply situated behind the carotid sheath and all the structures in front of the sheath. Disappears into the foramen of the sixth cervical transverse process, and becomes the second part.

Relations.—Common carotid artery is antero-medial below, and anterior to it above; vagus, vertebral vein and int. jugular vein are antero-lateral; inf. thyroid artery crosses in front of it immediately before it disappears into the sixth transverse foramen; and the thoracic duct crosses in front of the *left* artery opposite seventh vertebra.

Thyro-cervical trunk and scalenus anterior are lateral to it. Longus cervicis and the lower cervical part of the sympathetic trunk are medial.

Pleura is posterior at its origin; and, higher up, the inferior cervical ganglion, seventh cervical transverse process and 7th and 8th cervical nerves are behind it.

Branches.—Only small unnamed *muscular.*

Vertebral vein emerges from the sixth cervical transverse process, descends at first in front of the vertebral artery and then lateral to it, and in front of the pleura and subclavian artery, behind the internal jugular vein; and ends in the innominate. It has a valve at its termination.

It receives:—(1) the *anterior vertebral vein*, which accompanies the ascending cervical artery; (2) the *deep cervical vein*; (3) the *first posterior intercostal vein* (sometimes); (4) small veins from bones and muscles.

Second part traverses the foramina in the upper six cervical vertebræ and the intervals between the transverse processes.

Relations.—Surrounded by the plexus of nerves from inferior cervical ganglion and by a plexus of veins which begins in the suboccipital plexus and ends at the sixth transverse process by giving rise to the vertebral vein. The artery is in front of the anterior primary rami of cervical nerves and is medial to the intertransverse muscles.

[The *uppermost portion* of the second part—the portion between the holes in axis and atlas—is nearly an inch long, and is curved with a convexity backwards and in a lateral direction. The first slip

of scalenus medius and the first posterior intertransverse muscle are anterior or antero-lateral relations. Levator scapulæ is lateral. Longissimus capitis and splenius and obliquus inferior are behind it. The atlanto-axial joint and adjoining bone are medial. The anterior primary ramus of the second cervical nerve curves forwards across its lateral side to reach the front of it, before turning on to the anterior surface of the first slip of scalenus medius.]

Branches of Second part.—1. Small unnamed *muscular.*

2. *Spinal branches*, which pass through the intervertebral foramina to assist in the supply of the contents of the vertebral canal.

Third and **Fourth Parts** of **Vertebral Artery.**—*See* pp. 281, 430.

Right Internal Mammary Artery.—Arises from the lower surface of the first part of the subclavian at the medial border of scalenus anterior. Runs downwards, forwards and medially, on the anterior surface of the pleura, to enter the thorax immediately behind the first cartilage.

Anterior to it are clavicle, termination of internal jugular, and the commencement of innominate vein, from behind which it emerges as it enters the thorax. While it lies behind the innominate vein it is crossed obliquely, latero-medially, by the phrenic nerve, and gives off its *pericardiaco-phrenic branch.*

The **left artery** is alike, except that: (1) it is behind the subclavian vein instead of the jugular before it passes behind the innominate vein; and (2) the left phrenic nerve, having slipped off scalenus anterior at a higher level than the right nerve, does not cross the mammary artery or does so at the origin of the artery.

Internal mammary vein does not ascend into the neck; it ends in the innominate at the inlet of the thorax.

Thyro-cervical trunk arises from the front of the first part of the subclavian between scalenus anterior and the vertebral artery, and between the phrenic and vagus, behind the internal jugular vein; and divides almost at once into inferior thyroid, transverse cervical and suprascapular.

Transverse cervical and **suprascapular arteries** run laterally, in front of scalenus anterior and the phrenic nerve, deep to the sternomastoid, and pass into the posterior triangle (p. 274). Their veins end, in the posterior triangle, by joining the external jugular.

Inferior Thyroid Artery.—Runs upwards along the medial border of scalenus anterior, behind the internal jugular vein, as far as the level of the sixth vertebra. It then turns abruptly medially and crosses behind the vagus, common carotid and middle cervical ganglion, in front of the vertebral artery and longus cervicis; reaches the middle of the back of the thyroid gland and runs downwards along it.

Recurrent laryngeal nerve ascends either in front of or behind the inferior thyroid artery; and, on left side, the thoracic duct is in front of the origin of the artery.

Inferior thyroid veins (p. 325) do not accompany the artery.

Branches.—1. Unnamed muscular branches to adjacent muscles.
2. Ascending cervical.
3. Inferior laryngeal branch, which enters the larynx under cover of the lower border of inferior constrictor, with the recurrent laryngeal nerve.
4. Branches to trachea and œsophagus.
5. Terminal branches to the thyroid gland.

Ascending cervical artery arises from the bend of inferior thyroid. Runs upwards behind internal jugular over cervical transverse processes, between the origins of scalenus anterior and longus capitis. Gives branches to these muscles, and sends *spinal branches* into the vertebral canal through the intervertebral foramina.

The companion vein is the *anterior vertebral vein*; and it ends in the vertebral vein.

Costo-Cervical Trunk.—Arises from the second part of subclavian; ascends over the pleura, behind scalenus anterior, to reach the neck of the first rib; and divides there into the deep cervical and superior intercostal.

The **left** trunk may arise from the first part of subclavian.

Deep cervical artery passes backwards between the neck of the first rib and the seventh cervical transverse process, and ascends in the back of the neck. (*See also* p. 282.)

Superior intercostal artery turns downwards in front of the neck of the first rib, behind the apex of the pleura, between the sympathetic trunk medially and the first thoracic nerve laterally, and ends in branches for the upper two intercostal spaces.

First posterior intercostal vein ascends along the lateral side of the superior intercostal artery, in front of the neck of the first rib, passes forwards above apex of pleura, and either ends in the vertebral vein, or descends between the subclavian artery and pleura to end in the innominate vein. As it ascends across the neck of the rib it may pass obliquely in front of the superior intercostal artery to gain its medial side before it leaves the rib.

Right Common Carotid Artery.—A terminal branch of innominate. Begins behind the upper border of the sterno-clavicular joint. Runs upwards and slightly sidewards through the lower part of the neck into the carotid triangle, where it ends by dividing into external and internal carotids opposite the upper border of the thyroid cartilage and lower border of the third cervical vertebra. Enclosed with internal jugular vein and vagus in the carotid sheath.

Gives no branches except its terminals.

Relations.— *Anterior*:—1. Skin.
2. Superficial fascia with platysma and branches of the medial supraclavicular nerves and anterior cutaneous nerve of the neck.
3. Deep fascia.
4. Sterno-mastoid, under cover of which the anterior jugular vein passes laterally just above the clavicle.
5. Then come sterno-hyoid, omo-hyoid and sterno-thyroid.
6. Under cover of these there are the middle thyroid vein and ansa hypoglossi.

Anterior to the small part of it in the carotid triangle, the descendens hypoglossi descends vertically; the artery to sterno-mastoid and the superior thyroid vein cross laterally.

Medial:—Trachea, œsophagus, recurrent laryngeal nerve below; larynx and pharynx above.

Thyroid gland is medial and overlaps it anteriorly.

Posterior:—Longus cervicis below; longus capitis above. Sympathetic trunk all the way. Recurrent laryngeal nerve near its origin; and inferior thyroid artery opposite the cricoid cartilage and sixth vertebra.

The subclavian artery is behind the common carotid at their origin. Vertebral artery is related to its lower part—at first postero-lateral, and then behind it.

Lateral:—Internal jugular vein; vagus and cardiac nerves between the posterior parts of the vein and artery.

Left Common Carotid Artery.—Springs from the aortic arch on the front of the trachea opposite a point a little to the left of the centre of manubrium. Runs upwards and slightly sidewards and backwards, slipping off the front of the trachea on to its left side as it enters the neck opposite the *lower* border of the sterno-clavicular joint, antero-medial to the subclavian artery.

It then runs its course and ends like the right artery; and the relations are alike except for some differences in the root of the neck:—

1. Recurrent laryngeal nerve is not a posterior relation.
2. Thoracic duct passes laterally behind it, between it and the vertebral artery, at the level of the seventh vertebra.
3. Internal jugular vein tends to overlap it more.
4. Since it begins its cervical course at the lower border of the sterno-clavicular joint, the joint is an additional anterior relation—separated by the sterno-thyroid and sterno hyoid and the left innominate vein. And the pleura is an additional lateral relation.

Carotid sinus is the slight dilatation of the end of the common carotid and beginning of the internal carotid.

Carotid Body.—*See* p. 679.

Styloid Process.—An inch long; slender and pointed. Juts downwards, forwards and medially from the petrous temporal between the external and internal carotids to reach the side of the pharynx. Three muscles and two ligaments spring from it:

Stylo-hyoid muscle arises near its root and passes superficial to both carotids to reach the hyoid bone.

Stylo-pharyngeus arises near its root and, with the styloid process and glosso-pharyngeal nerve, passes between the external and internal carotids to reach the pharynx.

Stylo-glossus passes to the tongue from the tip of the process and is therefore not related to the arteries unless the process is so short that it ends between the arteries.

Stylo-hyoid and Stylo-mandibular Ligaments.—*See* pp. 125, 316.

If the styloid process is long or is lengthened by ossification of the upper part of the stylo-hyoid lig., it can be felt by the finger

passed through the mouth into the pharynx and pressed sidewards ; and a long process, thus felt, may be mistaken for a foreign body in the wall of the pharynx.

Internal Carotid Artery.—A terminal branch of common carotid. Begins opposite the upper border of the thyroid cartilage.

Ascends along the side of the pharynx to the base of the skull, traverses the carotid canal, crosses the upper part of foramen lacerum, pierces the outer layer of dura mater, runs forwards on the side of the body of the sphenoid in the cavernous sinus, escapes from the sinus by piercing the inner layer of dura mater, pierces the arachnoid at the same time, bends backwards above the sinus to middle the vallecula of the cerebrum by dividing into the anterior and end in cerebral arteries.

Throughout its course, it is surrounded by the *internal carotid plexus* of nerves derived from the internal carotid branch of the superior cervical ganglion of the sympathetic trunk.

Relations in Neck.—Enclosed in carotid sheath with jugular vein lateral to it, and vagus between and behind them. Ext. carotid is anterior and medial to it below, and separated from it above by styloid process, stylo-pharyngeus, glosso-pharyngeal n., pharyngeal branch of vagus and part of parotid gland.

Posterior :—Longus capitis ; sympathetic trunk ; superior laryngeal nerve ; pharyngeal veins.

Medial :—Pharynx ; ascending pharyngeal artery ; external and internal laryngeal nerves.

Lateral :—Vagus ; internal jugular vein.

Superficial : (A) *In carotid triangle*—Skin. Superficial fascia, with platysma, cervical branch of facial nerve and branches of anterior cutaneous nerve of neck. Deep fascia.

Sterno-mastoid overlaps it ; common facial and lingual veins, hypoglossal nerve and occipital artery cross it ; and descendens hypoglossi runs down over it.

(B) *Above carotid triangle*, it is crossed from below upwards by posterior belly of digastric, stylo-hyoid, posterior auricular artery ; and above that by the structures that separate it from external carotid. (*See above.*)

Near base of skull, it is nearly half an inch medial to posterior part of mandibular joint (tympanic plate and osseous part of pharyngo-tympanic tube intervening) ; cartilaginous part of tube and tensor palati are anterior ; levator palati is medial to it ; jugular vein, glosso-pharyngeal, vagus, accessory and hypoglossal nerves are posterior.

No branches in the neck.

Relations in Carotid Canal.—Tympanic cavity and cochlea are above and behind it ; trigeminal ganglion is above it. (*See also* p. 428.)

Relations in Cranial Cavity.—*See* p. 57.

External Carotid Artery.—A terminal branch of common carotid. Begins in the carotid triangle at the level of the upper border of the thyroid cartilage.

Runs upwards and slightly backwards and sidewards, passing either just behind the angle of mandible or under cover of it.

Ends behind the neck of the mandible opposite the lobule of the ear by dividing into the maxillary and superficial temporal arteries.

At first, it is in the carotid triangle on the side of the pharynx, antero-medial to the internal carotid, and is fairly superficial. It leaves the triangle by disappearing under the posterior belly of digastric and the stylo-hyoid and the lower part of parotid gland. Immediately above stylo-hyoid it enters so deep a groove in parotid gland that it is, in effect, inside the gland; and it ends either in the groove or after its emergence from the groove.

Relations.—Throughout, it is surrounded by the *external carotid plexus*, which is derived from external carotid branches of the superior cervical ganglion and sends off secondary plexuses around the branches of the artery.

In Carotid Triangle.—*Superficial*:—Skin. Superficial fascia, with platysma and cervical branch of facial nerve and branches of the anterior cutaneous nerve of the neck. Deep fascia.

Hypoglossal nerve and anterior division of posterior facial vein pass forwards across it; and the common facial and lingual veins backwards. Sterno-mastoid overlaps it.

Deep:—Inferior and middle constrictors of pharynx; external and internal laryngeal nerves.

Above Carotid Triangle.—*Superficial*:—Posterior belly of digastric; stylo-hyoid; parotid gland. And, while in the gland, posterior facial vein and the terminal branches of facial nerve.

Deep:—Internal carotid and pharynx, completely separated by the structures between the arteries—a portion of parotid gland, styloid process, stylo-pharyngeus, glosso-pharyngeal nerve and pharyngeal branch of vagus.

External carotid is now antero-lateral to internal carotid instead of antero-medial.

Branches.—Ascending pharyngeal; superior thyroid; lingual (p. 318); facial (pp. 267, 318); occipital (pp. 262, 281, 298); posterior auricular, and the two terminal branches—maxillary (p. 306) and superficial temporal (p. 261).

Ascending Pharyngeal Artery.—Small. Springs from the medial side of the root of external carotid. Runs up between the pharynx and internal carotid to the base of the skull.

Branches.—1. **Pharyngeal,** to pharynx and pharyngo-tympanic tube.

2. **Prevertebral,** to prevertebral muscles and lymph-glands.

3. **Meningeal** pass to the dura mater through anterior condylar canal and jugular foramen or foramen lacerum.

4. **Inferior tympanic** accompanies the tympanic nerve to the tympanum.

5. **Palatine,** when present, pierces pharyngo-basilar fascia and accompanies levator palati to the soft palate.

Superior Thyroid Artery.—Springs from the front of the external carotid. Usually near its root but may be higher up ; or it may come from the common carotid if that artery ends at a higher level than usual.

Runs with a curve first forwards and then downwards under cover of skin, fasciæ and the anterior edge of sterno-mastoid, on the fat that conceals the side of the pharynx and contains the external laryngeal nerve. Disappears under omo-hyoid and sterno-thyroid, where it encounters the top of the thyroid gland, and is distributed mainly to it by means of three terminal branches.

Branches.—1. **Infrahyoid artery** runs along the lower border of hyoid bone under cover of thyro-hyoid muscle.

2. **Superior laryngeal artery** disappears under the posterior border of thyro-hyoid, pierces the thyro-hyoid membrane, together with internal laryngeal nerve, and supplies mucous membrane, muscles and ligaments of larynx.

3. **Sterno-mastoid branch** crosses common carotid to enter the muscle.

4. **Crico-thyroid artery** runs forwards, over or under sterno-thyroid, over crico-thyroid muscle, to the anterior surface of crico-thyroid ligament, and anastomoses with its fellow.

5. **Terminal branches** supply thyroid gland and adjacent muscles.

Superior Thyroid Vein.—*See* p. 325.

Posterior Auricular Artery.—Small. Springs from the back of external carotid immediately above stylo-hyoid. Crosses stylo-hyoid and runs upwards and backwards along the upper border of the posterior belly of digastric where that belly overlies the carotid sheath ; and, here, the artery is deeply placed under the parotid gland and is not accompanied by its vein. Then, more superficially, it runs in company with its vein and the posterior auricular nerve, on the mastoid temporal behind the root of the auricle, where it ends in auricular and occipital branches.

Branches.—1. To parotid gland and adjacent muscles.

2. **Stylo-mastoid artery** enters stylo-mastoid foramen to ascend through the facial canal to the medial wall of tympanum.

3. **Auricular branch** supplies both surfaces of auricle.

4. **Occipital branch** supplies the scalp near the auricle.

Posterior auricular vein does not accompany the artery far, for it passes from behind the auricle on to the sterno-mastoid and helps to form the beginning of the external jugular vein.

Internal Jugular Vein.—Longest vein in the neck, and the right vein is usually wider than the left.

Begins in the jugular foramen opposite the lower margin of the external auditory meatus as a continuation of the sigmoid sinus.

Descends along the lateral side of the internal and common carotid arteries. When full of blood, it tends to overlap the arteries ; but both veins trend towards the right, and, at the lower part, the left vein overlaps the common carotid still more, while the right vein may be separated from the artery by an angular interval.

Ends by joining the subclavian to form the innominate vein behind the clavicle about an inch lateral to the sterno-clavicular joint on the right side and rather less on the left owing to the trend. The lowest part of the vein is therefore opposite the hollow between the heads of sterno-mastoid above the clavicle.

Dilated at its beginning. This dilated part is the **superior bulb**; it lies in the jugular fossa of the skull below the middle ear and tympanic antrum, and it adheres to the walls of the fossa. **Inferior bulb** is a much smaller dilated part near the lower end; and below this bulb there is a *valve*.

Relations.—Enclosed in carotid sheath with the vagus and internal and common carotids. Numerous lymph-glands lie along it, especially in front and laterally.

Posterior:—1. Rectus capitis lateralis; 2. Cervical transverse processes and certain muscles attached to them (longus capitis, levator scapulæ, scalenus medius and anterior). 3. Ascending cervical artery and anterior vertebral vein on the transverse processes. 4. Cervical plexus on scalenus medius and levator; and 5. phrenic nerve on scalenus anterior.

Lower down—6. Thyro-cervical trunk and its branches near their origins. 7. Vertebral vessels; and 8. first part of subclavian artery. And it ends on the front of—9. the cervical pleura. 10. Thoracic duct crosses behind the left vein at the level of the seventh vertebra.

Lateral:—Root of styloid process and facial nerve; roots of descendens cervicalis; lymph-glands; posterior part of sterno-mastoid. (The vein is easily found if one lifts up the posterior border of sterno-mastoid in the middle of the neck.)

Medial:—Vagus; internal and common carotid.

If a skull is examined, it will be seen that, at the beginning of the vein, the hypoglossal nerve is medial to it, and the 9th, 10th and 11th nerves and internal carotid artery are in front of it. But they all soon become medial.

Superficial:—Skin and fasciæ, and:—

(A) *Above carotid triangle*—parotid gland; posterior belly of digastric, posterior auricular artery; accessory nerve; styloid process and origins of stylo-hyoid and stylo-pharyngeus; meningeal branches of occipital artery.

(B) *In carotid triangle*—sterno-mastoid; lymph-glands; occipital artery; accessory nerve; sterno-mastoid branches of occipital artery; descendens cervicalis; sterno-mastoid branch of superior thyroid artery.

(C) *Below carotid triangle*—sterno-mastoid; anterior jugular vein; tendon of omo-hyoid and the nerve to its inferior belly; sterno-hyoid and sterno-thyroid.

Tributaries.—Inferior petrosal sinus at the jugular foramen; pharyngeal, lingual, common facial and superior thyroid in the carotid triangle; middle thyroid vein in the root of the neck.

It communicates with external jugular by a vein that bends round the anterior border of sterno-mastoid.

Subclavian Vein.—*See* p. 274.

Innominate Veins.—Have no valves. Each begins by the union of subclavian and internal jugular on the front of the pleura below the first part of subclavian artery **behind the clavicle,** about an inch lateral to the sterno-clavicular joint.

They end by joining each other to form the superior vena cava behind the lower edge of the first right costal cartilage at its junction with the manubrium. The left vein is therefore much longer than the right, as it has to cross behind the upper part of manubrium to reach the right vein.

In the neck, the **right** vein has clavicle and costo-clavicular lig., sterno-hyoid and sterno-thyroid *in front* of it; innominate artery is *medial*; vagus and cardiac nerves are *postero-medial*; phrenic nerve and internal mammary artery are *behind*; pleura and lung are *behind* and also *lateral*.

Its **tributaries** in the neck are subclavian, internal jugular, vertebral, first posterior intercostal, and either the right lymphatic duct or the mediastinal lymph-trunk.

Left vein is more oblique and has a longer course in the neck.

In front of it, there are: first, the clavicle; and, next, the sterno-clavicular joint separated by sterno-thyroid and sterno-hyoid.

Behind it: first, the internal mammary artery, phrenic nerve, pleura and lung; and, next, vagus and cardiac nerves and ascending part of subclavian artery; and it crosses the common carotid as it enters the thorax.

Tributaries in the neck: subclavian, internal jugular, vertebral, first posterior intercostal, and the thoracic duct.

Lymph-Trunks and Lymph-Ducts.—**Subclavian lymph-trunk** drains the lymph from the upper limb.

Jugular lymph-trunk drains the lymph from its own half of the head and neck.

Mediastinal lymph-trunk drains the lymph from the interior of its own half of the thorax.

On the right side, the subclavian trunk ends in the subclavian vein, jugular trunk in internal jugular and mediastinal trunk in the innominate vein. But the jugular and subclavian trunks may unite at the medial margin of scalenus anterior to form a vessel called the **right lymphatic duct,** which descends across the front of the first part of the subclavian artery to enter the beginning of the innominate vein.

On the left side, the mediastinal trunk usually ends in the innominate vein; the subclavian trunk may end in the subclavian vein; but they may all end in the thoracic duct in the root of the neck, and then the thoracic duct drains the lymph of both halves of the body below the diaphragm and the left half above the diaphragm.

Thoracic Duct.—Ascends into the neck on the left border of the œsophagus, having the subclavian artery in front of it, pleura lateral to it and longus cervicis behind it.

At the level of the seventh cervical vertebra it arches laterally above the pleura behind the common carotid artery, the vagus, cardiac nerves and internal jugular vein; in front of the sympa-

thetic trunk, vertebral vessels (sometimes between artery and vein) and inferior thyroid artery. It now turns downwards in front of the transverse cervical and suprascapular arteries, phrenic nerve and medial border of scalenus anterior, under cover of sterno-mastoid; it then bends more medially and descends in front of the subclavian artery to end in the commencement of the innominate vein. Before ending, it may break up into two or more channels which join the large veins separately.

Nerves in the Deep Part of Neck

Glosso-pharyngeal and its branches; vagus and its branches; accessory; hypoglossal and its branches; sympathetic trunk and its three cervical ganglia and their branches; cervical plexus and its branches; brachial plexus (p. 276).

Glosso-Pharyngeal Nerve.—Ninth cranial. Mixed. Supplies:—Stylo-pharyngeus; mucous membrane of posterior third of tongue (taste and common sensation), mucous membrane of tympanic cavity and of pharynx (including tonsil); parotid gland (in a roundabout way—*see* p. 302).

Motor and secretory fibres arise in medulla oblongata. Sensory fibres arise in two little ganglia on the nerve-trunk in the jugular foramen; their peripheral branches run on in the nerve; their central branches end in medulla oblongata.

Attached to the side of the uppermost part of medulla oblongata by a vertical row of 4 or 5 roots which pierce the pia mater and unite to form the nerve.

The nerve passes laterally across the jugular tubercle to the jugular foramen at the notch on its anterior margin directly below the internal auditory meatus; pierces the arachnoid and dura mater (carrying off a sheath); and descends through the jugular foramen into the neck.

In the neck, it descends between the internal jugular vein and internal carotid artery, deep to the styloid process and its muscles. Then, inclining forwards with the stylo-pharyngeus, it passes between the internal and external carotids, and, having escaped from under cover of stylo-pharyngeus at its posterior border, it curves forwards across the superficial surface of the muscle on to the side of the pharynx to enter the submandibular region under cover of the submandibular gland and the medial pterygoid muscle. In this region, it disappears under hyo-glossus and breaks up into its terminal branches.

Branches.—1. **Communicating branches** arise in jugular foramen and connect it with vagus and superior cervical ganglion.

2. **Tympanic nerve** arises in the lowest part of jugular foramen, enters a small hole on the ridge between jugular foramen and carotid canal, runs up through the *tympanic canaliculus* into the middle ear and breaks up on its medial wall to form a great part of the tympanic plexus.

3. **Nerve to stylo-pharyngeus** enters the muscle, supplies it, and

passes through it into the wall of the pharynx to ramify in the mucous membrane.

4. **Pharyngeal Branches.**—Two small branches pierce superior constrictor to reach the mucous membrane at once. A larger branch sends a filament to the carotid body and sinus, and joins other pharyngeal nerves to form the *pharyngeal plexus* on the middle constrictor before its fibres reach the mucous membrane.

5. **Terminal branches** supply the mucous membrane of the posterior third of the tongue, and also the mucous membrane of the soft palate, tonsil, front of epiglottis and the epiglottic folds.

Tympanic Plexus.—Lies under cover of the mucous membrane in grooves on the promontory of the medial wall of the tympanic cavity.

Formed by :—(1) Branches of tympanic nerve. (2) Filaments from the facial ganglion and greater superficial petrosal nerve. (3) Upper and lower **carotico-tympanic nerves,** which arise in the carotid canal from the sympathetic plexus on the internal carotid artery and pierce the wall of the canal to enter the middle ear. (4) a filament from nervus spinosus (p. 307).

The plexus gives branches to the lining membrane of the middle ear, pharyngo-tympanic tube, tympanic antrum and mastoid air-cells. Sends a root to the lesser superficial petrosal nerve through a small hole in front of the fenestra vestibuli. That root contains the secretory fibres of the glosso-pharyngeal for the parotid gland.

Vagus Nerve.—Tenth cranial. Mixed. Wide distribution.

Motor to heart, respiratory organs and many digestive organs.

Secretory to liver, pancreas, kidney, and glands in alimentary canal.

Sensory to dura mater, external auditory meatus and respiratory and digestive organs.

Motor and secretory fibres arise in medulla oblongata. Sensory fibres arise in two ganglia on the nerve-trunk—an upper in the jugular foramen and a lower just below the foramen. Their peripheral branches run on in the nerve ; their central branches end in the medulla oblongata.

Attached to the side of medulla oblongata below the ninth nerve by a vertical row of about 10 roots which pierce the pia mater and unite to form the nerve-trunk.

The nerve passes laterally across the jugular tubercle with the 9th and 11th nerves to the jugular foramen between the sigmoid and inferior petrosal sinuses, pierces the arachnoid and dura mater with the 11th nerve (carrying off a sheath common to these two nerves), and descends through the jugular foramen, in which the cranial part of accessory nerve joins it and is incorporated within it.

Having entered the neck, the vagus descends to the root of the neck in the carotid sheath between the posterior parts of the internal jugular vein and the carotid arteries, in front of longus capitis and longus cervicis ; and it has the same relations as those vessels.

At the root of the neck, the **right** vagus crosses in front of the first part of the subclavian artery and then inclines medially in the

fat behind the innominate vessels to enter the thorax and gain the right side of the trachea.

The **left** vagus, at the root of the neck, descends in front of the ascending part of the subclavian artery, postero-lateral to the common carotid, behind the internal jugular and innominate veins, and enters the thorax from behind the innominate vein.

Branches in Head and Neck.—Communicating; meningeal; auricular; pharyngeal; superior laryngeal; cardiac; and, on the right side, recurrent laryngeal.

Communicating branches connect it with the 9th, 11th and 12th nerves and with the superior cervical ganglion and the first cervical nerve.

The largest communication is the cranial part of accessory nerve, which gives to it the motor fibres for pharynx, larynx, soft palate and heart. The communication from the superior cervical ganglion brings visceral fibres to the vagus. If the communication from the anterior primary ramus of the first cervical is big, the descendens hypoglossi arises from the vagus.

Meningeal branch arises in the jugular foramen from the upper ganglion and supplies dura mater in the posterior cranial fossa.

Auricular branch also arises from the upper ganglion. Enters a minute hole in the lateral wall of the jugular fossa; runs transversely in the *mastoid canaliculus* across the back of the facial canal; emerges through a little hole in the tympano-mastoid fissure on the side of the skull immediately behind the external auditory meatus; supplies the skin of the back of the meatus, and then passes forwards between the cartilage and the bone of the meatus to supply the skin that lines the lower part of the meatus and tympanic membrane.

Pharyngeal branch arises from the lower ganglion. Runs downwards and forwards between the external and internal carotids to the side of the pharynx. Breaks up and unites with other nerves to form the pharyngeal plexus.

Superior laryngeal nerve also arises from the lower ganglion. Runs downwards and forwards between internal carotid and superior constrictor, and on to the middle constrictor, where it ends by dividing into the external and internal laryngeal nerves.

Internal laryngeal nerve passes downwards and forwards, first between external carotid and middle constrictor and then in the fat between the deep fascia and the thyro-hyoid membrane, where it falls in with the superior laryngeal artery and its vein. The nerve and vessels then disappear under the posterior border of thyro-hyoid, pierce the membrane, pass down between it and the mucous membrane of the pharynx and reach the larynx. The nerve supplies the mucous membrane of larynx down to the level of the vocal fold.

External laryngeal nerve gives a branch to the inferior constrictor and supplies the crico-thyroid—the only laryngeal muscle met with in the dissection of the neck. It runs downwards and forwards in the fat on the side of the pharynx deep to the external carotid and superior thyroid artery; disappears under omo-hyoid, sterno-

thyroid and thyroid gland, and passes off the inferior constrictor into the crico-thyroid.

Cardiac Branches.—Two arise from the vagus in the neck—one high up, the other low down—at inconstant points; and they descend with the vagus to the root of the neck.

On the right side, they pass behind the subclavian artery (sometimes in front), incline medially to reach the trachea and run over it to the deep cardiac plexus at its lower end.

On the left side, they descend with the vagus in front of the subclavian artery; the upper one leaves the vagus and runs over the trachea to the deep cardiac plexus; the lower one crosses the left side of the aortic arch in front of the vagus and ends in the superficial cardiac plexus on the end of the pulmonary trunk.

Right recurrent laryngeal nerve arises as the vagus crosses the subclavian artery. It hooks backwards below the artery and then upwards and medially between the artery and the pleura and behind the common carotid near its root, and reaches the groove between trachea and œsophagus.

The **left nerve** arises as the vagus crosses the left side of the arch of aorta. It curves medially below the arch to reach the groove between trachea and œsophagus. It is therefore already in the groove when it reaches the neck and does not have to pass behind the subclavian and carotid arteries.

In the neck, each nerve ascends either in the groove or on the side of the trachea, medial to the common carotid and thyroid gland, and in front of the inferior thyroid artery or behind it; and it passes under the lower border of the inferior constrictor to reach the larynx.

Branches.—**Cardiac** branches to the deep cardiac plexus as the nerve hooks round the subclavian artery or the aortic arch.

Tracheal and **œsophageal** branches.

Branches to **inferior constrictor.**

Laryngeal branches to all intrinsic muscles of larynx (except crico-thyroid) and to the mucous membrane up to the vocal fold.

Pharyngeal Plexus.—Lies on the middle constrictor under cover of the carotid arteries. It has some minute ganglia in it.

Formed by the pharyngeal branches of glosso-pharyngeal, vagus and superior cervical ganglion of sympathetic trunk.

Supplies the mucous membrane of pharynx, and the muscles of pharynx and soft palate (except stylo-pharyngeus and tensor palati and possibly levator palati and musculus uvulæ); muscular fibres come from the vagus and are probably derived from the accessory.

Lingual branch of vagus is a filament that arises from the plexus and passes laterally between carotids to join hypoglossal.

Accessory Nerve.—Eleventh cranial. Motor. Has two roots.

Cranial root is accessory to the vagus. It arises in the medulla oblongata and emerges through the side of the lower part of it as a vertical row of bundles that are in line with the roots of the vagus and the posterior roots of cervical nerves. They unite into one bundle which passes to the jugular foramen.

Spinal root arises in the upper five segments of the spinal cord

and emerges through the side of it as a vertical row of bundles. They unite into one cord which ascends through the foramen magnum and joins the cranial root.

The nerve-trunk pierces the arachnoid and dura mater at the jugular foramen with the vagus and descends with it through the jugular foramen; and, there, the cranial part separates off and unites with the vagus (p. 343).

The spinal part goes on as the accessory nerve in the neck, and it supplies the greater parts of sterno-mastoid and trapezius.

It first descends vertically between the internal jugular vein and internal carotid artery, under cover of the parotid gland, styloid process, posterior auricular artery and posterior belly of digastric, till it reaches a point midway between the angle of the mandible and the mastoid process. It then runs downwards and backwards across the upper angle of the carotid triangle to reach sterno-mastoid. As it crosses, it is superficial to the internal jugular vein, is overlapped by sterno-mastoid, is crossed by the occipital artery, is accompanied by the upper sterno-mastoid branch of occipital artery, and is surrounded by lymph-glands.

It then pierces sterno-mastoid; and, either before or after it enters the muscle, it communicates with the branch of the second cervical nerve which also supplies the muscle. It emerges through the posterior border of sterno-mastoid a little above its middle; passes downwards and backwards across the posterior triangle imbedded in the deep fascia of its roof, parallel to the fibres of levator scapulæ, from which it is separated by some fat; disappears under trapezius about two inches above the clavicle; and ramifies on the deep surface of trapezius—communicating with the branches from the 3rd and 4th cervical which also supply the muscle.

Hypoglossal Nerve.—Twelfth cranial. Motor to muscles of the tongue.

Arises in medulla oblongata and emerges through the front of its upper half as a vertical row of bundles which pierce the pia mater and unite to form two roots.

The roots run laterally to the anterior condylar canal, pierce the arachnoid and dura mater as separate bundles and unite as they leave the canal.

In the neck, it is at first lateral to the atlanto-occipital joint and medial to the internal jugular vein, but soon inclines laterally to reach the vagus between the vein and internal carotid; twists round behind and lateral to the vagus to gain the front of it, and then descends between the big vessels, deep to the parotid gland, styloid process and posterior belly of digastric.

At the lower border of the posterior belly, it enters the carotid triangle and emerges from between the vein and artery; it then curves forwards through the triangle into the submandibular region (pp. 298, 320).

Branches.—Communicating; meningeal; muscular to infra-hyoid muscles, genio-hyoid and muscles of tongue.

Communicating branches connect it with the vagus and superior

cervical ganglion and first cervical nerve. The chief is the branch which it receives from the anterior primary ramus of the first cervical nerve. That branch conveys into it the fibres of its meningeal branch and its descendens branch and the branches to thyro-hyoid and genio-hyoid.

Meningeal branch arises in the anterior condylar canal and supplies the dura mater near the foramen magnum.

Descendens hypoglossi arises as the hypoglossal emerges from between the jugular vein and carotid artery at the lower border of the digastric. It runs downwards over the internal carotid on to the common carotid, deep to the vessels that cross these arteries in the carotid triangle; and it ends by joining the end of descendens cervicalis to form a loop called the ansa hypoglossi.

Ansa hypoglossi lies on the common carotid under cover of sterno-thyroid opposite the lower part of the larynx. It gives branches to sterno-hyoid, sterno-thyroid and both bellies of omo-hyoid. The branches to sterno-hyoid and sterno-thyroid run down to enter the muscles near their lower ends.

Nerve to thyro-hyoid arises as the hypoglossal crosses the lingual artery. It runs downwards and forwards across the hyoid bone near its tip, under the deep fascia, and enters the muscle near its posterior border.

Nerve to genio-hyoid arises in the submandibular region and runs downwards and forwards between mylo-hyoid and genio-glossus into the muscle.

Nerves to the tongue supply: (1) stylo-glossus, hyo-glossus and genio-glossus (*i.e.* the extrinsic muscles except palato-glossus), and these branches arise in the submandibular region; and (2) the intrinsic muscles of tongue, and these branches arise after the terminal branches of the hypoglossal have penetrated genio-glossus and entered the tongue.

Sympathetic trunk extends from the second cervical vertebra to the coccyx, one inch from the median plane throughout and, for the most part, in relation to the front of the vertebral column.

In the neck, it is opposite the roots of transverse processes of the lower six cervical vertebræ, and it enters the thorax by descending across the front of the neck of the first rib. It lies on longus capitis and longus cervicis, behind the internal and common carotid arteries, imbedded in the posterior wall of the carotid sheath. The inferior thyroid artery crosses behind it at the level of the cricoid cartilage and sixth vertebra (sometimes in front of it or through it); and, below that, the trunk is close by the medial side of the vertebral artery. On the left side, the thoracic duct crosses in front of it at the level of the seventh vertebra.

The trunk has three ganglia in the neck—superior, middle and inferior and its branches arise from them. (*See also* p. 577.)

Superior Cervical Ganglion.—An inch long. Spindle-shaped. Lies behind internal carotid on longus capitis opposite the second and third vertebræ.

Communications.—With 9th, 10th and 12th cranial nerves.

Branches.—*Grey rami communicantes* pass behind the vagus to

join the anterior primary rami of the upper four cervical nerves as they lie between transverse processes.

Internal carotid nerve springs from the upper end of the ganglion and breaks up to form the internal carotid plexus around the internal carotid artery (pp. 58, 336).

External carotid nerves form a plexus around the external carotid artery from which secondary plexuses are given to its branches.

Pharyngeal branch runs down over the side of the pharynx to take part in the pharyngeal plexus (p. 344).

Superior cardiac nerve descends along the carotid arteries to the root of the neck. *Left nerve* continues down along the common carotid into the thorax, crosses the left side of the aortic arch and ends in the superficial cardiac plexus. *Right nerve* crosses the subclavian artery (either in front or behind) and then runs along the back of the innominate artery to the trachea, and along it to the deep cardiac plexus.

Middle Cervical Ganglion.—"Pin-head" size. Lies behind common carotid on the inferior thyroid artery opposite the cricoid cartilage.

Branches.—*Grey rami communicantes* pass between the slips of origin of longus capitis and scalenus anterior to join the anterior primary rami of c. 5 and 6.

Thyroid branches accompany the inferior thyroid artery to the thyroid gland.

Middle cardiac nerve runs down along the common carotid and, after reaching the trachea, ends in the deep cardiac plexus. *Left nerve* passes obliquely through the fat between carotid and subclavian arteries to reach the trachea. *Right nerve* accompanies the superior nerve.

Ansa subclavia descends along the lateral side of the common carotid, crosses in front of the first part of subclavian, curves backwards below subclavian and upwards behind it to end in the inferior ganglion. It gives filaments to the subclavian artery and its branches, and it communicates with the phrenic nerve.

Inferior Cervical Ganglion.—Size of a small pea, but irregular. Lies behind the common carotid artery and partly tucked in behind the vertebral artery, between the seventh cervical transverse and the neck of the first rib, and therefore in front of the 8th cervical nerve and just above the pleura. May extend down behind the pleura in front of the neck of the first rib to join the first thoracic ganglion at the medial side of the superior intercostal artery.

Branches.—*Grey rami communicantes* pass to the anterior primary rami of c. 7 and 8—either directly as they lie above and below the seventh transverse process or through the scalenus anterior to reach them farther laterally.

Vertebral branches form a plexus around the vertebral artery.

Inferior cardiac nerve accompanies the middle nerve to the deep cardiac plexus.

Subclavian filaments join branches of the ansa in the plexus around the subclavian artery.

Cervical Plexus.—Formed by the anterior primary rami of the upper four cervical nerves.

Lies on the transverse process of atlas and on scalenus medius, overlapping the origin of levator scapulæ. It is behind the fascia on these muscles and behind the internal jugular vein and sterno-mastoid in the upper part of the neck, opposite a line drawn from the mastoid process towards the tip of the shoulder but stopping at the level of the upper border of the thyroid cartilage.

The four nerves increase rapidly in size from above downwards and unite with each other to form a looped plexus. The **first** nerve runs down over the front of the transverse process of atlas on to scalenus medius to unite with the **second**; they descend together to unite with the **third,** which is connected by a strong loop with the **fourth**; and the cervical plexus is connected with the brachial plexus by a branch which the fourth sends to the fifth. (*See also* p. 556.)

Branches.—Communicating, cutaneous, muscular.

Communicating Branches.—1. Grey rami communicantes from superior cervical ganglion.

2. Branch from c. 1 to hypoglossal (p. 346).

3. The branch of c. 2 to sterno-mastoid and the branches from c. 3 and 4 to trapezius communicate with accessory.

Cutaneous Branches (*see* pp. 261, 275).—Lesser occipital; great auricular; anterior cutaneous of neck; supraclavicular.

Muscular Branches (including branches from the roots of brachial plexus):—

To rectus capitis anterior and rectus capitis lateralis from c. 1.
To longus capitis from c. 1-4.
To sterno-mastoid from c. 2.
Descendens cervicalis from c. 2 and 3 (p. 298).
To intertransverse muscles from c. 2-8.
To levator scapulæ and trapezius from c. 3 and 4.
Phrenic from c. 3, **4** and 5.
To longus cervicis from c. 3-8.
To scalenus medius from c. 3-7.
To scalenus anterior from c. 4-7.
To scalenus posterior from c. 5-7.

Phrenic Nerve.—Arises from the 3rd, **4th** and 5th cervical anterior rami, at the lateral margin of scalenus anterior, on scalenus medius, opposite the middle of the sterno-mastoid at the level of the upper border of the thyroid cartilage.

It descends over scalenus anterior, deep to sterno-mastoid, overlapped by the internal jugular vein; crossed superficially by omo-hyoid, transverse cervical artery and suprascapular artery, in that order from above downwards. It is deep also to the fascia that clothes scalenus anterior; and it gradually crosses the muscle from lateral to medial border.

Immediately below the level of the subclavian artery, the **right nerve** passes off scalenus anterior on to the pleura, behind the innominate vein, and crosses the internal mammary artery from lateral to medial side, usually in front of it, but often behind it; leaves the back of the innominate vein to enter the thorax, on the lateral side of the vein, between it and the pleura, a little behind the first

cartilage, and accompanied by the pericardiaco-phrenic artery, which arises from the internal mammary in the root of the neck.

Left nerve differs from the right in that:—1. It leaves scalenus anterior at a higher level and crosses the first part of subclavian artery at the medial margin of scalenus anterior, and therefore crosses the mammary artery either not at all or very near its origin.

2. It is crossed by the thoracic duct.

3. It is behind the end of the subclavian vein before it passes behind the innominate.

4. It enters the thorax in front of the ascending part of subclavian artery, after escaping from under cover of the innominate vein.

On each side, the root from the 5th nerve may descend into the thorax before it joins the other roots; and it may arise from the nerve to subclavius instead of directly from c. 5.

The main root (from c. 4) arises in common with the branch that the fourth sends down to the fifth.

Muscles of Soft Palate.—*See Palate*, p. 616.

Muscles of Pharynx.—*See Pharynx*, p. 623.

Muscles of Larynx.—*See Larynx*, p. 597.

Muscles of Orbit.—*See Orbit*, p. 67.

THORAX

Boundaries (p. 26).

Inlet (pp. 26, 328); **outlet** (p. 26).

WALLS OF THORAX

A framework of bones and cartilages (p. 26), joints and ligaments (pp. 119, 125), clothed and supplemented by muscles and membranes with their nerves and vessels.

Landmarks to be Identified.—Upper margin of manubrium; sternal angle; xiphi-sternal joint; sterno-clavicular joint. Costal cartilages: 2, 7, 9, 10. Ribs: 3, 4, 7, 12. Thoracic spines: 1, 3, 7, 12.

Muscles and Membranes

Extrinsic Muscles.—Are muscles of the head, neck, back, abdomen and upper limb that are attached to the framework of the thorax or overlie it without attachment.

Longus cervicis attached to the front of the bodies of the upper three or four thoracic vertebræ. Sternal head of *sterno-mastoid* to the front of manubrium; and *sterno-hyoid* and *sterno-thyroid* to

the back of it (and sterno-thyroid also to the back of the first cartilage). *Scalenus anterior* and *medius* to the first rib and *scalenus posterior* to the second.

Serratus posterior superior to spines and the upper four ribs. *Serratus posterior inferior* to spines and the lower four ribs. Divisions of *sacro-spinalis* and other *deep muscles of the back* to spines, transverse processes and ribs.

Rectus abdominis to the seventh, sixth and fifth costal cartilages. *Obliquus externus abdominis* to the lower eight ribs. *Quadratus lumborum* to the twelfth rib. Upper ends of *psoas major* and *minor* to the twelfth thoracic vertebra.

Trapezius to all thoracic spines. *Latissimus dorsi* to the lower six spines and the lower three or four ribs. The *rhomboids* to the upper spines. *Pectoralis major* to the front of the sternum and upper six costal cartilages. *Subclavius* to the first rib and cartilage. *Pectoralis minor* to the third, fourth and fifth ribs near their cartilages. *Serratus anterior* to the upper eight ribs farther back. *Other scapular muscles*, though not attached to the thorax, overlie it.

The exterior of the thorax is wholly covered with extrinsic muscles except at three places:—(1) The median line of the sternum. (2) The median line of the back. (3) When the scapula is drawn forwards, a small triangle on the back opposite the sixth and seventh ribs medial to the lower part of the scapula bounded by trapezius, latissimus dorsi and rhomboideus major. (*See also* p. 172.)

Intrinsic Muscles and Intercostal Membranes.—Intercostals; transversus thoracis; levatores costarum. Anterior and posterior intercostal membranes.

Intercostales.—Two in each of the eleven intercostal spaces. They are supplied by intercostal nerves; and they elevate ribs.

External intercostals lie in the same plane as obliquus externus abdominis. Each **arises** from lower border of rib above. Its fibres are directed downwards and forwards to be **inserted** into upper border of rib below. It extends from tubercle of rib to junction of rib and cartilage, where it is continuous with **anterior intercostal membrane**, which extends to the side of the sternum.

Internal intercostals lie in the same plane as obliquus internus abdominis, and those of lowest two spaces are continuous with it. Each **arises** from the costal cartilage and the upper margin of the costal groove of the rib above. Its fibres are directed downwards and backwards to the upper border of the rib below. It extends from the side of the sternum to the angle of the rib, where its border is free, except for a loose connexion with retropleural fibrous tissue. Its inner surface is in contact with pleura, except, in the lower spaces, where it is in contact with the diaphragm.

In some bodies the internal intercostal is, to a varying extent,

divided into two strata. The deeper stratum is called the *innermost intercostal* muscle or *intercostalis intimus*.

Posterior intercostal membrane, which replaces int. intercostal, is attached medially to sup. costo-transverse ligament, and laterally it slips in between ext. and int. intercostals and soon fades away.

Transversus thoracis lies in the same plane as transversus abdominis, and is divided into three parts—sterno-costalis, the innermost intercostals and the subcostals.

The **sterno-costalis** is a series of thin, flat slips that **arise** by tendinous and fleshy fibres from the xiphoid process and the lower three pieces of the body of the sternum; they radiate to their **insertion** into the 6th, 5th, 4th, 3rd and 2nd costal cartilages, close to their junction with ribs. **Nerves :** corresponding intercostals.

It separates int. mammary vessels from pleura.

It depresses costal cartilages in forced expiration.

The **subcostals** are small slips found on the inner surfaces of the lower ribs near their angles. They have the same direction as internal intercostals, but they pass over several ribs.

Levatores Costarum.—12 small, fan-shaped muscles in series with external intercostals, and found in the deepest part of the dissection of the back. **Arise** by their apices from transverse processes, from 7th cervical to 11th thoracic vertebra. **Inserted** into the ribs medial to their angles. **Nerves :** intercostals.

Nerves of Walls of Thorax

Thoracic nerves and their branches; sympathetic trunk with its ganglia and their branches.

THORACIC NERVES.—Like other spinal nerves, each thoracic nerve is attached to the spinal cord by two roots—anterior and posterior.

Anterior root is made of bundles of **motor** fibres that arise in the grey matter of the cord and emerge through the front of it.

Posterior root is made of bundles of **sensory** fibres that arise in the **spinal ganglion** which is placed on the root in the intervertebral foramen. Each fibre, while still in the ganglion, divides into a central branch and a peripheral branch. *Peripheral branches* run into the nerve-trunk and its branches. *Central branches* form the posterior root. They enter the cord through the floor of a narrow groove on the back of it, and they end in the grey matter of either the cord or the medulla oblongata.

The two roots unite just lateral to the ganglion, in the intervertebral foramen, to form the nerve-trunk and mingle the motor and sensory fibres.

The **nerve-trunk** is very short, for it divides almost at once into an anterior and a posterior primary ramus, each of which contains both motor and sensory fibres. But, before the trunk divides, it sends a **meningeal branch** inwards to supply the meninges and vessels of the spinal cord.

Posterior primary ramus emerges from the intervertebral foramen, passes backwards between transverse processes and divides into lateral and medial branches which supply the skin and the deep muscles of the back. In the upper half of the body, the **cutaneous nerve** comes from the medial branch and pierces the deep fascia about a thumb's breadth from the median plane; in the lower half, it comes from the lateral branch and pierces the fascia a hand's breadth from the median plane.

Anterior primary ramus is larger; and in the 2nd-11th it is an intercostal nerve.

TYPICAL INTERCOSTAL NERVE.—Emerges from the intervertebral foramen, and, as it does so, it is crossed anteriorly from below upwards by the posterior intercostal artery (with its vein) and thereafter lies below them, so that the order from above downwards in an intercostal space is vein, artery, nerve.

In the posterior part of the space, the nerve and vessels are below the rib, behind the pleura, in front of the superior costo-transverse ligament and posterior intercostal membrane, and are accessible from the back without injury to the rib.

At the angle of the rib, they slip in between the internal and external intercostal muscles and enter the costal groove; on the side of the chest, they are therefore under shelter of the lower part of the rib.

But the nerve gradually pierces the internal intercostal muscle so that, on the front of the chest near the costal cartilage, it is behind the muscle on the front of the pleura. Along the lower edge of the cartilage, it is in front of sterno-costalis also; and, half an inch from the sternum, it crosses in front of the internal mammary vessels.

At the edge of the sternum, it passes forwards through the internal intercostal muscle, anterior intercostal membrane, pectoralis major and the deep fascia, and becomes the **anterior cutaneous branch.**

Branches.—Rami communicantes; muscular; collateral; lateral cutaneous and anterior cutaneous.

1. As the intercostal nerve emerges from the intervertebral foramen, it sends a **white ramus communicans** forwards to the sympathetic trunk, and it receives a **grey ramus communicans** from it.

2. **Muscular twigs** arise throughout its course.

3. A **collateral branch** (not always present) arises at or near the angle of the rib, runs forwards along the upper border of the rib below, gives branches to intercostal muscles, and either ends as one of these branches or rejoins the main trunk.

4. **Lateral cutaneous branch**—thicker than what is left of the trunk—arises at or near the angle and runs forwards between the intercostal muscles till about half way round the chest. It then passes through the external muscle, and divides into anterior and posterior branches under cover of serratus anterior (or obliquus externus abdominis if below the seventh). These branches come through the muscle or appear between its digitations, pierce the deep fascia and supply the skin of the side of the trunk—the anterior branches sweeping forwards over pectoralis major and

obliquus externus and the posterior branches backwards over latissimus dorsi.

5. **Anterior cutaneous branch** is the terminal part of the nerve. It divides into a small medial branch and a larger lateral branch which pass medially and laterally to supply skin of the front of the trunk.

Only four of them are wholly typical—3, 4, 5 and 6.

First thoracic anterior ramus is a thick nerve, but the first intercostal space is short and requires only a small nerve. The first therefore gives off a small intercostal nerve and then passes obliquely upwards and sidewards across the first rib at the junction of its neck and shaft to join the brachial plexus. Further, the first intercostal nerve runs along the pleural surface of the first rib and does not enter the space till near the costal cartilage; it has no lateral cutaneous branch; and its anterior cutaneous is absent or very small, for the supra-clavicular nerves supply skin of the chest down to the level of the second cartilage.

Second intercostal sends a communicating branch to the first anterior ramus to be carried into the brachial plexus. And its lateral cutaneous branch (*intercosto-brachial nerve*) is distributed not to skin of the chest but to skin of the floor of axilla and skin of the medial side and back of upper arm.

Seventh to **eleventh** run part of their course in the wall of the abdomen. At the line where costal cartilages begin to bend upwards, the nerves leave the intercostal spaces, pass deep to the cartilages between the digitations of the diaphragm, and enter the wall of abdomen between transversus and obliquus internus abdominis.

Twelfth is not intercostal but **subcostal**, and runs nearly its whole course in the walls of the abdomen. In its short course in the thorax, it runs obliquely behind the psoas major and then in front of quadratus lumborum (the parts of these muscles that are above the arcuate ligaments are in the thorax); and it enters the abdomen from behind the lateral arcuate ligament.

DISTRIBUTION.—Muscles :—**Posterior primary rami** supply the deep muscles of the back and sacro-spinalis.

Each **intercostal** supplies intercostal muscles; and it sends a branch back through the posterior intercostal membrane and external intercostal muscle to a levator costæ. In addition:

Second to *sixth* supply sterno-costalis; and a variable number supply the subcostal muscles.

Serratus posterior superior is supplied by the *upper three or four* and serratus posterior inferior by the *lower four*.

Lower five and **subcostal** supply obliqui and transversus and rectus abdominis—and the subcostal supplies pyramidalis also.

Mammary Gland :—Receives filaments from 4, 5 and 6.

Skin :—*Cutaneous branches* of **posterior primary rami** supply the skin of the back down to the iliac crest—loin as well as chest.

Lateral cutaneous branches of **intercostals** supply skin of axilla and upper arm and skin of the side of the trunk down to the iliac crest;

and the **subcostal** sends its lateral cutaneous branch down into the gluteal region.

Anterior cutaneous branches of 2-6 supply the skin of the front of the chest below the level of the second cartilage. 7-12 supply the front of abdomen from xiphi-sternal joint almost to the pubis.

The lateral cutaneous branches droop down to the level of the anterior branches before they reach the skin; and so do the cutaneous branches of the posterior rami. Therefore, although the general course of an intercostal nerve has the same obliquity as a rib yet the belt of skin supplied by a thoracic nerve is a horizontal strip at the level of the anterior cutaneous branch.

Sympathetic Trunk.—A long, slender cord that resembles a knotted string because of the ganglia on it. Extends from the second cervical vertebra to the coccyx, one inch from the median plane throughout; and, for the most part, it is related to the front of the vertebral column.

Enters the thorax from the neck by descending across the front of the neck of the first rib at the medial side of the superior intercostal artery. Descends through the thorax and leaves it to enter the abdomen by passing behind the medial arcuate ligament at the anterior edge of psoas major.

In the upper part of thorax, the vertebral bodies are not wide enough to reach the trunk, and the trunk is related to ribs—on the necks of the first and second and on the heads and radiate ligaments of others—till, at any level between the fifth and the tenth, the bodies become wide enough for the trunk to lie on their sides. It is under cover of the pleura throughout; and it is in front of intercostal vessels from the third downwards.

Branches.—Rami communicantes; aortic and œsophageal; cardiac and pulmonary; and three splanchnic nerves.

They arise from the **ganglia**, of which there are 12 typically—one for each vertebra. But neighbouring ganglia may fuse; and the first may be fused with the inferior cervical on the front of the neck of the first rib.

1. A **grey ramus communicans** of non-medullated fibres arises in a ganglion and passes back to each anterior primary ramus. White rami communicantes are sent to the ganglia from the anterior rami (from 2nd thoracic to 2nd lumbar inclusive); they are made of medullated fibres that arise in the spinal cord. The upper rami communicantes are very short; the lower ones are longer, and they cling to the sides of the vertebral bodies alongside intercostal vessels.

2. **Aortic** and **œsophageal** filaments arise from the upper five ganglia.

3. **Cardiac** and **pulmonary nerves** are filaments that arise from 2nd, 3rd and 4th ganglia, slant downwards over vertebral bodies to the œsophagus and over it to the trachea, and they end in the deep cardiac plexus on the end of the trachea and the posterior pulmonary plexus on the back of the bronchus.

4. **Greater splanchnic nerve** runs down in front of the lower vertebral bodies and intercostal vessels close by the lateral side of the azygos vein or the inferior hemiazygos, and pierces the crus of diaphragm to enter the abdomen, where it ends in the cœliac ganglion. It arises from 5, 6, 7, 8, 9 ganglia by five long roots that pass downwards and forwards over the bodies and intercostal vessels to the side of the vein. Filaments pass to the plexuses on aorta and œsophagus from the greater splanchnic nerve and from a **splanchnic ganglion** placed on it opposite the 11th thoracic vertebra.

5. **Lesser splanchnic nerve** arises from 10th and 11th ganglia, pierces the crus and ends in the cœliac ganglion.

6. **Lowest splanchnic nerve** is seldom found. Springs from 12th ganglion, pierces crus and ends in the renal plexus.

Though the splanchnic nerves appear to spring from ganglia, most of their fibres come from white rami communicantes.

Vessels of Walls of Thorax

Internal mammary artery and its branches; posterior intercostal arteries; subcostal artery.

Anterior and posterior intercostal veins; subcostal vein; internal mammary veins; vena azygos; superior and inferior hemiazygos veins.

Internal Mammary Artery.—Arises in the root of the neck from the first part of subclavian artery. Runs downwards, forwards and medially over the front of the pleura behind the large veins and the clavicle, and enters the thorax behind the first costal cartilage.

In the thorax, it runs downwards about half an inch from the edge of the sternum, and it ends behind the 6th intercostal space by dividing into the musculo-phrenic and superior epigastric.

Behind it, the pleura down to the 3rd cartilage; below that, the sterno-costalis separates it from pleura more or less completely. *In front of it*, the upper 6 costal cartilages; and, between each two cartilages, the intercostal nerve, internal intercostal muscle and anterior intercostal membrane. And in front of cartilages and spaces there are pectoralis major, fasciæ and skin.

Venæ comitantes (formed by the union of the companion veins of musculo-phrenic and superior epigastric arteries) run along the sides of the internal mammary artery, till, at a variable point near the 3rd cartilage, they unite into a single vein that runs up along the medial side of the artery and ends in the innominate vein at the inlet of thorax.

Branches.—Pericardiaco-phrenic; mediastinal; intercostal; perforating; terminal—superior epigastric and musculo-phrenic.

Pericardiaco-phrenic—long and very slender. Arises in the root of the neck and accompanies the phrenic nerve to the diaphragm, giving branches to pericardium and parietal pleura on the way.

Mediastinal are small, irregular branches to fat, thymus and front of pericardium.

Anterior intercostal—two for each of the upper six spaces—

pierce the internal intercostal muscle and anastomose with the posterior intercostal and its collateral branch.

Perforating branches accompany the anterior cutaneous nerves; those in the 2nd, 3rd and 4th spaces are big in women, for they help to supply the mammary gland.

Superior epigastric runs down behind 7th costal cartilage, passes between the sternal and costal slips of diaphragm and enters the sheath of rectus abdominis.

Musculo-phrenic runs downwards and sidewards behind the 7th cartilage, passes between the slips of diaphragm from the 7th and 8th cartilages, and runs along the deep surface of the costal margin over the abdominal surface of the diaphragm as far as the 10th rib, or farther.

Gives *branches* to diaphragm and anterior wall of abdomen, and sends two **anterior intercostal arteries** into each of the 7th, 8th and 9th spaces. (The 10th and 11th spaces do not come far enough forwards to require anterior arteries.)

POSTERIOR INTERCOSTAL ARTERIES.—Two sources :—

1. From superior intercostal branch of costo-cervical trunk for the upper two spaces.
2. From descending thoracic aorta for the lower nine spaces.

The most important practical points about the relations of intercostal vessels are :—(1) At the back, they are between ribs and are therefore accessible. (2) On the side, they are under shelter of the lower part of the rib and are liable to be torn when the rib is broken.

Costo-cervical trunk springs from the second part of subclavian, arches upwards and backwards over the top of the pleura to reach the neck of the first rib, and divides there into the deep cervical and superior intercostal; and the **deep cervical** passes backwards above the rib to the muscles of the back of the neck.

Superior Intercostal Artery.—Arises from costo-cervical trunk at the neck of the first rib. Descends across the front of it behind the pleura, with sympathetic trunk on its medial side and the anterior primary ramus of the first thoracic nerve on its lateral side. Gives off the **first posterior intercostal artery**, and then descends across the front of the neck of the second rib to become the **second posterior intercostal.**

Lower Nine Posterior Intercostal Arteries (Aortic Intercostals).—Spring from the back of descending aorta and pass over the front and sides of vertebræ towards intercostal spaces.

Upper four or five pairs have to ascend to reach their spaces, because the descending aorta begins only at the lower border of 4th vertebra; those of the right side are longer, because the descending aorta begins on the left side of the vertebral column.

Those of the right side all pass behind thoracic duct and vena azygos; and the upper five are behind œsophagus also.

On the left side, the upper five or six pass behind the superior hemiazygos vein; the lower three or four pass behind the inferior hemiazygos vein.

On both sides, beyond the veins, they lie under cover of pleura, and the lower six are behind the splanchnic nerves and their roots.

Each then passes onwards behind sympathetic trunk to its space; crosses in front of the intercostal nerve from below upwards, and passes laterally on the pleural surface of the superior costo-transverse lig. and posterior intercostal membrane, with the vein above, the nerve below; reaches the angle of the rib, where it slips in between external and internal intercostal muscles; proceeds forwards in the costal groove; and ends by anastomosing with the upper of the two anterior intercostal arteries of the space—except in the lowest two spaces, where it is very small and accompanies the intercostal nerve into the abdominal wall between obliquus internus and transversus abdominis.

Branches.—Irregular *muscular*; to *mammary gland* from the upper four; *right bronchial* (p. 608) from the first; posterior branch; collateral branch; lateral cutaneous branch.

Posterior branch arises as soon as the artery reaches the intercostal space. It passes backwards between the vertebra and the superior costo-transverse ligament, sends a *spinal branch* through the intervertebral foramen into the vertebral canal, and then accompanies the posterior primary ramus to the muscles and skin of the back.

A **collateral branch** arises from each of the upper seven (*i.e.* in 3rd to 9th spaces) near the angle of the rib. It runs along the upper border of the rib below; and it ends by anastomosing with the lower of the two anterior intercostals.

The **lateral cutaneous branch** accompanies the lateral cutaneous branch of the intercostal nerve.

Subcostal Artery.—Springs from the back of the lowest part of thoracic aorta.

The **right** artery curves backwards over the body of the twelfth thoracic vertebra on to quadratus lumborum, running behind thoracic duct, vena azygos, splanchnic nerves, sympathetic trunk, pleura and diaphragm, with subcostal vein above and the nerve below; and it passes behind the lateral arcuate ligament into the abdomen.

The **left** artery differs only in that it is behind the inferior hemiazygos vein instead of thoracic duct and azygos vein.

Anterior Intercostal Veins.—Two in each of the upper nine spaces. Run with the arteries in the anterior parts of the spaces. End in internal mammary and musculo-phrenic veins.

Posterior Intercostal Veins.—One above each posterior intercostal artery in the space, and (except the first) on the side of the vertebral body.

Receive tributaries that correspond to the branches of the arteries, including veins from the contents of the vertebral canal.

Differ on the two sides in their mode of termination.

Right Side.—**First** passes upwards over the front of the neck of the first rib alongside the superior intercostal artery (often cross-

ing in front of the artery from lateral to medial side), arches forwards over the top of the pleura to end in the innominate vein (or the vertebral vein) in the root of the neck.

Second and **third** unite to form the **right superior intercostal vein,** which slants downwards and forwards over the third and fourth vertebræ to join vena azygos as it leaves the vertebral column.

Fourth to **eleventh** and the **subcostal vein** end in vena azygos.

Left Side.—**First** is like that of the right side.

Second and **third** form the **left superior intercostal vein,** which slants down over the third and fourth vertebræ to reach the end of aortic arch, and then upwards and forwards over the left side of the arch to end in the left innominate vein above the arch. It communicates with the superior hemiazygos vein and may end in it.

Fourth to **eighth** end in superior hemiazygos.

Ninth, tenth and **eleventh** and the **subcostal vein** end in inferior hemiazygos.

Vena Azygos.—Extends from one vena cava to the other. Arises from the back of inferior vena cava at the level of the renal vein. Runs obliquely upwards on the tendinous part of the right crus of diaphragm behind the renal artery; passes off the crus on to its medial side and enters the thorax through the aortic opening of diaphragm. (Occasionally, its abdominal part is atrophied. It then begins in the thorax on the twelfth thoracic vertebra by the union of the right subcostal vein and ascending lumbar vein.)

In the thorax it runs upwards on the front of the backbone to the disc between the fifth and fourth thoracic vertebræ, where it leaves the backbone and arches forwards above the root of the lung to enter the back of superior vena cava just above the pericardium opposite the second right costal cartilage.

In its upward course, the right subcostal and intercostal arteries cross *behind* it. Descending aorta is to *its left*, separated by thoracic duct. Splanchnic nerves and pleura are to its *right*. *In front*, there are first the diaphragm and then the œsophagus.

The **arch** of vena azygos has the root of the lung *below* it; œsophagus, vagus and lower end of trachea *medial to* it; pleura and lung *lateral to* it; and it grooves the lung so deeply just above the hilum that pleura and lung are also *above* it. (*See also* p. 442.)

Tributaries. Correspond to a large extent to branches of descending aorta.

1. *Œsophageal* and *pericardial.*
2. *Phrenic,* from posterior part of diaphragm.
3. *Mediastinal,* from fat and lymph-glands in posterior mediastinum.
4. *Right bronchial,* from the lung.
5. *Upper two right lumbar* (occasionally).
6. *Right subcostal* and the lower eight *intercostal.*
7. *Right superior intercostal,* from the third and second spaces.
8. *Superior* and *inferior hemiazygos* veins bring blood to it from the left side, including the lower eight spaces.

Hemiazygos Veins (p. 609).—Lie close along the left side of the

descending thoracic aorta, and at the 8th and 9th vertebræ they cross behind it and the thoracic duct to end in the azygos vein.

CAVITY OF THORAX.—*See* **Pleuræ, Mediastinum, Lungs: Heart** and **Pericardium: Great Vessels**, pp. 423, 441.

ABDOMEN

ANTERIOR WALL OF ABDOMEN

Includes the side-wall between costal margin and iliac crest as well as the front.

Landmarks to be Identified.—4th, 5th and 12th ribs; 7th, 9th and 10th costal cartilages. Xiphi-sternal joint. Umbilicus. Mons pubis; pubic symphysis, crest and tubercle. Superficial inguinal ring; inguinal ligament; mid-inguinal point. Anterior superior iliac spine; tubercle of iliac crest.

Skin.—Thin. Pubic hairs in women are limited to the pubic region. In men, a strip of hairs extends from the pubic region to the umbilicus.

Linea semilunaris is a shallow, linear depression that extends from the pubic tubercle to the ninth costal cartilage at or near its tip, and is opposite the lateral margin of rectus abdominis.

Superficial Fascia.—Contains: a very variable quantity of *fat*, and cutaneous *vessels* and *nerves*.

In the lower part of abdomen, it is divided into two layers—a superficial layer which is loose and fatty, and a deep layer which is membranous—with vessels between them.

Fatty layer is continuous with the superficial fascia of adjoining parts of the body. In the penis it is devoid of fat; and in the scrotum the fat is replaced by the *dartos* muscle.

Membranous layer fades away superiorly by joining with the fatty layer below the level of the umbilicus. Thickened in the median plane and connected with linea alba. Has definite connexions inferiorly. On each side it has a nearly horizontal attachment to the medial part of the inguinal lig. and fascia lata below the lateral part of the ligament. In the middle it passes over the pubis into the perineum to become continuous with the membranous layer there. In the female, this median portion passes through the mons pubis into the deeper part of the labia majora. On its way to the perineum in the male:—1. It is pierced by the penis, which carries off a tube that ensheaths it as far as the neck and fuses with the superficial layer. 2. It forms a layer in the scrotum under the dartos; and, with fibres of dartos, it is carried backwards into the scrotum as an imperfect median septum.

Continuous line of attachment (including the part in perineum) is:—(1) posterior border of perineal membrane; (2) margin of pubic arch; (3) deep fascia on gracilis and adductor longus near their origins; (4) medial half of inguinal lig. (or the fascia just below it);

(5) fascia lata a little below the lateral half of inguinal lig. These attachments prevent the passage of extravasated urine backwards into ischio-rectal fossa or downwards into the thigh.

Cutaneous Nerves.—**Anterior cutaneous nerves** are the terminal parts of seven nerves—*lower five intercostal, subcostal* and *ilio-hypogastric*. They pierce the external oblique aponeurosis at varying distances from the median plane and ramify to supply the skin of the front of abdomen—7th intercostal near xiphoid process, 10th at the level of umbilicus, ilio-hypogastric an inch above the superficial inguinal ring, and the others at proportional distances between them.

Terminal part of *ilio-inguinal nerve* emerges through the superficial ring, pierces the external spermatic fascia and descends to supply the skin of genital organs and medial side of thigh.

Lateral cutaneous branches of the *lowest two intercostal nerves* pierce the external intercostal muscle and divide under cover of obliquus externus into anterior and posterior branches which appear through obliquus or between its lower digitations. Posterior branches sweep backwards over latissimus dorsi. Anterior branches give twigs to obliquus externus and pass forwards over it, supplying the skin of the side of the abdomen.

(Lateral cutaneous branches of subcostal and ilio-hypogastric descend at once over the iliac crest into the gluteal region.)

Cutaneous Vessels.—**Arteries.**—(1) Branches of lower *intercostal arteries* accompany the lateral cutaneous nerves.

(2) Branches of *superior* and *inferior epigastric* accompany the anterior cutaneous nerves.

(3) Three *superficial inguinal arteries* arise from the femoral artery a little below inguinal lig. and supply the skin of the lowest part of abdomen :—

(*a*) **Superficial external pudendal** runs medially in front of spermatic cord or round ligament of uterus ; sends small branches up over the inguinal lig. to skin of abdomen, and ends in the skin of genital organs.

(*b*) **Superficial circumflex iliac** runs laterally just below inguinal lig. and supplies skin of abdomen and thigh.

(*c*) **Superficial epigastric** ascends over the inguinal lig. at the mid-inguinal point and runs upwards and medially, supplying skin as far as the umbilicus.

Veins.—Form a network in the superficial fascia drained by veins that accompany the arteries. The superficial inguinal veins end in the long saphenous vein.

When there is obstruction to the free flow of venous blood inside the abdomen, the superficial veins enlarge, and conspicuous features are a whorl of veins around the umbilicus and a large vein that runs up the side of the trunk from the groin to the armpit.

Lymph-Vessels.—From the lower part to glands in the groin ; from the upper part to glands in the armpit.

One or two of the inguinal *lymph-glands* may stray up between the two layers of superficial fascia and lie just above the inguinal lig.

Deep Fascia.—Very thin over the fleshy part of obliquus externus ;

fuses with its aponeurosis anteriorly and passes on to latissimus dorsi posteriorly.

Fascia Transversalis.—Is the internal fascial lining of the anterior wall of the abdomen. Lines the inner surface of transversus, and is separated from the peritoneum by a thin layer of extra-peritoneal areolar fatty tissue.

Anteriorly it is continuous with its fellow; is adherent to linea alba above umbilicus, but separated from it below umbilicus by a strip of fat.

Posteriorly it is lost in the fascia around the kidney.

Superiorly it joins the fascia on the lower surface of diaphragm.

Inferiorly it is continuous with fascia iliaca along iliac crest and the lateral half of inguinal lig.; in front of femoral vessels it is carried into thigh as the anterior wall of femoral sheath; and, medial to that, it is attached to the pectineal line and pubic crest.

It is pierced by spermatic cord or by round lig. of uterus at the *deep inguinal ring* (p. 367), above the mid-inguinal point.

Internal spermatic fascia is a membranous tube which is prolonged from the margins of the deep ring as a complete tubular investment for spermatic cord, and descends with the cord to form a complete layer in the wall of the scrotal chamber of that side.

In the female, there is no such tube, for the round ligament is developed in (and with) the abdominal wall; but in those cases where the peritoneum sends a short, tubular process into the female inguinal canal, the process pushes a sheath of transversalis fascia in front of it.

Fascia iliaca is the thin fascia that covers psoas and iliacus; it is prolonged into thigh as the posterior wall of femoral sheath.

Linea Alba.—A band, half an inch broad above umbilicus, but so narrow below it that the recti almost touch. Extends from xiphoid process to pubic symphysis. Formed by the interlacing insertions of aponeuroses of obliqui and transversi abdominis.

Pierced in fœtus by **umbilicus,** which remains in adult as a puckered cicatrix opposite the disc between 3rd and 4th lumbar vertebræ; the fibrous tissue around umbilicus is very dense.

Muscles of Anterior Wall.—Rectus, obliquus externus and internus, transversus and pyramidalis.

Nerve Supply of Muscles.—Lower 5 intercostal nerves, subcostal; and 1st lumbar (through ilio-hypogastric and ilio-inguinal).

Actions.—Flex the backbone; oblique muscles can rotate it—external of one side acting with internal of the other side. But their chief action is to flatten the anterior abdominal wall and compress viscera; they are called into use in forced expiration, in vomiting, and in defæcation, micturition and parturition.

Rectus abdominis lies alongside linea alba, enclosed in a sheath composed of the aponeuroses of obliqui and transversus.

Origin (tend.) : pubic crest and ant. lig. of symphysis.
Insertion (fl.) : anterior surfaces of xiphoid process and 7th, 6th, 5th costal cartilages.

These cartilages are so oblique that they lie almost side by side ; the insertion is in a horizontal line across them, and usually reaches the bony end of 5th rib. Since the upper lateral part of left rectus overlies 5th interchondral space, it is in front of apex of heart.

Substance is traversed by three horizontal *tendinous intersections*—one opposite umbilicus, another near the xiphoid, a third midway between these. They are fused with the **anterior wall** of the sheath, but not with its posterior wall.

Pyramidalis.—Lies in front of rectus. May be very small or absent. **Origin** (fl.) : pubic crest. **Insertion** (tend.) : linea alba below umbilicus. **Nerve** : subcostal. Tightens linea alba.

Obliquus externus abdominis lies superficially on the chest and in the antero-lateral wall of the abdomen.

Origin (fl.) : lower 8 ribs, interdigitating with serratus anterior and latissimus dorsi.

Insertion : by *fleshy fibres* into ant. half of outer lip of iliac crest ; by broad *aponeurosis* into xiphoid process, linea alba, symphysis, pubic crest and pectineal line.

Fibres run downwards, forwards and medially, with varying obliquity—the upper nearly horizontal, the lower nearly vertical. *Upper border* extends from 5th rib (below and lateral to nipple) to xiphoid ; it is overlapped by lower part of pectoralis major, which arises from the aponeurosis. *Posterior border* extends from last rib to middle of iliac crest ; its upper part is overlapped by latissimus dorsi.

Lower border of aponeurosis is thickened and curved backwards, so that it is grooved along its abdominal surface ; and it is called the *inguinal ligament*.

Inguinal lig. is the lower border of ext. oblique aponeurosis thickened and folded back on itself. It lies in the groove that marks the boundary between front of abdomen and thigh, and can be felt there as a tense, elastic band. It is convex towards the thigh—sloping steeply downwards from the iliac spine and then curving medially to the pubic tubercle.

Connexions.—Attached laterally to anterior superior iliac spine ; medially to pubic tubercle, and, by an expansion

called its **pectineal part,** to the pectineal line for nearly an inch. Fascia lata is attached to its lower margin. Obliquus internus arises from the lateral two-thirds of its abdominal surface ; cremaster arises with the lowest fibres of obliquus ; and transversus arises from the lateral third, behind obliquus.

Mid-inguinal point is a point *on inguinal lig.* equidistant from pubic symphysis and ant. sup. iliac spine ; it is therefore half an inch medial to the middle of the lig.

At this point, psoas major leaves the abdomen ; external iliac artery ends and femoral artery begins ; superficial epigastric artery ascends in front of the ligament and the inferior epigastric behind it ; deep inguinal ring is less than half an inch above it. (*See also* p. 214.)

RELATIONS.—The relations of the inguinal ligament are important, since it is in the boundary between the abdomen and the thigh.

Muscles.—Obliquus internus, cremaster, and transversus, as above. *Iliacus, psoas major* and *pectineus* occupy the greater part of the space between inguinal lig. and hip-bone, in that order from lateral to medial side. Fascia transversalis and fascia iliaca become continuous with each other along the lateral part of the ligament, in relation to iliacus ; but more medially they pass behind the ligament into the thigh, around the femoral vessels, as the femoral sheath.

Vessels.—*External iliac artery* becomes the femoral artery between the inguinal lig. and psoas, at the mid-inguinal point. *Femoral vein* becomes ext. iliac, on the medial side of the artery, between the inguinal lig. and the contiguous margins of psoas and pectineus ; and the *femoral ring* is medial to the vein, between the inguinal lig. and pectineus.

Superficial circumflex iliac artery runs laterally towards the anterior superior iliac spine below the inguinal lig. ; and it sends small branches upwards over it. *Superficial epigastric artery* ascends over the ligament to the anterior abdominal wall. *Superficial external pudendal artery* runs medially below the ligament toward the external genital organs ; and it sends small branches upwards over the ligament.

Inferior epigastric art. arises from the external iliac near its end, and turns upwards and medially behind the ligament ; having crossed the lig., it sends its pubic, or its "abnormal obturator", branch downwards and medially behind the lig. *Deep circumflex iliac art.* arises from the external iliac and runs laterally behind the lig.—first in the extraperitoneal fat and next in a fascial canal.

Testicular in the spermatic cord and the *cremasteric* in its coats, are above the medial part of the ligament.

All these arteries are accompanied by *veins.*

Nerves.—*Lateral cutaneous nerve* of thigh passes out of abdomen between the ligament and iliacus close to the anterior superior

iliac spine ; *femoral nerve*, in the groove between iliacus and psoas ; *femoral branch of genito-femoral nerve*, in the lateral wall of femoral sheath. *Ilio-inguinal nerve* passes through the superficial inguinal ring, above the medial end of the ligament. *Genital branch of genito-femoral nerve* on cremaster and sympathetic *testicular plexus* on the testicular artery are above the medial part of the lig.

Viscera.—*Superficial inguinal lymph-glands* lie in the superficial fascia below the ligament, and their afferents from anterior abdominal wall descend over the ligament. (One or two of these glands may lie above the ligament.)

Medial part of the inguinal lig., including its pectineal part, forms the floor of the inguinal canal, and supports the *spermatic cord* and its internal spermatic and cremasteric coats. The medial end of the inguinal lig. forms the infero-medial part of the inferior crus of the superficial ring ; and the cord lies on this part of the crus as it emerges through the ring.

Lateral half of the inguinal lig. is related to the *cæcum* on the right side, *descending colon* on the left side (peritoneum and transversalis fascia intervening in both cases).

Pectineal Part of Inguinal Lig.—This is a triangular expansion from the medial part of the inguinal lig.

Apex is attached to the pubic tubercle.

Posterior border is attached to the pectineal line for nearly an inch, in front of the conjoint tendon.

Anterior border is continuous with the inguinal lig.

Base is free, directed sidewards, and forms the medial boundary of the femoral ring. An abnormal obturator artery may descend along the back of the base. *Abdominal surface* supports the spermatic cord. Pectineus and the upper margin of the saphenous opening are attached to the *femoral surface*.

Pectineal lig. is a strong, fibrous ridge that extends laterally along the pectineal line from the base of the pectineal part of the inguinal lig. Fibres of pectineus and pectineal fascia are attached to it.

Reflected part of inguinal lig. is seldom present. It is a triangular sheet of fibres reflected upwards and medially from the pubic attachments of the inguinal lig. The fibres run behind the spermatic cord, pass through linea alba, and mingle with the fibres of the opposite external oblique aponeurosis.

Superficial inguinal ring (p. 367) is a triangular aperture in the external oblique aponeurosis, immediately above the pubic tubercle and the medial end of the inguinal ligament.

External spermatic fascia is a membranous tube that begins at the margins of the superficial ring, and is prolonged as a sheath for the round ligament of the uterus or as a coat for the spermatic cord down to the scrotum, where its lower part expands to form a complete layer in the wall of a scrotal chamber.

Anterior abdominal foramina are small, irregular holes in the external oblique aponeurosis near the linea alba; pellets of fat protrude through them.

Obliquus internus abdominis lies deep to obliquus ext. in the antero-lateral wall of abdomen.

Origin (fl.): Lumbar fascia, anterior two-thirds of iliac crest, lateral two-thirds of inguinal lig.

Fibres are directed mainly upwards and forwards; upper or posterior fibres are nearly vertical; lower fibres are horizontal; the lowest are bent downwards.

Insertion: Posterior part, by *fleshy fibres*, into the last three ribs and costal cartilages. Remainder, by a broad *aponeurosis*, into—cartilages of 9th, 8th, 7th ribs; xiphoid process; linea alba; pubic crest and pectineal line.

Aponeurosis, from the costal margin down to a point midway between umbilicus and symphysis, splits at linea semilunaris into two laminæ which enclose rectus. Aponeurosis of the part that arises from inguinal lig. does not split, but passes wholly in front of rectus, joining with the corresponding part of transversus to form the conjoint tendon.

Lowest fleshy fibres run medially in front of spermatic cord, and, becoming aponeurotic, arch downwards, behind the cord. Lowest part of internal oblique has, therefore, a triple relation to the cord:—First, in front, in the anterior wall of inguinal canal; second, above, in the roof of the canal; third, behind, in the posterior wall of the canal.

Spermatic cord, as it passes below this arched lower border of obliquus internus, drags off from it a number of bundles that form the loops of cremaster muscle; the loops are held together by fascia called **cremasteric fascia.**

Cremaster Muscle.—A series of loops that descend over spermatic cord and testis, one end of loop being attached with lowest fibres of obliquus internus to the inguinal lig., the other to the pubic tubercle. Exists in male only. **Nerve**: genital branch of the genito-femoral by fibres from L. 1, 2. Draws up testis.

Transversus abdominis.—Deepest muscle in the antero-lateral wall of abdomen.

Origin (fl.): (1) inner surfaces of lower six costal cartilages, interdigitating with diaphragm; (2) lumbar fascia; (3) anterior two-thirds of inner lip of iliac crest; (4) lateral third of inguinal lig. Fibres run mostly horizontally, but those from the last two cartilages incline downwards at first, and those from the inguinal ligament pass at first medially and then turn downwards.

Insertion: by aponeurosis into—xiphoid process; linea alba; pubic crest and pectineal line.

Aponeurosis passes behind the rectus from costal margin down to a point midway between umbilicus and pubis: in front of rectus below that point. Part that arises from inguinal lig. is above the level of spermatic cord, but its aponeurosis joins the corresponding part of obliquus internus and passes down behind the cord.

Conjoint Tendon.—Composed of the fused aponeuroses of those parts of obliquus internus and transversus that arise from the inguinal ligament.

Spreads medially and also downwards—its lateral part passing behind the spermatic cord, its medial part passing in front of rectus.

Attached medially to the linea alba, and inferiorly to the pubic crest and pectineal line behind obliquus externus.

SHEATH OF RECTUS.—1. *From rib-margin down to midway between umbilicus and pubis*, it is complete.

Anterior wall: aponeurosis of obliquus ext.; anterior lamina of obliquus internus.

Posterior wall: aponeurosis of transversus; posterior lamina of obliquus internus. At its upper end, the aponeurosis of transversus is so narrow that the uppermost fleshy fibres of transversus are found in the posterior wall of the sheath.

The tendinous intersections of rectus are fused with the anterior wall of the sheath, but not with the posterior wall. Therefore, rectus is easily detached from the posterior wall, but has to be cut from the anterior wall.

2. *Above rib-margin*, the sheath is incomplete, for the transversus and internal oblique do not reach above the rib-margin. Therefore, the **anterior wall** is external oblique aponeurosis alone; the **posterior wall** is absent and the rectus lies on the costal cartilages.

3. *From pubis up to midway between pubis and umbilicus*, it is incomplete. **Posterior wall** is absent, and rectus lies on transversalis fascia. All the aponeuroses are in front of rectus and form the **anterior wall** at this level. Transversus and int. oblique are fused; but ext. oblique does not fuse with them till near the median line.

Anterior wall of sheath, therefore, is complete from end to end, but has a varying composition.

Posterior wall has a uniform composition, but is incomplete.

Superiorly, the posterior wall ends at the rib-margin, where it is attached to the seventh cartilage; and the superior epigastric vessels pierce it there to enter the sheath.

Inferiorly, it ends half-way between umbilicus and pubis in a curved ridge called the **arcuate line**; and the inferior epigastric vessels slip into the sheath by passing upwards in front of it. The arcuate line is not wholly a free edge, except by dissection. It is,

rather, a linear thickening; and a thin stratum is continued downwards from it for some distance, and probably consists of some fibres of transversus which have not passed in front of rectus.

Contents of Sheath.—Rectus abdominis; pyramidalis; superior and inferior epigastric vessels; terminal parts of the lower five intercostal nerves and the subcostal nerve.

The nerves enter the sheath by piercing its lateral margin.

INGUINAL CANAL.—A passage, an inch and a half long, situated above the medial half of inguinal ligament, among muscles, aponeuroses and fascia of the lower part of anterior wall of abdomen, for the transmission of spermatic cord in male, round ligament of uterus in female. It is directed medially, downwards and forwards.

Its ends are called inguinal rings :—

Deep Inguinal Ring.—An aperture in fascia transversalis, barely big enough to admit the tip of little finger. Situated less than half an inch above the mid-inguinal point. Upper end of int. spermatic fascia (p. 361) is continuous with its margins.

Peritoneum covering it is puckered and may pass a little way through it into the canal; and, in the male, it is connected with the shrivelled fibrous vestige of the proximal part of the *processus vaginalis*—*i.e.* fœtal prolongation of peritoneum into the scrotum.

Inferior epigastric vessels are first below the ring and then medial to it; and as they pass by its medial side the artery sends its cremasteric branch into it and the vein receives its cremasteric tributary.

An indirect inguinal hernia enters the canal through the ring.

Transmits : *In female*—Round lig. of uterus and its vessels and nerve.

In male—1. Vestige of processus vaginalis, at the upper part.

2. Cremasteric vessels, at the medial part.

3. Genital branch of genito-femoral nerve, at the lower part.

4. Constituents of spermatic cord : (*a*) vas deferens and its artery; (*b*) testicular artery, above the vas; (*c*) pampiniform plexus of veins (bulkiest constituent of cord), around artery and vas—chiefly above; (*d*) testicular lymph-vessels, among the veins; (*e*) sympathetic nerves, with the artery.

Superficial Inguinal Ring.—An aperture in aponeurosis of obliquus externus, immediately above pubic tubercle and medial end of inguinal lig. Barely large enough to admit a finger-tip; smaller in female. Triangular or lanceolate in shape—long axis and *apex* directed upwards and sidewards; *base* is the lateral part of pubic crest. Margins are called *crura* and are sewn together by diagonal fibres called *intercrural fibres*. External spermatic fascia (p. 364) is continuous with the margins and with these fibres.

Superior crus is straight. **Inferior crus** is curved; its medial part is the medial part of the inguinal lig. and supports spermatic cord.

The ring **transmits :** *In female*—Round lig. of uterus ; its vessels and nerve ; and the terminal part of ilio-inguinal nerve.

In male.—1. All structures transmitted by the deep ring.

2. Two of the coats of the spermatic cord, viz.—internal spermatic fascia, derived from fascia transversalis at the margins of the deep ring ; and cremasteric muscle and fascia, derived from the lower border of obliquus internus.

3. Terminal part of ilio-inguinal nerve.

Anterior Wall of Inguinal Canal.—Aponeurosis of obliquus externus in all the length of canal ; lowest fleshy fibres of obliquus internus in lateral half, behind obliquus externus.

Posterior Wall.—Fascia transversalis in all the length of canal ; conjoint tendon in the medial half, in front of fascia transversalis ; reflected part of inguinal lig., when present, in the medial quarter, in front of the conjoint tendon.

Roof.—Lower border of obliquus internus.

Floor.—Inguinal lig. (separating spermatic cord from femoral sheath) and pectineal part of inguinal lig.

Contents of Canal.—Structures transmitted by the rings.

Relations of Canal.—*Inferior* : Femoral sheath.

Anterior : Skin; two layers of superficial fascia containing superficial epigastric artery and its vein opposite the lateral part of the canal, and one or more small branches of superficial external pudendal at the medial part.

Posterior : Peritoneum ; extraperitoneal tissue containing inferior epigastric artery and its veins opposite the lateral part of the canal, and the lateral umbilical ligament opposite the medial part.

Inguinal Triangle.- **Bounded** medially by rectus abdominis, laterally by inf. epigastric vessels, inferiorly by inguinal ligament.

Floor : fascia transversalis, with conjoint tendon in front of it in the medial part of the triangle. Lower part of the floor is the posterior wall of inguinal canal. A direct inguinal hernia enters the inguinal canal on the medial side of the epigastric vessels, pushing the floor of the triangle before it.

Lumbar Triangle.—Not always present. **Bounded** by latissimus dorsi posteriorly, obliquus externus anteriorly, iliac crest (immediately behind its mid-point) inferiorly.

Floor : obliquus internus or the fascia of quadratus lumborum or both. A lumbar abscess or hernia may come through it.

Deep Nerves of Anterior Wall of Abdomen.—Lower five intercostal ; subcostal ; ilio-hypogastric ; ilio-inguinal.

Lower Five Intercostal Nerves.—A little beyond the junction of ribs and their cartilages, these five nerves leave the intercostal spaces and pass between the slips of origin of diaphragm and transversus abdominis into the abdominal wall—the 7th, 8th and 9th having to pass deep to the 8th, 9th and 10th cartilages.

In the abdominal wall, they run forwards and downwards between transversus and obliquus internus accompanied by very small branches of intercostal vessels, and reach the sheath of rectus; pierce the sheath; pass in behind rectus and then forwards through it and through the anterior wall of its sheath to become anterior cutaneous nerves, accompanied by branches of epigastric vessels.

They give twigs to transversus, both oblique muscles and rectus.

Subcostal Nerve.—The anterior primary ramus of 12th thoracic. Enters abdomen from thorax by passing behind the lateral arcuate ligament of diaphragm, which arches across the front of quadratus lumborum.

Runs obliquely across the front of quadratus behind the kidney, below subcostal vessels and the last rib. At the lateral border of quadratus, it pierces the posterior aponeurosis of transversus, and then runs its course like a lower intercostal nerve, giving branches to muscles of anterior wall, including pyramidalis.

Its **lateral cutaneous branch** pierces the oblique muscles and deep fascia in front of the tubercle of iliac crest, and descends into the gluteal region.

Before the subcostal nerve enters the abdomen, it sends a branch down through psoas major to join the first lumbar nerve.

Ilio-Hypogastric Nerve.—A branch of the lumbar plexus. Arises in the substance of psoas major from the anterior primary ramus of 1st lumbar. Emerges through the lateral margin of psoas two inches below the last rib. Runs sidewards and downwards across the front of quadratus lumborum behind kidney and colon; pierces the posterior aponeurosis of transversus; curves forwards and downwards between transversus and internal oblique a little above the iliac crest; pierces internal oblique an inch in front of anterior superior iliac spine; runs on between the oblique muscles; and becomes the anterior cutaneous branch by piercing external oblique aponeurosis an inch above the superficial inguinal ring.

It gives branches to the transverse and oblique muscles; and it sends its **lateral cutaneous branch** through the oblique muscles and deep fascia behind the tubercle of iliac crest and then down into the gluteal region.

Ilio-Inguinal Nerve.—Same origin as ilio-hypogastric and the same course but a little lower—skirting the iliac crest. Pierces internal oblique below and medial to the ilio-hypogastric, and, running on between the oblique muscles, finds itself in the inguinal canal; and escapes from it through the superficial ring.

Supplies the muscles between which it lies. Has no lateral cutaneous branch.

Deep Vessels of Anterior Wall.—1. Slender branches of intercostal and subcostal arteries accompany the nerves.

2. Minute branches of lumbar arteries in the side-wall of abdomen.
3. Musculo-phrenic.
4. Superior epigastric.
5. Inferior epigastric.
6. Deep circumflex iliac.

All these arteries are accompanied by veins.

Musculo-Phrenic Artery.—A terminal branch of internal mammary. Arises near the sternum behind the 6th intercostal space. Passes downwards and sidewards behind the 7th cartilage, and enters abdomen between the slips of diaphragm from the 7th and 8th cartilages.

Runs along the deep surface of the costal margin over the abdominal surface of diaphragm as far as the 10th intercostal space.

Gives branches to diaphragm and anterior wall of abdomen; and it sends two anterior intercostal arteries into each of the 7th, 8th and 9th spaces.

Superior Epigastric Artery.—The other terminal branch of internal mammary.

Enters abdomen by descending behind 7th cartilage between the sternal slip of diaphragm and its first costal slip.

Pierces the upper end of the posterior wall of the sheath of rectus. Breaks up into branches which sink into rectus and supply it and the overlying skin. Gives off also a long, slender **hepatic branch**; this branch descends to the umbilicus and then runs along the round ligament to the liver.

Inferior Epigastric Artery.—One of the two branches of external iliac. Springs from that artery near its lower end.

Curves forwards below the lower border of the peritoneum. Ascends behind the inguinal lig. at the mid-inguinal point. Runs upwards and medially, at first below the deep inguinal ring and then close by its medial side, and reaches the lateral edge of rectus. Up to this point, it is in the extraperitoneal fat—*i.e.* between peritoneum and transversalis fascia. It now pierces transversalis fascia, slips in behind rectus abdominis, climbs up over the arcuate line into the sheath, and divides into branches which sink into rectus.

As it passes by the medial margin of the deep inguinal ring, it is behind the inguinal canal, and the vas deferens or the round ligament of uterus "hooks round" it—being behind the artery in the extraperitoneal fat, lateral to it in the ring, and in front of it in the canal.

Its *venæ comitantes* end in the external iliac vein.

Branches.—Muscular to rectus; *cutaneous* to overlying skin; *pubic*; *cremasteric.*

Pubic branch arises a little above the inguinal lig. Runs downwards and medially across the back of the inguinal lig. and its pectineal part to the pelvic surface of pubis, where it anastomoses with the pubic branch of obturator.

May be a big branch called the **abnormal obturator** because it takes the place of the ordinary obturator artery. An abnormal obturator artery may be present on one or both sides. May or may not be accompanied by an *abnormal obturator vein.* Or there may be an abnormal vein without an abnormal artery.

If the abnormal artery is near the free edge of the pectineal part of the inguinal ligament, it is in danger in the operation to relieve a femoral hernia.

Artery to Cremaster.—Arises as inferior epigastric runs by the medial side of the ring. Passes through the ring into inguinal canal to supply cremaster and anastomose with the testicular.

Artery of Round Lig. of Uterus.—Is the corresponding artery in the female.

Deep Circumflex Iliac Artery.—The other branch of external iliac. Arises at the same level as inferior epigastric. Runs along the back of inguinal ligament to the anterior superior iliac spine and then along the iliac crest to its middle.

For a short distance in extraperitoneal fat. Then, having pierced transversalis fascia, it runs in a fibrous canal at the junction of that fascia and fascia iliaca at the back of the ligament. Pierces transversus muscle a little beyond the iliac spine and ramifies between transversus and internal oblique. Shortly before it reaches the iliac crest, it sends an *ascending branch* up through transversus to ascend between it and internal oblique.

Deep circumflex iliac vein ends in the external iliac. To reach vein it has to cross superficial to the external iliac artery behind the root of the inferior epigastric artery.

INTERIOR OF ABDOMEN.—*See* **Cavity of Abdomen** (p. 627); **Urogenital organs** (p. 654); **Aorta**; **Inferior vena cava**; **Ductless glands** (pp. 675, 678); **Sympathetic plexuses** (p. 579).

DIAPHRAGM

The diaphragm is the arched musculo-tendinous partition between thorax and abdomen, forming the **roof of the abdomen** and the floor of the thorax; and it is the chief muscle of respiration.

Its circumferential part is fleshy; and the muscular fibres curve upwards and inwards from every side to join the edges of an aponeurotic sheet called the **central tendon.**

The central tendon is the **insertion.** It is crescentic in outline, with the convexity forwards, the convexity being accentuated in the middle; and the tendon is described as having three *lobes—right, left* and *median*, of which the right is the biggest and the left the smallest.

Origin: 1. Back of xiphoid process, by a pair of short, narrow fleshy slips.

2. Inner surfaces of lower six costal cartilages by wide fleshy slips that interdigitate with transversus abdominis.

3. Lateral and medial arcuate ligaments.

4. Bodies of the upper three lumbar vertebræ, by a pair of crura.

5. Median arcuate ligament.

Lateral arcuate lig. is a tendinous band that arches across the anterior surface of quadratus lumborum from the last rib to the first lumbar transverse process; it is fused with the anterior layer of the lumbar fascia.

Medial arcuate lig. is a tendinous band that arches across the front of psoas major from the first lumbar transverse process to the body of the second lumbar vertebra and the tendinous part of the crus; it is fused with the fascia that clothes the front of psoas.

Crura are long, tapering bundles, fleshy above, tendinous below, attached to the bodies and discs.

Left crus, attached to the upper two lumbar vertebræ, extends upwards, a little to the left of œsophagus, to reach the left lobe of central tendon; and it may send a slip behind œsophagus to the right lobe.

Right crus, thicker and longer, attached to the upper three vertebræ, spreads out to reach all three lobes; the part most to the left splits into two bundles to encircle œsophagus, and they meet and decussate in front of it before they reach the central tendon.

Median arcuate lig. is a tendinous band that arches across the front of aorta from one crus to the other, and gives rise to fibres that mingle with those of the right crus.

Vertebro-costal trigone is a gap between the part that arises from last rib and the part from lateral arcuate lig. Usually larger on left side, and may be present only on left side. The gap is filled with a thin sheet of fibrous tissue that separates kidney and its fat from the pleura.

A smaller gap may exist between the sternal and costal slips of origin. There, the peritoneum and pleura are separated by areolar tissue only.

Nerves: phrenic, by fibres from C. 3, **4**, 5; phrenic plexus of sympathetic; lower intercostals (sensory).

Action: *See* p. 127.

RELATIONS OF DIAPHRAGM.—Abdominal surface.—Liver occupies a great part of abdominal surface, especially on the right side. Stomach is in relation to the left and anteriorly; spleen, to the left and posteriorly. Kidney of each side lies against the crus and the part that arises from the arcuate ligaments. Suprarenal gland lies on crus; cœliac ganglion is medial to suprarenal gland. Pancreas lies across crura. Inferior vena cava lies on right crus.

Between the Crura.—Aorta, cisterna chyli, and vena azygos, in

that order from left to right—the vein being behind the right crus rather than between the crura.

Thoracic Surface.—Pericardium and heart are related to the median area; pleura, lung, and phrenico-pleural lig., to the lateral area. A considerable circumferential area (below pleura and phrenico-pleural lig.) is in contact, posteriorly, with quadratus lumborum and psoas above the level of the arcuate ligaments; and antero-laterally, with costal cartilages, ribs and internal intercostal muscles; therefore, an instrument passed through a lower intercostal space, in the mid-axillary line, misses the pleura: it pierces the diaphragm at once and enters the abdomen.

Besides these, there are various vessels and nerves and small portions of organs in relation to diaphragm:—

Abdominal surface: Duodenum, upper end of descending colon and, sometimes, upper end of ascending colon. Left renal vessels, right renal artery, middle suprarenal arteries, phrenic and musculophrenic vessels, hepatic artery, left gastric and splenic vessels, cœliac plexus.

Posterior to each crus are the upper two lumbar arteries; and vena azygos is overlapped by the right crus.

Thoracic surface: Thoracic aorta, œsophagus, thoracic duct, azygos and inferior hemiazygos veins, splanchnic nerves, sympathetic trunks, subcostal vessels and nerves.

OPENINGS IN DIAPHRAGM.—Aortic opening: Between crura, behind median arcuate ligament, opposite lower border of last thoracic vertebra.

Transmits aorta, thoracic duct, vena azygos, and two lymph-trunks that descend from lower intercostal glands to cisterna chyli.

Œsophageal opening: Behind central tendon, amidst fibres of right crus, opposite 7th costal cartilage, an inch to the left of the median plane. May be lower and near or at the median plane.

Transmits œsophagus, gastric nerves, œsophageal branches of left gastric artery and their veins.

Vena-caval opening: Between right and median lobes of central tendon, opposite sixth costal cartilage, an inch to the right of the median plane.

Transmits vena cava inferior, branches of right phrenic nerve, and a few lymph-vessels from liver.

Smaller Structures that pass between Thorax and Abdomen.—*Superior epigastric vessels* pass between the slip from xiphoid process and the slip from 7th cartilage.

Musculo-phrenic vessels, between slips from 7th and 8th cartilages.

Lower five intercostal nerves, accompanied by vessels, between slips from 7th down to 12th cartilage.

Subcostal nerve and vessels, behind lateral arcuate lig.

Sympathetic trunk, behind medial arcuate lig.

Greater, lesser and *lowest splanchnic nerves* pierce the crus.

Left crus is pierced also by the *inferior hemiazygos vein*; and right crus, occasionally, by v. azygos.

POSTERIOR WALL OF ABDOMEN

Landmarks to be Identified.—7th and 12th thoracic spines; lumbar spines. 11th and 12th ribs. Iliac crest; posterior superior iliac spine.

Skin.—Very thick.

Superficial Fascia.—Fibrous and tough. Contains: a variable quantity of *fat*; small *cutaneous vessels*—branches and tributaries of lumbar vessels that pierce the deep fascia; *cutaneous nerves*—branches of posterior primary rami of the lower **thoracic** nerves.

Deep Fascia.—(1) A layer that covers latissimus dorsi; (2) the lumbar fascia; (3) fascia of psoas and iliacus.

Lumbar Fascia.—3 layers: anterior, middle and posterior.

Posterior Layer.—Thick, dense and strong. Covers sacro-spinalis. Attached to lumbar spines; and fuses with the middle layer at the lateral border of sacro spinalis. Extends downwards into the sacral region over the lower part of sacro-spinalis, and upwards over its prolongations in the back of the chest. Latissimus dorsi and serratus posterior inferior take partial origin from it; and, through it, they arise from lumbar spines.

Middle Layer.—Much thinner. Covers the back of quadratus lumborum. Separates it from the lateral part of sacro-spinalis and, infero-laterally, from latissimus dorsi. Stretches from the last rib to the ilio-lumbar ligament and iliac crest. Attached to the tips of lumbar transverse processes medially. At the lateral border of quadratus it fuses with the anterior layer to form a flat band that stretches from iliac crest to the last rib and gives partial origin to transversus and obliquus internus.

Anterior Layer.—Stronger than the middle layer. Covers the front of quadratus and separates its medial part from psoas major. Stretches from the last rib to the ilio-lumbar lig. and iliac crest. Fused with the middle layer laterally. Attached medially to the fronts of lumbar transverse processes near their tips. A little below the last rib, it is fused with the lateral arcuate lig. of diaphragm.

Fascia of Psoas and Iliacus.—Covers the front of these muscles. Easily separated from them.

Below iliac crest, it covers both muscles without sending a septum between them, and is called **fascia iliaca.** This part extends from iliac crest to the bony rim of the pelvis; inferiorly, its lateral part meets and fuses with fascia transversalis at the back of the inguinal ligament, but its medial part is prolonged down as the posterior wall of the femoral sheath.

Above iliac crest, it covers psoas only, and it is thinner. Laterally, it fuses with the anterior layer of lumbar fascia; medially, it is attached to the fibrous arches which bridge over the lumbar vessels on the sides of the vertebræ; superiorly, it fuses with the medial

arcuate ligament of diaphragm and is then continued up over the part of the psoas that is in the thorax above the arcuate lig.

Muscles of Posterior Wall.—Latissimus dorsi; serratus posterior inferior; sacro-spinalis; multifidus; intertransverse; quadratus lumborum; psoas major; psoas minor; iliacus.

Latissimus dorsi is the most superficial muscle (p. 172).

Serratus posterior inferior is under cover of latissimus. It is a thin sheet that passes to the lower four ribs from the upper two lumbar spines and lower two thoracic spines (p. 279).

Sacro-spinalis is the thick mass of muscle alongside the lumbar spines, on the back of the transverse processes and quadratus lumborum (p. 283).

Multifidus is deep to sacro-spinalis, on the back of the vertebral laminæ.

Intertransverse muscles connect the transverse processes.

Quadratus lumborum lies alongside the tips of lumbar transverse processes, enclosed between the anterior and middle layers of lumbar fascia. Sacro-spinalis covers the upper part of its posterior surface and overlaps the lower part; psoas major overlaps its anterior surface. The part above the lateral arcuate ligament is in the thorax behind the diaphragm.

Origin (fl.-tend.): ilio-lumbar ligament; iliac crest behind and lateral to that ligament; lower lumbar transverse processes.

Insertion (fl.-tend.): medial half of the lower border of last rib; upper lumbar transverse processes.

Nerves: L. 1, 2, 3, 4, directly.

Fixes last rib in respiration. Extends vertebral column and bends it sidewards.

Psoas major and iliacus are together called **ilio-psoas.**

Psoas major, a long, thick muscle, lies—(*a*) alongside lumbar vertebral bodies on the front of the transverse processes, overlapping quadratus lumborum; (*b*) along the side of the brim of the pelvis, overlapping and narrowing the inlet; (*c*) in the middle of the floor of the femoral triangle on the front of the hip-joint, from which it is separated by a *bursa*; and (*d*), at its insertion, below the hip-joint.

A fleshy **origin** from: (1) transverse processes of all lumbar vertebræ; (2) disc above each lumbar vertebra and adjacent margins of bodies, including 12th thoracic;

(3) fibrous arches over lumbar vessels on the sides of the upper 4 lumbar bodies.

Insertion by tendon into lesser trochanter.

Nerve: 2nd, 3rd, 4th lumbar directly and through femoral.

Iliacus, a fan-shaped muscle, lies—(*a*) in iliac fossa; (*b*) in the lateral part of the floor of femoral triangle on the front of the hip-joint; (*c*) below the hip-joint.

A fleshy **origin** chiefly from the floor of iliac fossa; and a fleshy **insertion** into (1) tendon of psoas, (2) lesser trochanter, (3) surface of femur below lesser trochanter for an inch.

Nerve: femoral, while the nerve is still in the abdomen.

Femoral nerve is in the groove between iliacus and psoas; external iliac and femoral arteries on psoas; femoral vein and the beginning of external iliac vein on the contiguous margins of psoas and pectineus.

Ilio-psoas flexes the thigh and rotates it medially during flexion, but rotates it laterally after it is flexed. Psoas flexes the vertebral column also.

Psoas Minor.—Absent in 40 per cent. Lies in abdomen, on anterior surface of psoas major. **Arises** by small, fleshy belly from lateral margins of twelfth thoracic and first lumbar vertebræ and disc between them. **Inserted**: by long tendon into pectineal line, and into fascia on ilio-psoas. **Nerve**: L. 1, directly.

It flexes vertebral column.

Arteries of Posterior Wall.—Subcostal; lumbar; ilio-lumbar.

Subcostal Artery.—Last parietal branch of thoracic aorta. Passes from thorax into abdomen behind the lateral arcuate ligament above the nerve and below the vein. Runs with them between kidney and quadratus, and through transversus; and it soon ends in branches to transversus and internal oblique.

Lumbar Arteries.—4 pairs from the back of abdominal aorta and a fifth pair from the median sacral behind the left common iliac vein.

Fifth pair are small. Each curves backwards over the fifth vertebra and disappears behind sympathetic trunk and psoas to end by anastomosing with branches of ilio-lumbar.

Each of the **upper four pairs** also curves back over its vertebra and disappears behind the sympathetic trunk and psoas.

On each side, the upper two pass behind the crus of diaphragm before they reach the sympathetic trunk; and the upper two right pass behind cisterna chyli and vena azygos also. Third and fourth right are behind inferior vena cava.

Having crossed behind the sympathetic trunk, each passes backwards, with the rami communicantes, under the fibrous arch that protects them from psoas, and reaches the root of the transverse process. It then runs sidewards along the lower edge of the process behind psoas and passes onwards behind quadratus lumborum to end in small branches between transversus and internal oblique. Fourth sometimes passes in front of quadratus.

A **posterior branch** arises at the root of the transverse process; sends a *spinal branch* through the intervertebral foramen into the vertebral canal; and then runs backwards below the process to supply muscles and skin of the loin.

Ilio-Lumbar Artery.—A branch from the end of internal iliac or from the beginning of its posterior division. Arises near the brim of the pelvis. Passes upwards, deeply hidden in the fat behind the common iliac artery, between lumbo-sacral trunk and obturator nerve. Disappears behind psoas and soon divides into two branches—iliac and lumbar:—

1. **Iliac branch** crosses behind psoas and ramifies widely in the iliac fossa—partly on the surface of iliacus and partly deeply in its substance.

2. **Lumbar branch,** much smaller, runs up behind psoas into quadratus lumborum. It sends a *spinal branch* through the lumbo-sacral intervertebral foramen.

Veins of Posterior Wall.—Ilio-lumbar; lumbar; ascending lumbar; subcostal; azygos; inferior hemiazygos.

Ilio-Lumbar Vein.—Emerges at the medial side of psoas major and ends in the back of the common iliac of its own side.

Lumbar Veins.—Collect blood from the back-wall and the side-wall of the abdomen.

They run medially behind quadratus lumborum and on the front of the lower edges of the transverse processes, immediately above their arteries, behind the psoas.

The **fifth** passes forwards between the psoas and the fifth vertebra and ends in the ilio-lumbar vein.

The **fourth** and **third** curve forwards between the psoas and the vertebral bodies to end in the inferior vena cava—the right ones passing behind the sympathetic trunk, and the left ones behind that trunk and the aorta.

The **second** and **first** end usually in ascending lumbar vein, but they may pass forwards between psoas and the vertebral bodies to end in the abdominal part of vena azygos or inferior vena hemiazygos.

Ascending Lumbar Vein.—A long anastomosing channel that connects lateral sacral veins, ilio-lumbar vein, lumbar veins and subcostal vein.

It begins in the lower lateral sacral veins, ascends over pelvic surface and ala of sacrum, and over the fronts of the roots of lumbar transverse processes in the substance of psoas major, to end in the subcostal vein on the side of the twelfth thoracic vertebra. Upper two lumbar veins usually end in it.

Subcostal Vein.—Runs along the upper border of its artery. Passes with it behind lateral arcuate ligament into thorax; receives the ascending lumbar vein and ends on the 12th thoracic vertebra by joining vena azygos or inferior vena hemiazygos.

Azygos Vein.—Arises from the back of inferior vena cava at the level of the renal vein.

Lies at first behind inferior vena cava on the tendinous part of right crus of diaphragm. Passes upwards and medially behind the right renal artery; slips over the medial margin of the crus and runs to the aortic opening of diaphragm—lying deeply in the fat in front of the first right lumbar artery, with cisterna chyli and aorta medial to it and right crus lateral to it and overlapping it.

In a few bodies it pierces the right crus or pierces the diaphragm at the lateral side of the crus; and it may receive the upper two right lumbar veins.

Inferior Hemiazygos Vein.—Springs from the back of the lower part of the left renal vein. Ascends between the renal artery and the tendinous part of the left crus, and pierces the fleshy part of the crus to enter the thorax.

Cisterna Chyli.—A bag-like vessel about 2 inches long and a quarter of an inch wide. Receives the lymph from abdomen and lower limbs.

Lies hidden in the fat between aorta and vena azygos in front of the upper two lumbar vertebræ and upper two right lumbar arteries.

It receives:—1. The **intestinal lymph-trunk,** which brings the lymph from the small intestine.

2. A pair of **lumbar lymph-trunks,** which bring the lymph from nearly all the rest of the abdomen and from the lower limbs.

3. A pair of **descending lymph-trunks,** which descend through the aortic opening and bring lymph from the back part of the thorax.

The upper end of the cisterna narrows to become the **thoracic duct,** which enters the thorax through the aortic opening.

Nerves of Posterior Wall.—Cutaneous branches of posterior primary rami of lower thoracic nerves (p. 285); subcostal nerve (p. 369); lumbar nerves and their branches; sympathetic trunk with its ganglia and their branches and communications.

Sympathetic Trunk.—A slender cord that resembles a knotted string because of the ganglia on it.

Leaves the thorax and enters the abdomen behind the medial arcuate ligament. Descends between the vertebral bodies and the anterior edge of psoas major across the lumbar vessels. Disappears behind the common iliac vessels and enters the pelvis.

Right trunk is behind the renal artery, inferior vena cava and common iliac vessels.

Left trunk is behind the pancreas, renal vessels, end of duodenum, testicular artery, inferior mesenteric artery and the common iliac vessels.

Lumbar Ganglia.—There should be 5—one opposite each vertebra. But they vary in position and from 4 to 8 in number.

Branches.—Arise from the ganglia.

1. A **grey ramus communicans** passes to the anterior primary ramus of each lumbar nerve. It is made of non-medullated fibres that arise in a ganglion; and it curves backwards over the vertebral body with a lumbar artery under psoas.

2. Irregular filaments pass to the aortic plexus and over the common iliac vessels to the hypogastric plexus, which lies between the two common iliac arteries.

Each of the upper two lumbar anterior rami sends a **white ramus communicans** to the trunk. It is made of medullated fibres that arise in the spinal cord; and it lies alongside the grey ramus.

LUMBAR NERVES.—Like other spinal nerves, each lumbar nerve is attached to the spinal cord by two bundles of fibres called its *roots* —an anterior and a posterior.

Anterior root is composed of motor fibres which arise in the grey matter of the cord and emerge through its anterior surface.

Posterior root is thicker and has a ganglion on it—the **spinal ganglion.** The root is composed of sensory fibres which arise from cells in the ganglion. While still in the ganglion, each fibre divides into a central branch and a peripheral branch. The **peripheral branches** run on in the nerve. The **central branches** form the root. They run to the spinal cord and enter through the floor of a narrow groove on its posterior surface; and they end in the grey matter of the spinal cord or the medulla oblongata, *i.e.* the lowest part of the brain.

The roots unite just beyond the ganglion to form the **spinal nerve-trunk,** in which the motor and sensory fibres are mingled. The trunk is very short, for it divides almost at once into an **anterior** and a **posterior primary ramus,** each of which is composed of both motor and sensory fibres. But, before the trunk divides, it gives off an exceedingly slender branch called the **meningeal branch,** which runs inwards to supply the meninges and vessels of the cord.

The ganglion lies in the intervertebral foramen below the vertebra of corresponding number; and the union of the roots and splitting of the trunk take place in the foramen. The roots are therefore long (especially the lower ones), for the cord ends at the upper border of the second lumbar vertebra, and the lumbar region of the cord, to which the lumbar nerves are attached, is opposite the last two thoracic vertebræ.

Posterior Primary Rami.—Emerge from the intervertebral foramina, pass backwards between transverse processes, and, like posterior rami elsewhere, they divide into lateral and medial branches. The *medial branches* supply multifidus. The *lateral branches* supply sacro-spinalis, and the upper three of them give off cutaneous branches. These three **cutaneous branches** do not supply skin of the loin. They pierce the deep fascia at the highest part of iliac crest and descend into the gluteal region.

Anterior Primary Rami.—Thicker than posterior rami and increase in thickness from above downwards.

They emerge from intervertebral foramina and pass sidewards and downwards into the substance of psoas major. As they emerge, each receives a grey ramus communicans from the sympathetic trunk, and the upper two send white rami communicantes to it.

Within the psoas—1. The first receives a branch from the subcostal.

2. The upper four give off muscular branches.

3. The upper four divide to form the roots of six named nerves; these roots (crossing each other) and the communication from subcostal form the *lumbar plexus*.

4. The lower division of the 4th descends through psoas and joins the 5th to form a thick cord called the *lumbo-sacral trunk*.

The **muscles** supplied directly are:—*Psoas minor* from the first. *Intertransverse muscles* and *quadratus lumborum* from the upper four. *Psoas major* from 2nd, 3rd and 4th.

LUMBAR PLEXUS.—Formed by the upper 3 lumbar anterior primary rami and part of the 4th, with a branch from subcostal.

Lies in the substance of psoas on the front of the lumbar transverse processes.

Gives off six nerves:—Ilio-hypogastric and ilio-inguinal from L. 1 (p. 369); genito-femoral from L. 1 and 2; lateral cutaneous nerve of thigh from L. 2 and 3; femoral and obturator from L. 2, 3 and 4.

They all arise in the substance of psoas and have to escape from it—genito-femoral through its anterior surface; obturator through its postero-medial border where it reaches the pelvic brim; the other four through its lateral border.

Genito-Femoral Nerve.—Slender. Emerges through the front of psoas at the level of the 3rd lumbar vertebra. Runs down over psoas behind the ureter and the branches of mesenteric vessels; and, at a varying point, it divides into two—genital and femoral.

Genital branch runs down over psoas to the lateral side of external iliac artery, pierces the fascia, passes on to the front of the iliac artery, whence it passes through the deep inguinal ring into the inguinal canal to supply cremaster muscle and send a filament to the skin of scrotum; or, to supply the round lig. of uterus, along which it runs to the skin of labium majus.

Femoral branch runs down over psoas along the lateral side of external iliac artery, crosses in front of the deep circumflex iliac artery, passes behind the inguinal ligament in the lateral wall of femoral sheath, pierces the deep fascia and supplies skin of the uppermost part of front of the thigh.

Lateral Cutaneous Nerve of Thigh.—Emerges through the lateral margin of psoas at the iliac crest. Slants across iliacus muscle, between it and fascia iliaca, behind the ascending or the descending colon, and leaves the abdomen by passing behind the inguinal lig. at the medial side of the anterior superior iliac spine.

Femoral Nerve.—Thickest nerve of the plexus. Runs downwards and laterally across the tip of the 5th lumbar transverse process and the abdominal surface of sacro-iliac joint. Emerges through the lateral margin of psoas at a variable point below the iliac crest

(depending on the thickness of psoas); and it never leaves the lateral margin of psoas.

Runs down in the groove between psoas and iliacus, behind the fascia—the right nerve behind cæcum and the left behind descending colon—and passes behind the inguinal ligament into the thigh.

In the abdomen, it gives branches to psoas major and iliacus.

Obturator Nerve.—Descends across the 5th lumbar transverse process medial to the femoral and passes on to the ala of the sacrum, where it emerges through the postero-medial margin of psoas and, having pierced the fascia, passes over the sacro-iliac joint at the lower margin of the ala into the true pelvis. Before it enters the pelvis it lies deeply in the fat at the lateral side of the ilio-lumbar artery behind the common iliac vessels.

Descending Branch of Fourth Lumbar.—Of variable thickness. Descends through psoas across the 5th transverse process, medial to the obturator; and it joins the anterior primary ramus of L. 5 on the ala of sacrum.

(Note the crowd of nerves related to the fifth lumbar transverse process—roots of femoral and obturator and the descending branch of the 4th on the front of it, and the 5th below it.)

Anterior Primary Ramus of L. 5.—Very thick. Passes from the lumbo-sacral intervertebral foramen on to the ala of sacrum, where it is joined by the descending branch of L. 4.

Lumbo-Sacral Trunk.—Formed by the union of the whole anterior ramus of L. 5 and the descending branch of L. 4.

Runs sidewards and downwards over the ala of the sacrum (grooving the bone slightly), and passes over the lateral part of the lower border of the ala into the true pelvis to form part of the sacral plexus.

Lies close to the ala, hidden in the fat behind the common iliac vessels and the medial part of psoas. Ilio-lumbar artery and obturator nerve are close to its lateral side; and the sympathetic trunk, entering the pelvis, is a little medial to it.

Accessory Obturator Nerve.—Of no importance. Seldom present. Arises from L. 3 and 4. Runs down along the medial side of psoas into the thigh. Gives branches to the hip-joint and unites with the obturator nerve. May give a branch to pectineus.

TRUE PELVIS

Bones.—**Sacrum** and **coccyx** above and behind. Lower half of **hip-bone**—comprising *ischium*, *pubis* and a small part of *ilium*—at the side and below or in front. (*See* pp. 13, 90, 95.)

Contents of Sacral Canal.—(1) A quantity of fat. (2) Branches of lateral sacral arteries and a plexus of veins. (3) Roots of sacral and coccygeal nerves. (4) Filum terminale. (5) Dura mater down to the level of the second sacral spine. (6) Arachnoid mater for a like distance, and filled with (7) cerebro-spinal fluid.

Sacral hiatus is the lower end of the canal. It transmits the filum terminale and the anterior and posterior primary rami of the fifth sacral nerve and coccygeal nerve.

Posterior sacral foramina transmit the posterior primary rami of the upper four sacral nerves and terminal branches of lateral sacral arteries with their veins.

Anterior Sacral Foramina.—Branches of the lateral sacral arteries enter them to reach the sacral canal. Anterior primary rami of the upper four sacral nerves and the tributaries of the lateral sacral veins emerge through them.

Pelvic Joints and Ligaments and Sciatic Foramina.—*See* pp. 142-145.

Muscles.—Piriformis ; obturator internus ; sphincter urethræ and deep transversus perinei ; levator ani ; coccygeus.

Piriformis lies in the dorsal wall of cavity of pelvis.

Obturator internus in the side-wall.

Sphincter urethræ and the **deep transversus perinei** form a sheet of muscle that lies in the ventral wall, stretching across the pubic arch, enclosed between the perineal membrane (pp. 395, 399) and the fascia of the pelvis.

Levator ani is a wide sheet that stretches from the side-wall (and ventral wall) towards the median plane ; with its fellow, it forms a " floor " for the pelvis which shuts off the ischio-rectal fossæ from the pelvis.

Coccygeus lies at the junction of floor and dorsal wall, between levator and piriformis.

Obturator internus arises from the pelvic surface of obturator membrane and the bone around the obturator foramen, especially above and behind—reaching as far as the margin of the greater sciatic notch. Fibres converge on the lesser sciatic foramen and form a tendon that passes out through the foramen, bends at a right angle, and runs across the back of the hip-joint to be **inserted** into the medial surface of the greater trochanter. (*See also* p. 224.)

Nerve : Nerve to obturator internus from sacral plexus.

Abducts the flexed thigh ; rotates the extended thigh laterally.

Obturator fascia is the strong fascia that covers the pelvic surface of obturator internus, and is continuous inferiorly with the edge of the falciform process of the sacro-tuberous ligament.

Not to be confused with obturator membrane.

A great part of levator has a linear origin from the fascia. The part of the obturator muscle and fascia below the level of that attachment is in the side-wall of the ischio-rectal fossa (p. 394). Part above is in the side-wall of the pelvis, and is related :—*in both sexes*, to obturator vessels and nerve, ureter and infero-lateral surface of bladder ; *in male*, to vas deferens also ; *in female*, to ovary, round lig. of uterus and lateral attachment of broad lig.

Piriformis arises mainly from the pelvic surface of the 2nd, 3rd

and 4th pieces of sacrum ; passes sidewards and downwards across the lowest part of the pelvic surface of the sacro-iliac joint ; leaves the pelvis through the greater sciatic foramen ; crosses the uppermost part of the back of the hip-joint, tapering into a tendon which is **inserted** into the top of the greater trochanter. (*See also* p. 224.)

Nerves : Twigs from anterior primary rami of s. 1, 2.
Same actions as obturator internus.

Relations of Piriformis.—Lower part of **pelvic colon** and upper part of **rectum** overlap it medially. Upper part of **sacral plexus** lies above it, across the pelvic surface of sacro-iliac joint; lower part of the plexus lies on piriformis, between it and its fascia.

Most of the branches of the plexus leave the pelvis through the greater sciatic foramen in close relation to piriformis—one above it, and the rest below it.—*See* Greater Sciatic Foramen, p. 143.

The branches of the internal iliac artery lie in the fat that covers the fascia, and three of them, accompanied by their veins, pierce the fascia and pass out with the nerves.

Coccygeus is a small, thin, triangular sheet that **arises** (tend.) by its apex from the tip of the ischial spine, and is **inserted** (fl.-tend.) by its base into the margin of last piece of sacrum and first piece of coccyx. **Nerves** : s. 3, 4 directly, and through perineal of s. 4.

Relations.—*Dorsal surface of* coccygeus is fused with the **sacro-spinous lig.** and has the same attachments—which are too rigid for the muscle to have any appreciable action. With the loss of flexibility of coccyx, the muscle became passive, and the ligament is merely the fibrosed dorsal part of it.

Dorsal surface of the ligament is largely covered by the **sacro-tuberous lig.**, and that, in turn, by **gluteus maximus.**

Pelvic surface of coccygeus is overlapped medially by the middle part of the **rectum** ; and it is clothed with **fascia** ; nerves related to its pelvic surface are between the muscle and the fascia—perforating cutaneous, perineal of s. 4 and the coccygeal plexus.

Ano-coccygeal body is a fibrous nodule between the coccyx and the anal canal.

Perineal body is a fibro-fatty mass situated between the front of the anal canal and the posterior border of the perineal membrane (with which it is continuous).

Levator ani, with its fellow, forms the movable "floor" of the pelvis. It is a wide, curved sheet of muscle, much thicker anteriorly than posteriorly.

Has a linear, fleshy **origin** from the back of the body of the pubis, from the obturator fascia and from the ischial spine. Anterior fibres curve downwards, backwards and only slightly medially, so that the anterior border looks medially rather than forwards ; posterior fibres curve downwards and medially.

It is **inserted** by fleshy fibres into the perineal body, side of anal

canal (between the sphincters), ano-coccygeal body and lower pieces of coccyx.

The most anterior fibres curve backwards round the side of prostate or of vagina, and are inserted into the perineal body ; but a large bundle of anterior fibres sweeps backwards, above the medial part of the posterior fibres, to gain insertion into coccyx and ano-coccygeal body, and the most medial of them run along the side of anal canal to meet their fellows behind it and form with them a sling around the upper part of the canal.

Nerves : Inf. hæmorrhoidal (s. 2, 3) ; twigs from s. 3, 4, 5.

Actions.—" Anterior " borders of the two muscles can elevate the prostate or compress the vagina. The sling can compress the upper end of anal canal and increase the angle between it and rectum, and so prevent untimely descent of fæces. The sling is relaxed during defæcation ; but the fibres inserted into anal canal pull the canal upwards over descending fæces. Whole muscle, acting with its fellow, raises the pelvic floor, and assists the muscles of the anterior abdominal wall to compress the viscera during forced expiration, etc. (*See* p. 361.)

Relations of Levator Ani.—*Perineal surface* is clothed with a thin layer of fascia called **anal fascia ;** forms nearly the whole of the medial wall of ischio-rectal fossa ; is related to the **ischio-rectal pad** of fat (which covers it), and to perineal branch of 4 s. nerve and branches of inferior rectal vessels and inf. hæmorrhoidal nerve.

Pelvic surface is covered with loose **fascia** and a quantity of **fat.**

In male : **bladder** is related to its anterior part ; **rectum,** to its posterior part ; **seminal vesicle,** between these two ; **prostate,** below bladder ; **ureter,** curving forwards to reach the postero-lateral angle of bladder, at the upper end of the vesicle ; **vas deferens,** turning medially above the ureter ; and **inferior vesical vessels,** running forwards, below the ureter, towards bladder.

In female : **bladder** is related to the anterior part ; **rectum,** to the posterior part ; **vagina,** between these two ; attachment of root of **broad lig.,** lateral to vagina ; **ureter,** running forwards towards bladder, below broad lig., close to vagina ; **uterine vessels,** running forwards and medially to the root of broad lig., and then medially between its layers above ureter ; and **vaginal vessels,** running forwards to vagina and bladder.

Posterior border of levator is edge to edge with **coccygeus,** or overlaps it.

"Anterior" border is the thickest part of the muscle. It is separated from its fellow by a triangular or elliptical interval largely occupied by the lower part of the prostate or by the vagina.

Between the sphincter urethræ and the plane of the anterior borders of the levatores, there is a small interval occupied by : (1) fat and fascia ; (2) recto-urethralis muscle ; (3) lower part of prostate or a small portion of vagina ; (4) urethra, contained within the prostate, or closely attached to the anterior wall of the vagina ; (5) a plexus of veins around prostate or vagina.

Pelvic Fascia.—A loose, fibrous spongework, largely permeated by extensions from the fat that separates it from the peritoneum; it is condensed into sheets where it clothes the muscles and enheaths the viscera. The nerves lie outside the fascia (except sympathetic plexuses and obturator); and the pelvic splanchnic nerves pierce the fascia to reach the viscera. The vessels lie in the fat between the fascia and peritoneum; they have to pierce the fascia both to reach viscera and to escape from pelvis.

The most conspicuous parts of it are the arcus tendineus, medial pubo-prostatic or pubo-vesical ligaments, utero-sacral ligaments, recto-vesical septum and the obturator fascia (p. 382).

Arcus tendineus is not important. It is a curved, linear band that stretches from back of pubis to ischial spine, and often appears as a *white line* in the fascia. Its *posterior part* is a thickening of obturator fascia at the origin of posterior part of levator ani; its *anterior part* is a thickening of the fascia that covers the anterior part of levator near its origin.

Medial Pubo-Prostatic Ligs.—A pair of strong, short, thick, important bands that fix the prostate and neck of bladder. They spring from the lower part of the back of the pubes at the sides of the symphysis, and pass backwards to fuse with the front of the strong fascia that surrounds the base of the prostate and the neck of the bladder. They are the resisting ligaments that intercept the fingers pushed down between the bladder and pubis at the sides of the symphysis. A thin, fibrous lamina unites them across the median plane; and, together, they roof over the anterior part of the space between the "anterior" borders of the levatores. The lateral edge of each is continuous with the *lateral pubo-prostatic lig.* That ligament is merely the fascia that covers the pelvic surface of levator at and near its anterior border, and it fuses with the fascia at the side of the base of the prostate and the neck of the bladder.

Pubo-Vesical Ligs.—Medial and lateral—are the corresponding ligaments in the female, the difference being that, in the absence of a prostate, their visceral connexion is neck of bladder alone.

Utero-sacral ligs. are a pair of bands that curve backwards from cervix uteri to the sacrum at the sides of the rectum. Usually weak, but may be strong enough to raise up a pair of ridges of peritoneum called *recto-uterine folds*.

Recto-Vesical Septum.—A sheet of fascia that extends from the perineal body to the peritoneum of the floor of the recto-vesical pouch. It separates the lower part of the rectum from the seminal vesicles and vasa deferentia and from the prostate, and it is fused with the fascial sheath of the prostate. It owes its thickness to the

fact that it is largely the remains of the peritoneum that lined a recess between rectum and prostate in early fœtal life.

Students are expressly advised not to burden the memory with any detailed account of pelvic fascia: even if they can understand it.

Retropubic Space.—A space between the bladder and the ventral pelvic wall, filled with areolar tissue and a quantity of fat called the **retropubic pad of fat.**

It extends on each side as far as the internal iliac artery and its visceral branches, and is limited below by the pubo-prostatic (or pubo-vesical) ligaments and the fascia that clothes levator ani. Superiorly, it is continuous with the interval between peritoneum and fascia transversalis that extends up to umbilicus and is limited on each side by the lateral umbilical lig. ; that interval is occupied by extraperitoneal fat, and by the median umbilical lig., which bisects it.

Nerves of Pelvis.—Sympathetic trunk ; sympathetic plexuses ; obturator nerve ; lumbo-sacral trunk ; sacral nerves ; coccygeal nerve.

Sympathetic Trunk.—Leaves abdomen and enters pelvis by crossing the margin of the ala of sacrum near the sacral promontory. Runs over the pelvic surface of sacrum, crossing the medial margins of the anterior sacral foramina. Ends on the coccyx by joining its fellow in a median ganglion called *ganglion impar*.

The upper part is covered only with peritoneum, which separates it from intestine ; but the lower part is behind the rectum.

Ganglia.—Usually one at each sacral foramen ; and ganglion impar.

Branches.—Arise from the ganglia.

1. Grey rami communicantes to the anterior primary rami of sacral and coccygeal nerves.
2. Filaments to the plexus around median sacral artery.
3. Branches from upper ganglia to the pelvic plexus.
4. Branches from lower ganglia to the rectum.
5. Filaments from ganglion impar to glomus coccygeum.

Hypogastric Plexus.—Is under cover of peritoneum, chiefly in the abdomen—on 5th lumbar vertebra and left common iliac vein between the common iliac arteries—but its lower part is on the sacral promontory. (It has been called the "presacral nerve" ; but it is a plexus, not a nerve, and it merely touches the sacrum.)

Formed as a continuation of aortic plexus complemented by branches from lower lumbar ganglia which cross the upper part of the common iliac arteries.

Sends secondary plexuses to the external iliac and median sacral arteries and then divides at the sacral promontory into a right and a left pelvic plexus.

Pelvic Plexus.—Inclines sidewards to reach the internal iliac artery and to surround it. Receives filaments from upper sacral

anglia ; and minute *ganglia* are placed on the points where these laments join the plexus. Divides into secondary plexuses that ccompany the branches of the artery and are distributed with them —largest around visceral branches. These visceral plexuses are oined by the branches of the pelvic splanchnic nerves; and these ranches are relayed in microscopic ganglia which lie in the lexuses on the walls of the viscera.

Obturator Nerve.—Arises in the psoas from L. 2, 3, 4. Emerges hrough the postero-medial margin of psoas at the back part of the elvic brim ; pierces the fascia on psoas and enters the pelvis.

Runs downwards and forwards along the side-wall of pelvis n front of (or above) the obturator vessels, on the edge of bturator internus—*i.e.* not far from the brim. Leaves the pelvis hrough the anterior or upper part of obturator foramen to enter he thigh, where it supplies the hip-joint and the adductor muscles.

Covered with peritoneum, which separates it from the intestine nd ovary.

Under cover of peritoneum, it is crossed, at its entrance into elvis, by the internal iliac vessels and ureter, and then, from behind orwards, by the umbilical artery, which is thereafter in front of it. An inch below the ureter, it is crossed by the attachment of the road ligament of uterus ; and, near its exit, by the round lig. of terus or by the vas deferens.

Gives no branches in the abdomen or the pelvis.

Lumbo-Sacral Trunk.—A very thick cord. Formed on the ala f sacrum by the anterior primary ramus of L. 5 and the descending ranch of L. 4. Slants downwards and sidewards over the ala, asses into pelvis, runs obliquely across the upper part of the pelvic urface of the sacro-iliac joint and joins the first sacral nerve on he pelvic surface of piriformis. The internal iliac vessels and their nterior divisions are in front of it. Their posterior divisions, ecoming superior gluteal, cross its medial side to pass between it nd the first sacral nerve.

SACRAL AND COCCYGEAL NERVES.—Each has two roots—*ee* Lumbar Nerves, p. 379. The roots are very long ; for the acral region of spinal cord is opposite the last thoracic and first umbar vertebræ, and the roots do not unite until they reach the acral canal. In the upper part of the sacral canal, the roots are ithin the tubes of arachnoid and dura mater. The roots of the pper four sacral pierce the tubes (dragging off sheaths) and unite o form the nerve-trunks opposite the sacral foramina ; and each runk straightway divides into primary rami. The roots of s. 5 ierce the lower end of the tubes and unite in the lower part of the anal. The roots of the coccygeal nerve unite inside the tubes ; the runk pierces the tubes and then divides into primary rami.

Posterior Primary Rami.—Those of the upper four sacral pass hrough the posterior sacral foramina. They supply multifidus nd sacro-spinalis on the back of the sacrum, and the *upper three* **ive off cutaneous branches** which supply skin on the back of the acrum and then pass into the gluteal region.

Posterior rami of s. 5 and the coccygeal nerve are exceedingly slender. They descend through the sacral hiatus, pierce the overlying ligament and end in skin on the back of the coccyx.

Anterior Primary Rami.—Much thicker than posterior rami, but diminish rapidly below the second.

Those of the upper four sacral pass through anterior sacral foramina, slant downwards and unite with each other and with the lumbo-sacral trunk to form the *sacral plexus*. S. 4 shares also in the *coccygeal plexus*.

S. 5 and the coccygeal descend through the sacral hiatus, turn sidewards and forwards—s. above the transverse process of coccyx and c. below it. Pierce the sacro-tuberous and sacro-spinous ligs. and coccygeus. Unite with each other and with a branch of s. 4 to form the *coccygeal plexus*.

As the anterior rami enter the pelvis, each receives a grey ramus communicans from the sympathetic trunk. And before they form the plexuses they give off branches :—(*a*) To piriformis from s. 1, 2. (*b*) To coccygeus and levator ani from the others. (*c*) Pelvic splanchnic.

Pelvic Splanchnic Nerves.—Very slender. Arise from s. 2 and 3 or s. 3 and 4. Join the visceral sympathetic plexuses and are distributed by them to pelvic organs and the lower part of colon.

SACRAL PLEXUS.—Formed by the lumbo-sacral trunk and anterior primary rami of the upper three sacral nerves and part of the fourth.

These roots of the plexus converge upon the lower part of the greater sciatic foramen, dividing and uniting with one another to form the two terminal branches of the plexus—*sciatic* laterally and *pudendal* medially. The other branches of the plexus spring from its pelvic and dorsal surfaces.

The plexus lies mainly on piriformis but its upper part is on the sacrum and sacro-iliac joint—s. 1 crossing the joint at the upper border of piriformis before it passes on to piriformis.

The plexus is behind the fascia of piriformis, the ureter, and the internal iliac vessels and their branches and tributaries. The rectum overlaps the lower part medially ; and the upper part is separated by fat and peritoneum from ileum or pelvic colon. Gluteal vessels pass between the roots of the plexus—the superior between lumbo-sacral trunk and s. 1, and the inferior between s. 1 and s. 2.

Terminal Branches.—Sciatic ; pudendal.

Sciatic Nerve.—Arises from the lumbo-sacral trunk and the upper three sacral nerves and is made therefore of fibres of L. 4, 5 and s. 1, 2, 3.

Begins on the front of piriformis between the muscle and its fascia ; leaves the pelvis at the lower border of the muscle through the lower part of the greater sciatic foramen ; passes through the gluteal region into the back of the thigh ; ends half way down the thigh by dividing into lateral and medial popliteal.

Sometimes these two nerves arise directly from the plexus. The ıteral popliteal nerve then pierces piriformis and the medial nerve akes the usual route below it.

Pudendal Nerve.—Formed by separate roots from s. 2, 3, 4. Begins on the front of piriformis, between the muscle and its fascia. oon leaves the pelvis through the lower part of the greater sciatic ɔramen, between piriformis and coccygeus, medial to the internal udendal vessels. (*See* p. 403.)

Branches from Pelvic Surface of Sacral Plexus.—Nerve to quadratus femoris; nerve to obturator internus.

Nerve to Quadratus Femoris.—Springs from the lumbo-sacral runk and the first sacral; its fibres come, therefore, from L. 4, 5 nd S. 1. Runs down over the pelvic surface of sciatic nerve and eaves the pelvis with it.

Nerve to Obturator Internus.—Arises from lumbo-sacral trunk nd the upper two sacral. Fibres from L. 5; S. 1, 2. Runs down ver the plexus and piriformis and leaves the pelvis about midway etween sciatic and pudendal.

Branches from Dorsal Surface of Sacral Plexus.—Superior gluteal; nferior gluteal; posterior cutaneous of thigh; perforating utaneous; perineal branch of fourth sacral.

Superior Gluteal Nerve.—Arises from lumbo-sacral trunk and rst sacral, and is therefore above piriformis. Fibres from L. 4, 5; 1. Leaves the pelvis through the upper part of the greater sciatic ramen.

Inferior Gluteal Nerve.—Arises from lumbo-sacral trunk and e upper two sacral. Fibres from L. 5; S. 1, 2. Runs along the ack of the sciatic nerve and out of the pelvis behind it or at its edial side.

Posterior Cutaneous Nerve of Thigh.—Arises from S. 1, 2, 3. ccompanies the inferior gluteal.

Perforating Cutaneous Nerve.—From S. 2, 3. Runs down over riformis on to coccygeus. Either pierces coccygeus or slips out tween it and levator ani. Bends backwards to perforate the sacrotberous lig. and gluteus maximus; and curves upwards to supply e skin of the lower medial part of the buttock.

Perineal Branch of Fourth Sacral.—Pierces coccygeus; reads its way downwards between it and the sacro-spinous and cro-tuberous ligs. (supplying them); enters the posterior corner ischio-rectal fossa close by the coccyx; runs forwards over the rineal surface of levator ani to supply sphincter ani externus and e skin around the anus.

Coccygeal Plexus.—Not important. Formed by anterior mary rami of the coccygeal and S. 5 and part of S. 4. Lies on e pelvic surface of coccygeus. Gives branches to coccygeus and ator ani. Sends branches back through coccygeus and the ligaents to skin over the coccyx and between coccyx and anus.

Arteries of Pelvis.—Median sacral; superior rectal; ovarian; internal iliac and its branches.

Median Sacral Artery.—Arises from the back of aorta half an inch or less above its bifurcation. Descends over the lower two lumbar vertebræ and the pelvic surface of sacrum on to the coccyx to end in the glomus coccygeum.

In abdomen, it is behind aorta, left common iliac vein, hypogastric plexus and peritoneum. In pelvis, peritoneum separates its upper part from intestines, but its lower part is behind the rectum.

Venæ comitantes of its pelvic part unite to form a single vein which ascends along its right side and ends in the left common iliac vein.

Branches.—(1) Fifth lumbar (p. 376). (2) Small branches run to the anterior sacral foramina and anastomose with lateral sacral. (3) Small branches to the back of the rectum.

Glomus Coccygeum.—A small nodule of unknown function. On pelvic surface of coccyx. Clumps of cells amidst areolar tissue, with minute vessels and sympathetic filaments.

Superior Rectal Artery.—Continuation of inferior mesenteric. Begins on the middle of the left common iliac artery. Enters the medial limb of the pelvic mesocolon at once and runs in its root across the left common iliac vein and sympathetic trunk to the back of the beginning of the rectum at the middle piece of the sacrum. Divides there into two branches which diverge, give branches to the rectum, subdivide and sink into its side-walls about its middle, and descend, branching in the submucous coat, to its lower end.

Superior rectal vein runs up alongside the artery and becomes the inferior mesenteric vein when it reaches the left common iliac artery.

Ovarian Artery.—Long and slender. Arises from aorta a little below the renal.

Runs down over the back-wall of abdominal cavity to reach the external artery at its lateral side. Crosses that artery about an inch below its origin. Enters the infundibulo-pelvic ligament and descends in it to the ovary. Supplies the ovary and sends branches to the uterine tube, one of which anastomoses with a branch of the uterine artery.

Veins of the ovary form a *pampiniform plexus* around the pelvic part of the artery. Two veins arise out of the plexus at the pelvic brim and soon unite into a single *ovarian vein*, which ascends alongside the artery to end—the *right* in inferior vena cava, the *left* in the left renal vein.

Internal Iliac Artery.—One of the two branches of common iliac. Widest artery in the pelvis. About an inch and a half long.

Begins in abdomen on psoas major opposite sacro-iliac joint at the level of lumbo-sacral joint. Passes backwards and slightly downwards across the medial surface of psoas into the back part of pelvis and soon ends—near the upper margin of the greater sciatic

oramen—by splitting into an anterior and a posterior division, rom which its branches arise.

Its vein is *above and behind* it; the ureter *below and in front.* 'eritoneum and intestine are *medial.* *Laterally*, the external iliac ein is between it and psoas, and the obturator nerve between it nd the side-wall of pelvis.

Branches of Posterior Division of Internal Iliac.—Ilio-lumbar p. 377); lateral sacral; superior gluteal.

Lateral Sacral Arteries.—Two. Run downwards and medially ver the sacral nerves. Divide to enter the four anterior sacral oramina. Supply the contents of sacral canal; and their terminal ranches come out through the posterior foramina to supply muscles nd skin on the back of sacrum.

Superior Gluteal Artery.—The continuation of the posterior ivision; and it is the widest branch of internal iliac.

Runs backwards through the fascia and between lumbo-sacral runk and first sacral nerve across the pelvic surface of sacro-iliac oint, and out of the pelvis above piriformis through the uppermost art of the greater sciatic foramen with the superior gluteal nerve.

Branches of Anterior Division in the Male.—Umbilical (which ives off superior vesical); obturator; middle rectal; inferior vesical; nd two terminal branches—pudendal and inferior gluteal.

In the female.—Umbilical (which gives off superior vesical); bturator; middle rectal; vaginal; uterine; and two terminal ranches—pudendal and inferior gluteal.

Umbilical Artery.—Springs from the end of the iliac trunk or he beginning of the anterior division. Crosses the obturator nerve nd runs downwards and forwards in front of it along the side-wall f pelvis near the brim, parallel to the lateral margin of bladder, t a little distance from an empty bladder but in contact with a ull one. Covered with peritoneum. Crossed near its origin by the reter, an inch below that, by the attachment of broad lig., and, ear the bladder, by the round lig. or by vas deferens.

Gives off two or three **superior vesical arteries** to the upper part f the bladder. Up to that point it has a lumen. Beyond that it s a fibrous cord called the *lateral umbilical lig.* That ligament asses out of the pelvis and runs up in the extraperitoneal fat of nterior abdominal wall to the umbilicus.

Has no companion vein, for the umbilical vein becomes the lig. eres of liver.

Obturator Artery.—Arises near the umbilical. Runs down- ards and forwards along the side-wall of pelvis, and escapes hrough the anterior part of the obturator foramen.

Behind or below the nerve, between the nerve and the vein; he order is therefore—nerve, artery, vein, from before backwards or bove downwards. (Contrast with intercostal nerve and vessels.) overed with peritoneum and crossed by the same structures as the mbilical.

Branches.—(1) Small unnamed branches to fat, bladder and obturator internus. (2) *Pubic branch* ramifies on the pelvic surface of pubis, anastomoses with pubic branch of inferior epigastric, and may enlarge to form part of the abnormal obturator.

Abnormal Obturator Artery.—Present in 30 per cent. Replaces obturator wholly or in part. Springs from inferior epigastric, runs downwards across the back of the inguinal ligament and the pectineal part of that ligament, and across the pubic bone to the obturator foramen.

May be present on one or both sides. May or may not be accompanied by a vein of comparable size. Or an abnormal vein may be present alone on one or both sides.

Middle Rectal Artery.—Arises at a variable point. Runs medially in the fat in front of sacral plexus to the rectum. Its branches supply not only the rectum but also the vagina or the prostate, seminal vesicle and vas deferens. A special condensation of areolar tissue around it helps to hold the rectum in place.

Inferior Vesical Artery.—Only in the male. Arises near the middle rectal. Runs forwards in the fat between peritoneum and levator ani, and, near the bladder, is crossed by the ureter and vas deferens. Gives branches to the lower and hinder parts of bladder, to prostate, seminal vesicle and ureter; and it gives off the **artery of vas deferens,** which supplies the vas and accompanies it as far as the testis and anastomoses with the testicular artery.

Vaginal Artery.—Takes the place of inferior vesical and is larger. Arises near middle rectal. Runs in the fat between peritoneum and levator ani towards the bladder. Though some of its branches reach the lower and hinder parts of the bladder, most of them are intercepted by the vagina and a few are given to the rectum.

Uterine Artery.—Large and tortuous. Arises either independently or with one of the preceding. Runs forwards in the fat between peritoneum and levator ani to the root of the broad lig., and then medially between the layers of the ligament above the ureter and vagina, and forwards along the side of the uterus.

Supplies the uterus and gives branches also to the vagina, round ligament and uterine tube. A branch to the tube anastomoses with a branch of ovarian.

Internal Pudendal Artery.—A terminal branch of the anterior division of internal iliac. Runs downwards and backwards in the fat in front of sacral plexus and piriformis; pierces the fascia of piriformis and leaves the pelvis through the lower part of greater sciatic foramen between piriformis and the origin of coccygeus. (*See also* p. 402.)

Inferior Gluteal Artery.—The other terminal branch of the anterior division and its largest branch. Runs downwards and backwards in the fat in front of the first sacral nerve and piriformis, usually behind and lateral to internal pudendal; pierces the fascia of piriformis and passes between the first and second sacral nerves (sometimes 2 and 3); leaves the pelvis through the lower part of the greater sciatic foramen, with the inferior gluteal nerve, at the medial side of the sciatic nerve or behind it.

Veins of Pelvis.—Internal iliac and its tributaries; median sacral (p. 390); superior rectal (p. 390); ovarian (p. 390); and the plexuses in the fat and on the viscera which give rise to the superior rectal and the visceral tributaries of the internal iliac.

Plexuses.—The veins are large and numerous, and anastomosis is very free. Networks therefore abound in the fat and on the walls of viscera and in their submucous coats; and the plexuses of one viscus communicate freely with those of its neighbours through the plexuses in the fat. The plexuses are named after the viscera—*rectal, etc.* The rectal plexus is drained by the superior rectal vein, which is part of the portal system, and by the middle and inferior rectal veins, which are systemic veins; and the rectum is therefore one of the chief meeting-places of portal and systemic veins.

Internal Iliac Vein.—Widest vein in the pelvis, but little more than an inch in length. Lies on the side-wall of pelvis very near the dorsal wall.

Begins just above the greater sciatic notch by the union of the veins that accompany the gluteal arteries and other branches of internal iliac. Passes forwards and slightly upwards out of the pelvis on to the medial surface of psoas, where it joins the external iliac vein to form the common iliac.

It is *above and behind* its artery, *below and in front* of the lumbo-sacral trunk and sacro-iliac joint. Peritoneum and intestine are *medial*. *Laterally* there are first the obturator nerve and pelvic wall, and then psoas at the end of the vein.

Tributaries.—Correspond to the branches of internal iliac artery —except ilio-lumbar (whose vein ends in common iliac) and umbilical (which has no companion vein).

LYMPH-GLANDS OF PELVIS.—*See* pp. 457, 458.

VISCERA.—*See under* **Intestine** (pp. 636, 639), **Peritoneum** (pp. 648, 649), **Urogenital System** (p. 657).

PERINEUM

Perineum is the lower end of the trunk and the lower division of the pelvis—shut off from the rest of the pelvis by the levatores ani and the fascia on the sphincter urethræ. Extends from coccyx to pubic symphysis.

On the surface, it is only the floor of the groove between the thighs and between the lower parts of the buttocks. When exposed by the removal of the skin, it is a diamond-shaped space whose boundaries are those of the outlet of pelvis—coccyx, sacro-tuberous ligs., ischial tuberosities, sides of pubic arch (*i.e.* conjoined rami of ischium and pubis) and pubic symphysis. A transverse line

drawn between the ischial tuberosities a little in front of the anus divides the diamond space into an *anal triangle* and a *urogenital triangle*.

Anal Triangle.—Divided into a right and a left ischio-rectal fossa and a median portion occupied by the lower part of the anal canal surrounded by sphincter ani externus.

Superficial Fascia.—In the middle, it is thin, and contains some bundles of non-striped muscle, called *corrugator cutis ani*, which radiate from margins of anus and are attached to the skin around it. On each side, it forms a large, fatty, fibrous pad that fills the ischio-rectal fossa. The **ischio-rectal pad** acts as an elastic cushion that yields before the pressure of a mass of fæces, giving room for the bowel to expand, and springs back again when the mass has passed.

Deep fascia covers the muscles of the walls of ischio-rectal fossa.

Sphincter Ani Externus.—**Superficial part** springs from the tip of the coccyx and the ano-coccygeal body and sweeps forwards by the sides of the anus to the perineal body. **Deep part** encircles the lower two-thirds of the anal canal, overlapping the internal sphincter in the middle third. Posteriorly, the fibres of the two sides join each other; anteriorly, they mingle with each other and with other muscles in the perineal body; superiorly, some fibres of levator mingle with them.

Nerves.—Inferior hæmorrhoidal (s. 2, 3, 4); perineal of s. 4.

(*Sphincter ani internus* is a thickening of the circular fibres of the gut; it surrounds the upper two-thirds of the anal canal.)

Except when fæces are passing, the sphincters are in a state of tonic contraction and keep the side-walls of the anal canal pressed together.

Ischio-Rectal Fossa.—A wedge-shaped space whose base is at the skin of perineum, and whose edge is at the origin of levator ani from the obturator fascia—two inches and a half above the skin posteriorly, where the fossa is deepest.

Boundaries.— *Anterior*: Transverse muscles of the perineum and the fascia that covers them.

Posterior: Sacro-tuberous lig. and the overlying part of gluteus maximus.

Lateral: From without inwards—(*a*) ischium, (*b*) obturator internus, (*c*) obturator fascia and falciform process.

Medial: Levator ani and external sphincter, covered with the sheet of fascia called *anal fascia*.

Contents.—(1) *Ischio-rectal pad*, traversed latero-medially by (2) *inferior rectal vessels and inf. hæmorrhoidal nerve*. (3) *Perineal branch of fourth sacral nerve* (accompanied by slender, unnamed vessels) enters at the posterior angle and runs over levator to the external sphincter. (4) *Posterior scrotal* (*labial* in female) *nerves and*

vessels enter the anterior part of the fossa from the pudendal canal, and run forwards into the urogenital triangle.

Pudendal Canal.—A tunnel in the substance of obturator fascia. It begins at the lesser sciatic foramen, curves forwards and downwards in the side-wall of the ischio-rectal fossa and ends anteriorly, at the side of the pubic arch, by opening into the deep perineal pouch. Its middle part is about an inch and a half above the lower end of the ischium, and its contents can be felt by the finger-tip during the process of dissection.

It **contains**: internal pudendal vessels; perineal division of pudendal nerve, below the vessels; dorsal nerve of penis (or of clitoris), above them.

Urogenital Triangle in Male.—The **skin** presents a median ridge or **raphe** that extends from the anus to the scrotum (and onwards over the scrotum to the penis).

Superficial Fascia.—Two layers. **Superficial layer** is fatty, is continuous with the superficial fascia of the rest of the body, and contains small cutaneous vessels and nerves.

Deeper layer is membranous. *Posteriorly*, it is fused with the posterior border of the perineal membrane, and is pierced there by the posterior scrotal vessels and nerves. *On each side*, it is attached to the side of pubic arch and to the deep fascia on gracilis near its origin from the pubic ramus. *Anteriorly*, it is continuous with the fascia of scrotum, penis, and anterior wall of abdomen (p. 359).

Deep Fascia.—Three layers. (1) An exceedingly delicate layer that covers the superficial muscles. (2) The perineal membrane. (3) A layer of pelvic fascia.

The layer of pelvic fascia mentioned is a loose layer that covers the pelvic surface of the sphincter urethræ and the deep transversus perinei. On each side, it is connected with the obturator fascia. Apex of prostate rests on its upper surface, and it is continuous with the fascial sheath of prostate. Urethra, emerging from prostate, pierces it in the middle.

Perineal Membrane.—A fairly strong fibrous sheet which lies across the pubic archway, and is comparable to the obturator membrane.

Connections and Relations.—*Superiorly*, it is related to the sphincter urethræ and the deep transversus, for it clothes their lower surface.

Its *lower surface* is largely covered by the root of the penis.

At each side, it is attached to the side of the pubic arch.

Its *posterior border* is fused with the posterior borders of the fascia on the upper surface of the deep transversus and the membranous layer of the superficial fascia; in the middle, the fused borders are continuous with the fatty, fibro-muscular nodule, called the *perineal body*, which gives attachment to levator ani, external

sphincter, bulbo-spongiosus and the transverse muscles of perineum (p. 402).

Its *anterior border* is fused with the anterior border of the fascia on the pelvic surface of sphincter urethræ.

These fused anterior borders are thickened to form a band called the *transverse ligament of perineum*. Between that ligament and the inferior ligament of pubic symphysis, there is an oval interval through which the deep dorsal vein of penis passes up into pelvis to end in the network around the prostate.

The perineal membrane is *pierced* by : (1) urethra and the bulbo-urethral ducts, in the middle ; (2) artery of bulb, a little lateral to that ; (3) internal pudendal vessels and dorsal nerve of penis, at the side of the pubic arch.

Deep Perineal Pouch in the Male.—Is the space enclosed between the perineal membrane and the fascia on the pelvic surface of sphincter urethræ and the deep transversus.

Contains :—1. The sheet of muscle whose smaller, posterior part is a pair of muscles called the *deep transversus perinei*, while the rest of it is the *sphincter urethræ* (p. 401).

2. Membranous part of *urethra*, in the middle, enveloped in the sphincter.

3. *Dorsal nerve* of penis and *internal pudendal vessels*, close along the side of the pubic arch.

4. *Artery of bulb*, running medially from internal pudendal to pierce the perineal membrane and enter the bulb of the penis.

5. A pair of *bulbo-urethral glands*, behind urethra.

Bulbo-Urethral Glands.—Function not known. Each is the size of a small pea in a young man, but they shrink with age. Each has a slender **duct** that passes through the perineal membrane with the urethra, and runs along the urethra for an inch before entering it.

Superficial Perineal Pouch.—The space between perineal membrane and the membranous layer of superficial fascia.

It **contains** *the root of the penis* and the *superficial perineal muscles* and *vessels* and *nerves*.

Root of penis comprises a pair of crura penis and the bulb.

(**Body of penis** is made up of three columns of erectile tissue (p. 666)—a pair of **corpora cavernosa penis** united together side by side, and a much more slender **corpus spongiosum,** which lies along the lower surface of the united corpora cavernosa and is traversed lengthwise by the urethra. At the lower part of the pubis, the three corpora separate. Corpora cavernosa diverge from each other and become the crura ; corpus spongiosum enlarges to become the bulb of the penis.)

Crus penis is the continuation of a corpus cavernosum. It passes backwards and sidewards, tapering to a point near the lower end of

the ischium. It lies in a shallow groove on the perineal surface of the side of pubic arch and on the adjoining part of the lower surface of the perineal membrane; it is adherent to both bone and membrane, and it is covered by the ischio-cavernosus muscle.

Bulb of penis is the greatly-enlarged continuation backwards of corpus spongiosum. It lies in the median plane on the lower surface of the perineal membrane; it is adherent to the membrane and is covered by the right and left bulbo-spongiosus muscles; its posterior end is notched in the middle.

Superficial Perineal Muscles.—Bulbo-spongiosus, ischio-cavernosus, superficial transversus perinei—arranged in pairs.

Transverse muscles lie along the posterior border of the perineal membrane, and meet in the perineal body.

Each **ischio-cavernosus** lies on a crus.

Bulbo-spongiosus muscles lie on the bulb, and are united to each other by a median fibrous *raphe* that extends forwards over the bulb from the perineal body; the membranous layer of the superficial fascia is adherent to the raphe. (*See also* p. 402.)

Superficial Perineal Vessels.—Posterior scrotal and transverse perineal arteries and veins.

Posterior scrotal arteries—a **lateral** and a **medial**—spring from the internal pudendal in the pudendal canal, pierce the wall of the canal, enter the anterior part of the ischio-rectal fossa, run forwards, pierce the membranous layer of the superficial fascia, pass either deep or superficial to transversus superficialis muscle, and run on to the wall of the scrotum. The medial one gives off the **transverse perineal**, which runs medially along the transversus muscle.

Superficial Perineal Nerves.—Posterior scrotal; long perineal.

Posterior scrotal nerves—a **lateral** and a **medial**—arise in the pudendal canal from the perineal division of pudendal, and they accompany the arteries.

Long perineal nerve, a branch of the posterior cutaneous of thigh, arises in buttock, runs medially below the ischium, across the back of the hamstrings, curves forwards, pierces fascia lata at the side of the pubic arch, enters the superficial fascia, and runs forwards to the scrotum.

Pudendal Nerve and **Internal Pudendal Artery.**—*See* pp. 402, 403.

Urogenital Triangle in Female.—The **skin** is broken by the orifices of vagina and urethra, and is thrown into folds to form some of the external genital organs and to cover others of them.

External genital organs=*pudendum muliebre* or vulva. They are:—Mons pubis, labia majora, anterior and posterior commissures, pudendal cleft, clitoris, labia minora, frenulum labiorum vestibule of vagina (including the vestibular fossa).

Mons Pubis.—Elevation on the front of the pubis produced by a fatty, fibrous pad that underlies the skin. Covered with hair after puberty. Is the only part of the external genitals visible in a well-made adult standing upright.

Labia Majora.—A pair of large folds of skin that enclose masses of vascular, fatty, fibrous tissue, and are separated by the **pudendal cleft,** into which the vagina and urethra open. Begin at the mons, where the medial margins are united by a low ridge of skin called the **anterior commissure.** Sweep backwards, diminishing in size, to end by joining a slight transverse ridge of skin, in front of the anus, called the **posterior commissure.** Their *lateral surfaces* are covered sparsely with hair after puberty. Their *medial surfaces* are smooth and moist, and are largely in contact with each other, so that the remaining external genitals are hidden in the cleft between them.

Each labium majus corresponds to a half of the scrotum ; lig. teres uteri breaks up and ends in it.

Arteries.—Labial branches of external and internal pudendal.

Nerves.—Perineal of posterior cutaneous ; labial branches of ilio-inguinal and of perineal division of pudendal; genital branch of genito-femoral.

Lymph-vessels end in the glands of the groin.

Clitoris.—Homologue of penis ; has similar structure, vessels, and nerves ; but is very much smaller and does not contain the urethra. Lies hidden in the anterior part of the pudendal cleft.

Body is slender, about an inch long, is attached by one end to the lower part of the pubis. From the pubis it curves forwards and downwards, and its free end is capped by a little swelling called the **glans.**

Body is encased in fasciæ and skin. Deep fascia is blended with a fibrous band, called the **suspensory lig.,** that extends from the dorsum of clitoris to the pubic symphysis. Skin is pinched up on the dorsum and drawn forwards as a fold, called the **prepuce,** that hoods over the anterior part of the body and the glans.

Body is made up of :—

1. A pair of columns of erectile tissue (p. 666), called **corpora cavernosa,** which are fused together side by side.

2. A slender slip of erectile tissue that springs from the commissure of the bulbs (p. 401) and runs forwards along the lower surface of the corpora, and corresponds to the male corpus spongiosum but is not traversed by the urethra. Anteriorly, this slip swells out to form the glans.

At the root of the clitoris, the two corpora widen, separate, diverge and become continuous with the **crura of clitoris,** which run backwards along the sides of pubic arch (p. 400).

Labia Minora.—A pair of thin folds of skin that do not contain fat, placed at the sides of the orifice of the vagina. Posteriorly, they rapidly diminish and end by joining a slight transverse ridge of skin, called **frenulum labiorum,** that lies nearly a finger's breadth behind the vaginal orifice. Anteriorly also, they diminish in size ; and each divides into two folds or ridges of skin. Lateral pair of folds run forwards to become continuous with the prepuce of the

clitoris. Medial pair unite to form a median fold which is attached to the glans and is called the **frenulum of clitoris.**

Vestibule of Vagina.—Space between labia minora. Vagina opens into its middle part; and the orifice is partially closed by a fold of mucous membrane called the *hymen*. *Urethra* opens into the anterior part, immediately in front of the vagina, about an inch behind the clitoris; and its orifice has raised, firm margins that enable it to be identified by touch when a catheter has to be passed.

Vestibular fossa is the posterior part of the vestibule—between the vaginal orifice and the frenulum labiorum.

Superficial Fascia.—Two layers. **Superficial layer** is fatty, is continuous with the superficial fascia of the rest of the body, contains cutaneous vessels and nerves, and is thickened to form the substance of the labia majora.

Deeper layer is membranous. It is almost completely divided into right and left halves by the vagina and urethra. *Anteriorly*, the two halves unite in front of the vestibule of vagina, and are continuous with the deeper layer of the superficial fascia of the front of the abdomen. *Posteriorly*, they end by fusing with the posterior border of the perineal membrane, and are pierced there by the posterior labial vessels and nerves. *At the side*, each half is attached to the side of the pubic arch and to the deep fascia that covers gracilis near its origin from the pubic ramus.

Deep Fascia.—Three layers. (1) A very delicate layer that clothes the superficial muscles. (2) The perineal membrane. (3) A layer of pelvic fascia.

The *layer of pelvic fascia* mentioned is a loose layer that covers the pelvic surface of the sphincter urethræ and deep transversus perinei. On each side it is connected with the obturator fascia. It is pierced by the vagina and by the urethra (which is adherent to the anterior wall of the vagina); and it is continuous superiorly with the fascia around the vagina and bladder.

Perineal Membrane.—Is a stronger sheet of fascia, bridges across the pubic archway, and is in the same plane as the obturator membrane.

Connexions and Relations.—It is interrupted in the middle for the passage of the vagina and urethra, which divide it into a right and a left half.

The *lower surface* of each half is nearly all covered by the bulb of vestibule and crus of clitoris.

Superiorly, it clothes the perineal surface of the sphincter urethræ and the deep transversus.

It is attached, *laterally*, to the side of the pubic arch, and, *medially*, to the side of the vagina.

Posteriorly, the two halves join each other behind the vagina, and their posterior border is fused with the posterior borders of

the fascia above the deep transversus and the membranous layer of the superficial fascia. In the middle, the united posterior borders are continuous with a fatty, fibro-muscular mass, called the *perineal body*, that separates the anal canal from the lower third of the vagina.

Anteriorly also, the halves meet, in front of the vagina and urethra, and their border is fused with the anterior border of the fascia above the sphincter urethræ. The fused anterior borders are thickened to form a band, called **transverse lig. of perineum,** which is separated from the inferior lig. of the pubic symphysis by an oval interval that transmits the dorsal vein of the clitoris—ascending into the pelvis to join the plexus of veins around the neck of the bladder.

Each half of the perineal membrane is *pierced*, at the side of the pubic arch, by the internal pudendal vessels and dorsal nerve of clitoris, and, near the vagina, by the artery of the bulb.

Deep Perineal Pouch in the Female.—Is the space enclosed between the perineal membrane and the fascia on the pelvic surface of the sphincter urethræ and deep transversus.

Contents : 1. A segment of the *vagina*, in the middle.

2. *Urethra*, closely connected with the anterior wall of vagina.

3. The sheet of muscle whose smaller, posterior part is the pair of muscles called the *deep transversus perinei*, while the rest of it (called *sphincter urethræ*) is partly interrupted by the vagina and partly envelops urethra (p. 401).

4. *Dorsal nerve* of clitoris and *internal pudendal vessels*, close along the side of the pubic arch.

5. *Artery of bulb*, running medially from internal pudendal to pierce the perineal membrane and enter the bulb of the vestibule.

Superficial Perineal Pouch.—Is the space between the perineal membrane and the membranous layer of the superficial fascia. Its right and left halves are separated from each other by the lowest part of the vagina.

Each half **contains** *crus of clitoris, bulb of vestibule, greater vestibular gland,* and *superficial perineal muscles* and *vessels* and *nerves.*

Crura of clitoris are continuous with the corpora cavernosa (p. 398) at the lower part of the pubic symphysis, and are very large in comparison with the corpora. From the symphysis, each crus sweeps backwards and sidewards, and tapers to a point near the lower end of the ischium. It lies on the lower surface of the perineal membrane close along the side of the pubic arch, whose perineal surface is slightly grooved to accommodate it ; it is adherent to both the bone and the membrane, and it is covered by the ischio-cavernosus muscle.

Bulb of vestibule corresponds to a half of the bulb of the penis. It is an elongated, piriform mass of erectile tissue (p. 666), whose anterior end is pointed and is connected with its fellow by a slender band

of erectile tissue called the *commissure of the bulbs*. It lies on the lower surface of the perineal membrane (to which it is adherent), closely applied to the side of the lowest part of the vagina, opposite the labium minus and the medial part of the labium majus (p. 398); and it is covered by the bulbo-spongiosus muscle.

Greater Vestibular Gland.—Function not known. About the size of a small bean. Lies on the side of the lowest part of the vagina under cover of the posterior part of the bulb. Its **duct** opens into the groove between the hymen and labium minus. Infection from the exterior can travel along this slender duct, attack the gland, and give rise to a painful abscess in the perineum.

Superficial Perineal Muscles.—Three pairs. Bulbo-spongiosus, ischio-cavernosus and superficial transversus perinei.

The **transverse** muscles lie along the posterior border of the perineal membrane, and meet in the perineal body.

Bulbo-spongiosi lie on the bulbs of the vestibule, and form a kind of sphincter for the lower end of the vagina.

Each **ischio-cavernosus** lies on the crus. (*See also* p. 402.)

Superficial Perineal Vessels.—Posterior labial and transverse perineal arteries and veins.

Posterior labial arteries—a **lateral** and a **medial**—arise from the internal pudendal in the pudendal canal, pierce the wall of the canal to enter the anterior part of the ischio-rectal fossa, run forwards out of the fossa, pierce the membranous layer of the superficial fascia, pass either superficial or deep to the superficial transversus muscle, and end in the skin of labium majus. The medial one sends the **transverse perineal artery** medially along the transverse muscle.

Superficial Perineal Nerves.—Posterior labial; long perineal.

Posterior labial nerves—a **lateral** and a **medial**—arise in the pudendal canal from the perineal division of pudendal (p. 404), and accompany the arteries to the skin of labium majus.

Long perineal nerve arises in buttock from the posterior cutaneous nerve of the thigh; passes medially below the ischium, across the back of the hamstrings; curves forwards and upwards to the side of the pubic arch, where it pierces the fascia lata and enters the superficial fascia to end in the skin of the labium majus.

Muscles of Urogenital Triangle.—Supplied by branches of perineal division of pudendal nerve from S. 2, 3, 4.

The *internal fibres* of the **sphincter urethræ** do not have a bony attachment. In the male they form a muscular tube around the membranous part of the urethra; and they are continuous superiorly with the muscular substance of the prostate. In the female they surround a great part of the urethra and are continuous with the neck of the bladder. The *external fibres* of each half spring from the inferior ramus of the pubis and spread medially to unite

with their fellows in front of the urethra and behind it; but, in the female, many of the posterior fibres are attached to the side of the vagina.

Deep transversus perinei is a bundle that *arises* by tendinous fibres from the junction of the pubic and ischial rami, together with the most posterior fibres of the sphincter; it separates from the sphincter to be *inserted* into the perineal body.

Superficial transversus perinei is not always present. It is a slender slip that *arises* from the ramus of the ischium close to the tuberosity, and runs medially below the posterior margin of the perineal membrane to be *inserted* into the perineal body.

Ischio-cavernosus *arises* by fleshy and tendinous fibres from the ramus of the ischium close to the tuberosity; extends forwards over the crus; becomes aponeurotic and is *inserted* into the sides and lower surface of the crus and into the side and dorsum of the lower part of the corpus cavernosum of penis or of clitoris.

Bulbo-spongiosus in male *arises* from the perineal body and from the median fibrous raphe that lies on the surface of the bulb of the penis and of the adjoining part of corpus spongiosum. The right and left muscles are therefore united by the raphe, and they cover the bulb and part of the corpus spongiosum. Their fibres curve upwards and forwards and are *inserted*, from behind forwards (*a*) into the perineal membrane, (*b*) into a tendinous sheet on the dorsum of corpus spongiosum, and (*c*), by a pair of slips that curve round the body of the penis into the deep fascia of the dorsum.

Bulbo-spongiosus in female is a thin sheet that *arises* from the perineal body, spreads forwards over the bulb of the vestibule and divides into slips to be *inserted* into the side of the pubic arch near the symphysis, into the side of the body of the clitoris and into the deep fascia on its dorsum.

Internal Pudendal Artery.—One of the two terminal branches of the anterior division of internal iliac (the other being the inferior gluteal).

Arises in the posterior part of the pelvis near the side-wall.

Runs downwards and backwards, and pierces the pelvic fascia to leave the pelvis through the lower part of the greater sciatic foramen, between the lower border of piriformis and the origin of coccygeus.

Enters the gluteal region and descends across the back of the tip of the ischial spine, and then passes forwards through the lesser sciatic foramen into the perineum.

Runs forwards and downwards in the side-wall of the ischio-rectal fossa enclosed in the pudendal canal; passes from the canal into the deep perineal pouch (pp. 396, 400), where it runs forwards close along the side of the pubic arch.

Pierces the perineal membrane an inch or less from the pubic symphysis, and ends at once by dividing into two branches—the deep and dorsal arteries of penis or of clitoris.

Though it passes through so many regions, yet its course is not devious: it forms a fairly uniform curve.

Relations.—It is accompanied throughout by venæ comitantes. *In the pelvis*, it runs downwards in the fat in front of piriformis and the sacral plexus; inferior gluteal artery is first behind it, and then lateral to it; as it leaves the pelvis, the pudendal nerve is medial, and the nerve to obturator internus is lateral.

In the gluteal region, it lies between these two nerves, in the fat under cover of gluteus maximus; and it is accompanied by them *through the lesser sciatic foramen.*

In the pudendal canal, the dorsal nerve of penis or of clitoris is above it; the perineal division of pudendal nerve is below it.

In the deep perineal pouch, the dorsal nerve lies between it and the side of the pubic arch, and the fibres of the deep transversus and the sphincter urethræ are above it.

Branches.—(1) Small, unnamed branches to muscles, nerves and fat in the pelvis and in the gluteal region. (2) Inferior rectal. (3) Posterior labial or scrotal (pp. 397, 401). (4) Artery of bulb. (5) Terminal branches—deep and dorsal.

Inferior rectal artery arises in the posterior part of the pudendal canal, runs medially through the ischio-rectal pad of fat, and ramifies to supply gluteus maximus, levator ani, external sphincter and the overlying skin.

Artery of bulb arises in the deep perineal pouch, runs medially below the sphincter urethræ, pierces the perineal membrane and enters the bulb. In the female, it supplies the bulb. In the male, it gives branches to the bulb and the bulbo-urethral gland, and runs on in the substance of the corpus spongiosum to the glans penis.

Deep artery of penis or of clitoris sinks into the crus and runs lengthwise in the substance of corresponding corpus cavernosum, supplying it.

Dorsal artery of penis or of clitoris passes forwards between the crus and the side of the pubic arch to reach the dorsum of penis or of clitoris, and runs onwards giving branches to the corpora and the skin; and its terminal branches end in the glans, prepuce and frenulum. Dorsal nerve is lateral to it; and it is separated from its fellow by the deep dorsal vein.

Pudendal Nerve.—One of the two terminal branches of the sacral plexus. Springs from anterior primary rami of s. 2, 3, 4.

Descends over the front of piriformis between the muscle and its fascia, and leaves the pelvis through the lower part of the greater sciatic foramen between piriformis and coccygeus, medial to the internal pudendal vessels.

Enters the gluteal region and descends across the back of the sacro-spinous lig., under cover of gluteus maximus.

Passes, with the internal pudendal vessels, through the lesser sciatic foramen into the perineum, where it enters the pudendal canal

and divides at once into three branches—inferior hæmorrhoidal, perineal division and dorsal nerve of penis or of clitoris.

Inferior hæmorrhoidal nerve runs medially with the inferior rectal vessels through the ischio-rectal pad, and divides to supply levator ani, external sphincter and skin.

Perineal division runs forwards in the pudendal canal below the internal pudendal vessels, and divides into branches :—

1. *Two posterior scrotal* or *labial nerves* (pp. 397, 401).

2. A *muscular branch* that runs forwards and ends in branches to the muscles of the urogenital triangle and to the bulb.

Dorsal nerve of penis or of clitoris runs forwards first in the pudendal canal above the internal pudendal vessels, and then in the deep perineal pouch between these vessels and the side of the pubic arch ; pierces the perineal membrane with them ; gives a branch to the crus ; accompanies the dorsal artery to the dorsum of the penis or clitoris, lying along the lateral side of the artery.

It gives branches to the skin of the body of the penis, and its terminal filaments supply the skin of the glans.

BLOOD-VASCULAR SYSTEM

Heart, the propulsive organ; **arteries,** the tubes or vessels through which blood is sent from the heart; **veins,** the vessels through which blood returns to the heart; **capillaries,** the microscopic vessels in which arteries end and veins begin.

THE HEART

Shape, Size and Position.—Heart is a hollow muscular organ, more or less cone-shaped, possessing a **base, apex,** and three **surfaces— anterior, inferior,** and **left**—and measuring about 5 in. in length and 3 or 3½ in diameter at its base.

Lies obliquely in middle mediastinum, enclosed in a fibro-serous sac called *pericardium*. Base looks backwards and to the right and slightly upwards; apex points forwards, to the left and downwards. In recumbent posture, base is opposite the bodies of middle four thoracic vertebræ (therefore opposite 4th, 5th, 6th and 7th spines); front of heart is opposite the body of sternum and 3rd, 4th, 5th and 6th costal cartilages of both sides, but to a greater extent on the left than on the right, because two-thirds of the heart is to the left of median plane. In erect posture, the heart is nearly an inch lower.

Divisions, Septa and Sulci.—Heart has four chambers—a right and a left atrium, a right and a left ventricle.

Atria form the basal part of heart—*i.e.* its posterior, right and upper part. Each sends forwards an ear-shaped prolongation, called its **auricle,** from its upper lateral part. Cavities of the two atria are completely separated by a **septum**; but each atrium is in free communication with corresponding ventricle through a large **atrio-ventricular orifice.** The orifice is guarded by a valve which allows blood to pass from atrium to ventricle, but shuts to prevent its return.

Ventricles form the anterior, left and lower part of heart; their cavities also are completely separated by **a septum,** which is continuous postero-superiorly with the septum of the atria.

Division into four chambers is indicated on the surface by grooves. Groove that encircles heart between atria and ventricles is called the **atrio-ventricular groove.** **Anterior** and **inferior interventricular grooves** are longitudinal grooves on the front and on the lower surface, opposite the edges of the septum. **Interatrial groove** is a shallow, ill-defined, almost vertical groove on the back of heart, opposite the edge of the septum.

Interventricular grooves are well-marked, open grooves; atrio-ventricular groove, in most of its length, is a deep, narrow furrow; in the undissected heart, these three grooves are filled with fat and blood-vessels.

Course of the Blood.[1]—Atria receive the blood from the veins (*atrium* = an entrance hall); ventricles drive it into the arteries.

Right atrium receives impure blood (*a*) from walls of heart by some **small veins** and by a larger vessel called **coronary sinus,** and (*b*) from every other part of body by two very large veins called **superior** and **inferior venæ cavæ.** Atrium contracts and sends the blood through **atrio-ventricular orifice** into **right ventricle.**

Right ventricle contracts and propels the impure blood, received from atrium, into a large artery called **pulmonary trunk.** The trunk divides into a **right** and a **left pulmonary artery,** which carry the blood to the **capillaries** in **lungs,** where it gets rid of carbon dioxide and absorbs oxygen. **Pulmonary veins**—two from each lung—collect the purified and oxygenated blood from the capillaries and carry it to **left atrium.**

Left atrium contracts and sends its blood through **atrio-ventricular orifice** into **left ventricle,** which contracts and drives it into a large artery, called **aorta,** whose branches distribute it to all parts of body, including the walls of the heart itself.

While heart is at rest, blood flows from veins into atria and some of it trickles into ventricles. When atria are full, they contract simultaneously; none of the veins that enter heart has a competent valve, and therefore

[1] The *fœtal circulation* is described on p. 451.

their cardiac ends contract at the same time to prevent blood from returning into them. Ventricles contract simultaneously immediately after atria; the increase of pressure shuts atrio-ventricular valves at once, and that prevents return of blood into atria. Entrances to aorta and pulmonary trunk are guarded by valves which shut as soon as ventricles cease to contract; for then the pressure of blood in arteries becomes at once higher than that in ventricles.

External Characters and Relations.—**Apex,** blunt; formed by the left ventricle. Is the lowest part of the heart and farthest forward and to the left. Is opposite the fifth left intercostal space between three and three and a half inches from the median plane, and, in a man, usually an inch below and medial to the nipple. Overlaps the fundus of the stomach, from which it is separated by the pericardium and diaphragm.

Separated from the skin by:—1. Pericardium.
2. Pleura and lung.
3. Contents of fifth space.
4. Upper lateral part of left rectus abdominis.
5. Uppermost part of external oblique aponeurosis.
6. Lowest fibres of pectoralis major and deep fascia.
7. Superficial fascia (containing, in a woman, the lower edge of the mammary gland).

Base is plane vertically but curved horizontally; looks partly backwards and partly to the right and slightly upwards. Is formed by the two atria—rather more by the left than by the right. **Inter-atrial groove** is vertical and ill-defined. The two *right pulmonary veins* enter its upper part, one below the other, immediately to the left of the groove. The two *venæ cavæ* enter it immediately to the right of the upper and lower ends of the groove; their entrances are oblique, especially the superior—whose medial edge is the higher.

Margins of base are *lower*, *left*, and *right*; they separate the base respectively from the lower, left, and anterior surfaces of the heart. But the right margin is highly curved at its middle, where the superior vena cava enters it; and it is divided at that entrance into two parts named *right border* and *upper border*.

Upper border is the highest part of the heart. It extends to the left and slightly backwards and upwards from the right side of the entrance of the superior vena cava to the root of the left auricle; is formed by both atria; and is related to the bifurcation of the pulmonary trunk and to the right pulmonary artery as that artery runs to the right to cross behind the superior vena cava.

Right border curves downwards from the superior vena cava, and ends nearly an inch to the right of and in front of the entrance of the

inferior v. cava; it is formed by the right atrium, and looks forwards as well as to the right; it is related to the right pleura and lung.

Left border descends from the auricle, a little behind the left part of the atrio-ventricular groove; is formed by the left atrium; and is related to the left pleura and lung. *Left pulmonary veins* enter the upper part of the base, one below the other, close to the left border.

Lower border is nearly horizontal and is curved, and is considerably longer than the upper; it is formed by the two atria where they form the lip of the lower part of the *atrio-ventricular groove*; it is related therefore (*a*) to the coronary sinus and left coronary artery, between the left atrium and ventricle, and (*b*) to the small cardiac vein and right coronary artery between the right atrium and ventricle. Inferior vena cava enters the base immediately above the lower border and immediately to the right of the interatrial groove.

Basal part of the heart being thin-walled and flaccid, soon loses its shape when the heart is removed; its direction and relations are seen best in horizontal sections of the thorax.

Part of base formed by right atrium looks to the right and backwards; is related to pericardium, right phrenic nerve and pericardiaco-phrenic vessels, pleura and lung, and the front of the lower part of the lung-root.

Part formed by left atrium looks almost directly backwards. Oblique vein of left atrium slants downwards and to the right over it.

It is separated from the backbone by:—1. Pericardium.

2. Descending aorta, behind pericardium.

3. Œsophagus, first to the right of aorta and then in front of it.

4. The vagi, in a network around œsophagus.

5. Vena azygos, on the right of aorta, behind œsophagus.

6. Thoracic duct, between v. azygos and aorta.

7. Hemiazygos veins, crossing behind aorta and the duct to join v. azygos.

8. Right aortic intercostal arteries, crossing behind the duct and v. azygos.

Left surface of the heart is a wide area, convex in both directions, and narrowing towards the apex. Formed chiefly by the left ventricle—the left atrium forming only a small part postero-superiorly. Upper part is crossed by **atrio-ventricular groove,** containing the left coronary artery and great cardiac vein. Outside the pericardium, it is related to the left phrenic nerve, pericardiaco-phrenic vessels, pleura and lung.

Inferior surface is called the **diaphragmatic surface.** (Note that the inferior surface is not the base.) Flat or slightly concave; looks downwards and slightly backwards; formed by both ventricles —chiefly the left ventricle. Is traversed obliquely, from behind forwards and to the left, by the **inferior interventricular groove,**

which runs from the base to the right side of the apex, and lodges the inferior interventricular artery and middle cardiac vein. Pericardium and diaphragm separate the surface from the liver and stomach.

Anterior surface is called the **sterno-costal surface.** Looks forwards, upwards, and slightly to the left, and its contours are uneven. Formed by all four chambers—the right ventricle having the largest share.

Ventricular part of sterno-costal surface is the larger part; is slightly convex, and is below and to the left. The small artery and vein that run along its lower margin are the *marginal artery* and *small cardiac vein*. *Pulmonary trunk* springs from its uppermost part, concealing the *aorta*. The surface is traversed by the **anterior interventricular groove,** which begins at the left side of the root of the pulmonary trunk and runs obliquely to the lower margin near the apex; the groove lodges the *anterior interventricular artery* and *great cardiac vein*.

Atria form the upper and right parts of the surface. **Right area** is formed by the right atrium. Some veins, called *anterior cardiac*, from the front of the right ventricle and atrium, pierce it near the atrio-ventricular groove. **Upper area** is formed of the upper parts of both atria and their auricles. Owing to the curves and forward projection of the auricles, it is markedly concave from side to side; the concavity lodges the *ascending aorta* and *pulmonary trunk*, which conceal a large part of the area, and are, in turn, overlapped anteriorly by the tips of the auricles. *Superior vena cava* enters the right part of the upper area, behind the root of the right auricle.

A shallow part of the **atrio-ventricular groove** is hidden behind the aorta and pulmonary trunk. The part to the left of them runs horizontally between the left auricle and ventricle and lodges the *left coronary artery* and *great cardiac vein*. The part on their right descends, between the right atrium and ventricle, to the right end of the lower border, and it lodges the *right coronary artery*.

Relations of sterno-costal surface are very numerous.

Inside pericardium, there are the vessels already mentioned aorta, pulmonary trunk, coronary, interventricular and marginal arteries, and great, small, and anterior cardiac veins.

Between pericardium and skin:—1. Lower part of thymus.

2. Both pleuræ and lungs.

3. Sterno-costalis, in front of each pleura.

4. Internal mammary vessels, in front of sterno-costalis, about half an inch from the sternum.

5. Body of sternum and 3rd to 6th costal cartilages, with corresponding intercostal nerves, internal intercostal muscles, and anterior intercostal membranes.

6. At the apical part, a small portion of left rectus abdominis with the overlying external oblique aponeurosis.

7. Pectoralis major and its deep fascia.

8. Superficial fascia (and, in a woman, the mammary gland, which reaches medially to the sternum and downwards to the sixth rib).

Borders of Heart.—The important borders are the margins of the sterno-costal surface—*lower*, *left* and *right*. Right margin is markedly curved at its middle, where the *superior vena cava* enters it, and is divided by that entrance into *upper border* and *right border*.

Upper border, including the part where vena cava enters, is formed by the two atria—chiefly the left atrium. It is a fairly sharp edge, and is also the upper border of the base; its relations are given on p. 407. It is opposite a line drawn *from* the lower border of the second left costal cartilage, an inch and a half from the median line, *to* the upper border of the third right cartilage, an inch from the median line.

Right border is formed by the right atrium. It is merely the line where the right part of the sterno-costal surface merges into the base, and is therefore also the right border of the base. It is opposite a line, slightly convex towards the right, drawn from the third cartilage to the sixth, its ends being an inch from the median line.

Left border is merely the line where the sterno-costal and left surfaces meet. Begins at the left end of the upper border and runs to the apex. Upper fifth is formed by the auricle of the left atrium, and the rest by the left ventricle. It is opposite a curved line, convex towards the left, begun at the point opposite the apex and drawn to the lower border of the second left cartilage, an inch and a half from the median line.

Lower border is a sharp margin that separates the sterno-costal and diaphragmatic surfaces; is wedged in between the anterior chest-wall and diaphragm, being at the level of the xiphi-sternal joint in the median plane. Runs from the lower end of the right border to the apex. The half inch next the apex is formed by the left ventricle and the rest by the right. It is opposite a line drawn from the point for the apex to the sixth right cartilage an inch from the median line.

Area of Complete Cardiac Dullness.—Is the area of chest-wall opposite the part of the front of pericardium and right ventricle that has no covering of lung, and therefore gives out a completely dull note on percussion. The area includes the lower, left quarter of the body of the sternum and the part of the chest-wall immediately to the left of that. Can be marked approximately by: (1) a line along the middle of the sternum from the level of the fourth cartilage down to the xiphi-sternal joint; (2) a horizontal line from the joint towards the left for two inches and a half; (3) a curved line, convex upwards and to the left, that connects the ends of 1 and 2. In the part of the area to the left of sternum, the pericardium is covered by pleura though not by lung. The part behind the sternum is covered by neither lung nor pleura. Right ventricle

is therefore nearest the surface at the lower left quarter of the sternum, and consequently the sound of the tricuspid valve is heard best there.

Chambers of Heart.—**Atrial part** of heart is more or less cuboidal; but the upper part, which rises above the level of the ventricles, is crescentic in outline, owing chiefly to the forward sweep and curve of the auricles.

Right atrium forms the right border of the heart and parts of the base, of the upper border and of the sterno-costal surface. Is largely in front of the left atrium; its posterior wall is therefore the septum, which is set very obliquely.

Tributaries are the superior and inferior venæ cavæ, coronary sinus, anterior cardiac veins and venæ cordis minimæ.

In its interior, the following parts are to be looked for:

1. Opening of *superior vena cava*, at its upper and back part.
2. Opening of *inferior vena cava*, at the lower and back part.
3. *Valve of inferior vena cava* is a thin fold or ridge of the lining membrane of the heart that stands up from the anterior margin of the opening; it has no valvular function after birth.
4. *Atrio-ventricular orifice*, in the lower and front part.
5. Opening of *coronary sinus*, between the atrio-ventricular orifice and the valve of vena cava, close to the septum; partially guarded by the *coronary valve*, which consists of a single flap that overlaps the lower part of the opening.
6. *Fossa ovalis*, a shallow depression on the septum above the opening of the inferior vena cava—about the size of a thumb-print.
7. *Annulus ovalis* is a curved ridge that forms the upper boundary and anterior or left boundary of the fossa; its left part is continuous, inferiorly, with the left end of the valve of vena cava.
8. A slit-like, persisting part of the fœtal *foramen ovale* (p. 452) may be hidden under cover of the upper part of the annulus.
9. *Crista terminalis* is a smooth, vertical ridge on the right wall of the chamber; extends between the anterior margins of the openings of the venæ cavæ. (Occasionally, a shallow, vertical *sulcus terminalis* can be found on the exterior of that wall, opposite the crista—though what is usually identified as the sulcus is an accidental crease. The crista and sulcus indicate the line of union between the fœtal atrium proper and sinus venarum; the sinus forms the smooth part of the fully-formed atrium behind the crista, and receives the venæ cavæ.)
10. *Musculi pectinati* are a number of nearly parallel ridges most of which start at the crista and curve forwards and downwards over the right and anterior wall towards the atrio-ventricular orifice; but some of them are on the walls of the auricle and almost fill its interior.

11. Openings of the *anterior cardiac veins* are on the anterior wall below the auricle.

12. Openings of the *venæ minimæ* are in eight of the two dozen little pits that are scattered here and there. The most constant of them opens near the septum below the superior vena cava.

Left atrium forms parts of the base, of the upper border, of the left surface and of the sterno-costal surface; its auricle forms the uppermost part of the left border.

Tributaries are the four pulmonary veins—an upper and a lower from each lung—and a few venæ cordis minimæ.

Interior is smooth except for a few *musculi pectinati* in its auricle, which is narrower than right auricle and therefore seems to be longer. *Atrio-ventricular orifice* is in its lower and anterior part. Openings of *pulmonary veins* are in its posterior wall close to its right and left borders, and nearer its upper border than its lower.

Ventricular part of heart is cone-shaped. Its **apex** is the apex of the heart. Its **base** looks backwards, to the right and upwards, and is completely covered by the atria and the origins of the aorta and pulmonary trunk. It is partly separated from the atria by the atrio-ventricular groove and its fatty and vascular contents; and the ventricular wall of the groove forms a strip of varying width at the sides and postero-inferiorly. But the greater part of base is occupied by the **four large orifices** enclosed by **fibrous rings** that give attachment to the walls of the two atria and the walls of the two large arteries, and to the flaps of the valves that guard the orifices.

Atrio-ventricular orifices are the larger pair. They are almost side by side in the postero-inferior part of the base; but, when the heart is in position, the right one is farther forward and rather lower; their valves are shut only when the ventricles contract; when the valves are open, their flaps project into the cavities of the ventricles; the flaps, at the ends of their attached borders, are either directly continuous with each other or are connected by small, subsidiary flaps. Right valve has three flaps or cusps (anterior, medial and inferior); hence, the valve and orifice are called **tricuspid.** Left valve has two cusps (anterior and posterior); the valve and orifice are therefore bicuspid, but they are more commonly called **mitral,** because the flaps are shaped like a bishop's mitre.

Aortic orifice is above the interval between the atrio-ventricular orifices. About an inch in diameter. **Valve** has three flaps or *cusps—anterior, right posterior* and *left posterior.* **Pulmonary orifice** is above the aortic and farther forward; and it is more to the left, though it is in the right ventricle. Diameter is about an inch; its **valve** also has three *cusps—posterior, right anterior* and *left anterior.*

Cusps of the two arterial valves are similar. A thickening in the middle of the free edge of each cusp is called the **nodule**; the part on each side of nodule is thinner than the rest of the cusp, and, being semilunar in outline, is called the **lunule.** When the valve is

shut, the ventricular surfaces of nodules and lunules of the three cusps are pressed together and their edges look into the artery. Valves are open only while the ventricles are contracting; and the cusps then project into the arteries, close to their walls.

At the root of the aorta, there is an outward bulging of the wall opposite each cusp. These bulgings are called **aortic sinuses**—an anterior and two posterior. Pulmonary trunk has similar, but shallower, sinuses at its root. The blood in these sinuses prevents the cusps from sticking to the wall of the artery and failing to shut.

Fibrous rings around the aortic and atrio-ventricular orifices are connected together by a small fibrous body, called the **fibrous trigone**, which is continuous with the ventricular septum; in some animals, it is ossified to form the *os cordis*.

Septum of ventricles is very oblique, and the right ventricle is therefore partly in front of the left. Septum is curved with its convexity towards the right ventricle; the cavity of the right ventricle is therefore crescentic in section, and the cavity of the left is nearly circular. Nearly the whole of the septum is fleshy; but there is a small, oval, **membranous part**, immediately below the aortic orifice, opposite the interval between the anterior and right posterior cusps, and continuous posteriorly with the septum of the atria. The atrio-ventricular orifices are not quite side by side, and the fibrous ring of the right orifice crosses the membranous part of the ventricular septum; the anterior half of the membranous part is therefore between the ventricles, but its posterior half is between the left ventricle and right atrium.

Right ventricle forms a large part of the sterno-costal surface, the smaller part of the diaphragmatic surface and nearly the whole lower border. On the sterno-costal surface, its upper part is prolonged upwards and to the left for nearly an inch as a wide, funnel-shaped tube, called the **infundibulum**, whose narrower, upper end gives origin to the pulmonary trunk; infundibulum lies in front of the root of the aorta, and is attached to it by a tendinous prolongation from the septum. The infundibulum is therefore the uppermost part of the ventricle, immediately below the root of the pulmonary trunk; it is peculiar in that the inner surface of its wall is smooth, while that of the rest of the ventricle is roughened by trabeculæ carneæ and papillary muscles.

In the interior, the following parts are to be looked for:—trabeculæ carneæ, papillary muscles, chordæ tendineæ, tricuspid valve, infundibulo-ventricular crest, and the cavity of the infundibulum leading up to the pulmonary valve.

Trabeculæ carneæ are fleshy elevations of two kinds—*ridges* and *bridges*. The bridges are bands attached at each end and free in the middle. Vary in size and are very numerous—crossing and uniting with one another, making a coarse, spongy meshwork on the wall. The largest of them, called the **moderator band**, crosses the cavity,

being attached by one end to the septum and by the other to the sterno-costal wall at the root of the anterior papillary muscle.

Papillary muscles are conical projections whose apices give rise to a number of slender, fibrous threads called **chordæ tendineæ.** Chordæ are inserted into the free edges and ventricular surfaces of the flaps of the tricuspid valve, leaving the atrial surfaces smooth for the blood to flow over as it runs from atrium to ventricle. When the ventricular walls contract and the tricuspid valve is shut, the papillary muscles also contract, and their chordæ prevent the flaps from being driven into the atrium.

There are three groups of chordæ tendineæ. One group springs from the large **anterior papillary muscle,** which juts from the sterno-costal wall. Another springs from the **inferior papillary muscle,** which is smaller and irregular, and juts from the diaphragmatic wall. The third group springs from a number of little nipples on the septum, collectively called the **septal papillary muscle.**

Each group is inserted not into one flap but into the contiguous halves of two flaps—the anterior group into the anterior and inferior flaps, the inferior group into the inferior and medial flaps, and the septal group into the medial and anterior flaps.

Tricuspid orifice is situated in the posterior and right end of the ventricle, and is separated from the pulmonary orifice by the length of the infundibulum. Large enough to admit three fingers; and its **valve** has three flaps or cusps. Cusps are more or less triangular in outline, with their bases attached to the fibrous ring. **Anterior cusp,** the largest, is placed between the orifice and the lower end of the infundibulum; the **inferior cusp** is related to the diaphragmatic wall; and the **medial cusp** is applied to the septum.

Infundibulo-ventricular crest is a smooth, blunt muscular ridge that begins in the posterior wall of the infundibulum and curves to the right and downwards, along the root of the anterior cusp, and merges into the sterno-costal wall.

Left ventricle forms the apex of the heart, nearly the whole of the left border and left surface, the greater part of the diaphragmatic surface, and a small part of the sterno-costal surface. Aorta springs from its uppermost part, anteriorly. Its walls are thrice as thick as those of the right ventricle.

In the interior, the following parts are to be looked for:—aortic vestibule, trabeculæ carneæ, papillary muscles, chordæ tendineæ, and mitral valve.

Aortic vestibule is the part of the cavity immediately below the aortic valve (p. 412). Bounded by the membranous part of the septum and the anterior cusp of the mitral valve; its walls are therefore smooth, while the walls of the rest of the cavity are roughened by trabeculæ carneæ. Note that the aortic and mitral orifices are close together, being separated by little more than the

thickness of the anterior cusp of the mitral valve, but the orifices of the right ventricle are an inch apart.

Trabeculæ carneæ resemble those of the right ventricle; but the coarse spongework of bridges is deeper, and there is very seldom a moderator band.

Two papillary muscles. **Superior** springs from the sterno-costal wall; **inferior** springs from the diaphragmatic wall. Larger than those of the right ventricle, and their **chordæ tendineæ** are thicker but less numerous. Chordæ of each are distributed to the contiguous halves of the two cusps of the mitral valve. Inserted into the free edges and ventricular surface of the posterior flap, but only into the edges of the anterior flap, leaving both of its surfaces smooth, because the blood flows over the atrial surface when entering the ventricle, and over the ventricular surface when it passes towards the aorta.

Mitral orifice is in the posterior and right end of the ventricle, below the aortic orifice. Large enough to admit two fingers; and is guarded by a valve of two flaps or **cusps**—**anterior** and **posterior**—which are larger and thicker than those of the tricuspid valve. Cusps are triangular in outline, and their bases are attached to the fibrous ring around the orifice. Anterior cusp is the larger, and is smooth on both surfaces.

Sounds of Cardiac Valves.—Sounds made by the valves of the heart, when they shut, are conducted along the walls of the ventricles and the arteries, and are heard best where the ventricles and large arteries are nearest the surface of the body.

Sound of the **mitral** valve is conducted along the left ventricle and is heard best on the front of the chest *opposite the apex*, for the left ventricle is nearest the surface there.

Sound of the **tricuspid** valve is heard best where the right ventricle is nearest the surface, and that is at the *lower left quarter of the body of the sternum.*

Ascending aorta passes forwards as well as upwards and to the right, and is nearest the surface at its termination, behind the junction of the right margin of the sternum and the second costal cartilage. Sound of the **aortic** valve is therefore heard best at the *second right cartilage* where it joins the sternum; and, consequently, that cartilage is sometimes called the *aortic cartilage.*

Sound of the **pulmonary** valve is heard best at the *third left cartilage* close to the sternum, *i.e.* opposite the valve itself; for the pulmonary trunk recedes from the surface as it passes upwards.

Structure of Heart.—(1) A thin, transparent, outer covering, called *epicardium*; (2) a muscular wall, called *myocardium*; (3) a lining membrane, called *endocardium.*

Epicardium is the visceral layer of the serous pericardium (p. 419 and footnote on p. 627). Vessels that supply the heart lie between

the epicardium and myocardium; and so does the fat, which is most abundant in the grooves and along the borders.

Myocardium consists of a kind of striped muscle found only in the heart. Only about one line (2 mm.) in thickness in the atria, for they have to send blood only into the ventricles; slightly thicker in the left atrium than in the right. Three times as thick in the right ventricle, which has to drive the blood through the lungs. Three times as thick in the left ventricle as in the right, for the left has to drive the blood through the whole body. Fleshy part of the septum is of the thickness of the left ventricular wall. Fleshy fibres of the atria are separated from those of the ventricles by the fibrous rings around the orifices (to which the atria are attached); and there is no muscular continuity between an atrium and a ventricle except by means of the atrio-ventricular bundle.

Atrio-ventricular bundle lies in the septum. It is about the thickness of a match, and consists of pale muscle-fibres mingled with nerve-fibres. It begins above the opening of the coronary sinus in a vascular nodule of small spindle-shaped, unstriped muscle-cells mingled with nerve-cells and nerve-fibres, called the **atrio-ventricular node.** From the node, it runs forwards along the lower border of the membranous part of the septum across the attachment of the medial cusp of the tricuspid valve; divides into right and left branches which run onwards in the corresponding sides of the ventricular septum, and break up to ramify in the walls of both ventricles.

Sino-atrial node is a fibro-cellular rod, identical in structure with atrio-ventricular node; half an inch or more in length and one line in thickness; lies vertically in the atrial wall between the uppermost part of the crista terminalis and the floor of the sulcus terminalis. It is thought that contraction of heart begins in it, spreads through the atria, and is transmitted to the ventricles by the atrio-ventricular bundle.

Endocardium is a thin, fibro-elastic membrane covered with endothelial cells which are continuous with the endothelial lining of the blood-vessels. At the orifices it is pinched up into folds of two adherent layers to form the cusps of the valves.

Weight and Capacity.—Heart increases in size rapidly up to the age of 20, and thereafter gradually till 50. Average weight is 11 oz. in men and 9 in women. Each ventricle holds about 4 oz., and each atrium a little less.

Arteries.—Right and left coronary. Spring from the root of the ascending aorta. Since the heart is developed from primitive vascular tubes, they are enormously enlarged *vasa vasorum*.

Right coronary artery springs from the anterior sinus of the aorta. It passes forwards between the auricle of the right atrium and the root of the pulmonary trunk; and it runs its course in the atrio-ventricular groove. It first descends in the front of the heart, between the right atrium and ventricle, to the right end of the lower border, and then, in company with the small cardiac vein, it turns backwards round the lower end of the right border, and runs along the lower border of the base to meet the left coronary artery and anastomose with it.

Branches of Right Coronary Artery.—(1) **Small, unnamed branches** to aorta, pulmonary trunk, right auricle, atrium, and ventricle. (2) **Marginal artery** runs from right to left along the lower border of the heart, alongside the small cardiac vein, giving branches to the right ventricle. (3) **Inferior interventricular artery** arises near the termination of the right coronary, and runs towards the apex in the inferior interventricular groove, alongside the middle cardiac vein, giving branches to both ventricles.

Left coronary artery springs from the left posterior sinus of the aorta. It passes forwards between the auricle of the left atrium and the root of the pulmonary trunk; and it runs its course in the atrio-ventricular groove. It first curves downwards and backwards around the left surface of heart, between the left atrium and ventricle, and then to the right and forwards, along the lower border of the base, to meet and anastomose with the right artery. It accompanies first the great cardiac vein and then the coronary sinus.

Branches.—(1) **Small, unnamed branches** to aorta, pulmonary trunk, left auricle, atrium and ventricle.

(2) **Anterior interventricular artery** arises from it where it enters the atrio-ventricular groove, and runs towards the apex, in the anterior interventricular groove, giving branches to both ventricles; it is larger than the continuation of the parent stem; it is accompanied by the great cardiac vein.

Veins of Heart.—Venous blood in the walls of the heart is removed partly by the venæ minimæ, but chiefly by veins that come to the surface and unite to form the anterior cardiac veins and the tributaries of the coronary sinus. They have unicuspid valves at the junction of tributaries.

Venæ cordis minimæ are minute veins that open directly into the chambers of the heart—chiefly into the right atrium.

Anterior cardiac veins are small veins that lie on the front of the right atrium and ventricle, and they open independently into the right atrium near the atrio-ventricular groove.

Coronary sinus is a venous channel that lies in the lower part of the atrio-ventricular groove, between the left atrium and ventricle, partly covered by some fibres of the atrium, in company with the left coronary artery. Begins as a continuation of the great cardiac vein and runs its course from left to right and forwards along the lower border of the base. Ends in the lower part of the right atrium close to the septum, between the tricuspid orifice and the valve of inferior vena cava; and its opening is partly guarded by a unicuspid valve.

Tributaries of Coronary Sinus.—Great, small, and middle cardiac veins, oblique vein of left atrium, and other veins that are too inconstant in position or too small to merit names.

Great cardiac vein begins at the apex, ascends alongside the anterior interventricular artery in the anterior interventricular groove to reach the atrio-ventricular groove, and then curves backwards in it, across the left surface of the heart, to enter the left end of the coronary sinus—forming the commencement of that sinus. There is a valve at the point where the vein becomes the sinus.

Small cardiac vein begins at the apex, runs in company with the

marginal artery along the lower border of the heart to the lower end of the right border; at that point, it enters the atrio-ventricular groove, curves backwards in company with the right coronary artery, and runs along the lower border of the base between the right atrium and ventricle to join the coronary sinus near its termination.

Middle cardiac vein begins at the apex, runs backwards on the diaphragmatic surface in the groove between the ventricles, in company with the inferior interventricular artery, and joins the coronary sinus near its termination.

Oblique vein of left atrium is very narrow, without valves and often impervious, and would not be specially named or described were it not that it is a remnant of embryonic left duct of Cuvier. Begins at the left border of the base in front of the lower left pulmonary vein, and descends obliquely across the back of the left atrium to join the coronary sinus at a varying point.

Lymph-Vessels of Heart.—Emerge from the substance and form a network between epicardium and myocardium. Network is drained by vessels that run along ascending aorta to glands in anterior mediastinum, and along pulmonary trunk to glands at the end of trachea.

Nerves of Heart.—Descend from the cardiac plexus to the heart along the pulmonary trunk and ascending aorta. Form fine networks under the epicardium and in the muscular substance; on the nerve-strands there are some ganglionic nerve-cells.

(The nerves that convey impulses from central nervous system are called *efferent*, and those to the nervous system *afferent*.)

Efferent nerve-nuclei of heart are in the medulla oblongata, in or near the nuclei of the vagus. These nuclei are under the influence of higher centres through fibres that descend to them from the cerebrum; the commonest evidence of such influence is the modified action of the heart during emotion.

The fibres that arise in these nuclei take two courses :—

1. Some enter the vagus and are conveyed to the cardiac plexus by cardiac branches of the vagus and of the recurrent laryngeal nerve; they end partly in the cardiac ganglion and partly in ganglion-cells of the heart; another relay of fibres takes the impulses to the muscle-fibres. Vagal efferent impulses depress or restrain the rate and strength of heart-beats.

2. The other efferent fibres descend through the spinal cord to its upper thoracic segments and end in the lateral grey column. A second relay passes out in the anterior roots of the upper four thoracic nerves, and onwards into their anterior primary rami, and thence, by white rami communicantes, to the sympathetic trunk; some of the fibres end at once in the 2nd, 3rd and 4th thoracic ganglia of the trunk, while others ascend to the cervical ganglia. A third relay arises in these thoracic and cervical ganglia and enter their cardiac branches, which pass to the cardiac plexus and thence to the heart. Sympathetic efferent impulses increase the rate and strength of heart-beats.

(Some vagal fibres are derived probably from the accessory nerves; but it is possible that all vagal fibres come from the sympathetic

through communicating branches sent to the vagus by the superior cervical ganglion.)

The **afferent nerve-fibres** arise in the inferior ganglion of the vagus and the ganglia of upper four thoracic posterior nerve-roots ; each fibre divides into a central and a peripheral branch.

Vagal peripheral branches are carried by the cardiac branches of the vagus and recurrent laryngeal nerve to the cardiac plexus, whence they descend to the heart. *Vagal central branches* end in or near the dorsal nucleus of the vagus. Some afferent impulses carried by vagal fibres reflexly depress the heart ; others stimulate it.

Spinal peripheral branches run outwards from the ganglion into the nerve-trunk to reach the anterior primary ramus, and onwards through the white ramus communicans to the sympathetic trunk. Some of them pass at once into the thoracic cardiac branches of the sympathetic trunk ; others ascend in the trunk to the neck to enter the inferior and middle cervical cardiac branches. In these branches they pass to the cardiac plexus, and thence to the heart. *Spinal central branches* are taken by the posterior nerve-root into the spinal cord to end in the posterior grey column ; a second relay carries the impulses to the nuclei in medulla oblongata—or even higher, for they probably carry impulses of a sensory nature.

PERICARDIUM

Definition and Shape.—Pericardium is a fibro-serous sac that encloses the heart and the great vessels near the heart. More or less conical in shape. **Base** rests on the diaphragm ; **apex** is truncated and surrounds the great vessels opposite the sternal angle and the second costal cartilages of both sides.

Position.—In middle mediastinum, opposite bodies of middle four thoracic vertebræ, behind body of sternum and 2nd to 6th costal cartilages (to a greater extent on the left than on the right), having the same position as the heart, except that it reaches up to the second cartilage of both sides, whereas, on the right side, the heart reaches only the third.

Arrangement and Structure.—Three layers. A strong, outer layer, called **fibrous pericardium**, made of tough fibrous tissue ; and *two* layers of transparent membrane called **serous pericardium**—a *parietal* layer and a *visceral* layer—continuous with each other after the manner of the two halves of a rubber ball that has been deflated and doubled into itself to make a cup.

Parietal layer lines the fibrous pericardium.

Visceral layer covers the heart and is called the

epicardium. From the heart, it is prolonged over the great vessels to be reflected on to the upper and back part of the fibrous pericardium, where it becomes continuous with the parietal layer along certain lines.

These two layers are the result of the invagination of the serous pericardium by the heart during the course of development. They are separated by the **cavity of pericardium,** which, however, is merely a capillary space that contains enough lymph to keep the surfaces moist.

Each is a very thin sheet of fibro-elastic tissue covered with endothelial cells which make the opposed surfaces of the two layers smooth and glistening so that they glide over each other with a minimum of friction during the movements of the heart. Parietal layer is so closely adherent to the fibrous pericardium that they can scarcely be separated. Visceral layer is partly adherent to the muscular substance of heart and partly separated from it by the cardiac blood-vessels and fat—especially at the grooves and borders.

Contents of Pericardium.—Heart and cardiac vessels and nerves; ascending aorta; pulmonary trunk; parts of the four pulmonary veins; lower half of superior vena cava; the end of inferior vena cava.

Sinuses of Pericardium.—**Transverse sinus** is a horizontal, tube-like recess, enclosed in serous pericardium behind ascending aorta and pulmonary trunk—separating them from the atria. Its ends open into the general pericardial cavity. **Oblique sinus** is a wide, slit-like recess at the back of the heart, between left atrium and the back of pericardium; it is bounded superiorly and at the sides by the reflexion of serous pericardium; inferiorly it opens into the general cavity.

Lines of Reflexion.—Reflexion of serous pericardium from the fibrous pericardium on to the vessels to reach the heart takes place along two separate lines; the one reflexion is associated with the two great arteries, the other with the six veins.

At upper part of pericardium, the serous pericardium leaves the fibrous pericardium along a contour line that surrounds the apertures made by the ascending aorta and pulmonary trunk, and is shaped like an hour-glass; from that line the serous pericardium descends to the heart as a single, tubular sheath that completely envelops these two large arteries.

At the back, it leaves the fibrous pericardium along an irregular double line curved to resemble a short boat-hook, the long limb

of the hook being towards the right. From that curved, double line, the serous pericardium passes towards the heart as a short and curved fold of two layers continuous with each other at the ends of the hook. The very ends of the veins (separated from one another by intervals of varying lengths) are enclosed in that short fold: the left pulmonary veins are in the short limb of the hook; the inferior vena cava and right pulmonary veins in the long limb, and the superior vena cava in the spur of the hook. Superior vena cava and the pulmonary veins pierce the fibrous pericardium not opposite the reflexion but some distance away from it—the superior cava enters the pericardium an inch or more above the reflexion, and the pulmonary veins a little lateral to it. They run their intra-pericardial course between the fibrous pericardium and the serous, towards the reflexion, and are therefore covered on the front and sides with the serous parietal layer, while their backs are in contact with the fibrous pericardium.

Formation and Boundaries of Sinuses.—Sinuses of pericardium owe their existence to the fact that there are two separate lines of reflexion and that one of the lines is curved; the oblique sinus is bounded by the hook-like reflexion; the transverse sinus is between the two reflexions, in front of the upper part of the oblique sinus, from which it is separated by the left atrium.

Transverse sinus, though compressed and reduced to an irregular capillary interval when parts are in place, can be widened to admit one or two fingers. Bounded *anteriorly* by the ascending aorta and pulmonary trunk, *postero-inferiorly* by the upper part of the atria, and *superiorly* by the end of the pulmonary trunk and by the right pulmonary artery. Its *ends* open into the general pericardial cavity—the *right* between the aorta and superior vena cava, the *left* between the pulmonary trunk and the auricle of the left atrium.

Oblique sinus is bounded *on the left* by the part of the reflexion related to the left pulmonary veins; *on the right* by the part of the reflexion related to the right pulmonary veins and inferior vena cava and the interval between the cava and the veins; *superiorly* by the part of the reflexion that forms the bend of the hook, where the serous pericardium passes from the fibrous pericardium on to the upper part of the left atrium between the left and right upper pulmonary veins. *Inferiorly*, the sinus opens into the rest of the pericardial cavity.

Fold and Ligament of Left Vena Cava.—The **ligament** is a fibrous thread that represents part of the left superior vena cava of the fœtus. It springs from the left superior intercostal vein on the arch of aorta, and descends to the oblique vein on the back of the left atrium. The **fold** is a small triangular fold of serous pericardium raised up by the ligament in the interval between the left pulmonary artery and the upper left pulmonary vein.

External Connexions of Pericardium.—Fibrous pericardium is connected, **anteriorly,** to the upper and lower ends of the body of sternum by weak, loose fibrous bands called the *upper* and *lower sterno-pericardial ligaments.*

Inferiorly, it lies on the central tendon of the diaphragm and,

towards the left, on the fleshy part also. In the middle, it is fused with the central tendon; on each side of that, it is bound to the diaphragm by areolar tissue; between the right and median lobes of the central tendon, it is pierced by the inferior vena cava, and is connected with its sheath.

Posteriorly, it is pierced by the four pulmonary veins, and is connected with their sheaths.

Superiorly, it is pierced by the superior vena cava, aorta and pulmonary trunk, and is connected with their sheaths. Immediately behind them, the pretracheal fascia fuses with it; and by that means it is connected with the cervical fascia.

On each side, a fold of pleura, called the **pulmonary ligament,** stretches from the pericardium to the lung below its hilum.

External Relations of Pericardium. — On each side: Phrenic nerve, pericardiaco-phrenic vessels, pleura, lung. Pleura and lung are so closely applied to the pericardium that the parietal pleura is adherent to it except where separated by the phrenic nerve and by the pericardiaco-phrenic vessels, which accompany it. The lung has a wide concavity in front of its hilum to accommodate pericardium and heart, and therefore lung and pleura are partly behind and in front of pericardium as well as lateral to it.

Anterior: 1. Lower part of thymus, and pleura and lung.

2. Sterno-costalis, internal mammary vessels, and intercostal nerves of 2nd to 5th spaces.

3. Body of sternum, 2nd to 6th costal cartilages, corresponding internal intercostal muscles and anterior intercostal membranes.

4. Upper lateral corner of left rectus abdominis, covered with external oblique aponeurosis.

5. Pectoralis major and deep fascia.

6. Superficial fascia and mammary gland.

The pleuræ cover the whole front of the pericardium except at the lower left quarter of the body of the sternum, where the pericardium is separated from the origin of the left sterno-costalis and from the bone only by fatty areolar tissue. (See *Area of Dullness*, p. 410.)

Inferior: Diaphragm; liver and stomach.

Posterior: Pleura and lung, towards the sides; descending aorta, œsophagus and œsophageal plexus, in the middle.

Vessels and Nerves of Pericardium.—Arteries: From descending aorta, internal mammary, pericardiaco-phrenic, and phrenic arteries.

Veins: Correspond to the arteries; but those that accompany the aortic branches end in vena azygos.

Lymph-vessels: End in glands that lie behind the pericardium and in front of it.

Nerves: On each side, twigs from the phrenic; on the back, filaments from the vagi and sympathetic, through œsophageal plexus.

PULMONARY ARTERIES

Pulmonary trunk springs from the infundibulum at the base of right ventricle, opposite the third left cartilage near sternum ; extends *backwards* and upwards for two inches, to end below aortic arch, opposite the second cartilage, by dividing into right and left branches.

Right pulmonary artery runs to the right and slightly downwards along upper border of heart, behind ascending aorta and superior vena cava, to reach the hilum of right lung ; it gives off a large branch to accompany the eparterial bronchus.

Intrapulmonary part descends postero-lateral to the stem-bronchus, and it gives off branches to accompany its dorsal, ventral, and accessory branches.

Left pulmonary artery is much shorter ; it runs along upper border of left atrium to the hilum of left lung ; before entering, it gives a branch to the upper lobe.

Intrapulmonary part as on right side.

RELATIONS—Pulmonary Trunk.—Within fibrous pericardium, enclosed with ascending aorta in a tube of serous pericardium.

Anterior : sternal end of second left intercostal space—left pleura and lung intervening. *Posterior* : ascending aorta and left coronary artery below ; left atrium above. *To the right* : right auricle and coronary artery below ; ascending aorta above. *To the left* : left auricle and left coronary artery ; left pleura and lung. *Above its bifurcation* : superficial cardiac plexus ; aortic arch.

Right Artery.— *Anterior* : ascending aorta ; upper right pulm. vein ; v. cava sup. *Superior* : aortic arch, right bronchus, eparterial bronchus. *Posterior* : œsophagus, hyparterial bronchus. *Inferior* : atria, transverse sinus, lower right pulmonary vein.

Left Artery.— *Anterior* : upper left pulmonary vein. *Superior* : recurrent nerve, aortic arch, lig. arteriosum. *Posterior* : descending aorta, left bronchus. *Inferior* : lower left pulmonary vein.

Lig. arteriosum, a fibrous remnant of fœtal ductus arteriosus, passes from the root of left pulmonary artery to the aortic arch, in the substance of the fibrous pericardium. Left recurrent laryngeal nerve hooks round behind it, at its attachment to aorta ; superficial cardiac plexus is in front.

SYSTEMIC ARTERIES

Aorta is the main systemic arterial trunk. It springs from the left ventricle and ascends to the second right

costal cartilage (**Ascending aorta**). From there it is directed, first to the left and then *backwards*, to the lower border of the fourth thoracic vertebra (**Arch of aorta**). From there it descends over the front of vertebral column to end at the fourth lumbar vertebra by bifurcating to form the common iliac arteries (**Descending aorta**, divided into *descending thoracic aorta* and *abdominal aorta*).

ASCENDING AORTA

Springs from base of left ventricle, opposite *left* margin of sternum at level of 3rd cartilage. Extends upwards, forwards, and to the right, to end behind *right* margin of sternum, at its junction with 2nd cartilage, by becoming continuous with aortic arch. At origin it has three bulgings, called *aortic sinuses*, opposite cusps of valve.

Relations.—Within fibrous pericardium, enclosed with pulmonary trunk in a tube of serous pericardium.

Anterior : upper part of infundibulum and root of pulmonary trunk ; pericardium ; right and left lungs and pleuræ ; sternum.

Right side : right auricle and atrium ; superior v. cava.

Posterior : both atria, right pulmonary artery, right bronchus, and superior vena cava slightly.

Left side : left auricle and pulmonary trunk.

Branches.—Right and left coronary arteries (*see* p. 416)

ARCH OF AORTA

Begins, as continuation of ascending aorta, behind *right margin* of sternum at the level of 2nd cartilage. Extends first to the left and then backwards, through superior mediastinum, opposite lower half of manubrium, to end at *left* side of lower border of 4th TH. vertebra, by becoming continuous with descending aorta.

Relations.—*See* p. 603.

Branches.—Innominate, left common carotid and left subclavian, which all spring from its upper border.

Innominate artery springs from convexity of aortic arch, opposite centre of manubrium ; runs upwards and to the right to end behind upper part of sterno-clavicular joint by dividing into right common carotid and right subclavian. (*See also* pp. 330, 604.)

Arteria thyreoidea ima, seldom present. Springs from innominate or from aortic arch. Ascends on anterior surface of trachea to end in the isthmus of thyroid gland.

Left common carotid artery springs from upper surface of aortic arch immediately to the left of innominate. Runs upwards and slightly sidewards, to enter neck behind lower part of left sterno-clavicular joint. Thence, upwards along the lower part of a line drawn from that joint to the lobule of the ear. It ends by dividing into external and internal carotids opposite the upper border of thyroid cartilage and lower border of 3rd cervical vertebra.

Relations.—*See* pp. 335, 604.

Right common carotid artery arises, as a branch of bifurcation of innominate, behind upper part of sterno-clavicular joint. Above the sterno-clavicular joint, the left and right arteries have similar courses.

Upper end of common carotid and root of internal carotid are slightly dilated. Dilated part is called the **carotid sinus.**

External carotid artery begins, as branch of bifurcation of common carotid, opposite upper border of thyroid cartilage and lower border of 3rd vertebra. Extends upwards and sidewards to end behind neck of mandible, by dividing into maxillary and superficial temporal.

Relations.—*See* pp. 301, 337.

Branches.—Sup. thyroid, ascending pharyngeal, lingual, facial, occipital, posterior auricular, and terminals.

Superior thyroid artery arises from the front of external carotid near its origin ; runs downwards, forwards, and medially and disappears under the sterno-thyroid to end in thyroid gland. Its branches supply also neighbouring muscles and the larynx. (*See* p. 338.)

Ascending pharyngeal artery arises from the medial side of ext. carotid near origin ; runs upwards to the base of skull, giving branches to pharynx and prevertebral muscles, and it ends in meningeal branches. (*See* p. 337.)

Lingual artery springs from ext. carotid opposite tip of greater horn of hyoid. **First part** forms a loop, convex upwards, which lies on the middle constrictor, above tip of greater horn. **Second part** runs forwards along upper border of hyoid under cover of hyo-glossus. **Third part** runs upwards along anterior border of hyo-glossus to the

tongue. **Fourth part** is called **profunda linguæ**, and runs forwards in the lower part of tongue to its tip. (*See also* p. 318.)

Facial artery arises immediately above lingual. Ascends medial to posterior belly of digastric and in a groove in posterior end of submandibular gland; then, forwards and downwards between the gland and pterygoideus medialis to the lower border of mandible. Pierces deep fascia and crosses mandible at the anterior border of masseter and runs a sinuous course, upwards and medially, to end near medial angle of eye. (*See also* pp. 267, 318.)

Occipital artery arises near posterior belly of digastric. Runs upwards and backwards, *under cover of* digastric, mastoid process and the muscles attached to it, and trapezius, which it pierces, to ramify over back of head. (*See also* pp. 298, 281 and 262.)

Posterior auricular artery arises immediately above posterior belly of digastric, runs upwards and backwards at first deeply, between parotid and digastric; then, more superficially, behind the auricle; and it ends in occipital and auricular branches. (*See* p. 338.)

Superficial temporal artery begins behind neck of mandible as a terminal branch of ext. carotid. Ascends over posterior root of zygoma, in front of auricle. Ends about an inch above zygomatic arch by dividing into an *anterior* and a *posterior* branch, which run towards the frontal and parietal eminences (p. 261).

Maxillary artery arises behind neck of mandible. Extends—(1) Forwards to lower border of pterygoideus lateralis between mandible and spheno-mandibular ligament. (2) Upwards and forwards, superficial to pterygoideus lateralis, between it and temporal muscle; or deep to pterygoideus lateralis. (3) Medially, between two heads of pterygoideus lateralis and through pterygo-maxillary fissure into pterygo-palatine fossa, to end in numerous branches.

Branches of (1): deep auricular, anterior tympanic, middle and accessory meningeal, inferior dental.

Of (2): masseteric, deep temporal, pterygoid, buccal.

Of (3): posterior superior dental, infra-orbital, palatine, artery of pterygoid canal, spheno-palatine, pharyngeal.

(I.) **Branches of First Part.**—(*a*) **Deep auricular,** to ext. auditory

meatus. (*b*) **Anterior tympanic** traverses squamo-tympanic fissure and enters tympanic cavity near tymp. membrane. (*c*) **Accessory meningeal** runs up, deep to pterygoideus lateralis; enters middle cranial fossa through foramen ovale; and supplies dura mater and trigeminal ganglion. (*d*) **Middle meningeal.** (*e*) **Inferior dental.**

Middle meningeal artery arises at the lower border of pterygoideus lateralis and passes upwards across its medial side to enter the middle cranial fossa through foramen spinosum. Runs forwards and sidewards in the outer layer of the dura, to end at a variable point by dividing into anterior and posterior branches. (*See also* pp. 306 and 55.)

Anterior terminal branch runs upwards to a point opposite the pterion, where it grooves the skull deeply or tunnels it, and from there upwards and backwards, opposite motor area of brain, to the vertex, giving branches backwards and forwards.

Posterior terminal branch runs backwards and upwards towards the lambda.

Inferior dental artery descends between ramus of mandible and spheno-mandibular ligament; enters mandibular foramen, accompanied by vein and nerve, and runs along mandibular canal.

Branches.—(1) **Lingual** accompanies lingual n. (2) **Mylo-hyoid** pierces spheno-mandibular lig., and runs downwards and forwards in the mylo-hyoid groove. (3) Branches to gums and teeth. (4) **Mental** passes through mental foramen to the face.

(II.) **Branches of Second Part of Maxillary Artery.**—(1) **To pterygoid muscles.** (2) **Masseteric** passes laterally through mandibular notch to masseter. (3) **Anterior** and **posterior deep temporal** ascend between temporal muscle and side of skull, supplying both. (4) **Buccal** accompanies buccal nerve, between temporal and pterygoid muscles, to the skin and mucous membrane of cheek.

(III.) **Branches of Third Part.**—**Posterior superior dental** descends over posterior surface of maxilla; sends branches to gums and buccinator, and, through the bone, to molars, premolars, and maxillary sinus. **Infra-orbital** passes from pterygo-palatine fossa to orbit through inf. orbital fissure. Runs through infra-orbital groove, canal and foramen to the face, accompanied by infra-orb. n. While in floor of orbit it gives branches to orbital structures, maxillary sinus, and sends *ant. sup. dental* to canine and incisor teeth.

Greater palatine artery descends through greater palatine canal and foramen, runs forwards on oral surface of bony palate, close to alveolar border, and ends by passing up lateral incisive canal to

the nose. It sends the *lesser palatine arteries* down through lesser palatine canals to soft palate ; and it gives branches to hard palate.

Artery of pterygoid canal runs backwards through that canal to upper part of pharynx.

Pharyngeal runs backwards through palatino-vaginal canal to roof of pharynx.

Spheno-palatine enters nasal cavity through spheno-palatine foramen ; supplies mucous membrane of nose, adjacent sinuses and pharynx. Longest branch crosses roof, descends on septum to anastomose with greater palatine and superior labial of facial.

Internal carotid artery arises at upper border of thyroid cartilage as branch of bifurcation of common carotid. Ascends to base of skull, opposite a line drawn from upper border of thyroid cartilage to the front of tragus of ear. Traverses carotid canal of temporal, crosses foramen lacerum, pierces outer layer of dura mater ; runs forwards and then upwards in a cavernous sinus ; pierces inner layer of dura and arachnoid at the medial side of anterior clinoid process ; bends backwards above cavernous sinus, and, finally, upwards again to end at anterior perforated substance by dividing into anterior and middle cerebral arteries.

Relations in Neck.—*See* p. 336.

Relations in Carotid Canal.—Surrounded by small veins and by branches from superior cervical ganglion of sympathetic. Cochlea and tympanic cavity are posterior and superior ; pharyngo-tympanic tube and tensor tympani are anterior and lateral ; trigeminal ganglion is superior.

Branches in Canal.—**Carotico-tympanic** perforates posterior wall of canal and anastomoses with other arteries in tympanum. **Pterygoid** accompanies greater superficial petrosal nerve.

Relations in Cranial Cavity.—In cavernous sinus, it is clothed *medially* by endothelium of sinus, and is related to sphenoidal air-sinus. Oculomotor, trochlear, ophthalmic and abducent nerves, in wall of sinus, are *lateral*. *See also* p. 57.

Branches in Cranial Cavity.—(1) Branches to walls of cavernous sinus and nerves there, to trigeminal ganglion, hypophysis, dura mater ; (2) ophthalmic (p. 68) ; (3) branches to the brain—posterior communicating ; choroid ; ant. cerebral ; middle cerebral.

Posterior communicating artery arises near end of carotid. Runs backwards below optic tract, in front of cerebral peduncle, above oculomotor n., and joins posterior cerebral, giving branches to these, to interpeduncular structures, to uncus, and to thalamus and internal capsule.

Anterior choroid arises near end of carotid. Runs backwards between cerebral peduncle and uncus; enters inferior horn of lateral ventricle to end in its choroid plexus. Supplies optic tract, basis pedunculi, uncus and posterior part of internal capsule, basal nuclei, and anterior commissure.

Anterior cerebral artery runs medially above optic chiasma, in front of lamina terminalis, where it is connected with its fellow by the **anterior communicating artery**; winds round genu of corpus callosum; runs backwards on the trunk of corpus callosum (or in sulcus cinguli) to precuneus. **Central branches** supply lamina terminalis, corpus callosum, septum lucidum, anterior column of fornix, anterior commissure, caudate and lentiform nuclei. **Cortical branches** supply *medial surface of hemisphere almost as far back as parieto-occipital sulcus, upper inch of supero-lateral surface for a like distance,* and the *medial half of orbital surface.*

Middle cerebral artery passes into the lateral sulcus, and ends in branches on the surface of insula.

Cortical branches supply: (1) Insula; (2) lateral half of orbital surface; (3) anterior end of temporal lobe; (4) *most of supero-lateral surface of hemisphere* (*i.e.*, all except occipital lobe, inferior temporal gyrus and a strip, about an inch in breadth, along upper margin).

Central branches pass up through ant. perforated substance and supply caudate and lentiform nuclei, internal capsule, anterior commissure, and thalamus. Those that supply lentiform and caudate nuclei (corpus striatum), are called *striate arteries*. Most lateral of them groove the lower half of lateral surface of lentiform nucleus before they sink into it to reach internal capsule and caudate nucleus. The largest of this group pierces the anterior part of lentiform nucleus, and it is called " the artery of cerebral hæmorrhage ".

Cortical branches of cerebral arteries anastomose freely in the pia mater, but very little, if at all, after entering the brain-substance; and the central branches do not anastomose at all.

Vertebral artery arises from first part of subclavian; enters foramen in transverse process of 6th cerv. vertebra, traverses transverse foramina of upper six cervical vert.; turns backwards and medially on post. arch of atlas; pierces dura mater, enters foramen magnum; and ends at lower border of pons by joining its fellow to form the basilar. Divided into four parts:—(1) In root of neck.

(2) In transverse processes. (3) In suboccipital triangle. (4) In cranial cavity.

Relations of first, second and third parts.—*See* pp. 332 and 281.

Fourth part pierces dura mater and arachnoid, enters cranial cavity through foramen magnum, and runs upwards and medially on lateral and anterior surfaces of medulla oblongata to end at the middle of lower border of pons.

Branches of Fourth Part.—1. **Meningeal branches** (before it pierces dura), to bone and dura mater of posterior cranial fossa.

2. **Posterior spinal** descends and divides into branches which lie both in front of and behind posterior nerve-roots.

3. **Anterior spinal** unites with its fellow on the front of medulla oblongata to form a single artery which runs down between the lips of the anterior median fissure of spinal cord.

4. **Posterior inferior cerebellar** arises near the end of vertebral, runs obliquely backwards around medulla oblongata into vallecula cerebelli, where it divides into *medial* and *lateral branches* to supply vermis and inferior surface of hemisphere.

5. Small **branches to medulla oblongata.**

Basilar artery is formed at lower border of pons by union of vertebrals; runs upwards in relation to dorsal surface of clivus of skull and dorsum sellæ, in the groove on the front of pons, to end at its upper border by dividing into two posterior cerebral arteries.

Branches.—1. Small **branches to pons.**

2. **Internal auditory** accompanies auditory nerve.

3. **Anterior inferior cerebellar** passes backwards to anterior part of inferior surface of cerebellar hemisphere.

4. **Superior cerebellar** arises near end of basilar, runs along upper border of pons and across lateral surface of basis pedunculi, below oculomotor and trochlear nerves, to ramify on upper surface of cerebellar hemisphere.

Posterior cerebral artery arises at upper border of pons as a branch of bifurcation of basilar; runs backwards and upwards between basis pedunculi and uncus, above oculomotor and trochlear nerves, to the calcarine sulcus, to end in cortical branches there. It is connected with int. carotid by the posterior communicating.

Branches.—**Cortical branches,** to tentorial surface of hemisphere (except ant. end of temporal lobe) and adjoining part of lateral surface, post. part of medial surface (including posterior half-inch of præcuneus) and adjoining part of upper surface.

Central branches, to mamillary body, basis pedunculi, red nucleus, thalamus, geniculate bodies and fornix.

Posterior choroid, to choroid plexus of lateral ventricle.

Circulus arteriosus is situated in subarachnoid space at base of brain, enclosing the optic chiasma and the structures in the interpeduncular fossa. It is formed by the point of bifurcation of basilar, two posterior cerebrals, two posterior communicating, two internal carotids, two ant. cerebrals, and ant. communicating.

Relations, passing from posterior to anterior limit of circle.—**Within the circle** are the posterior perforated substance, mamillary bodies, tuber cinereum and infundibulum; lamina terminalis and optic chiasma. **Above it** are the posterior perforated substance, basis pedunculi, optic tract, anterior perforated substance, posterior end of gyrus rectus and medial root of olfactory tract, rostrum of corpus callosum, and longitudinal fissure. **Below it** are the dorsum sellæ, attached margin of tentorium cerebelli near posterior clinoid process, cavernous sinus, and optic chiasma.

Circumferentially it is related to upper border of pons, basis pedunculi, oculomotor nerve and uncus, beginning of stem of lateral sulcus, gyrus rectus, and longitudinal fissure. (Oculomotor nerve is first behind posterior cerebral artery (behind its anastomosis with posterior communicating) and then turns forwards beneath posterior cerebral to lie between posterior communicating and uncus.)

Left subclavian artery arises from aortic arch, behind and to left of carotid, at left side of trachea; ascends to root of neck; arches laterally behind scalenus anterior, across the front of cervical pleura and over first rib, to end at outer border of first rib by becoming continuous with axillary.

Divided into three parts: (1) from origin to medial border of scalenus ant.; (2) behind scalenus ant.; (3) from lateral border of scalenus ant. to outer border of first rib. Position in neck may be indicated by an arched line, convex upwards, drawn from sterno-clavicular joint to middle of clavicle, highest point of arch being half an inch or more above clavicle.

Relations.—*See* pp. 331, 604.

Right subclavian artery begins behind upper part of sterno-clavicular joint. Arches laterally across the front of the cervical pleura, behind scalenus anterior, to end at outer border of first rib. Divided, in same way as left, into three parts.

Relations.—*See* p. 330.

Branches are alike on both sides: vertebral (pp. 281, 332, 430); thyro-cervical trunk (p. 333); internal mammary (pp. 333, 355); costo-cervical trunk (p. 334).

Axillary artery begins at outer border of first rib as continuation of subclavian ; arches in a lateral direction and downwards through axilla to end at lower border of teres major tendon by becoming brachial ; but its course varies with position of arm. When arm is abducted to a right angle, artery is opposite a line drawn from middle of clavicle to junction of arm with lower border of posterior wall of axilla.

Divided into three parts. **1st part,** from outer border of first rib to upper border of pectoralis minor. **2nd part** is behind pectoralis minor. **3rd part,** from infero-lateral border of pectoralis minor to lower border of teres major.

Relations.—*See* p. 167.

Branches.—**First part :** superior thoracic.

Second part : acromio-thoracic, lateral thoracic.

Third part : subscapular ; anterior and posterior circumflex.

Superior thoracic art. crosses deep or superficial to axillary vein and ramifies over the first intercostal muscle.

Acromio-thoracic artery pierces clavi-pectoral fascia and divides into four branches which radiate from it to supply muscles and skin.

Lateral thoracic art. runs downwards and medially behind axillary vein, and along infero-lateral border of pectoralis minor to the wall of the thorax ; supplies muscles and sends *external mammary branches* to the mammary gland.

Subscapular art. runs along lower border of subscapularis, at first behind ulnar nerve and axillary vein and then crosses in front of the lower subscapular nerve to accompany the nerve to latissimus dorsi into that muscle at the lower angle of scapula. It supplies adjacent muscles ; and, after emerging from behind axillary vein, it gives off the **scapular circumflex,** which gives branches to muscles and then crosses the triangular space to reach the dorsum of scapula by passing under teres minor.

Anterior humeral circumflex art. runs laterally in front of surgical neck of humerus ; gives branches to muscles ; sends a branch up the bicipital groove to the shoulder-joint, and another downwards in it, supplying pectoralis major tendon.

Posterior humeral circumflex art. passes backwards through quadrilateral space below the circumflex nerve, and then winds forwards around surgical neck under cover of deltoid. (*See* p. 178.)

Brachial artery begins, as the continuation of axillary, at lower border of teres major tendon ; runs downwards

and slightly laterally to end in cubital fossa, anteromedial to neck of radius, by dividing into radial and ulnar.

Relations and **Branches.**—*See* p. 182.

Radial artery arises in cubital fossa as a branch of bifurcation of brachial; descends to apex of styloid of radius; then, curves round lateral side of wrist under abductor pollicis longus and extensor pollicis brevis, crosses the "anatomical snuffbox", and passes under extensor pollicis longus to reach the proximal end of first intermetacarpal space; thence, through that space between the heads of the first dorsal interosseous muscle into the palm, where it turns medially between the two heads of adductor pollicis and becomes the deep palmar arch. It is accompanied by venæ comitantes.

Relations and **Branches.**—*See* pp. 189, 201, 209.

Ulnar artery begins as branch of bifurcation of brachial in cubital fossa. Runs in upper third of forearm downwards and medially; in lower two-thirds, vertically. Ends on the flexor retinaculum by giving off a deep branch and becoming the superficial palmar arch. Venæ comitantes accompany it.

Relations and **Branches.**—*See* pp. 190, 197.

DESCENDING THORACIC AORTA

Begins, as a continuation of arch, at left side of lower border of 4th TH. vertebra; descends through the posterior mediastinum, *over the bodies of vertebræ*, inclining forwards and medially to gain median plane; ends in aortic opening of diaphragm, opposite lower border of 12th thoracic vertebra, by becoming the abdominal aorta.

Relations and **Branches.**—*See* pp. 607, 608.

ABDOMINAL AORTA

Begins at the lower border of 12th thoracic vertebra, between crura of diaphragm, as continuation of thoracic aorta; passes downwards and slightly to left, to end on the front of the 4th lumbar vertebra, to the left of median plane, half an inch below and to left of umbilicus (*i.e.* at the level of highest part of iliac crest), by dividing into right and left common iliac arteries.

Relations. — *Anterior* :—1. Cœliac and aortic plexuses.
2. Body of pancreas and splenic vein.
3. Origin of superior mesenteric art., uncinate process of pancreas, left renal vein.
4. Third part of duodenum, origin of inf. mesenteric art.
5. Root of mesentery and sup. mesenteric vessels.
6. Peritoneum and coils of small intestine.

Right side:—Right crus of diaphragm, v. azygos and cisterna chyli, at upper part. Inf. v. cava, at lower part.

Left side:—Left crus, termination of duodenum, peritoneum and coils of intestine.

Posterior :—Upper four L. vertebræ, ant. longitudinal lig., 3rd and 4th left lumbar veins. Lumbar and median sacral arteries spring from the back of it.

Branches.—*Paired visceral* : middle suprarenal, renal, testicular or ovarian.

Unpaired visceral : cœliac, superior and inferior mesenteric.

Paired parietal: phrenic, four lumbar.

Unpaired parietal : median sacral.

Phrenic arteries arise near beginning of abdominal aorta. Each passes upwards and sidewards on corresponding crus close to the suprarenal gland—the *right* behind vena cava, the *left* behind œsophagus. Each gives one or more **superior suprarenal** arteries to the suprarenal gland and ramifies on abdominal surface of diaphragm.

Lumbar arteries, four pairs, arise from the back of aorta, curve backwards on the bodies of the upper four lumbar vertebræ, and disappear under psoas major (*see* p. 376).

Median Sacral Artery.—*See* p. 390.

Middle suprarenal arteries—very small, and not always present—arise opposite first lumbar vertebra, near sup. mesenteric. Each passes upwards and sidewards across crus of diaphragm, through or behind cœliac ganglion, to reach suprarenal gland.

Renal arteries arise from sides of aorta, below sup. mesenteric, opposite upper border of 2nd L. vertebra ; each passes sidewards on crus and psoas, and enters hilum of kidney. *Left* is behind its own vein and the pancreas. *Right* is longer and is behind its own vein, inf. vena cava, and end of left vein ; and these vessels are behind head of pancreas and second part of duodenum.

Branches.—(*a*) To kidney. (*b*) **Inf. suprarenal** ascends to suprarenal gland. (*c*) To ureter.

Testicular arteries arise from the front of aorta, below renal. Each runs downwards and sidewards to deep inguinal ring, traverses inguinal canal, descends tortuously in spermatic cord, in front of vas deferens; divides at upper end of testis to supply testis and epididymis.

Relations in abdomen: *Accompanied* by testicular veins.

Right artery *lies on* aorta, vena cava, ureter, genito-femoral nerve, psoas, ext. iliac art. *Covered with* peritoneum, and *crossed anteriorly* by third part of duodenum, right colic, ileo-colic and superior mesenteric vessels, root of mesentery (and end of ileum and vermiform appendix, separated by peritoneum).

Left artery *lies on* aorta, sympathetic trunk, ureter, genito-femoral n., psoas, ext. iliac art.

Covered with peritoneum, and *crossed by* left colic vessels and terminal part of descending colon.

Near the deep ring each artery crosses in front of deep circumflex iliac vein and the origin of inf. epigastric art.

Branches.—To ureter, to cremaster. Terminal branches supply epididymis, anastomose with artery of vas deferens, and enter back of testis.

Ovarian arteries correspond to testicular. Have same relations down to brim of pelvis, where each turns medially over ext. iliac artery, an inch below its origin, and enters infundibulo-pelvic lig. to reach ovary. Gives branches also to ureter, uterine tube, lig. teres, and uterus.

Cœliac artery arises from the front of first half-inch of abdominal aorta, runs horizontally forwards for half an inch (or less), across lower border of caudate lobe of liver, and upper border of pancreas, and divides into left gastric, splenic, and hepatic branches.

Relations.—*Surrounded* by cœliac plexus. Median arcuate ligament and caudate lobe *above*. Crus of diaphragm and cœliac ganglion *on each side*. Pancreas and splenic vein *below*. Lesser sac of peritoneum separates it from lesser omentum, *in front*.

Left gastric artery (smallest branch of cœliac) runs up and to the left on left crus, behind lesser sac, to œsophageal end of stomach; sends **œsophageal branches** upwards through œsophageal opening of diaphragm; turns over upper border of lesser sac, and descends along lesser curvature of stomach, between layers of lesser

omentum, on anterior wall of lesser sac (occasionally divided into two parallel trunks), giving branches to both surfaces of stomach; ends by anastomosing with right gastric.

Splenic artery (largest branch) runs to left and upwards, sinuously, along upper border of pancreas, on left crus and cœliac ganglion, suprarenal and kidney, behind lesser sac and stomach, and divides into 5-8 splenic branches. Splenic vein lies below it, behind pancreas.

Branches.—(*a*) **Splenic** pass forwards in lieno-renal ligament and enter the hilum on gastric surface of spleen. (*b*) **Pancreatic.** (*c*) **Short gastric** (5 or 6) run between layers of gastro-splenic lig. to fundus of stomach. (*d*) **Left gastro-epiploic artery** arises near spleen, runs in gastro-splenic ligament to left end of stomach, and then along its lower border, between the anterior two layers of greater omentum. Gives numerous branches to both surfaces of stomach, and some to greater omentum; others anastomose with branches of middle colic. Ends by anastomosing with right gastro-epiploic.

Hepatic artery runs to the right and slightly downwards, in front of right crus and cœliac ganglion, along upper border of pancreas, to first part of duodenum: then, forwards below the opening into lesser sac, and, lastly, upwards in front of the opening, between layers of lesser omentum near its free border, in front of portal vein, on medial side of bile-duct, to reach porta hepatis, where it divides into right and left hepatics.

Branches.—(*a*) **Right gastric** runs to the left along lesser curvature, between layers of lesser omentum; gives branches to both surfaces of stomach; ends by anastomosing with left gastric.

(*b*) **Gastro-duodenal** descends behind first part of duodenum and ends at its lower border (or behind it) by dividing into: (i.) *superior pancreatico-duodenal*, which runs to the right and then downwards between duodenum and pancreas, supplying both, and anast. with inf. pancreatico-duodenal; and (ii.) *right gastro-epiploic*, which runs to left along greater curvature, between anterior two layers of greater omentum, sending branches to both surfaces of stomach, and some to the greater omentum and to anastomose with middle colic; ends by anastomosing with left gastro-epiploic.

(*c*) A **duodenal branch** arises in the lesser omentum and descends to supply either the beginning of the duodenum or the convex side of the bend of first and second parts of duodenum.

(*d*) **Right** and **left hepatic branches** enter porta and sink into liver. In porta they lie behind hepatic ducts, in front of branches of portal vein. Right branch sends *cystic* branch downwards to gall-bladder.

Superior mesenteric artery arises from the front of aorta below cœliac, behind pancreas, opposite first lumbar vertebra, in the transpyloric plane. Crosses third part of duodenum, enters root of mesentery and takes a curved course, with its convexity towards the left. Ends in right iliac fossa by anastomosing with a branch of the ileo-colic artery.

Relations.—Its vein on its *right* side. *Anterior*: body of pancreas, splenic vein, peritoneum of mesentery, coils of small intestine. *Posterior*: left renal vein, uncinate process of pancreas; third part of duodenum; aorta; vena cava; right ureter, psoas, genito-femoral nerve and testicular (or ovarian) vessels.

Branches.—(1) **Jejunal** and **ileal arteries**, 12-15, arise from the left or convex side, run towards small intestine between layers of mesentery, divide and anastomose, forming *arterial arcades*, from which small vessels spring, divide, and anastomose, several times, till 3-5 series of arcades are formed before intestine is reached.

(2) **Middle colic artery** arises at lower border of pancreas; enters transverse mesocolon, in which it runs downwards and forwards to supply transverse colon; divides into right and left branches, which anast. with right and left colics, and with right and left gastro-epiploics.

(3) **Inf. pancreatico-duodenal** runs to the right between pancreas and duodenum; supplies both, and anastomoses with sup. pancreatico-duodenal.

(4) **Right colic artery** arises below duodenum, runs to the right, under cover of peritoneum, across vena cava, testicular vessels, ureter and psoas (often higher up, across duodenum and kidney), to supply ascending colon. Divides into ascending and descending branches to anast. with middle colic and ileo-colic, respectively.

(5) **Ileo-colic artery** arises either with the preceding, or,

independently, below it; runs to the right, under cover of peritoneum, across vena cava, testicular vessels, ureter and psoas. Divides into: (i.) *ascending branch*, which anast. with right colic and supplies ascending colon; and (ii.) *descending*, which anast. with end of sup. mesenteric, and gives (*a*) branches to ileum and cæcum, and (*b*) an *appendicular art.*, which passes behind end of ileum and enters mesentery of vermiform appendix, in which it proceeds to the appendix.

Inferior mesenteric artery arises from front of aorta an inch and a half above bifurcation, opposite third lumbar vertebra, behind duodenum. Runs downwards and to the left, *behind* peritoneum; *in front of* aorta, sympathetic trunk and psoas, to reach the middle of the front of left common iliac artery, where it ends by becoming the superior rectal artery. Its vein is a little to the left of it.

Branches.—(1) **Upper left colic artery** arises near duodenum, runs sidewards, behind peritoneum and inf. mesent. vein, across left sympathetic trunk, ureter, testicular vessels and psoas. Divides into two: (*a*) *ascending branch* crosses lower part of left kidney, and ends in branches for left colic flexure and transverse colon, and anastomoses with middle colic; (*b*) *descending branch* supplies desc. colon, and anast. with lower left colic arteries.

(2) **Lower left colic arteries**, 2 or 3, run downwards and to the left, behind peritoneum and behind or in front of inf. mesenteric vein; across psoas, ureter, and testicular vessels; supply lower part of descending colon and the pelvic colon. Anastomose with upper left colic. Lower branches cross iliac vessels and enter pelvic mesocolon to reach pelvic colon and to anastomose with superior rectal.

(3) **Superior rectal artery** is the continuation of inferior mesenteric; enters pelvic mesocolon, descends to rectum, and is its chief supply. (*See also* p. 390.)

Common iliac arteries begin on the front of body of fourth lumbar vertebra, a little to the left of median plane, as branches of bifurcation of aorta. Each runs downwards and sidewards, and ends at the level of lumbo-sacral disc, opposite sacro-iliac joint, by dividing into

external and internal iliac. Upper third of line drawn from a point half an inch to the left of and below umbilicus to mid-inguinal point corresponds to common iliac, and lower two-thirds corresponds to external iliac.

Relations.— *Anterior* : peritoneum and intestine; nerves from sympathetic trunk to hypogastric plexus. Sup. rectal and branches of lower left colic vessels also lie on left art. *Posterior* : bodies of fourth and fifth lumbar vertebræ and disc between ; sympathetic trunk ; psoas ; and, some distance away, obturator n., lumbo-sacral trunk and ilio-lumbar art. Right artery is separated from all these (except at lower end where it touches psoas) by termination of right and left common iliac veins and origin of vena cava. Left common iliac vein is below and medial to its artery.

Branches.—None of consequence except the terminal branches.

Internal iliac artery arises, as a terminal branch of the common iliac, on the antero-medial border of psoas ; runs backwards and downwards, across the medial surface of psoas into the pelvis, to end, near the upper border of greater sciatic notch, by breaking up into an anterior and a posterior division.

Narrower in adult than ext. iliac, but twice as wide in fœtus, where its umbilical branch runs to umbilicus and thence to placenta. After birth, that branch is pervious only up to point where it gives off superior vesical arteries, beyond which it is a fibrous cord called lateral umbilical lig.

Branches.—*See* PELVIS, PERINEUM and LOWER LIMB.

Relations.—*See* p. 391.

External iliac artery arises at level of lumbo-sacral disc, opposite sacro-iliac joint, as branch of bifurcation of common iliac ; runs downwards and sidewards in relation to psoas major, and ends by becoming femoral behind inguinal ligament at mid-inguinal point.

Branches.—Inf. epigastric and deep circumflex iliac (pp. 370, 371).

Relations.—Its vein is behind its upper part and medial to its lower part. Psoas is lateral to its upper part and behind its lower part.

Superficial : Peritoneum separates it from intestines. *Under cover of peritoneum* :—Crossed by ureter at its origin, by ovarian vessels an inch lower down, and, at its lower end, by deep circumflex iliac vein, lig. teres uteri or vas deferens. Testicular vessels and

genito-femoral nerve are lateral to its upper part; but the vessels and the genital branch of the nerve pass on to the front of its lower part.

The left artery is crossed by the terminal part of the descending colon and by branches of the lowest left colic vessels.

Femoral artery (*see also* p. 219) begins as continuation of ext. iliac, behind the inguinal ligament, at mid-inguinal point; descends through femoral triangle and subsartorial canal, and ends at the junction of the middle and distal thirds of thigh by passing through the opening in adductor magnus and becoming popliteal.

Relations and **Branches.**—*See* pp. 211, 220.

Popliteal artery (*see also* p. 230) begins as continuation of femoral; runs downwards through popliteal fossa to end at distal border of popliteus by dividing into ant. and post. tibial. Popliteal vein is medial to it at its lower end, crosses behind it to lie postero-lateral to it at its upper end. Medial popliteal nerve is lateral to both artery and vein at upper end, and crosses behind them to lie on their medial side.

Branches.—Muscular, cutaneous, and five genicular. (*See* p. 231.)

Posterior tibial artery descends through the back of the leg to end at the distal border of flexor retinaculum by dividing into medial and lateral plantar. (*See* p. 250.)

Medial plantar artery (*see also* p. 255) arises at the distal border of the flexor retinaculum; runs first under cover of abductor hallucis, then between it and flexor digitorum brevis to reach the base of the hallux; and ends by joining the plantar digital artery for the medial side of hallux.

Lateral plantar artery (*see also* p. 255), larger than medial, begins at distal border of flexor retinaculum; runs forwards and sidewards under cover of abductor hallucis and flexor digitorum brevis, accompanied by lateral plantar n.; and at base of fifth metatarsal it runs medially across sole, as *plantar arch*, to end at *base* of first metatarsal by joining dorsalis pedis.

Plantar arch (*see also* p. 256), formed by lateral plantar, completed medially by junction with dorsalis pedis at *proximal end* of first intermetatarsal space. Lies across bases of middle three metatarsals, and is accompanied by deep branch of lateral plantar nerve.

Anterior tibial artery arises at distal border of popliteus as a terminal branch of popliteal; runs downwards and forwards through upper part of interosseous membrane, and descends over that membrane and lower end of tibia to the front of ankle-joint midway between malleoli, where it ends as dorsalis pedis. (*See* pp. 242, 250.)

A. dorsalis pedis (*see also* pp. 242, 256) begins on front of ankle, midway between malleoli, as the continuation of ant. tibial; runs forwards upon talus, navicular, and intermediate cuneiform, to *proximal end* of first intermetatarsal space; dips down into sole, and ends by joining plantar arch.

VEINS

Pulmonary veins begin in capillaries of the lungs and convey oxygenated blood to the left atrium.

Veins of portal system begin in capillaries of spleen and pancreas and of abdominal part of alimentary canal. Principal trunk is the portal vein, which breaks up into capillaries in the liver, from which the blood is conveyed to the inferior vena cava by hepatic veins.

Systemic veins arise in capillaries of all other parts of the body, and they contain impure blood. Principal trunks—coronary sinus, superior and inferior venæ cavæ—convey systemic and portal blood to the right atrium.

PULMONARY VEINS

Two on each side, pierce fibrous layer of pericardium; receive a covering from serous layer on anterior, upper, and lower surfaces; enter upper and posterior part of left atrium, near its right and left borders.

Relations.—In root of lung, upper vein is below and in front of artery; lower vein is below bronchus. On right side, the lower vein passes behind the right atrium, and the upper vein passes behind the entrance of superior vena cava into that atrium. On left side, both are in front of descending aorta, upper being separated from it by bronchus.

SYSTEMIC VEINS

Deep veins accompany arteries (venæ comitantes). Large arteries have only one accompanying vein; medium

and small arteries have usually two. **Superficial veins** lie in superficial fascia, anastomose with one another, communicate with deep veins and, after piercing deep fascia, end in deep veins. They may or may not accompany superficial arteries. **Visceral veins** accompany visceral arteries, usually one to each. Excepting those which form portal system, they end in deep veins.

Veins of the Heart.—*See* p. 417.

Vena Cava Superior and its Tributaries

Superior vena cava, two inches long, begins behind the lower border of first right costal cartilage by union of the two innominates. Pierces pericardium opposite second right cartilage. Ends in upper and back part of right atrium, behind third right cartilage. Has no valves.

Tributaries: right and left innominates; v. azygos; small mediastinal and pericardial veins.

Relations.—*See* p. 603.

Vena Azygos.—Arises from the back of inferior vena cava at the level of the renal vein. (This was the origin in eleven of thirteen cadavera specially examined.)

Passes upwards into thorax through aortic opening of diaphragm. Ascends in posterior mediastinum on the right side of aorta. Enters superior mediastinum and arches forwards over root of right lung to end in superior vena cava. Has only a few imperfect valves, but its tributaries have complete valves.

Relations and **Tributaries.**—*See* p. 358.

Inferior vena hemiazygos arises from the back of left renal vein; pierces left crus, ascends over lower thoracic vertebræ along left side of aorta. At the ninth vertebra, it turns to the right, behind the aorta and thoracic duct, and ends in v. azygos. (*See* p. 609.)

Abdominal parts of v. azygos and inferior hemiazygos may be absent. Each of them then begins on the side of twelfth thoracic vertebra by the union of subcostal vein and ascending lumbar vein.

These abdominal parts of azygos and hemiazygos have been described as a "pair" of lumbar azygos veins—a confusing description, for *azygos* means *un*paired.

Superior Vena Hemiazygos.—*See* p. 609.

Subcostal Vein.—*See* p. 378.

Intercostal Veins.—*See* p. 357.

Innominate veins (*see also* pp. 340, 602).—Have no valves. Each begins in the neck, behind clavicle near

its sternal end, on the front of the pleura, by the union of subclavian and int. jugular. They end by uniting behind lower border of first right costal cartilage close to the sternum to form superior vena cava.

Right vein, an inch long, passes downwards and slightly medially along right side of innominate art. **Left**, three inches long, passes obliquely to the right and downwards, behind left sterno-clavicular joint and upper part of manubrium, in front of the three branches of aortic arch.

Veins of Head and Neck

Internal jugular vein begins in jugular foramen as the continuation of sigmoid sinus. Descends along the lateral side of internal and common carotid. Ends behind clavicle, an inch lateral to the sterno-clavicular joint, by joining subclavian to form innominate.

Both veins trend to the right in their descent, so that left vein is almost in front of common carotid at lower end, while right vein is a little way lateral to it.

Relations and **Tributaries**.—*See* pp. 338, 339.

Subclavian vein begins at outer border of first rib as continuation of axillary. Runs medially on first rib, behind subclavius and clavicle, in front of subclavian artery but at a lower level and separated from it by scalenus anterior. Ends at medial border of scalenus ant. by joining int. jugular to form innominate.

Tributary: external jugular. It has a valve on the distal side of the entrance of external jugular.

Veins of Scalp.—*See* p. 262.
Diploic and **Meningeal Veins.**—*See* pp. 54, 55.
Veins of Orbit.—*See* p. 69.

Veins of nose form dense plexuses in the mucous membrane. They combine to form **spheno-palatine,** which passes through spheno-palatine foramen to reach pterygoid plexus. They communicate with ophthalmic and with nasal tributaries of anterior facial.

Pterygoid plexus surrounds pterygoid muscles and receives tributaries which correspond to branches of maxillary art. **Maxillary vein** arises out of the plexus posteriorly, and passes backwards to join posterior facial. (*See also* pp. 306, 307.)

Posterior facial vein is formed by union of superficial temporal and middle temporal veins above zygoma; descends in front of auricle, within parotid gland. Splits

into two divisions which emerge from lower end of parotid gland. *Anterior division* unites with anterior facial to form common facial; *posterior division* unites with posterior auricular to form external jugular.

Anterior facial vein begins at medial angle of eye by the union of supratrochlear and supra-orbital. Runs downwards and backwards behind facial artery. Pierces deep fascia at lower border of mandible and joins anterior division of posterior facial to form common facial. Communicates with pterygoid plexus by deep facial vein. (*See also* p. 267.)

Common facial vein passes backwards across external and internal carotid arteries and joins internal jugular vein under cover of sterno-mastoid.

External jugular vein begins below parotid gland, on sterno-mastoid, by union of post. auricular with posterior division of post. facial. Descends almost vertically over sterno-mastoid, pierces deep fascia at its posterior border an inch above clavicle; crosses third part of subclavian art.; ends in subclavian vein. (*See* p. 275.)

Anterior jugular vein begins in small veins below chin; descends near median plane, pierces the first layer of deep fascia above manubrium; anastomoses with its fellow by means of the *jugular arch*; passes sidewards deep to sterno-mastoid, to end in ext. jugular vein.

Veins of Brain.—Very thin-walled. Described with BRAIN

VENOUS SINUSES OF CRANIUM.—*See* p. 51.

SPINAL VEINS.—*See* pp. 287, 545.

VEINS OF UPPER LIMB

Deep veins, except axillary vein, accompany arteries as venæ comitantes, which are provided with valves; and their blood is conveyed ultimately to axillary vein.

Axillary vein begins opposite lower border of teres major as continuation of basilic vein; runs upwards and medially along medial side of axillary artery; and ends at outer border of first rib by becoming subclavian. It possesses several valves.

Tributaries.—(1) Venæ comitantes of branches of axillary art. (except acromio-thoracic); (2) venæ

comitantes of brachial artery at the lower border of subscapularis; (3) cephalic vein.

Relations of Axillary Vein.—*Anterior*: skin, etc.; pectoralis major; branches of acromio-thoracic artery, and of medial pectoral nerve; pectoralis minor and clavi-pectoral fascia.

Lateral: axillary artery; medial pectoral nerve between vein and first part of artery, medial cord between it and second part, ulnar nerve deeply between it and the third part.

Posterior: first digitation of serratus anterior, subscapularis, latissimus dorsi, teres major; nerve to serratus anterior, superior thoracic art., lateral thoracic art., medial cutaneous nerve of arm, subscapular art. and nerves, nerve to latissimus dorsi.

Medial: lymph-glands; medial cutaneous nerve of arm.

Superficial veins form networks. Chief channels are:—

Dorsal venous arch lies across distal part of back of hand.

Basilic vein begins at medial end of dorsal venous arch, runs along ulnar border of forearm and along medial border of biceps, pierces deep fascia about the middle of upper arm, and ends at lower border of teres major by becoming axillary vein. (*See also* p. 179, 186.)

Cephalic vein begins at lateral end of dorsal venous arch, ascends through lateral part of front of forearm and along lateral side of biceps, pierces deep fascia to ascend in the groove between pectoralis major and deltoid. Below clavicle it turns medially, pierces clavi-pectoral fascia, and ends in axillary vein. (*See also* pp. 178, 185.)

At the elbow, most of its blood is carried away by the **median cubital vein,** which slants upwards and medially to join basilic vein. Before the cephalic vein reaches the clavi-pectoral fascia it is joined by the venæ comitantes of the branches of the acromio-thoracic artery. Cf. tributaries of long saphenous vein near its upper end.

Median vein—not always present—begins at wrist, extends to cubital fossa, connected there with deep veins, and divides into two—*median basilic* and *median cephalic*—which slant upwards and end in basilic and cephalic veins. When median vein is present, its median basilic branch takes the place of median cubital. (*See also* p. 186.)

Vena Cava Inferior and its Tributaries

Inferior vena cava begins on front of body of fifth lumbar vertebra, in intertubercular plane, an inch to the

right of median plane, behind right common iliac art., by union of common iliac veins; ascends over backbone and diaphragm; pierces central tendon between right and median lobes, opposite eighth thoracic vertebra and sixth costal cartilage, an inch to the right of median plane; pierces pericardium, and ends in lower and back part of right atrium.

Relations in Abdomen.—*Anterior*: 1. Liver.

2. Opening into lesser sac, and the free edge of lesser omentum containing portal vein, bile-duct and hepatic artery.

3. First part of duodenum, with portal vein, bile-duct and gastro-duodenal artery intervening between it and vena cava.

4. Head of pancreas and lower part of bile-duct imbedded in the back of head of pancreas.

5. Third part of duodenum and right testicular or ovarian vessels.

6. Peritoneum, with right colic and ileo-colic vessels intervening.

7. Root of mesentery containing superior mesenteric vessels.

8. Right common iliac artery.

Medial:—Aorta in contact with lower part, but separated by right crus of diaphragm and caudate lobe of liver from upper part.

Lateral:—Ureter, kidney, suprarenal, liver, from below upwards. (Upper part is imbedded in a groove on the back of the liver, so that the liver is lateral and medial as well as anterior.)

Posterior:—Diaphragm above, with right phrenic art., small part of suprarenal gland, cœliac ganglion, middle suprarenal and renal arteries intervening. Posterior to it at a lower level there are bodies of lower lumbar vertebræ, anterior longitudinal lig., third and fourth lumbar arteries, sympathetic trunk, and psoas major.

In Thorax.—Owing to slope of diaphragm it presents only posterior and lateral surfaces, both related to pleura and lung. Phrenic nerve descends between its lateral surface and pleura. Pleura and lung separate posterior surface from vena azygos, greater splanchnic nerve, ninth intercostal vessels and ninth thoracic vertebra.

Tributaries.—Both hepatic veins, right phrenic, right

suprarenal, both renals, right testicular or ovarian, third and fourth lumbars of both sides, both common iliacs.

Right and **left hepatic veins** issue from the back of liver, and at once enter v. cava. Caudate lobe often provides a third vein.

Phrenic Veins.—Venæ comitantes of right artery enter vena cava; those of left artery end usually in left suprarenal.

Suprarenal vein issues from hilum of suprarenal. **Right vein** enters vena cava at once. **Left vein** runs down to renal vein.

Right renal vein, half an inch long, crosses to vena cava, in front of the right renal artery, and behind second part of duodenum.

Left renal vein, over two inches long, also in front of its artery, crosses aorta immediately below origin of sup. mesenteric art. Body and head of pancreas are anterior to it, but part of it may be seen through peritoneum below body of pancreas. It receives left suprarenal vein and left testicular or left ovarian vein.

Testicular Vein.—Veins from testis and epididymis accompany artery in spermatic cord as **pampiniform plexus,** from which two veins arise at deep inguinal ring and soon unite to form a single vein which accompanies art. in abdomen. **Right vein** enters v. cava behind third part of duodenum. **Left vein** deviates to the left from its artery; runs upwards between inferior mesenteric vein and ureter, and enters left renal vein, below or behind pancreas, nearer the kidney than suprarenal vein.

Ovarian Vein.—Veins of each ovary also form **pampiniform plexus,** from which two veins issue at brim of pelvis, and terminate in the same way as the testicular veins.

Lumbar Veins.—*Fifth* ends in ilio-lumbar. *Fourth* and *third* in inferior vena cava. *Second* and *first* in ascending lumbar vein. (*See also* p. 377.)

Ascending lumbar vein connects lateral sacral, ilio-lumbar, lumbar and subcostal veins. Lies on the sacrum and lumbar transverse processes. (*See also* p. 377.)

Precentral Vein.—Only occasionally present. Begins by union of small veins on the front of fifth lumbar vertebra. Ascends behind aorta, and ends at aortic opening of diaphragm by dividing into right and left branches which join v. azygos and inferior hemi-azygos. May receive some or all of the lumbar veins.

Common iliac vein begins at inlet of pelvis above the anterior part of internal iliac art., by the union of internal and external iliac veins. Ends on front of body of fifth lumbar vertebra, to the right of median plane, by joining its fellow to form v. cava inferior.

Right vein is behind its artery; and in front of obturator n. and ilio-lumbar artery. **Left vein** passes upwards and to the right, across body of fifth lumbar vertebra and median sacral art., below and medial to left common iliac artery, under cover of peritoneum and hypogastric plexus, to end behind right common iliac art. It is crossed by pelvic mesocolon, sup. rectal vessels, and one set of lower left colic vessels.

Tributaries.—**Ilio-lumbar vein** ends in the back of common iliac.

Median sacral vein : venæ comitantes of median sacral art. unite to form a single vein which lies on the right side of its artery and opens into *left* common iliac.

External iliac vein begins, as continuation of femoral, behind inguinal ligament at medial side of termination of ext. iliac art. Ends opposite lumbo-sacral joint, above the anterior part of internal iliac art., by joining internal iliac vein to form common iliac.

Relations.—Lies medial to the lower part of its artery and behind its upper part. Psoas major is behind its lower part, and lateral to its upper part. Superficially, it is covered with peritoneum, which separates it from intestines. Under cover of peritoneum, it is crossed by lig. teres uteri (or vas deferens), ovarian vessels, ureter, and internal iliac artery. The left vein is crossed also by the beginning of pelvic colon and by branches of the lower left colic arteries with their veins.

Tributaries.—Inferior epigastric and deep circumflex iliac veins end in it near its origin. It may receive a small *pubic vein*, which connects it with obturator.

Internal iliac vein begins at the upper part of the greater sciatic notch by the union of veins that accompany gluteal arteries and other branches of internal iliac ; passes forwards to the medial side of psoas to join external iliac. (*See also* p. 393.)

Tributaries.—*See* p. 393.

Tributaries of portal and systemic veins anastomose in walls of rectum. *Deep dorsal vein* of penis does not end in int. pudendal but passes into pelvis between inferior pubic ligament and transverse perineal ligament to join prostatic plexus ; and in female *dorsal vein of clitoris* ends in vesical plexus. (*Superficial dorsal vein of penis* ends by dividing into right and left branches, which join the right and left superficial external pudendal veins.)

Veins of Lower Limb

Deep veins.—Two venæ comitantes accompany all arteries in lower limb, except popliteal, femoral, and profunda femoris. They have numerous valves.

Popliteal vein begins at distal border of popliteus by union of ant. and post. tibial venæ comitantes. Runs upwards, crossing behind the popliteal art. from medial to lateral side. Ends at the opening in adductor magnus by becoming femoral. It has four valves. **Tributaries** correspond to branches of popliteal artery—with short saphenous vein in addition. (*See also* pp. 230, 231.)

Profunda femoris vein lies in front of its artery, and joins the femoral vein in the femoral triangle.

Femoral vein begins at junction of middle and distal thirds of thigh postero-lateral to its artery, and ends behind inguinal ligament at the medial side of its artery by becoming ext. iliac (*see also* p. 221). Has a valve at its termination, and another where profunda enters it.

Tributaries.—(1) Profunda vein; (2) long saphenous vein; (3) venæ comitantes of descending genicular art., of lateral and medial circumflex, of deep external pudendal and of unnamed muscular.

Relations.—*Anterior to it*: proximally, fascia lata and the cribriform fascia, ext. pudendal arteries (the deep artery may be posterior); distally, the femoral artery. *Lateral to it*, distally, are vastus medialis and the femur; proximally, the artery. *Posterior to it*, at first, is adductor magnus; then, add. longus, separating it from the profunda vessels; then, pectineus (and sometimes add. brevis), separated by the profunda vessels and much fat; and, lastly, the contiguous margins of psoas and pectineus. All these muscles, except psoas, are also *medial to it*; and the femoral canal is medial at its upper end.

Superficial veins form networks. Chief channels are:—

Dorsal venous arch lies across distal part of metatarsus.

Long saphenous vein begins at medial side of foot. Extends upwards in front of medial malleolus and across tibia; then, along medial border of tibia and over posterior part of medial side of knee; inclines laterally and forwards to reach cribriform fascia, which it pierces to enter femoral vein an inch and a half below inguinal lig. It receives numerous unnamed tributaries; and the superficial external pudendal, superficial epigastric and superficial circumflex iliac veins enter it just before it pierces the cribriform fascia. Cf. cephalic vein. (*See also* pp. 211, 245.)

Short saphenous vein begins on lateral border of foot. Extends upwards, behind lateral malleolus and over back of leg, to popliteal fossa, where it pierces popliteal fascia and joins popliteal vein.

PORTAL SYSTEM OF VEINS

Comprises veins that convey blood to liver from spleen, pancreas and abdominal part of alimentary canal (except part of blood from anal canal and lower end of rectum). They correspond to arteries that supply these parts. The

larger veins have no valves, but smaller tributaries have. Veins of portal system communicate with systemic veins at lower end of œsophagus, at lower end of rectum, on posterior wall of abdomen, and along lig. teres of liver.

Portal vein is the chief trunk. It begins behind neck of pancreas, by union of splenic and superior mesenteric, in transpyloric plane opposite first lumbar vertebra, an inch to the right of median plane. Ascends behind first part of duodenum; turns forwards at its upper border to enter lesser omentum, in the right margin of which it ascends to the right end of porta hepatis. There, it divides into right and left branches, which enter right and left lobes of liver, break up and end in capillaries common to them and to branches of hepatic artery.

Hepatic veins arise from these capillaries and carry the blood to inferior vena cava.

Left branch of portal vein is connected with umbilicus by ligamentum teres (remnant of fœtal umbilical vein) and with inferior vena cava by ligamentum venosum (fibrous remnant of fœtal ductus venosus).

Relations.—Posterior: Inferior vena cava throughout, but separated, in its upper part, by the opening into the lesser sac and by the caudate process of liver.

Anterior: *First*—Neck of pancreas.

Next—First part of duodenum, which, owing to its backward slant is lateral as well as anterior; bile-duct and gastro-duodenal art., between duodenum and the vein (artery medial to the duct).

In lesser omentum—Bile-duct and hepatic art.

In porta hepatis—Hepatic arteries are in front of the branches of portal vein; and hepatic ducts are in front of the arteries.

Tributaries.—Splenic, sup. mesenteric, right and left gastric, pancreatico-duodenal, and sometimes inf. mesenteric. Cystic, from gall-bladder, joins its right branch.

Splenic Vein.—Begins in the lieno-renal lig. by union of five or six veins that issue through the hilum of the spleen. Runs to the right and slightly downwards, across kidney and aorta, behind pancreas, below splenic and cœliac arteries, above left renal vein and origin of superior mesenteric artery. Ends behind neck of pancreas, in front of v. cava, by joining sup. mesenteric to form portal vein.

Tributaries correspond to branches of splenic artery (p. 436), and inf. mesenteric vein in addition.

Inferior Mesenteric Vein.—Begins on middle of front of left common iliac artery as a continuation of superior rectal.

Runs upwards on psoas, behind peritoneum, lateral to its artery, medial to ureter, in front of left genito-femoral nerve and testicular artery, and either in front of branches of its artery or behind them.

Above the level of origin of its artery, it ascends to end in splenic vein, behind pancreas, on the left side of aorta or in front of it—or, still farther to the right, in the origin of portal vein. In this, upper part of its course, it lies on psoas and crosses in front of left renal vein, behind peritoneum, with fourth part of duodenum medial to it, and left testicular vein on its lateral side between it and ureter.

Depending on its termination, it may either skirt duodeno-jejunal flexure or pass behind it, or behind the end of duodenum. Ascending branch of upper left colic artery sometimes accompanies it, part of the way.

As the vein approaches the duodeno-jejunal flexure, it often takes a curved course—first upwards and slightly laterally, overlapping left testicular vein, and then medially towards the flexure—raising up a curved ridge or fold of peritoneum that forms the left and upper boundaries of a depression called **paraduodenal fossa.** The fossa is near the lateral side of the fourth part of duodenum and it may be the site of an internal hernia.

Tributaries correspond to branches of the artery (p. 438).

Superior Mesenteric Vein.—Accompanies its artery, lying along its right side; and has practically the same relations. It may be behind or in front of the ileo-colic and right colic arteries.

Tributaries correspond to branches of its artery (p. 437), with right gastro-epiploic and superior pancreatico-duodenal in addition.

Left Gastric Vein.—Accompanies its artery as far as the cœliac artery, and then runs with the hepatic artery to the first part of the duodenum, where it enters the portal vein.

Right Gastric Vein.—Runs to right in company with its artery, and ends in the portal vein as it enters the lesser omentum.

Right gastro-epiploic vein may end in sup. mesenteric or in portal.

A small vein, called **prepyloric,** descends across the front of pylorus under peritoneum, from right gastric to right gastro-epiploic. Its importance is that it is a visible means of identifying the pylorus in an operation on the living person.

A **pancreatico-duodenal vein** accompanies superior artery of that name, and ends in sup. mesenteric; but the main **pancreatico-duodenal vein** runs along the medial side of the bile-duct on the back of the head of pancreas and ends in the portal vein.

CIRCULATION OF BLOOD IN FŒTUS

Preliminary Notes.—(1) Child *in utero* is excluded from air; its **lungs** have therefore no aerating function, and are small. Right and left **pulmonary arteries** are correspondingly narrow: and so are the **pulmonary veins.**

(2) **Pulmonary trunk** is, however, a wide vessel; but its branches (the right and left arteries), being narrow, carry away only a little of its blood; nearly all of its blood passes directly into a short, wide channel, called **ductus arteriosus,** which springs from the bifurcation of pulmonary trunk and joins aorta immediately beyond the origin of the subclavian artery.

(3) **Foramen ovale** of the fœtal heart is a large, oblique opening in the interatrial septum. Blood can pass through it from the right atrium into the left, but not in the opposite direction, because the part of the septum below and behind the opening is slack and overlapping, and acts as a flap-valve.

(4) **Umbilical cord** is a coiled and twisted cord that stretches from the umbilicus to the placenta, and connects the fœtus with the mother. Nearly two feet long; almost as thick as a little finger. Consists of a gelatinous (but firm) material enclosed in a strong, membranous sheath; contains a pair of umbilical arteries and a single umbilical vein.

(5) **Placenta** is a fleshy, vascular organ, flat and circular, over six inches wide and one inch thick. Develops concurrently with the growth of the child *in utero*; is attached to the inner surface of the uterus, usually on its upper (or posterior) wall. In the placenta, the fœtal blood comes into very close relation with the maternal blood, from which it gets both oxygen and food.

(6) In the fœtus, the internal iliac arteries are relatively very large vessels; and they are continued as the **right** and **left umbilical arteries,** which ascend from the pelvis along the back of the anterior wall of the abdomen to the umbilicus, whence they run, in the umbilical cord, to the placenta. **Umbilical vein** arises in the placenta, runs in the umbilical cord to the umbilicus, and thence, in the free edge of the falciform ligament, to the liver, where it joins the left branch of the portal vein.

(7) **Ductus venosus** is a wide vessel that springs from the left branch of the portal vein, and runs upwards in a groove in the back of the liver to join the inferior vena cava at the entrance of the left hepatic vein.

(8) In the fœtus, the blood in the descending aorta is impure. It contains carbon di-oxide and other waste-products of the metabolism of fœtal tissues; it is, in fact, largely venous blood, for it has come into aorta (through the heart) from the veins, in the way explained below. Umbilical arteries carry a large proportion of that impure blood to the placenta. In the placenta, the blood gets rid of waste-products; and it absorbs oxygen and food-stuffs from the maternal blood.

(9) Umbilical vein carries that purified and enriched blood to the liver. Sends some of the blood into the liver *via* branches of the portal vein, but sends most of it directly to the inferior vena cava *via* the ductus venosus. In the fœtus, the umbilical vein and

the ductus venosus are the only vessels of any kind that contain pure, unmixed blood.

(10) **Inferior vena cava** receives the impure blood drained by the veins from the lower limbs and the abdomen; but its uppermost part contains also the purest blood in the body, because the ductus venosus joins it.

Course of Fœtal Blood. — I. (*a*) **Inferior vena cava** receives impure blood from the lower part of the body, and pure blood from the placenta; and it pours that mixed blood into the right atrium.

(*b*) **Valve of inferior vena cava** is big in the fœtus. The valve keeps the inferior caval blood from passing through the tricuspid orifice into the right ventricle, and rather guides it towards the **foramen ovale**, through which it enters the **left atrium**. In the left atrium, it mingles with the small quantity of impure blood that the pulmonary veins have brought from the lungs.

(*c*) From the left atrium, the blood passes through the **mitral orifice** into the **left ventricle**.

(*d*) From the left ventricle, it passes into the **aorta**.

(*e*) The branches of the ascending aorta and of the arch receive most of it, and distribute it to the *heart*, the *upper limbs*, the *neck and head*, and a small part of the trunk; the little remainder of the blood passes on into the descending aorta.

II. (*a*) **Superior vena cava** brings blood back from the upper part of body to the **right atrium**; and it is now wholly impure, venous blood.

(*b*) From the right atrium, this blood passes straight through the **tricuspid orifice** into the **right ventricle**.

(*c*) From the right ventricle, it passes into the **pulmonary trunk**.

(*d*) **Ductus arteriosus** carries nearly all of it from the pulmonary trunk to the **aorta** near the junction of arch and descending aorta.

(*e*) Branches of the descending aorta distribute it to the trunk and lower limbs; and the umbilical arteries carry a great deal of it to the placenta to be purified and enriched.

The course is understood with less difficulty, if it is assumed that the contents of the two venæ cavæ take entirely different routes in the heart; but some mixing of their blood takes place in the right atrium.

Parts supplied with the Richest Blood.—Note that even the best blood sent out by the fœtal heart is mixed—being the blood received from the inferior vena cava.

Some of the best blood goes into the coronary arteries to supply the walls of the **heart**; nearly all the rest of it goes into the innominate, carotid, and subclavian arteries for the supply of the **head, neck,** and **upper limbs.** Therefore, at birth, the head and upper limbs are (compared with adult proportions) relatively very much bigger than the pelvis and lower limbs, whose supply is the much less pure blood of the descending aorta.

Liver is very large at birth; the pure blood sent by the umbilical vein into the branches of the portal vein partly accounts for that.

But growth depends on the quantity of blood as well as the quality of it. The neck is supplied with the same kind of blood as the head is, and yet the neck is so puny that it cannot hold up the head till two or three months after birth. Kidneys and suprarenal glands, in comparison with adult organs, are relatively even larger than the liver is; and yet their whole supply is the poor blood of descending aorta.

Changes after Birth.—(1) When the child is born, its first act is to draw in breath. That expands the lungs and calls them into use for aeration of the blood; the right and left pulmonary vessels widen at once to carry all the blood of the pulmonary trunk to the lungs and back again from them.

(2) Expansion of the lungs alters position of heart in such a way that the **ductus arteriosus** is occluded by twisting. It begins to shrink at once, and has become the impervious *lig. arteriosum* within a week. Occasionally it remains patent—disturbing the circulation and causing peculiar murmurs in the chest.

(3) The greater quantity of blood now brought by the pulmonary veins to the left atrium increases the pressure in that atrium so that the overlapping boundaries of the **foramen ovale** are pressed into permanent contact with each other; they begin to fuse, and the opening is closed within a fortnight. Part of the septum below and behind the foramen forms the floor of the *fossa ovalis* of right atrium; the antero-superior boundary of the foramen forms the *annulus ovalis.* Very often, the closure is not quite complete, and a small, slit-like opening persists under cover of the upper part of the annulus. Occasionally, the foramen ovale remains widely patent —giving rise to a disordered circulation and peculiar murmurs.

(4) **Valve of inferior vena cava** no longer requires to keep blood out of the right ventricle; its rate of growth at once ceases to keep pace with that of heart, and it gradually becomes relatively smaller.

(5) **Umbilical arteries** begin to shrink at once, and, from bladder to umbilicus, have become quite impervious within a week.

(6) In a like time, the **umbilical vein** and **ductus venosus** become impervious; the vein becomes the *ligamentum teres of liver,* and the ductus becomes the *ligamentum venosum.*

LYMPHATIC SYSTEM

Made up of lymph-vessels and lymph-glands. **Lymph-vessels** are exceedingly slender vessels filled with a clear liquid called **lymph** in which numerous white blood-corpuscles are suspended.

Lymph is derived from the blood. Liquid laden with food and oxygen for the tissues is exuded from blood-capillaries. This liquid is found in serous and meningeal cavities and it permeates the tissues of the body. A *network* of *lymph-capillaries* pervades the tissues and re-absorbs the liquid, as lymph, now laden with the products of tissues, including undissolved substances, *e.g.*, fat (lymph from intestine is whitish after a meal, owing to fat absorbed).

Lymph-vessels arise from lymph-capillaries. They anastomose freely, and they unite to form larger vessels which end ultimately in main lymph-vessels, and these vessels end in the large veins in the root of the neck. The largest of these main trunks is the *thoracic duct*; the others are the right and left *jugular*, *subclavian* and *mediastinal lymph-trunks*.

Interposed in the path of lesser vessels there are little nodules of lymphoid tissue called **lymph-glands**; before reaching the larger channels the lymph therefore traverses one or more glands. Vessels which carry lymph to glands are called *afferent*; those which carry it onward from glands are *efferent*; in many cases the efferents of one gland are afferents of another.

Lymph-vessels that drain skin and subcutaneous tissues lie in superficial fascia; those that drain deeper parts accompany deep blood-vessels.

Lymph-vessels can convey infection from diseased parts; their walls are therefore liable to inflammation, and lymph-glands are subject not only to disease arising within themselves but also to infection carried from other diseased structures.

Thoracic duct receives the lymph from, roughly, both halves of the body below the diaphragm and the left half above the diaphragm.

It begins at the upper end of a lymph-sac, called **cisterna chyli**, which lies on the front of the upper two lumbar vertebræ between the aorta and the right crus of diaphragm.

From cisterna the duct passes upwards through the aortic opening of diaphragm; ascends in the posterior mediastinum, first behind diaphragm and then behind œsophagus; inclines to the left at the fifth thoracic vertebra, and ascends in the superior mediastinum closely applied to left side of œsophagus.

Enters the root of the neck and turns sidewards

between carotid sheath and vertebral artery; it then bends downwards in front of subclavian artery, and enters the beginning of the left innominate vein.

It has numerous valves.

Its relations in the successive stages of its course are given on pp. 610, 607, 340.

Tributaries.—Thoracic duct receives various small vessels and several larger ones called lymph-trunks:—

(1) An *intestinal trunk* and (2) a pair of *lumbar trunks*, formed by efferents of lymph-glands in upper part of abdomen, join cisterna and convey lymph from abdomen and lower limbs.

(3) A pair of *descending trunks* from back part of thorax descend to cisterna through aortic opening of diaphragm.

At the root of the neck, efferent vessels of glands in neck and axilla form (4) the *jugular trunk*, and (5) the *subclavian trunk*; these trunks convey lymph from left side of head and neck and from left upper limb; and they end either in thoracic duct or in one of the large veins.

(6) The left *mediastinal trunk* drains lymph from the left half of thorax; usually it ends in the innominate vein, but may end in the thoracic duct.

The *mediastinal*, *jugular* and *subclavian trunks* of the **right** side are described on p. 340.

LYMPH-GLANDS

LYMPH-GLANDS OF LOWER LIMB.—Small **glands in popliteal fossa** (about six) receive deep lymph-vessels from leg and foot and superficial vessels from lateral part of sole and calf; and send efferents to deep glands in groin.

Glands in groin (inguinal) are partly superficial and partly deep. The superficial glands, numerous and large, are often palpable even when healthy. They lie immediately below inguinal lig. and also near the end of long saphenous vein. They receive lymph from superficial tissues of lower part of abd. wall and of whole lower limb (except lateral part of calf and sole), and from *external genitals*, lower parts of *vagina* and *anal canal* and free end of *uterus*; and they transmit it to deep group. Deep group are three or four small glands at the upper end of femoral vein (one may be in femoral canal); they receive lymph from the superficial glands and from the deep parts of the limb, and transmit it to glands around the external iliac artery.

Deep lymph-vessels of buttock and some from thigh accompany gluteal and obturator veins to glands around internal iliac artery.

LYMPH-GLANDS OF ABDOMEN.—In walls of abdomen they are small, few and inconstant. They may be found in superficial

fascia above inguinal lig., on front of pubis, along inf. epigastric art., along sup. epigastric and deep circumflex iliac vessels and near umbilicus. Some lymph-vessels of abdominal wall enter these glands, but most go to glands in axilla, thorax and groin.

Lymph-glands abound in interior of abdomen. They are very important, not only for the part they take in the economy of the body but also because of their liability to infection; in some maladies a knowledge of the position of lymph-glands that receive lymph from the diseased organ is essential for prognosis and for determining the range of operative treatment.

They may be divided into three chief groups: (1) Those in folds of peritoneum; (2) those in pelvis; (3) those on back-wall of abdomen proper.

(1) **Lymph-glands in peritoneal folds** receive lymph from neighbouring viscera and transmit it to glands on posterior wall:—

(*a*) In lesser omentum, especially in its free margin and along the lesser curvature of the stomach.

(*b*) In greater omentum near stomach.

(*c*) In lieno-renal and gastro-splenic ligaments alongside contained blood-vessels.

(*d*) In gastro-phrenic ligament, mesentery of appendix and vascular fold of cæcum.

(*e*) In transverse mesocolon, especially near colon and around the contained blood-vessels.

(*f*) In large numbers—100 to 200—scattered in the mesentery, but chiefly near its root, near the gut and along blood-vessels.

(*g*) In pelvic mesocolon, especially along superior rectal vessels.

(*h*) In broad ligament, especially near cervix uteri.

(2) **Lymph-glands of pelvis** receive lymph from contents and walls of pelvis and from thigh and buttock; they transmit it to glands on posterior wall of abdomen. They lie:—

(*a*) On front of sacrum, especially along median sacral artery.

(*b*) Between bladder and pubis, and at the side of the bladder along umbilical artery.

(*c*) Around internal iliac art. and around the roots of its branches.

(*d*) Around ampulla of rectum, under its fascial sheath.

(*e*) In pelvic mesocolon and broad ligament.

(3) Large numbers of **lymph-glands** are spread **over posterior wall of abdomen.**—They receive lymph (partly directly and partly through other glands) from contents and parietes of abdomen and pelvis, from lower limbs and external genital organs; and their terminal efferents form the lumbar and intestinal trunks.

They are most numerous, and are arranged in chains and clusters, in the following situations:—

(*a*) Around aorta and inferior vena cava.

(*b*) Alongside splenic artery and the first parts of left gastric, hepatic and gastro-duodenal arteries.

(*c*) Alongside mesenteric arteries and their colic branches.
(*d*) Between and alongside the common iliac arteries.
(*e*) Around external iliac artery, especially at its termination.
(*f*) Alongside ascending colon and descending colon (and even in appendices epiploicæ).

Lymph may have to traverse several glands or series of glands before reaching the lymph-trunks; and, generally speaking, the glands near an organ are the first to receive lymph from it. There are exceptions to that arrangement, notably in pelvis and perineum :—

Lymph-vessels of **anal canal** do not all go to nearest lymph-glands (which are in pelvis); some of them run forwards in perineum and turn upwards to glands in groin. So also do lymph-vessels of lower part of **vagina** and of **female external genital organs.**

Lymph-vessels of **testis** and **epididymis** run up with testicular veins to end in glands alongside aorta or vena cava; those of **ovary** and **uterine tube** and some from **uterus** also ascend to that level; a few others from uterus go to glands in groin.

Lymph-glands of interior of abdomen are commonly classified into a large number of named groups that drain territories many of which overlap; and the student, though aware of the importance of the lymphatic system, is apt to be discouraged by the poor progress he makes in studying it.

But what he should attempt to remember is :—

(i.) The regions and organs from which certain well-defined groups of glands receive lymph. In certain parts of the body, *e.g.*, groin, where glands are near the surface, their enlargement may be the first evidence of disease in the structures drained by them; therefore it is necessary to remember which structures these are.

(ii.) The general distribution of lymph-glands rather than the various and varying names of groups.

If he knows where lymph-glands lie, he can, from the position and blood-supply of a given organ, deduce the position of glands that receive lymph from that organ. For, with certain important exceptions noted already, the lymph of an organ goes, in the first instance, to the lymph-glands nearest to it. Ultimately it reaches the glands (near aorta and vena cava opposite upper lumbar vertebræ) from which the tributaries of the lymph-trunks arise; but on the way it may have traversed glands that lie alongside the blood-vessels that supply the organ. Therefore, the glands to be thought of are (*a*) near the organ, (*b*) near its blood-vessels, (*c*) near the abdominal aorta and the inferior vena cava.

Hæmal lymph-glands are found in various parts, especially along abdominal aorta. They resemble lymph-glands, but some of their sinuses contain blood and communicate with blood-vessels.

LYMPH-GLANDS OF THORAX are numerous. They are found:—
(*a*) Along internal mammary vessels.

(*b*) In front of pericardium.

(*c*) Above pericardium, especially alongside trachea and around its bifurcation.

(*d*) In roots, hila and interior of lungs.

(*e*) Behind pericardium, especially alongside aorta.

(*f*) At vertebral ends of ribs and intercostal spaces.

They receive lymph from neighbouring parts of walls of thorax and abdomen, and from neighbouring structures in interior of thorax; **and those around internal mammary vessels receive additional lymph-vessels from mammary glands** (p. 164).

Their efferents end in the mediastinal and descending trunks.

LYMPH-GLANDS OF UPPER LIMB.—The only superficial glands are one or two alongside basilic vein above medial epicondyle, and they are easily felt when enlarged. They receive superficial lymph-vessels from forearm and hand, and their efferents go to glands in axilla.

A few deep glands in cubital fossa, and others alongside brachial art. and in delto-pectoral groove, receive deep and superficial vessels from upper arm and forearm ; a small group between pectoralis major and minor receive vessels **from the mammary gland.**

These groups also transmit their lymph to glands in axilla.

Many lymph-glands lie **in axilla,** chiefly near axillary vein and its tributaries. They receive lymph from deep and superficial parts of upper limb (partly directly and partly through other glands), and lymph also from the side, back and front of the trunk, **including mammary gland.** Their efferents pass to glands in root of neck and to subclavian lymph-trunk.

It is usual to divide the lymph-glands of axilla into groups and to assign names and positions to them. The important points to remember, however, are not the names and reputed positions of the groups, but that :—

(1) Lymph-glands abound in the axilla.

(2) They all, directly or indirectly, receive lymph-vessels from the mammary gland and are liable to infection by disease carried from it.

(3) Disease may pass by their efferents to glands in neck.

(4) They are not palpable when healthy.

(5) They may harbour progressive disease for a long time before they become palpable.

LYMPH-GLANDS OF HEAD.—Receive lymph from neighbouring parts and transmit it to the nearest glands in the neck.

Superficial glands are : (*a*) A few lie on upper end of trapezius and receive lymph-vessels from back of head and neck ; (*b*) a few on insertion of sterno-mastoid drain lymph from auricle and posterior part of side of head ; (*c*) others on surface of parotid drain the rest of auricle and scalp and the superficial structures of upper part of face (vessels of lower part of face go to glands below mandible).

These superficial glands become palpably enlarged and tender when there are festering sores in scalp and face.

Deep glands are: (*a*) A small group imbedded in parotid drain ext. meatus, middle ear, palate, nose and deep parts of cheek. (*b*) Others on the lateral pterygoid muscle drain the contents of temporal and infratemporal fossæ, and of nasal, orbital and cranial cavities. (*c*) Inconstant glands in fat of face drain deeper parts of face. (*d*) Some lymph of tongue and floor of mouth traverses glands between and on genio-glossi and hyo-glossi.

LYMPH-GLANDS OF NECK.—Lymph-glands are very numerous in neck. They are found:—

(*a*) Alongside external jugular vein.
(*b*) Alongside anterior jugular vein.
(*c*) In the groove between mandible and submandibular gland.
(*d*) On mylo-hyoideus below chin—often palpable even healthy.
(*e*) On the front and along the sides of larynx and trachea.
(*f*) Behind the upper part of pharynx.
(*g*) **In large numbers** under cover of sterno-mastoid, on the surface and along the sides of internal jugular vein, extending forwards to overlie carotid arteries and backwards to appear in the posterior triangle behind the sterno-mastoid.

Those various groups receive lymph-vessels from adjacent structures in neck, and from structures in head partly directly and partly through lymph-glands situated in head. The deep glands—*i.e.* those under cover of sterno-mastoid and behind it—receive lymph-vessels from all other glands in head and neck as well as directly from adjacent structures; and those around the third part of subclavian art. and around lower end of int. jugular vein receive, in addition, lymph-vessels **from mammary gland,** and from lymph-glands of axilla and upper part of thorax.

A few lymph-vessels of tongue (p. 619) descend to glands low down in carotid triangle; but, for the most part, lymph-vessels of tongue and of other structures pass, in the first instance, to the nearest lymph-glands, and the lymph is borne, only subsequently, to the deep glands in lower part of neck from which the jugular trunk arises. Therefore: (1) If a structure is diseased or suspected of disease, the nearest glands are examined for evidence of infection. (2) Enlargement of a gland or group of glands suggests disease in a neighbouring structure: enlargement of glands below mandible (in the absence of manifest superficial cause) suggests trouble in teeth or tongue; enlargement of glands near angle of mandible suggests tongue or tonsil. No one gland is the sole recipient of the lymph-vessels of an organ; but any one of a group that drains an organ may become obviously enlarged before others have shown outward signs of infection, and its position varies within the limits of the space occupied by its group.

NEUROLOGY

THE **nervous system** governs the other systems and regulates their activities in order that all parts of the body may work together harmoniously.

It is divided into a central and a peripheral system.

Central nervous system comprises **brain** in cranial cavity and **spinal cord** in vertebral canal. These two are continuous with each other at the foramen magnum.

Peripheral nervous system comprises the **nerves**—cranial, spinal and sympathetic—and the **ganglia** associated with them.

BRAIN and **SPINAL CORD** are made up of **nerve-cells** and **nerve-fibres** and of a supporting tissue, called *neuroglia*, that unites the nerve-cells and nerve-fibres into a putty-like mass.

Nerve-ganglia are small collections of **cells** mingled with **fibres** and held together by a little fine fibrous tissue.

Nerves are cords made of **fibres** bound into bundles by a little fine fibrous tissue. Nerve-fibres are excessively slender threads that conduct impulses or messages. Each fibre springs from a nerve-cell, and it ends either in some other tissue (muscle, gland, skin) or by breaking up into branches around another nerve-cell. Fibres can carry impulses in either direction. Fibres that convey impulses away from the central nervous system are called *efferent*; those that carry impulses towards the central system are *afferent*.

The **nucleus** of a nerve is the group of nerve-cells in the brain or spinal cord with which the fibres of the nerve are connected.

There are 12 pairs of cranial nerves and 31 pairs of spinal nerves.

Each **spinal nerve** contains both afferent and efferent fibres. The part of the nerve nearest the spinal cord is divided into two loose bundles, called its anterior and posterior roots, which are attached to the spinal cord. The **anterior root** is composed of efferent (motor) fibres. The **posterior root** is composed of afferent (sensory) fibres; and a *ganglion* is placed on it from whose cells the fibres of the posterior root spring.

Cranial nerves are attached to the brain in different ways (described with the individual nerves). All except the first two pairs are attached to the part of the brain called the brain-stem. Some

of them are efferent or **motor**—3, 4, 6, 11, 12. Some are devoted exclusively to organs of **special sense**—1, 2, 8. The rest—5, 7, 9, 10—are **mixed** nerves, *i.e.* they contain both motor and sensory fibres. *Ganglia* are placed on the mixed nerves and on the eighth; and the sensory fibres arise in these ganglia.

The nuclei in the brain-stem and spinal cord from which the efferent fibres of a nerve spring are usually called **motor nuclei**; and those in which the afferent fibres end are **sensory nuclei.**

BRAIN OR ENCEPHALON

Brain is about 3 lb. in weight (1360 grm.) and almost fills the cranial cavity. Surrounded by three membranes or meninges named, from without inwards, **dura mater, arachnoid mater** and **pia mater.** When the brain is removed, dura mater is left in the skull; arachnoid and pia mater come away with the brain and have to be pulled away piecemeal before the brain is examined. The blood-vessels are removed at the same time, because the larger blood-vessels lie between arachnoid and pia mater, and the smaller ones ramify in the pia before they enter the brain-substance. On this account, the blood-supply of the brain has to be studied in a specimen from which the membranes have not been removed.

White and Grey Matter.—When the brain is cut, it is obvious that some parts of it are made of grey matter, and other parts of white matter.

White matter is composed of nerve-fibres and neuroglia. **Grey matter** is composed of nerve-cells and nerve-fibres and neuroglia. (*Neuroglia* consists of multitudes of minute cells with numerous branching processes that twine round the nerve-cells and nerve-fibres and bind them together: the word "glia" means *glue.*)

Divisions.—The five main divisions of the brain are—cerebrum, cerebellum, mid-brain, pons and medulla oblongata.

Cerebrum is by far the largest part. **Cerebellum,** next in size, lies below the posterior part of cerebrum. **Mid-brain, pons** and **medulla oblongata** lie one below the other, below cerebrum, in front of cerebellum. They are collectively called the *brain-stem,* for they form a kind of stalk for the cerebrum. Cerebellum, pons and medulla oblongata are collectively called the *hind-brain.*

Hind-brain lies in posterior cranial fossa, under cover

of the tense fold of dura mater called tentorium cerebelli. Cerebrum lies on tentorium and on the floors of middle and anterior cranial fossæ. Mid-brain is a short, thick isthmus that connects cerebrum with hind-brain, and occupies the doorway or opening of tentorium.

In brain-stem, the white matter is at the surface and the grey matter is inside. In cerebrum and cerebellum, the white matter is inside; most of the grey matter is at the surface, but there is some grey matter inside also; the grey matter at the surface is called the **cortex.**

External Characters of Cerebellum and Cerebrum.—Cerebellum has a **right** and a **left hemisphere** united by a median portion called the **vermis.** Hemispheres and vermis are cut into by a large number of narrow, deep, parallel *fissures* that give the cerebellum a characteristic foliated appearance. The grey matter at the surface lines the sides and bottom of each fissure; therefore each folium consists of a sheet of white matter covered on both sides with grey matter.

Right and left halves of cerebrum are called **cerebral hemispheres.** They are almost completely separated by a great, antero-posterior cleft called the **longitudinal fissure.** On the surface of each hemisphere there is a large number of *sulci* that vary from open, shallow grooves with visible floors to narrow clefts of an inch or more in depth. Some are short and some are long; some are sinuous and some are nearly straight. In different brains they vary in length, shape and direction, and they are unlike even in the two halves of the same cerebrum. But the size and position of some of them are sufficiently alike in different brains for a fairly constant pattern to be recognised; and many of them are named.

The grey matter of the surface lines the sides and bottom of each sulcus; and, since it does so and since the grooves are numerous and many of them deep, the surface area of grey matter is about five times as great as the surface area of the hemisphere. In this way the cortex is folded into an undulating layer. This is the only way in which the increasing amount of grey matter in the developing brain can be accommodated, for it cannot increase in thickness—that being determined by the histological structure of the different parts of the cortex. The areas, strips and ridges between the grooves are

called *gyri*; each gyrus has a core of white matter and a cortex of grey matter.

Lobes of Cerebrum.—For descriptive purposes, each cerebral hemisphere is divided, more or less artificially, into four main parts called **lobes**—frontal, occipital, parietal, temporal.

Frontal lobe is the anterior part, and is the largest part—reaching back almost to the middle.

Occipital lobe is the small, pointed, posterior part.

Parietal lobe—less easily recognised—lies between frontal lobe and the upper part of occipital lobe.

Temporal lobe is in front of the lower part of occipital lobe, below parietal and frontal lobes; and its anterior part bulges on the lower surface of the hemisphere.

Cavities of Brain.—Ventricles; aqueduct; central canal.

Inside each cerebral hemisphere there is a space called a **lateral ventricle**. It is divided into: (*a*) *Central part*; (*b*) *anterior horn*, which extends forwards into the frontal lobe; (*c*) *posterior horn*, which curves backwards into occipital lobe; (*d*) *inferior horn*, which sweeps downwards and then forwards into temporal lobe.

Between the lower parts of the two hemispheres there is an enclosed space called the **third ventricle**; it communicates with the lateral ventricle on each side through a slit called the *interventricular foramen*.

Aqueduct is a narrow tunnel that traverses the mid-brain from above downwards, and leads from the third ventricle to the fourth.

Fourth ventricle is a space in the hind-brain. Bounded posteriorly by cerebellum, and anteriorly by pons and upper half of medulla oblongata. Continuous inferiorly with a narrow **central canal** that tunnels the lower half of medulla oblongata and the whole length of spinal cord.

Ventricles, aqueduct and central canal are lined with a kind of ciliated epithelium called *ependyma*, and they are filled with a clear, yellowish liquid called *cerebro-spinal fluid*, which is secreted by certain specialised parts of the ependyma.

Upper Surface of Brain.—When the brain is examined from above, the only parts seen are the cerebral hemispheres. They are almost completely separated by the longitudinal fissure, which, before removal of the brain, was occupied by a fold of dura mater called *falx cerebri*.

The anterior parts of the two hemispheres are completely separated by the fissure, and so are the posterior parts; but the middle parts are united by a number of structures, of which the chief is the corpus callosum.

Median part of **corpus callosum** is seen at the bottom of longitudinal fissure when the hemispheres are pulled apart; and the pair of arteries that may be seen on its surface are the *anterior cerebral*. Corpus callosum is a long, wide, thick sheet of white matter, largely hidden in the interior of the hemispheres. Its main part is called its **trunk**. Posterior end or margin is thickened, and is called the **splenium**. Anterior margin is thickened and bent downwards and then backwards, and is called the **genu**. Lower part of genu is continued downwards and backwards as a thin sheet, called the **rostrum**, whose lower (or posterior) edge is connected with a transverse, rounded white bundle, called the *anterior commissure*, which assists the corpus callosum to connect the two hemispheres, and will be seen at a later stage of the dissection.

Lower Surface of Brain.—When the **base of brain** is examined, parts of all five of the main divisions can be seen.

On each side, anteriorly, there is the **frontal lobe** of the cerebrum, whose anterior extremity is called the *frontal pole*. The surface of the lobe seen here is called the *orbital surface*, because it lies mainly on the roof of orbit. Between the two frontal lobes, there is the anterior part of the **longitudinal fissure**; and, if its lips are pulled apart, the **genu** and **rostrum** of corpus callosum can be seen. On the orbital surface, the slender, white structure, seen near (and almost parallel to) the fissure, is the **olfactory tract** and **bulb**. The bulb is the slightly swollen, anterior half-inch of it; and the filaments of the olfactory nerve are attached to it. Both bulb and tract can be lifted out of the groove in which they lie (*olfactory sulcus*); but, posteriorly, the tract divides into diverging *roots*—a *lateral* and a *medial*—which are attached to the brain.

Behind the orbital surface, there is the bulging, anterior part of **temporal lobe**, whose anterior end is called the *temporal pole*. Postero-medial to the temporal pole, there is a part of the surface (about the size of a thumb print) called the *uncus*. It is separated from the temporal pole by a dent called *rhinal notch*; and it is the anterior part of the **hippocampal gyrus**, which lies in the medial part of

the lower surface of the hemisphere, and is largely hidden by cerebellum, if cerebellum is in place. **Stem of the lateral sulcus** is the name of the wide, deep, horizontal cleft between temporal lobe and orbital surface.

Posteriorly, the two hemispheres of cerebellum are seen, and, between them, the anterior surfaces of two large, white bodies—medulla oblongata and pons.

Medulla oblongata is the lower of the two, and tapers slightly towards its lower end, which was severed from the spinal cord when the brain was removed. A **median fissure** divides this surface of medulla oblongata into halves. The big bundle alongside the fissure is called the **pyramid**; lateral to its upper part there is an oval elevation called the **olive**; and, postero-lateral to that, a part of a big, rounded bundle called the **inferior cerebellar peduncle** is seen. Lower part of median fissure is interrupted by a number of small bundles that cross from one side to the other, interdigitating with the bundles of the other side. These bundles come from the pyramids; and their pleated crossing is called the **decussation of the pyramids.** If the large arteries of base of brain have been retained, the large pair seen winding from the sides of medulla on to the front of it are the *vertebral arteries*; they unite at the lower border of pons to form the *basilar artery*.

The row of slender nerve-bundles that emerge through the groove between pyramid and olive are the roots of *hypoglossal* nerve (12th cranial; motor). The row that emerges from the side of the lower half of medulla are the roots of upper part of the *accessory* nerve (11th c.; motor). The more crowded row of bundles attached to medulla a little behind the olive are mostly the roots of *vagus* (10th; mixed), but the uppermost are the roots of *glosso-pharyngeal* (9th; mixed). *Auditory* nerve (8th; special senses) is really two nerves joined together—*cochlear* (hearing) and *vestibular* (equilibration); they separate to clasp the inferior peduncle at the lower border of pons. *Facial* (7th; mixed) is attached to lower border of pons close by the medial side of vestibular. *Abducent* (6th; motor) is the slender nerve that issues through lower border of pons at the upper end of lateral margin of pyramid.

Pons is the large, white mass that lies above medulla oblongata, between the antero-superior parts of the hemispheres of cerebellum. Along its median line there is a

shallow groove, called **basilar groove**, in which the *basilar artery* lies. On each side, the pons narrows, inclines backwards, and sinks into the cerebellar hemisphere. The part that sinks into cerebellum is called the **middle cerebellar peduncle**. The thick nerve attached to the side of pons is the trigeminal (5th ; mixed). It is used as the march-stone between pons and middle peduncle : the part between the right and left nerves is pons ; the part beyond each nerve is the peduncle. A small, semi-detached part of cerebellum, called the **flocculus**, lies on lower surface of the middle peduncle. It is easily identified ; and it is useful as a guide to the auditory and facial nerves, which lie close together at its medial side, the auditory being the nearer to it. The part of pons seen here is its large, anterior or basilar part. The basilar part is made mainly of white matter ; but in its interior there are little nests of grey matter called **nuclei pontis**.

Mid-brain lies above the pons. The parts of it seen in the base are the right and left **basis pedunculi**—a pair of short, thick, white bundles (as wide as a finger) set close together at the upper border of pons, but diverging from each other as they are followed upwards.

Mid-brain, as a whole, is divisible into a **tectum** and a pair of **cerebral peduncles**. The tectum is its posterior part, and is therefore quite hidden at present. The cerebral peduncles make up the bulk of the mid-brain. Each pedunculus has three parts—named, from before backwards, basis pedunculi, substantia nigra, tegmentum.

The **tegmentum** is a large mass of mixed grey and white matter, and is nearly all fused with the tegmentum of the other peduncle. A small part of each tegmentum is at the surface near the pons in the floor of the interval between the two bases pedunculorum.

The **substantia nigra** is a thin layer of dark-coloured grey matter between tegmentum and basis.

The bundles of fibres that compose the **basis pedunculi** are slightly twisted, giving it a resemblance to a piece of thick rope. Inferiorly it sinks into the pons. From the pons, it extends upwards and in a lateral direction, diverging from its fellow and widening ; it disappears under cover of the uncus and sinks into the cerebral hemisphere. The nerve-bundles that emerge from the narrow groove between its medial margin and the tegmentum

are the roots of *oculomotor* (3rd cranial; motor). The slender nerve that curves forwards round its lateral margin is the *trochlear* (4th; motor). If large vessels are in place, the two that wind backwards round the peduncle are the *posterior cerebral artery* and the *basal vein*.

Optic chiasma is the short, flat, transverse, white bar that lies nearly an inch in front of pons at the posterior end of the part of longitudinal fissure seen in this view.

Optic nerves (2nd; special sense—sight) are the pair of round bundles attached to the anterior corners of chiasma. The pair of *optic tracts* begin at the posterior corners.

Each tract is a white band that passes backwards and in a lateral direction; it disappears under cover of the uncus, where it clasps the upper end of basis pedunculi and finally divides into a *medial* and a *lateral root*.

If chiasma is pulled downwards and backwards, a very thin (and easily torn) sheet of grey matter, called **lamina terminalis**, is seen extending upwards from it to be attached to the rostrum of corpus callosum at the anterior commissure. The lamina forms a great part of anterior wall of the third ventricle.

Interpeduncular fossa is a diamond-shaped space bounded by chiasma, anterior parts of optic tracts, the cerebral peduncles and upper border of pons. Structures seen within its boundaries (besides the oculomotor nerves) are, from behind forwards, posterior perforated substance, mamillary bodies and tuber cinereum with its infundibulum; and they form a great part of the floor of the third ventricle.

Mamillary bodies are a pair of small, white, pea-like bodies set side by side about the middle of the fossa. **Posterior perforated substance** is a small collection of grey matter behind the mamillary bodies, and it is pierced by small vessels. **Tuber cinereum** is a low, grey elevation between the mamillary bodies and the chiasma.

Before the brain was removed, the tuber cinereum was connected with *hypophysis cerebri* by a funnel-shaped stalk called the *infundibulum*. Hypophysis is a grey body, about the size of a large pea, that lies in hypophyseal fossa of skull under the diaphragma sellæ. When the brain was removed, the infundibulum was cut or torn across and the hypophysis was left in the skull.

Vallecula cerebri is the small, triangular space lateral

to the chiasma, large enough to accommodate only a finger-tip. The grey matter that forms its floor is pierced by small vessels, is called the **anterior perforated substance,** and is continuous with certain grey masses inside the hemisphere called *basal nuclei*. In a brain hardened *in situ*, the perforated substance and vallecula are *bounded —postero-medially* by optic tract, *anteriorly* by the roots of olfactory tract; *laterally* by the uncus (which overlaps it). The vallecula is continuous with the stem of lateral sulcus under cover of (*i.e.* above) the overlapping uncus. *Internal carotid artery* ends in vallecula by dividing into anterior and middle cerebral. *Middle cerebral artery* passes into the stem of lateral sulcus. *Anterior cerebral* passes above the root of optic nerve, between the nerve and the brain, to reach the longitudinal fissure, where it curves round the genu of corpus callosum and runs backwards on its trunk.

CEREBRAL HEMISPHERE

Surfaces.—Supero-lateral, medial, inferior. **Supero-lateral surface** is convex and adapted to vault of skull. **Medial surface,** flat and perpendicular, bounds longitudinal fissure. **Inferior surface,** uneven; divided by stem of lateral sulcus into an anterior and a posterior part. Anterior part is called *orbital surface*; small and concave; lies on the roof of orbit and roof of nose. Posterior part, larger, is called *tentorial surface*; lies on the floor of middle cranial fossa and on tentorium cerebelli; concave, and looks downwards and in a medial direction.

Poles —(1) **Frontal pole,** p. 465. (2) **Temporal pole,** p. 465. (3) **Occipital pole** is the posterior end of hemisphere; on it there is a broad, shallow groove (better marked in right hemisphere) for the end of superior sagittal sinus and beginning of transverse sinus.

Borders. — **Supero-medial** or **upper border** extends from frontal pole to occipital pole, between medial and supero-lateral surfaces; related, in its whole length, to superior sagittal sinus.

Infero-lateral or **lower border** extends from temporal pole to occipital pole, between tentorial and supero-lateral surfaces; posterior half is related to transverse sinus. **Pre-occipital notch** is a small impression on it, about an

inch and a half in front of occipital pole, and is produced by a slight bulging of the adjacent bone.

Superciliary border arches from frontal pole to lateral sulcus, between orbital and supero-lateral surfaces.

Infero-medial border is divided into three parts : (*a*) **Medial occipital border** extends from occipital pole to splenium of corpus callosum, between the posterior parts of medial and tentorial surfaces; fits into the angle between falx cerebri and tentorium, and is related to straight sinus. (*b*) **Hippocampal border** is the medial margin of the rest of the tentorial surface ; it is the medial edge of the hippocampal gyrus, and is separated from mid-brain by a gap that contains posterior cerebral artery, basal vein and trochlear nerve. (*c*) **Medial orbital border** extends from frontal pole to chiasma, between orbital surface and anterior part of medial surface ; lies on roof of nose, separated from its fellow only by meninges and crista galli.

Supero-lateral Surface of Hemisphere

Parts of all the four main lobes—*frontal, parietal, occipital, temporal*—are seen ; and, besides them, there is a submerged part of cortex, called *insula*, which is hidden in the lateral sulcus and is sometimes ranked with the lobes. The lobes provide a convenient means of dividing the supero-lateral surface, but are of little service in that respect on the other surfaces.

Interlobar Sulci.—Lateral ; parieto-occipital ; central ; circular.

Lateral sulcus has a stem and three branches.

Stem is the deep, wide, horizontal cleft on the base of the brain between frontal and temporal lobes. Begins at the vallecula; and it ends on supero-lateral surface by dividing into three rami at a spot opposite the pterion of the skull. Posterior margin of roof of orbit and the superficial middle cerebral vein lie between the lips of the stem ; deep middle cerebral vein and middle cerebral artery lie deeply within it.

Horizontal anterior ramus, less than an inch long, runs forwards into the frontal lobe a little above the superciliary border. **Ascending anterior ramus,** nearly an inch long, runs upwards and forwards into the frontal lobe. Those two rami may arise by a short common root.

Posterior ramus—more important than the stem and the other two rami—runs backwards and slightly upwards for nearly three inches, and then turns sharply upwards to end at the most convex point of supero-lateral surface. Its horizontal part has temporal lobe below it, and frontal and parietal lobes above it. Upturned part is in the parietal lobe ; the gyrus rolled round its termination is the anterior part of the inferior parietal lobule, and it underlies parietal eminence of skull. Branches of middle cerebral artery and deep middle cerebral vein lie deeply within the ramus ; and the superficial middle cerebral vein lies at the surface between its lips.

Central sulcus is a long, deep, oblique cleft situated about mid-way between frontal and occipital poles (hence the name "central") ; it is the middle one of three more or less parallel furrows that run obliquely downwards and forwards in that region. Begins at supero-medial margin a little behind its middle ; runs forwards and downwards between frontal and parietal lobes, forming with supero-medial margin an angle of about 70° (reckoned for convenience as three-quarters of a right angle). Ends near posterior ramus about an inch behind the end of stem of lateral sulcus. Its course is sinuous as well as oblique, the widest bend curving round behind the motor area of upper limb (p. 472).

Parieto-Occipital Sulcus.—Deep, nearly vertical cleft on medial surface, an inch and a half in front of the occipital pole. Upper end cuts the supero-medial margin, and, to the extent of its depth, it appears therefore on the supero-lateral surface between parietal and occipital lobes, almost opposite lambda of skull. Gyrus rolled round its end on the supero-lateral surface belongs to both parietal and occipital lobes, and is called *arcus parieto-occipitalis*.

Circular sulcus is the groove that circumscribes the base of the insula.

Frontal Lobe.—On supero-lateral surface, it is *bounded posteriorly* by central sulcus, *superiorly* by supero-medial margin, and *inferiorly* by superciliary margin and the first inch of posterior ramus of lateral sulcus.

Chief sulci are pre-central, superior and inferior frontal. (The anterior rami of lateral sulcus cut into lower part of the lobe.) **Pre-central** is nearly parallel to central

sulcus and a finger's breadth in front of it, and is divided into separate *upper* and *lower* parts. **Superior frontal** runs forwards from the upper part, and **inferior frontal** from the lower part.

Chief gyri are the pre-central, and superior, middle and inferior frontal.

Pre-central gyrus is the most important gyrus of the hemisphere, for it contains nearly the whole of the **motor area** of opposite half of body. It is the gyrus between the central and pre-central sulci, and it extends from supero-medial margin to posterior ramus. It lies under the anterior part of parietal bone and the structures of scalp and upper part of temporal fossa. The meninges separate it from the main stem of anterior branch of middle meningeal artery, which grooves the deep surface of the parietal bone ; and its upper end is below the largest of the lacunæ laterales of superior sagittal sinus.

The body is, as it were, turned upside-down in the motor area :—The area for *head* is in the lowest part of the gyrus ; next is *upper limb* ; and then *trunk* ; area for *lower limb* is in the uppermost part, and flows over on to medial surface. Anterior cerebral artery supplies the uppermost inch or half-inch of the gyrus ; middle cerebral supplies the rest.

Superior frontal gyrus is the region above superior frontal sulcus. *Middle frontal gyrus* is between the superior and inferior sulci ; the part of it in front of its centre lies under the frontal eminence.

Inferior frontal gyrus is the region below inferior frontal sulcus. Anterior rami of the lateral sulcus divide its lower part into three :—*Pars triangularis*, between these rami ; *pars orbitalis*, below them ; and *pars posterior*, behind them.

Motor centre for speech is in the lower parts of the pre-central and inferior frontal gyri of *left* hemisphere in right-handed people.

Temporal Lobe.—On supero-lateral surface, it is *bounded posteriorly* by the lower part of a line drawn from parieto-occipital sulcus to pre-occipital notch, *superiorly* by the horizontal part of the posterior ramus and a line continuing its direction backwards, *inferiorly* by infero-lateral border ; its *anterior* end is the temporal pole.

Chief sulci are superior and inferior temporal.

Superior temporal sulcus is sometimes divided into two parts. It is a finger's breadth below posterior ramus of lateral sulcus and is parallel to it, and, like that ramus, its posterior part bends up into parietal lobe; the gyrus of parietal lobe that is rolled round its end is the middle part of the inferior parietal lobule. **Inferior temporal sulcus**—a finger's breadth below the superior, and parallel to it—is near the infero-lateral margin. Usually divided into separate parts. Most posterior part bends up into parietal lobe, and it is often difficult to identify it; gyrus rolled round its end is the posterior part of the inferior parietal lobule, and is separated only by a sulcus from arcus parieto-occipitalis.

Chief gyri are *superior*, *middle* and *inferior temporal gyri* into which the surface is divided by the two sulci. Posterior branch of the middle meningeal artery runs parallel with the middle gyrus or with the inferior sulcus (separated from it by the meninges).

Centre for hearing is in the upper part of the middle of *superior temporal gyrus* and in adjoining part of the hidden, upper surface of the lobe. In left hemisphere, it is connected with the motor centre for speech by fibres which pass deep to the insula, and, by means of them, it exercises some control over the centre for speech.

Parietal Lobe.—On supero-lateral surface, it is *bounded superiorly* by supero-medial margin, *anteriorly* by central sulcus, *posteriorly* by parieto-occipital sulcus and a line drawn from it towards pre-occipital notch, *inferiorly* by the horizontal part of posterior ramus and a line continued backwards from it. The lobe is entirely under cover of parietal bone.

Chief sulci are the post-central and intraparietal; lower part of the lobe is broken up also by the ends of posterior ramus and superior and inferior temporal sulci.

Post-central sulcus is a finger's breadth behind central sulcus and has the same general direction. Divided into *upper* and *lower* parts, which, however, are often united in the adult. *Intraparietal sulcus* begins at or near one or other part of post-central. It runs backwards, and, passing between arcus parieto-occipitalis and the posterior part of the inferior parietal lobule, it enters the occipital lobe, where it soon divides into two widely diverging branches—the medial one forming the posterior

boundary of the arcus. The sulcus is often interrupted at the arcus.

Chief gyri are the post-central gyrus and the parietal lobules.

Post-central gyrus is the strip between the central and post-central sulci. It is an important gyrus, for it contains the **sensory area** (common sensation) of the opposite half of the body. As in the motor area, the body is turned upside-down in the sensory area, and the part for lower limb overflows into the medial surface.

Intraparietal sulcus divides the rest of the lobe into **a superior** and an **inferior parietal lobule.**

Parietal half of arcus parieto-occipitalis is partly cut off from the posterior part of superior lobule.

Inferior lobule is divided into three parts :—

1. *Anterior part,* around the end of posterior ramus of lateral sulcus, is the most convex part of hemisphere and lies under parietal eminence. It and the middle part contain the centre where the memory of the meanings of written and printed words is stored.

2. *Middle part,* around the end of sup. temporal sulcus.

3. *Posterior part,* around the end of inferior temporal sulcus, is immediately lateral to arcus parieto-occipitalis ; but it is often difficult to identify it.

Occipital Lobe.—On supero-lateral surface, it is *bounded superiorly* by supero-medial margin, *inferiorly* by infero-lateral margin, and *anteriorly* by parieto-occipital sulcus and a line drawn from it to pre-occipital notch.

Sulci and gyri are very inconstant.

Centre for sight is in occipital lobe. It is chiefly in the medial surface, but it may extend over the supero-medial margin into a small area on the lateral aspect immediately above the occipital pole.

Insula.—A pyramidal elevation that lies hidden at the bottom of lateral sulcus. The groove that circumscribes its base is the *circular sulcus.* Branches of middle cerebral artery lie on its surface, and so do the deep middle cerebral vein and its tributaries.

Opercula insulæ = the parts of cortex that overlap and conceal insula. There are four of them. They are bounded by, and separated from one another by, the stem and rami of lateral sulcus :—(1) **Temporal operculum,** between stem and posterior ramus, overlaps insula from below

and behind. (2) **Fronto-parietal,** between posterior ramus and ascending anterior ramus, overlaps it from above. (3) **Frontal,** between the two anterior rami (and therefore synonymous with *pars triangularis*), overlaps it from above and in front. (4) **Orbital operculum** is the posterior part of *pars orbitalis*; it lies between the stem and horizontal anterior ramus, and overlaps insula from in front.

BLOOD-SUPPLY OF SUPERO-LATERAL SURFACE.—Arteries come from all three cerebral arteries. Branches of **anterior cerebral** supply a strip, nearly an inch wide, along supero-medial margin, from frontal pole almost as far back as parieto-occipital sulcus. Branches of **posterior cerebral** supply arcus parieto-occipitalis and nearly all the occipital lobe and inferior temporal gyrus. Branches of **middle cerebral** supply the rest.

Veins end in *transverse sinus* and *superior sagittal sinus* and in *anastomotic* and *middle cerebral veins*. Veins that enter posterior part of sagittal sinus are peculiar in that they enter it from behind forwards—*i.e.* against the direction of blood-flow in the sinus.

Superficial middle cerebral vein lies at the surface between the lips of lateral sulcus. It begins near the end of posterior ramus, runs forwards in the ramus, and then medially in the stem to end in cavernous sinus. From the beginning of superficial middle vein, the **superior anastomotic vein** runs upwards to superior sagittal sinus, and the **inferior anastomotic** runs downwards to transverse sinus. **Deep middle cerebral vein** lies hidden in lateral sulcus on the surface of insula, and receives the veins from insula and deep surfaces of opercula. It ends in the basal vein. **Basal vein** is formed, in the vallecula, by the union of deep middle cerebral and anterior cerebral and a small vein, called *inferior striate*, which descends from the interior through anterior perforated substance. Basal vein curves backwards round the mid-brain and joins the *great cerebral vein* as that vein emerges from the interior below the splenium. Great cerebral vein then joins inferior sagittal sinus to form the straight sinus.

SMALLER FEATURES OF SUPERO-LATERAL SURFACE.[1]—A ridge across the bottom of *central sulcus*, opposite the motor area for trunk, indicates the original condition of the sulcus—*i.e.* separate upper and lower parts. Occasionally the original condition persists, and the ridge is at the surface.

The grey matter of **centre for sight** is divided into two layers by a thin sheet of white matter, seen in section as a white line called the **visual stria**; visual area is therefore often called the **striate area.** Posterior end of **post-calcarine sulcus** (an important cleft on the medial surface) often cuts the supero-medial margin a little above the occipital pole, and appears on the supero-lateral surface;

[1] Students should not read the paragraphs and sections in the smallest type till they have a fairly good grounding in what is described in the ordinary type.

it is only in such cases that the centre for sight encroaches on the supero-lateral surface ; and in these cases the limit of the visual area is marked by a curved groove called the **sulcus lunatus.**

Upper surface of temporal lobe forms the lower wall of posterior ramus of lateral fissure, and is applied to the insula and to the upper wall, which consists of the hidden surfaces of the parts of frontal and parietal lobes that form the frontal and fronto-parietal opercula. On those concealed surfaces, there are small sulci and gyri. The two gyri on the posterior part of upper surface of temporal lobe are named **anterior** and **posterior transverse temporal gyri** ; the anterior one contains a great part of the **centre for hearing.**

INSULA is a more or less three-sided elevation with its apex below and in front. **Circular sulcus,** around its base, is therefore triangular. The sulcus is interrupted at the antero-inferior corner ; for, at that point, the apex of insula is connected with the lateral part of the anterior perforated substance by a smooth, low ridge called the *limen insulæ* ; the ridge is produced by a bundle of fibres, called the fasciculus uncinatus, covered with a thin layer of grey matter. The surface of the insula is divided into two *long gyri* posteriorly, and several *short gyri* anteriorly.

Medial Surface of Hemisphere

When the brain is removed from the skull, the mid-brain is usually cut across about its middle ; when, later, the cerebrum is divided to expose the medial surface of the hemisphere, the knife bisects also the upper half of the mid-brain.

When the medial surface of half of the cerebrum is examined, the following parts are to be identified :—

(1) Supero-medial margin ; medial orbital margin ; medial occipital margin.

(2) Cut edge of bisected **corpus callosum** (which is a landmark) shows its *splenium, trunk, genu* and *rostrum.*

(3) **Cortex**—behind, above, and in front of the corpus callosum.

(4) The thin, white longitudinal strip seen a little below corpus callosum is the cut edge of the bisected **body of fornix,** which is a horizontal, triangular sheet of white matter seen more fully later.

(5) **Septum lucidum** is the thin, vertical sheet that fills the interval between corpus callosum and fornix. If it was destroyed when the brain was divided, a large cavity—the lateral **ventricle**—is exposed ; and, in that, a rounded, bulging mass of grey matter is seen, called the **head of the caudate nucleus.**

(6) Below fornix, there is the smooth, medial surface of a large mass of grey matter called the **thalamus.** It forms most of the side-wall of the median space called the **third ventricle.**

(7) If veins are full of blood, the **great cerebral vein** may be seen lying lengthwise in the narrow interval between fornix and thalamus.

(8) **Anterior column of fornix** is the round bundle (about the thickness of a wax-taper) that begins at the anterior end of body of fornix, curves downwards in front of thalamus, and sinks into side-wall of third ventricle. Slit between column and thalamus is the **interventricular foramen**; it leads from third ventricle into lateral ventricle.

(9) **Anterior commissure** is a white bundle, about the same thickness as column of fornix; it passes across from one hemisphere to the other, and has been bisected; its cut end is seen immediately in front of the column, at the lower or posterior end of rostrum of corpus callosum.

(10) Half of the bisected **lamina terminalis** is the thin, fragile sheet of grey matter that extends from the rostrum downwards and forwards to the bisected *optic chiasma* (already seen on the base).

(11) Behind chiasma there are, in sequence, half of tuber cinereum, one mamillary body, and half of posterior perforated substance (already seen on base).

(12) Behind these, and below thalamus, there is seen half of the bisected, upper part of the **mid-brain.** Posterior part of mid-brain is called the *tectum*, and its posterior surface is raised to form two pairs of rounded eminences, called *corpora quadrigemina*; and one of the upper pair is seen on the back of this half. *Cerebral pedunculus* (p. 467) makes up nearly the whole of each half. *Basis pedunculi* is seen on the front. *Tegmentum* was fused with its fellow and therefore makes up most of the cut surface. If the cut was exactly median, half of the bisected *aqueduct* is seen in the posterior part of the tegmentum.

(13) Above and behind upper end of aqueduct, there is a thin folded sheet that encloses a slender, white bundle called **posterior commissure.**

(14) Above and behind that, there lies half of the **pineal body** (about the size of a barley-corn); but, if the dividing knife was blunt, it may have been torn off.

(15) A slight ridge separates the medial surface of thalamus from its upper surface and leads back to the base of pineal body; and part of the upper surface of thalamus may be seen.

Chief Sulci of Medial Surface.—Callosal, calcarine, post-calcarine, parieto-occipital, suprasplenial and sulcus cinguli.

Callosal sulcus is the narrow slit above corpus callosum.

Sulcus cinguli is the groove about a finger's breadth from corpus callosum. It begins below anterior part of corpus callosum, arches upwards in front of genu, runs backwards above the trunk almost as far as splenium, and then turns sharply upwards to end by cutting supero-medial margin just behind upper end of central sulcus. (Central sulcus is not always easily identified on supero-lateral surface. The surest guide to it is sulcus cinguli; for sulcus cinguli is easily identified, and the sulcus that begins at the supero-medial margin immediately in front of the end of sulcus cinguli is the central.)

Suprasplenial sulcus, an inch or less in length, variable in position; usually nearly horizontally about a finger's breadth above and behind splenium.

Calcarine sulcus is a deep cleft that begins on tentorial surface a little below splenium, runs upwards and backwards on to the medial surface to join the lower end of the parieto-occipital sulcus; it is so deep that it produces an elevation, called *calcar avis*, in the medial wall of posterior horn of lateral ventricle. **Post-calcarine sulcus** is the continuation of the calcarine. It runs downwards and backwards to the occipital pole, and often curves round the margin on to the supero-lateral surface.

Parieto-occipital sulcus is a deep, nearly vertical cleft, about an inch and a half in front of occipital pole. Begins at the posterior end of calcarine sulcus and runs upwards to cut supero-medial margin; its upper end has been seen already on the supero-lateral surface between parietal and occipital lobes.

Chief Gyri of Medial Surface.—Gyrus cinguli and isthmus; g. rectus; medial frontal, including paracentral lobule; precuneus; cuneus; g. lingualis.

Gyrus rectus is the horizontal strip, half an inch wide, immediately above medial orbital margin; it includes that margin and appears also on the orbital surface.

Medial frontal gyrus is all the rest of the long, wide area between supero-medial margin and sulcus cinguli; it is bounded posteriorly by the upturned terminal part of sulcus cinguli. A branch of s. cinguli partly cuts an inch or more off its posterior part. That part is called *paracentral lobule*; for the upper end of central sulcus cuts into it, and it is continuous, over supero-medial margin, with the upper ends of the pre- and post-central gyri; its upper part contains the motor and sensory centres for the foot of the opposite side.

Gyrus cinguli is the strip that separates corpus callosum from sulcus cinguli and suprasplenial sulcus. It is so named because it contains a thick, longitudinal bundle of fibres called the *cingulum*. The gyrus is separated from the corpus callosum by the callosal sulcus. It begins below the anterior part of corpus callosum near anterior perforated substance, arches upwards around genu, runs backwards above the trunk of corpus callosum, and ends at the splenium by becoming continuous with a narrow strip of cortex, called the isthmus. The *isthmus* curves downwards between splenium and the anterior part of calcarine sulcus, and connects gyrus cinguli with the hippocampal gyrus of the tentorial surface.

Precuneus is the quadrate area *bounded inferiorly* by suprasplenial sulcus, *anteriorly* by the upturned part of sulcus cinguli, *superiorly* by supero-medial margin, and *posteriorly* by parieto-occipital sulcus.

Cuneus is the wedge-shaped area *bounded* by supero-medial margin, parieto-occipital sulcus, and post-calcarine sulcus.

Gyrus lingualis is the wide area below the calcarine and post-calcarine sulci; it includes the medial occipital border, and its lower part is on the tentorial surface.

Centre for sight is in occipital lobe in relation to the calcarine and post-calcarine sulci—below the calcarine, on both sides of the post-calcarine and accompanying that sulcus on to the supero-lateral surface.

BLOOD-SUPPLY OF MEDIAL SURFACE.—Branches of **anterior cerebral artery** supply it almost as far back as parieto-occipital sulcus; branches of **posterior cerebral** supply the rest. The veins end in **anterior cerebral vein** and in the adjoining *sinuses*—superior and inferior sagittal and straight.

Inferior Surface of Hemisphere

Divided by stem of lateral sulcus into orbital and tentorial parts.

ORBITAL SURFACE

Lies on roof of orbit and also on roofs of nose, ethmoidal sinuses, and anterior part of sphenoidal sinus. Is the lower surface of frontal lobe, and is *bounded anteriorly* and *laterally* by superciliary margin, *medially* by medial orbital margin, and *posteriorly* by vallecula and by stem of lateral sulcus.

Chief Sulci and Gyri.—Olfactory and orbital sulci; gyrus rectus and orbital gyri.

Olfactory sulcus is near and almost parallel to medial orbital margin. Olfactory tract and bulb lie on it and conceal all but its anterior end. The strip between it and medial orbital margin is the lower surface of *gyrus rectus*, which lies on roof of nose (cribriform plate) and on sphenoidal sinus. *Orbital sulci* usually form an H-shaped figure which divides the rest of the surface into *anterior, posterior, medial,* and *lateral orbital gyri*; the lateral gyrus is part of pars orbitalis of inferior frontal gyrus.

TENTORIAL SURFACE

Rests posteriorly on tentorium, and anteriorly on floor of the middle cranial fossa. Posterior part is therefore concave, and slopes from above downwards and sidewards; anterior part is rounded. The part in front of the middle of the surface rests on the roofs of internal ear and middle ear, tympanic antrum and pharyngo-tympanic tube. In that region (in brains hardened *in situ*), there is a depression, called *petrous impression*, that accommodates the arcuate eminence made by superior semicircular canal of internal ear; and from that the parts related to the middle ear etc. can be gauged if the upper surface of the base of the skull is examined.

Tentorial surface comprises the inferior surfaces of occipital and temporal lobes. It is *bounded* by occipital and temporal poles, infero-lateral margin, and medial occipital and hippocampal margins.

Chief Sulci.—Rhinal; collateral; occipito-temporal; calcarine.

Anterior part of **calcarine sulcus** cuts into the surface below the splenium.

Rhinal sulcus—short and not always present—extends backwards from the *rhinal notch* that separates the uncus from the temporal pole.

Collateral sulcus begins near occipital pole and runs forwards to end at or near the rhinal sulcus or notch. May be broken into two or more parts. Its middle part is the cleft that is seen about a finger's breadth lateral to hippocampal margin; and it sinks so deeply into the brain that it produces an elevation, called *collateral eminence*, in the floor of inferior horn of lateral ventricle.

Occipito-temporal sulcus, usually broken into several parts, is more or less parallel to collateral sulcus, between it and infero-lateral margin; it is not always easy to identify it.

Chief Gyri.—Lateral and medial occipito-temporal; lingual; hippocampal, and the isthmus.

Lateral occipito-temporal gyrus is the strip between the infero-lateral border and the occipito-temporal sulcus.

Medial occipito-temporal gyrus is the long, fairly wide strip that extends from occipital pole to temporal pole between occipito-temporal and collateral sulci.

Gyrus lingualis is the area that separates the collateral sulcus from the calcarine and post-calcarine sulci; part of it has therefore been seen already on the medial surface.

The **isthmus**—also seen already on the medial surface—is the narrow strip between the splenium and the anterior part of calcarine sulcus.

Hippocampal gyrus is an important gyrus, for it contains the centres for taste and smell. It is the most medial strip on the anterior part of tentorial surface, and lies between the collateral sulcus and the gap that separates tentorial surface from mid-brain. *Posterior end* of the gyrus is continuous, medially, with the isthmus, and, laterally, with gyrus lingualis.

Anterior inch of the hippocampal gyrus is slightly enlarged and is called the *uncus*, because its small, medial and upper part is bent backwards and gives it a slight resemblance to a hook. **Uncus** is separated from temporal pole by the rhinal notch; overlaps basis pedunculi, and hides the posterior part of optic tract; forms the postero-lateral boundary of vallecula and anterior

perforated substance ; and it lies above cavernous sinus and trigeminal ganglion.

Hippocampal gyrus has an upper surface, which can be seen if the medial margin of the gyrus is pulled downwards ; laterally, the cortex of this surface is continuous with the grey interior of the hippocampus—which is one of the structures that lie in the floor of inferior horn of lateral ventricle. A partial view of those structures may be obtained when the medial edge of hippocampal gyrus is pulled downwards. They are :—(1) **Hippocampus**—an elongated, curved, white elevation. (2) **Fimbria**—a tapering, white band prolonged from fornix ; it lies along the medial side of hippocampus and is fused with it, but shows a sharp, free, medial edge. (3) **Dentate gyrus** — a thin lamina of grey matter whose only visible part is its notched margin, which is seen under the free edge of the fimbria.

Centre for taste and smell is in the anterior half of hippocampal gyrus, including uncus.

BLOOD-SUPPLY OF INFERIOR SURFACE.—All three cerebral **arteries** are implicated. **Anterior cerebral** supplies medial half of orbital surface : **middle cerebral** supplies lateral half and temporal pole : **posterior cerebral** supplies all the tentorial surface except the temporal pole.

Veins of orbital surface end in **anterior cerebral** and **superficial middle cerebral veins.** Those of the tentorial surface end in **basal** and superficial middle cerebral veins, and in the neighbouring ***sinuses***—superior petrosal, transverse, and straight.

Cortical Areas

Motor area of the inverted opposite half of the body (defined on p. 472) contains the centres for **individual movements** such as bending a finger or straightening the knee. It comprises the anterior wall of the central sulcus and the adjoining part of the free surface of the pre-central gyrus and of the paracentral lobule. But the following parts also should be included :—the rest of the anterior part of the paracentral lobule, the rest of the pre-central gyrus and the adjoining parts of the three frontal gyri. In these parts there are higher centres that preside over the centres for individual movements and make them combine, *in an ordered sequence*, to carry out **acts** such as fastening a button or rising from a chair. Different parts of the body may be involved in such an act ; therefore this extension of the area cannot be sharply subdivided, but the centre for conjugate movements of eyes and associated movements of head have been located in the postero-inferior part of the middle frontal gyrus

and the centre for speech in the lower part of the inferior frontal gyrus.

Frontal area comprises the remainder of the frontal lobe, including the orbital surface and the medial frontal gyrus. Its functions are imperfectly known. Injury to this area has been followed by great diminution of the faculty of concentration and of even ordinary attention, and by gradual mental deterioration. Association fibres (p. 498) connect it with all parts of the cortex. Possibly, the association fibres bring to it the memories of the interpretations of experiences of *every kind* to be classified and co-related and to have their effects and reactions registered; therefore, it may be the centre for the intellectual processes.

Sensory area for ordinary sensation is the post-central gyrus and the posterior part of the paracentral lobule; as in the motor area, the opposite half of the body is represented in it upside-down. Sensations are received into consciousness in the *anterior part* of the area, and their quality is recognised there; in the *posterior part* they are related to past experience and thereby interpreted.

Parietal area comprises the rest of the parietal lobe, including the precuneus. It is surrounded by the interpreting parts of the sensory, auditory, visual, and olfactory areas, and is connected with them by association fibres. Items of information received and interpreted in these different centres are sent on to the parietal area to be co-related with one another and their meaning made clearer. Reading is an example of such co-relation, for it requires the combined memories of hearing and sight. Identification of an object by touch alone requires the aid of the memory of past visual experience; and the middle part of the inferior parietal lobule, being specially connected with the pulvinar (p. 504), may be the centre for that common function of the sense of touch. Playing the piano requires the co-related and combined memories of touch, sight and hearing. A smell, a tune or a picture often revives the memories of a variety of other sensory impressions whose sum is the memory of a particular event or situation.

The activities of the parietal area are on a lower plane than those of the frontal area, for it deals only with the information about material things.

Auditory area is in the upper and lateral surfaces of superior temporal gyrus. The small, secondary gyri in the posterior part of the upper or hidden surface and the adjoining middle part of the lateral surface constitute the area where sounds enter the consciousness and where the loudness, pitch, quality and direction are recognised. The rest of the gyrus contains the centres where the sounds are related to past experience and are interpreted; on the left side, this is therefore an important area in connection with speech.

The functions of the other temporal gyri and of the insula are not known.

Visual area is in the occipital lobe. Impressions of light are received in the cortex around the post-calcarine sulcus and below the calcarine; colour, size, shape and movement are recognised there. Most of the remainder of the occipital lobe on all of its three surfaces is used for the interpretation of the primary impressions.

Gustatory area is probably included in the olfactory area, since taste is closely allied to smell.

Olfactory area is difficult to identify owing to the complexity of the rhinencephalon and to the dispersion and partial suppression of its components by the growth of other parts of the human cerebrum. Probably the perceiving centre is the anterior half of hippocampal gyrus, and the interpreting centres are in the rest of that gyrus and in the lingual and medial occipito-temporal gyri and gyrus cinguli.

Rhinencephalon

Comprises a very large number of structures, many of which are mere vestiges in Man. It includes :—gyrus cinguli and isthmus, cingulum, hippocampal gyrus, hippocampus, fornix, mamillary body, mamillo-thalamic bundle, hippocampal commissure, septum lucidum, indusium griseum, paraterminal, splenial and dentate gyri, anterior perforated substance, olfactory pyramid, tract and bulb, part of anterior commissure, habenular nucleus and commissure. Several of them are described with the regions which they occupy.

The part most specially associated with the sense of smell is the uncus ; its surface differs from other parts in its whitish colour and peculiar, roughened, warty texture. It is the *posterior* and larger *part* of a **piriform area,** which represents in Man what is a very large part of the brain in lower animals. The *anterior part* of the area has become in Man a mere inconspicuous ridge that begins at the posterior end of the olfactory tract, runs laterally under cover of its lateral root, widens to form the limen insulæ, and then bends backwards to join the uncus.

Olfactory bulb is an elliptical body, over half an inch in length, made of grey matter covered with nerve-fibres. It lies in the olfactory sulcus of the brain and on the lateral edge of the cribriform plate of the ethmoid. Olfactory nerves (about 20), from olfactory mucous membrane, enter its lower surface.

Olfactory tract is a prismatic, white band continued backwards from the bulb; it lies in the olfactory sulcus and on the jugum sphenoidale. Both tract and bulb can be lifted out of the sulcus. Tract divides posteriorly into two roots which are attached to the brain. **Medial root** curves medially, in the posterior end of gyrus rectus and above the optic nerve, to reach the medial surface of the hemisphere, where it ascends to end partly by disappearing in gyrus cinguli, and partly by becoming continuous with the indusium griseum (p. 485). **Lateral root** is more easily seen. It runs backwards and in a lateral direction along the antero-lateral margin of the anterior perforated substance (in which some of its fibres end) to reach the limen insulæ, and it then bends sharply backwards across the floor of the stem of the lateral sulcus to end in the supero-lateral part of the uncus.

Olfactory pyramid is a triangular elevation of grey matter between the lateral and medial roots ; it fits into the posterior end of the olfactory sulcus, and its base is continuous posteriorly with the anterior perforated substance.

Anterior perforated substance is the grey matter that forms the floor of the vallecula cerebri.

Anteriorly, it is bounded by the roots of the olfactory tract; *laterally*, it is overlapped by the uncus, and is continuous with the limen insulæ; *postero-medially* it is bounded by the optic tract and is continuous with tuber cinereum and paraterminal gyrus; and its *deeper* parts are continuous with masses of grey matter in the interior, called basal nuclei, namely, amygdaloid, caudate, and lentiform nuclei and the claustrum.

The longitudinal striæ of indusium run through its posterior part, superficially, to reach the temporal lobe. The anterior commissure crosses its deep or upper part. Two bundles of fibres of the interior of the brain, called ansa peduncularis and ansa lenticularis, bend in a lateral direction between it and the anterior border of internal capsule. Its cells are connected with fibres of cingulum, of olfactory tract, and of slender bands in the interior called the habenular and semicircular striæ.

The striate vein or veins and the central branches of the middle cerebral artery perforate it. The basal vein begins below it; and the internal carotid artery ends there.

Paraterminal gyrus is a small strip of grey matter on the medial surface of the hemisphere immediately in front of the margin of the lamina terminalis, between that lamina and the ascending part of the medial root of olfactory tract.

Indusium griseum is a very thin, transparent sheet of grey matter spread over the upper surface of corpus callosum. Each half of it contains two slender strands of fibres called *longitudinal striæ*—a *medial* near the median plane, and a *lateral* under cover of gyrus cinguli. *On each side*, the indusium is continuous with gyrus cinguli at the bottom of the callosal sulcus. *Posteriorly*, it divides, and each half is continuous with the splenial gyrus and the hippocampus. *Anteriorly*, it bends downwards round the genu to the lower surface of the rostrum, and divides into right and left halves, each of which divides into two parts. One part joins the grey matter that underlies the medial olfactory root. The other part contains the longitudinal striæ; it runs downwards in the anterior margin of the paraterminal gyrus and then laterally, as a *diagonal band*, through the anterior perforated substance to the temporal lobe immediately lateral to the uncus.

Splenial gyrus is a slender band of grey matter continuous with the indusium. It curves downwards round the lateral part of the splenium, and, widening, is continued into the dentate gyrus.

Dentate gyrus is seen best when the part of the brain that shows the inferior and posterior horns is detached from the rest of the brain. It is an elongated, curled lamina of grey matter largely contained within the hippocampus, but protruding medially as a notched margin between the fimbria and the upper surface of the hippocampal gyrus. Posteriorly, it is continuous with the splenial gyrus. Anteriorly, it disappears into the cleft of the uncus; but it emerges again as a smooth, delicate band, called the *tail of dentate gyrus*, which curves medially over the inferior surface of the recurved part of uncus, and is lost on its surface.

Hippocampus.—An elongated, curved elevation in the floor of the inferior horn of the lateral ventricle. Composed of grey matter inside and white matter (called *alveus*) on the surface. Medial margin is the concave margin, and has the fimbria attached to it. Posterior end is narrow and curves upwards round the splenium to become continuous with the indusium. It expands as it extends forwards. Its anterior end is at the extremity of the inferior horn, and is called the *pes hippocampi* because grooves and notches on it give it a resemblance to the paw of an animal.

CORPUS CALLOSUM

A long, wide, thick sheet of white matter. Chief commissure of the hemispheres. Its fibres radiate to all parts of cortex except the lower and anterior parts of the two temporal lobes, which are connected by the anterior commissure.

Forms the floor of the longitudinal fissure ; unites the medial surfaces of the hemispheres in nearly half of their length, but is nearer the anterior than the posterior end of the brain. Concave downwards antero-posteriorly ; concave upwards from side to side.

Divisions.—Trunk. Genu, rostrum, and forceps minor. Tapetum. Splenium and forceps major.

Trunk is its main part. **Genu** is its anterior end or border—so named because it is bent downwards and then backwards. Lower part of genu is thin and is prolonged, as a thin lamina called the **rostrum**, downwards and backwards to be united by neuroglia to the upper edge of lamina terminalis at the anterior commissure. **Forceps minor** is the arch formed by genu and its curved extensions forwards into the two frontal lobes.

Splenium is the posterior end or border. Thick because it is reduplicated—*i.e.* bent downwards and forwards, and the lower part closely applied to the upper. **Forceps major** is the wide arch formed by splenium and the big bundle that curves backwards from it into the cuneus of each side ; this bundle bulges in the medial wall of the posterior horn of the ventricle, above calcar avis, producing an elevation called the *bulb of posterior horn*.

The upper part of the splenium passes as a thick, curved bundle into the posterior part of the precuneus. The posterior part of the lower (or reduplicated) portion passes into the cuneus as part of the forceps major ; most of the anterior part passes as a curved

bundle into the gyrus lingualis, but the fibres of the anterior edge of the reduplicated portion run into the alveus of the hippocampus.

Trunk is the main part, and most of its fibres sink into the white substance of the hemisphere above the caudate nucleus; as they do so, they intersect a great part of *corona radiata*. (The corona is a great system of fibres more or less vertically arranged in the white substance.) But the deepest fibres of the most posterior part of the trunk and the deepest fibres of the upper layer of the splenium form the tapetum.

Tapetum is a thin layer that passes as an uninterrupted sheet into the white substance. In the white substance, it spreads and curves to form (1) the roof and lateral wall of the posterior horn of the lateral ventricle, and (2) the lateral wall of the inferior horn; it lies between the ependyma and a part of the corona radiata called the *optic radiation*.

RELATIONS.—Upper surface of corpus callosum is covered with a thin, transparent layer of grey matter, called *indusium griseum*, in which two pairs of slender strands of fibres, called longitudinal striæ, are imbedded; and each half is related to the anterior cerebral vessels and to gyrus cinguli with its contained cingulum—though partly separated by the callosal sulcus.

Falx cerebri is in contact with the upper surface of splenium; and splenium overhangs the superior corpora quadrigemina, pineal body, great cerebral vein and the base of a triangular fold (or double layer) of pia mater, called *tela chorioidea*, which lies in the interior of the brain.

Superficial surface of genu and rostrum is related to the anterior cerebral vessels. Deep surface has the septum lucidum attached to it at the median plane; on each side, it is covered with ependyma of the anterior horn of the ventricle—since the genu lies in the anterior wall of the horn, and the rostrum in its floor.

Lower surface of the trunk has septum lucidum attached to it along the median plane (except posteriorly where the base of the body of fornix is adherent to corpus callosum in front of splenium). On each side of the septum, the surface forms the roof of the anterior horn and central part of lateral ventricle; is lined with the ependyma of the roof; and is separated by the cavity of the ventricle from the ependyma that covers the structures in the floor—namely, body of fornix, choroid plexus (a band of convoluted blood vessels in the margin of tela chorioidea), upper surface of thalamus and caudate nucleus.

Septum Lucidum and Fornix

Septum Lucidum.—A vertical, median partition between the lateral ventricles, separating their anterior horns and central parts. Occupies the triangular interval between fornix and corpus callosum; is attached to them by its edges, and to the anterior commissure by its antero-inferior angle. Consists of a pair of laminæ separated by a narrow cavity, which is shut in on all sides. Each lamina is made of grey and white matter, and is covered with the ependyma of lateral ventricle.

Fornix.—Highly arched. Made of white matter. Situated below corpus callosum. Some of its fibres are longitudinal, and connect parts on the same side of the median plane; others are commissural fibres that connect the right hippocampus with the left. Has a body and two pairs of columns.

Body of fornix is arched from before backwards; flattened from above downwards; triangular in outline, with the apex in front. Right and left halves are fused in the median plane. *Apex* is at the level of the interventricular foramina; there, the halves separate to form the anterior columns. *Base* is immediately in front of the splenium; there, the halves separate to form the posterior columns.

Posterior part of *superior surface* is adherent to the lower surface of corpus callosum. Anterior part is connected by the septum lucidum to the corpus callosum in the median plane; on each side of the septum, it lies in the floor of the central part of lateral ventricle, and is covered with ependyma. *Inferior surface* rests on the tela chorioidea, which separates it from the two thalami and from the ependyma that forms the roof of the third ventricle.

Each of its *margins*—*right* and *left*—is a free edge along which the choroid plexus lies.

Each **anterior column of fornix** is a rounded bundle that arches downwards in front of the interventricular foramen and behind the anterior commissure, diverging slightly from its fellow. It then sinks into the side-wall of the third ventricle, and runs downwards and backwards to the base of the brain to end in the mamillary body.

Each **posterior column of fornix** is thin and wide, and it is, at first, adherent to the corpus callosum. Diverges from its fellow; curves downwards behind the posterior end of thalamus; enters the inferior horn and runs forwards in its floor. There, its fibres partly spread sidewards to form the superficial white layer of the hippocampus, and partly run onwards along the medial margin of the hippocampus, forming a prominent edge or ridge, called the **fimbria,** which narrows down and ends in the tip of the recurved part of the uncus.

Most of the fibres of fornix arise in the hippocampus, dentate

gyrus and uncus, and probably convey olfactory impressions. Many of them run lengthwise, from behind forwards, in the fornix to end in the mamillary body, from which the mamillo-thalamic bundle (p. 506) conveys the impressions to the thalamus. Others cross and run in the reverse direction, to the other hippocampus, forming the *hippocampal commissure*.

Olfactory bundle consists of some fibres that leave the anterior column, descend in front of the anterior commissure, through the edge of rostrum, and enter the indusium, in which they run to the medial root of olfactory tract and to the uncus. These fibres form part of a bundle that lies in the upper medial part of each half of the body of the fornix, and leaves the fornix to join the splenium; from the splenium it runs backwards between the ependyma and the bulb of the posterior horn to the occipital lobe; it is probably a link between the olfactory and visual areas.

Stria habenularis (p. 505) is a slender bundle that leaves the anterior column and runs backwards to the habenular nucleus. *Stria semicircularis* (p. 494) joins the anterior column.

Tela Chorioidea of Third Ventricle

A double layer of pia mater thrust horizontally into the interior of the brain through the gap below the splenium. Triangular in outline, with the apex in front. Lies below the body of the fornix, on the medial parts of the upper surfaces of the two thalami and on the ependyma which forms the roof of the third ventricle.

Between its two layers it contains: (*a*) Choroid plexuses of the third ventricle, internal cerebral veins, and great cerebral vein, in or alongside the median plane; (*b*) choroid plexus of lateral ventricle and the choroid vein, in each of its two margins. The ependyma that covers the portions containing the plexuses is specialised to secrete the cerebro-spinal fluid.

Apex of the tela lies between the interventricular foramina; its two layers are continuous with each other there. The layers are continuous also at each **margin**, which bulges beyond the edge of the fornix into the lateral ventricle. **Base** lies below the splenium. There, the upper layer is continuous, round the splenium, with the pia mater on the corpus callosum and the hemispheres; the lower layer is wrapped round the pineal body, and then becomes continuous with the pia mater on the mid-brain.

Choroid plexus of lateral ventricle is an elongated, vascular plexus related to the central part and inferior horn of the lateral ventricle. *Upper part* lies in the margin of the tela, on the upper surface of thalamus, along the margin of the body of fornix; it bulges into the central part of ventricle, invaginating the ependyma of the floor; at the apex of the tela it communicates with its fellow. *Lower part* is continuous with the upper part at the posterior corner of the tela, and extends downwards and forwards along the medial wall of the inferior horn of the ventricle. That wall consists of ependyma alone. The plexus bulges into the horn, pushing the pia

mater and the wall of ependyma before it ; and, in a dissection, the plexus appears to lie in the cavity of the horn.

From the communication between the right and left plexuses at the apex of the tela, a pair of **choroid plexuses of third ventricle** extend backwards, side by side, between the layers of the tela, bulging the lower layer and the ependymal roof of the third ventricle downwards into the ventricle.

Arteries that enter the plexus are the *choroid branches* of internal carotid and posterior cerebral. **Veins** end in the veins that lie inside the tela—namely, choroid, internal cerebral and great cerebral.

Choroid vein begins in the inferior horn, runs alongside the plexus to the interventricular foramen, where it unites with the thalamostriate vein to form the internal cerebral vein. Right and left **internal cerebral veins** run backwards alongside the choroid plexuses of the third ventricle. At a varying point, they unite to form the **great cerebral vein,** which emerges from the tela at its base and curves upwards to unite with the inferior sagittal sinus to form the straight sinus.

The **thalamo-striate vein** runs along the medial side of the caudate nucleus in the roof of the inferior horn and in the floor of the central part of the lateral ventricle. It draws tributaries from the thalamus, the corpus striatum and the other basal nuclei ; and it ends at the interventricular foramen by uniting with the choroid vein.

Caudate and Amygdaloid Nuclei and Stria Semicircularis

Caudate nucleus (*see also* p. 493) is an elongated body of grey matter, curved into almost a circle, and therefore cut in two places by both horizontal and coronal sections. Large, convex part in the lateral wall of the anterior horn is the **head.** Narrowing portion in the floor of the central part of the ventricle is the **body.** The **tail** is the thin but fairly wide part in the roof of inferior horn. The tail ends in a mass of grey matter, called **amygdaloid nucleus,** which makes a rounded bulging in the most anterior part of the roof of inferior horn (*see also* p. 494).

Stria semicircularis (*see also* p. 494) is a slender band of fibres that lies along the medial side of the tail and body of the caudate nucleus, in company with the thalamo-striate vein.

LATERAL VENTRICLE

The cavity of the cerebral hemisphere. Communicates with the third ventricle through the **interventricular foramen,** which is a slit on the medial side of the lateral

ventricle, *bounded anteriorly* by the anterior column of fornix, and *posteriorly* by the anterior end of thalamus.

Ventricle is divided into a central part and three horns —anterior, posterior, inferior.

Anterior horn is the part in front of the interventricular foramen. **Roof:** trunk of corpus callosum. **Floor:** rostrum of corpus callosum. **Anterior wall:** genu of corpus callosum. **Medial wall:** septum lucidum. **Lateral wall:** the head of caudate nucleus, and, occasionally, part of the white substance of the hemisphere between caudate nucleus and roof.

Central part extends from interventricular foramen to splenium. **Roof:** trunk of corpus callosum. **Medial wall:** septum lucidum. **Floor:** caudate nucleus, stria semicircularis and thalamo-striate vein, thalamus, choroid plexus and body of fornix—in that order both lateromedially and from before backwards. Floor and roof usually meet laterally.

Posterior horn begins at the splenium, and curves backwards and medially into the occipital lobe, tapering to a point. **Roof and lateral wall:** tapetum of corpus callosum. **Infero-medial wall:** bulb of posterior horn, superiorly; calcar avis, inferiorly.

Inferior horn curves backwards and laterally behind the thalamus, then downwards and forwards into the temporal lobe, and, lastly, medially into the uncus. **Roof:** (1) tail of caudate nucleus; (2) stria semicircularis, along the medial side of the tail; (3) amygdaloid nucleus, at the anterior part of the roof. **Lateral wall:** tapetum of corpus callosum. **Medial wall:** ependyma only; and it is bulged into the cavity by the choroid plexus. **Floor:** hippocampus, with the fimbria along its medial margin, and the collateral eminence placed lateral to it.

Hippocampus is a pronounced, curved, white elevation, and, in the specimen in hand, the choroid plexus may conceal it; **fimbria** is a salient, white ridge or band attached to its medial margin. **Collateral eminence** is an elongated, antero-posterior, white elevation produced by the collateral sulcus; it may be absent, especially if the horn is narrow.

Collateral trigone is the floor of the part of the ventricular cavity that lies lateral to the point of divergence of posterior and inferior horns; the posterior part of collateral eminence appears in it.

The ependyma which forms the medial wall of inferior horn is continuous with the ependyma of the roof at the stria semicircularis, and with the ependyma of the floor at the fimbria.

Choroid fissure is a long, narrow, curved cleft that extends from the interventricular foramen to the anterior end of the inferior horn. *Upper part* is between the upper surface of thalamus and the body of fornix; *middle part* is between the posterior end of thalamus and the posterior column of fornix; *lower part* is between stria semicircularis and fimbria. Through the fissure, the choroid plexus (enclosed in pia mater) bulges into the central part and inferior horn of the ventricle, pushing the ependyma before it.

Transverse fissure is the gap below the splenium through which the tela is continuous with the pia mater of the exterior.

BASAL NUCLEI

Amygdaloid; caudate; lentiform; and claustrum.

Are large collections of grey matter in the interior of the hemisphere; but all of them approach the surface at the base of the brain, and are continuous with the anterior perforated substance. Amygdaloid and caudate nuclei are visible through the ependyma of the lateral ventricle; but the lentiform nucleus and claustrum are imbedded in the white substance of the hemisphere.

Caudate and lentiform nuclei are connected by bands of grey matter and are together called **corpus striatum.**

Amygdaloid and **caudate nuclei** were noted when the lateral ventricle was examined.

Claustrum.—Thin plate of grey matter co-extensive with insula. Lies between the white matter of insula and a thin sheet of white matter called **external capsule.**

Lentiform Nucleus.—A large body of grey matter that lies medial to the claustrum and therefore opposite the insula. Bi-convex on horizontal section, and triangular on coronal section. *Lateral surface* is covered, in sequence, by external capsule, claustrum, and insula. *Medial surface* is angled, and is closely applied to the thick layer of white matter called *internal capsule*; internal capsule separates its anterior part from the head of caudate nucleus, and its posterior part from the thalamus. Lateral and medial surfaces meet at the convex, *upper border*. *Lower surface* is nearly flat; its anterior part lies on the anterior perforated substance and is continuous with it; posterior part lies on the white matter

above the roof of inferior horn. The optic tract lies a little below the medial margin of the lower surface.

Both horizontal and coronal sections show that the medial part of lentiform nucleus is paler than the rest of it. The pale part is called the **globus pallidus**; the lateral part—much larger—is called the **putamen.**

CORPUS STRIATUM = caudate nucleus + lentiform nucleus. They receive the name "striatum" because, in coronal sections through their anterior ends, the grey bands that connect them give the internal capsule a cross-barred appearance.

Caudate nucleus has: (1) A large, convex **head,** which forms the lateral wall of the anterior horn of the ventricle; (2) a narrow, tapering **body,** in the floor of the central part of the ventricle; and (3) a thin, flat **tail,** in the roof of the inferior horn.

Its surfaces are superficial and deep. *Superficial surface* is covered with ependyma. *Deep surface* of the head lies on the medial surface of anterior part of the internal capsule; that of body and tail lies on the base of corona radiata.

Bands or laminæ of grey matter pass through the capsule and corona from the caudate nucleus to connect it with the lentiform nucleus. These laminæ become thicker and more numerous at the head of the nucleus, until the two nuclei are practically fused antero-inferiorly. Fused, lowest part of the head is imbedded in the white substance of the gyrus rectus and the posterior orbital gyrus, and, behind that, it is continuous with the anterior perforated substance. Anterior commissure, as it sinks into the hemisphere, runs in a lateral direction below the head.

In the central part of the ventricle, the medial edge of the caudate nucleus is related to the stria semicircularis and thalamo-striate vein, which separate it from the thalamus; lateral edge is related to a band of long association fibres, called the *fronto-occipital bundle,* which separates it from the base of corona radiata. In the roof of the inferior horn, the tail is in contact by its medial edge with the stria semicircularis, and by its lateral edge with the free margin of the tapetum; and the tail is continuous anteriorly with the amygdaloid nucleus.

Lentiform nucleus is almost completely encapsuled in white matter. The white matter on its lateral surface is the external capsule, and that on its medial side is the internal capsule. It does not reach so far forwards or so far upwards as the caudate nucleus does, nor so far back as the thalamus does. Its bi-convex outline in horizontal sections gives it the name "lentiform". Its small, pale, medial **globus pallidus** is separated from the larger, lateral **putamen** by a thin layer of white matter called **lateral medullary lamina**; and the globus is divided into lateral and medial parts by a **medial medullary lamina** of white matter.

Lateral surface is uniformly convex, and is smooth, except that at the lower part it is grooved by the striate arteries before they enter its substance. It is covered by the external capsule, beyond which there are the claustrum and the white and grey matter of insula.

Medial surface—angled rather than merely convex—is closely related to the internal capsule and covers the whole of its lateral surface. The capsule separates: (1) The angle from the stria semicircularis; (2) the part in front of the angle from the head of caudate nucleus; and (3) the part behind the angle from the thalamus. The part of the surface formed by the putamen is fused antero-inferiorly with the head of the caudate nucleus, and elsewhere is connected with the head, body, and tail of the caudate nucleus by grey laminæ that pass through the capsule and the base of the corona radiata.

Upper border is convex, and is situated just below a large bundle of fibres, called *superior longitudinal fasciculus*, which lies on the lateral surface of the base of the corona radiata.

Inferior surface—bi-convex in outline and nearly flat—does not reach the fused, anterior end. A deep groove (which lodges the anterior commissure) runs backwards and sidewards across it from the anterior part of its medial margin. Optic tract lies across the junction of the internal capsule and basis pedunculi, and is therefore immediately below the medial margin. The anterior part of the inferior surface is fused with the anterior perforated substance. Posterior part lies above the roof of the inferior horn. It is fused with part of the amygdaloid nucleus, but is separated from the rest of it and from the other structures in the roof of the horn (stria semicircularis and the tail of caudate nucleus) by white matter which contains the spreading fibres of the anterior commissure and the temporal radiation (p. 497).

Arteries.—Corpus striatum is supplied by branches of the anterior and middle cerebral arteries and the anterior choroid artery. Striate branches of the middle cerebral ascend through the anterior perforated substance, reach the lentiform nucleus, pass upwards over the lower part of its lateral surface (grooving it and diverging from one another), sink into it, traverse it and the internal capsule to reach the caudate nucleus. One of the **most anterior** of those arteries is the largest of the group, and is called "the artery of cerebral hæmorrhage".

Connexions.—Corpus striatum is a centre associated with the regulation of muscular tone and the control of automatic movements. It is a very old part of the hemisphere, and globus pallidus is the oldest part of it. Caudate nucleus and putamen receive fibres from the motor cortex, and send fibres into globus pallidus, whence other fibres descend to subthalamic nucleus (p. 506), to red nucleus (p. 510) to olivary nucleus (p. 528), and to the grey matter of dorsal part of the whole brain-stem. A reflex mechanism is completed by sensory fibres from thalamus to caudate nucleus and to globus pallidus, and from substantia nigra to globus pallidus.

Amygdaloid Nucleus.—A collection of grey matter—about the size of a bean in the anterior part of the roof of the inferior horn. It bulges down into its cavity above the pes hippocampi. Continuous with lentiform nucleus, tail of caudate nucleus, anterior perforated substance and grey matter of uncus.

Stria Semicircularis.—A slender band of fibres that begins in the amygdaloid nucleus. Runs backwards in the roof of the inferior

horn along the medial edge of the tail of the caudate nucleus ; curves upwards, immediately lateral to the posterior end of thalamus, to enter the central part of the ventricle ; runs forwards between the thalamus and caudate nucleus to join the anterior column of fornix ; thence, its fibres descend in front of and behind anterior commissure (giving some fibres to the commissure) ; and they end in the anterior perforated substance.

Covered with ependyma and overlapped by the thalamo-striate vein ; deep surface is related to the internal capsule at its junction with the corona radiata.

Claustrum.—A thin, grey plate that lies between the white matter of insula and the external capsule. Thickens towards its lower edge, which is continuous with the anterior perforated substance.

EXTERNAL AND INTERNAL CAPSULES

External Capsule.—Thin, white sheet between the claustrum and the putamen of lentiform nucleus. Merges, at its periphery, into the rest of the white substance of hemisphere. Consists of association fibres (p. 498) mingled with some fibres of the anterior commissure and of ansa lenticularis (p. 504).

Internal Capsule.—A broad, thick, fan-shaped lamina of white matter. Occupies the interval that separates the lentiform nucleus from the thalamus and the head of caudate nucleus. Nearly all the fibres that connect the cortex with the parts beneath are compactly gathered together in the capsule.

Lower end, narrow, is continuous with the basis pedunculi under cover of the optic tract. **Upper end**—wide, arched and curved—is continuous with the corona radiata at the ends and upper margin of the lentiform nucleus.

In horizontal sections, the capsule has an angled contour, for it is bent or moulded on the medial surface of the lentiform nucleus. **Genu** of internal capsule is the bend or angle, and lies between the lentiform nucleus and stria semicircularis. **Anterior limb** of internal capsule is the part in front of the genu ; it lies between the lentiform nucleus and the head of caudate nucleus. The part behind the genu is the **posterior limb**, and lies on the lateral surface of the thalamus ; it is divisible into a *lentiform portion* (between lentiform nucleus and thalamus) and a *retrolentiform portion* (behind and below the lentiform nucleus).

Chief Constituents.—Better known fibres are:—

1. **Cortico-pontine fibres** lie in all parts of the capsule. They are fibres which arise in various areas of cortex, descend through the corona radiata, internal capsule, and basis pedunculi, and end in the nuclei pontis.

2. **Motor fibres** (conveying voluntary impulses for the opposite half of the body) descend from the motor area (pre-central gyrus) to the motor nuclei of the brain-stem and spinal cord; they lie in the genu and in the lentiform portion of the posterior limb of the capsule, arranged in the following order from before backwards—head, upper limb, trunk, lower limb.

3. **Sensory fibres** (conveying ordinary sensory impulses from the opposite half of the body) ascend from the thalamus to the sensory area (post-central gyrus). They lie in the same order as the motor fibres, but since they issue from the thalamus, they are at first medial to the motor fibres.

4. **Auditory fibres** (which connect the lower centre for hearing with the higher centre in the superior temporal gyrus) and **Visual fibres** (which connect the lower centre for sight with the higher centre in the occipital lobe) lie in the retrolentiform portion of the capsule.

Arteries of internal capsule are derived from the anterior and middle cerebral, anterior choroid and posterior communicating. Most important are those derived from the middle cerebral, and they traverse lentiform nucleus. One of the most anterior of them is the "artery of cerebral hæmorrhage". When that artery ruptures, the blood-clot presses on the lateral surface of the anterior part of the capsule. The paralysis that results is less marked in the lower limb than in the upper, because the fibres for the lower limb are the farther back; and sensory paralysis is less marked than motor, because the sensory fibres are medial to the motor fibres.

Contents.—**Anterior limb** is greatly broken up by the grey laminæ that connect the putamen with the head of the caudate nucleus. It contains: (1) Fibres from thalamus to globus pallidus. (2) Fibres from thalamus to frontal cortex. (3) Fibres from the motor area to putamen and caudate nucleus. (4) Cortico-pontine fibres from the frontal cortex.

Genu and lentiform part of posterior limb contain: (1) Fibres to and from globus pallidus (p. 494). (2) Sensory fibres and (3) Motor fibres of opposite half of body. (4) Fibres from motor area to red nucleus. (5) Cortico-pontine fibres from frontal and parietal cortex.

Retrolentiform part contains: (1) Optic radiation. (2) Auditory

radiation. (3) Thalamo-temporal fasciculus, which connects the lateral geniculate body with the temporal cortex. (4) Cortico-pontine fibres from occipital and temporal cortex.

Temporal radiation is made up of the temporo-pontine fibres, the thalamo-temporal fasciculus and the auditory radiation as they pass below the lentiform nucleus, above the roof of the inferior horn.

Relations of Internal Capsule.—Lateral surface of internal capsule looks downwards as well as sidewards. It is concave antero-posteriorly to fit the lentiform nucleus, which covers the whole of it.

Medial surface looks upwards and medially, and is convex but uneven. Head of caudate nucleus lies on the part that belongs to the anterior limb of the capsule. Stria semicircularis lies on the maximum convexity or genu. Thalamus lies on the part that belongs to the posterior limb—which is divided into lentiform and retrolentiform portions.

Posterior border is thick, and very short—no longer than the width of stria semicircularis. The stria, bending round it from the inferior horn to the central part of the ventricle, therefore covers it.

Anterior border, traced upwards, changes direction from upwards to forwards so soon and so abruptly that nearly all of it is horizontal. It lies on ansa lenticularis, anterior commissure and the line of fusion of lentiform nucleus and head of caudate nucleus.

Lower end consists almost wholly of descending fibres, and is continuous with the basis pedunculi under cover of the optic tract.

Upper end is the wide end of an outspread fan, and is much longer than either of the borders. It is continuous with the corona radiata at the ends and upper border of the lentiform nucleus.

WHITE SUBSTANCE OF HEMISPHERE

Is made up of itinerant fibres, commissural fibres and association fibres all mingled together and held together by neuroglia.

Itinerant fibres (projection fibres) are the fibres that descend from the cerebral cortex to the parts beneath, and the fibres that ascend from these parts to the cortex. While they are scattered throughout the white substance they constitute the **corona radiata**; and they are congregated together in the **internal capsule.**

The fibres of the **corona radiata** partly converge upon the internal capsule from all areas of the cortex, and partly diverge from the capsule to reach different areas of the cortex. Near the upper end of the capsule, the fibres of the corona are collected together between the superior longitudinal fasciculus on the lateral side and the fronto-occipital fasciculus and caudate nucleus on the medial side. That part of corona is its **base.** Immediately above the base, the fibres of corona radiata (except those continuous with the retro-lentiform part of capsule) *intersect* the fibres of corpus callosum.

Commissural fibres are those that connect the cortex of one hemisphere with the cortex of the other. As they pass from one hemisphere to the other, they collect together to form the **corpus callosum** (p. 486) and the **anterior commissure.**

Anterior Commissure.—Connects anterior and inferior parts of one temporal lobe with corresponding parts of the other. A rounded cord, about the thickness of a wax-taper. Median part lies horizontally in the anterior wall of the third ventricle in front of the anterior columns of fornix. On each side it sinks into the hemisphere below the head of caudate nucleus, and runs sidewards and backwards, below the internal capsule and lentiform nucleus, into the temporal lobe to spread out and end in it.

Anterior commissure, as a whole, is bent like a Cupid's bow, but its ends spread out fanwise. It is twisted on itself, and that gives it the appearance of a spun cord.

Median part is in the anterior wall of the third ventricle, in front of the anterior columns of fornix, below recessus triangularis (p. 501) and above recessus opticus; therefore, between the columns, it is covered, above and below and behind, with the ependyma of the ventricle. Superiorly, it is also connected with the laminæ of the septum lucidum. Anteriorly, it is covered with the neuroglia that connects the lamina terminalis to the rostrum of corpus callosum.

Each **lateral part** is in the substance of the hemisphere. As a round compact bundle, it runs sidewards and slightly forwards below the head of caudate nucleus and the "anterior" border of internal capsule, and then sweeps sidewards and backwards in the groove on the lower surface of lentiform nucleus, and sinks into the white substance of the temporal lobe, where it spreads out like a fan. Anterior perforated substance, amygdaloid nucleus and temporal radiation are below it.

As the commissure crosses the anterior perforated substance, it sends forwards, through the substance, an *olfactory bundle* to join the lateral root of olfactory tract. Fibres of that bundle connect the olfactory bulb with the bulb and temporal lobe of the other side.

Association fibres are those that connect different areas of the cortex of the same hemisphere. They are far more numerous than itinerant and commissural fibres.

Short association fibres connect gyri that are near each other. They partly lie in the deeper layers of cortex, and partly arch round below the floors of the sulci; curving sheets of them are easily found if the grey lining of a sulcus is scraped away. **Long association fibres** connect gyri that are farther apart. They lie deeper, but do not attain the depths reached by itinerant fibres; and they

are collected into bundles that, throughout their whole course, send fibres into overlying gyri and receive fibres from the gyri.

Chief Bundles of Long Association Fibres.—Superior and inferior ongitudinal ; uncinate ; fronto-occipital ; cingulum.

Superior longitudinal fasciculus—about the thickness of a pencil—lies on the lateral surface of the base of corona radiata in the root of the fronto-parietal operculum. Begins in frontal lobe and arches backwards above the lentiform nucleus ; at the posterior end of the lateral sulcus, some of its fibres run backwards, under the floor of the intra-parietal sulcus into the occipital lobe, while most of them turn downwards and forwards into the temporal lobe.

Inferior longitudinal fasciculus—broad and flat—lies on the lateral side of the optic and temporal radiations ; it extends from occipital pole to temporal pole.

Fasciculus uncinatus—about half the thickness of a pencil—arches round the stem of the lateral sulcus, under cover of the (very thin) grey matter of the limen insulæ, and infero-lateral to the anterior part of the lentiform nucleus; its ends spread out in the lower part of frontal lobe and in the anterior part of temporal lobe.

Fronto-occipital fasciculus—little thicker than a match, but compressed sideways—lies immediately below the trunk of corpus callosum, between the caudate nucleus and the base of corona radiata. Anteriorly, it spreads out in the frontal lobe ; posteriorly, at the splenium, it joins the tapetum and radiates into the occipital and temporal lobes.

Cingulum—about the same thickness as the superior longitudinal fasciculus—lies in gyrus cinguli and the hypocampal gyrus. It begins at the anterior perforated substance, arches round the genu and lies on the trunk of corpus callosum in the gyrus cinguli, bends round the splenium in the substance of the isthmus, enters the hippocampal gyrus, and runs forwards in it to the uncus and the temporal pole.

Horizontal Section through Cerebral Hemisphere

The knife usually passes through both genu and splenium of corpus callosum. The structures to be looked for are :—

Cortex. White matter, showing droplets of blood where vessels have been cut.

Genu of corpus callosum, well forward in the section ; and **splenium,** a little behind the middle. Genu merges, antero-laterally, into the white substance. Lateral part of splenium merges, posteriorly, into the white substance, while, at the side, it bounds the commencement of the inferior and posterior horns of the ventricle.

Anterior columns of fornix, a little behind genu ; and lower part of **septum lucidum,** between columns and genu.

Thalamus—the large, grey area, triangular in outline, alongside

the median line, between anterior columns of fornix and splenium. If both hemispheres are cut—**third ventricle,** between thalami, and crossed by a grey band called the **interthalamic connexus ; pineal body,** behind the ventricle, between the posterior parts of the thalami and connected to them by a pair of ridges.

Head of caudate nucleus—a grey, semilunar mass a little farther forwards than thalamus and farther from median plane. The interval between it and genu of corpus callosum is the **anterior horn** of ventricle. **Internal capsule** is the bent, white band on the lateral side of caudate nucleus and thalamus ; anteriorly and posterolaterally it merges into the white substance. **Stria semicircularis** is cut in two places ; it is difficult to detect its cut ends ; one is on the medial side of the bend or **genu** of internal capsule, between thalamus and caudate nucleus ; the other is at the posterior part of internal capsule, immediately lateral to thalamus ; and the **tail of caudate nucleus**—very thin—is immediately lateral to the stria.

The opening behind internal capsule and lateral to splenium leads into the **posterior** and **inferior horns.** The elevation on the anteromedial boundary of the opening is the posterior part of **hippocampus** with the **fimbria** attached to it.

Lentiform nucleus is the large grey mass on the lateral side of internal capsule. If the brain is fairly fresh, there is a marked contrast in colour between **globus pallidus** and **putamen.**

Note that lentiform nucleus does not reach so far back as thalamus does, and that, therefore, part of internal capsule is *retrolentiform.* **External capsule** is the white stripe lateral to lentiform nucleus ; anteriorly and posteriorly it blends with internal capsule. **Claustrum** is the grey stripe between external capsule and the white matter of the insula.

THIRD VENTRICLE AND PARTS AROUND IT

Third Ventricle.—The cleft between the thalami. Crossed about its middle by a band of grey matter, called the **interthalamic connexus.**

Communicates anteriorly, on each side, with the lateral ventricle through the interventricular foramen ; and *posteriorly* with the fourth ventricle through the aqueduct.

It has a roof, a floor, anterior and posterior walls, and right and left side-walls.

Main part of each **side-wall** is the thalamus.

Anterior wall : free parts of the anterior columns of fornix ; anterior commissure, crossing in front of them ; lamina terminalis, stretching down from the commissure to the optic chiasma.

Floor: from before backwards—optic chiasma; tuber cinereum; mamillary bodies; posterior perforated substance; and the tegmenta of mid-brain as they separate from each other to become continuous with the thalami.

Posterior wall: from below upwards—upper end of aqueduct; posterior commissure; base of pineal body.

Roof: merely ependyma, covered with the tela chorioidea of third ventricle, and body of fornix above the tela.

It is only the anterior two-thirds of the medial surface of the thalamus that appears in the ventricle and it forms little more than the postero-superior half of the side-wall. The antero-inferior half is formed by the side-wall of the tuber cinereum (which is hollow), by the grey matter around the concealed part of anterior column of fornix, and by the tegmental subthalamic region (p. 506). The two parts or halves are separated by a groove called the **hypothalamic sulcus,** which runs along the side-wall of the ventricle from the interventricular foramen to the opening of the aqueduct.

The *interthalamic connexus* is usually of appreciable length; but in some brains it is so short and thick that the middle parts of the two thalami cohere.

Recesses of Third Ventricle.—**Pineal recess** is a pointed extension backwards into the base of the pineal body. **Suprapineal recess** is an ependymal evagination backwards above the base of the pineal body into a pocket of the lower layer of the tela chorioidea. **Infundibular recess** is the continuation of the cavity of tuber cinereum downwards into the infundibulum. **Optic recess** is an angular interval between the lamina terminalis and the antero-superior surface of chiasma. **Triangular recess** is a little space above the anterior commissure, between the anterior columns of fornix; it is bounded in front by the neuroglia that unites the edges of the laminæ of septum lucidum at their attachment to the columns and commissure.

Thalamus.—A great sensory relay-station. Receives sensory impulses from the other half of the body by fibres that ascend to it; and it transmits most of these impulses to the sensory area of the cortex (post-central gyrus and paracentral lobule) by fibres that ascend in the internal capsule and corona radiata.

It is a large, ovoid mass of grey matter, about an inch and a half long. It lies above the mid-brain, in the side-wall of the third ventricle and in the floor of the central part of the lateral ventricle.

It has an anterior and a posterior end and four surfaces —superior, inferior, lateral, medial.

Anterior end—small and rounded and free—forms the posterior boundary of interventricular foramen.

Posterior end is called the **pulvinar.** It is wide, like a border; and is horizontal and free. It juts backwards (especially medially, where it overhangs the side of mid-brain) and therefore has a free inferior aspect.

Superior surface of thalamus is divided into two parts. *Medial part* includes nearly the whole of the posterior end; it is covered with the tela chorioidea, which separates it from the body of fornix. *Lateral part* includes the anterior end; it is free in the floor of the central part of lateral ventricle; it is covered therefore with ependyma, but is also overlapped by the edge of the tela containing the choroid plexus of lateral ventricle. *Lateral margin* of the upper surface is related to the thalamo-striate vein and stria semicircularis, which separate it from the body of caudate nucleus. *Medial margin* is a free border along which the stria habenularis runs—forming a ridge.

Medial surface is a free surface, most of which lies in the side-wall of third ventricle, and is connected with the other thalamus by the interthalamic connexus. The portion in the ventricle is covered with ependyma, except at the attachment of the connexus.

Lateral surface is closely applied to the internal capsule, and is therefore seen only in sections.

Inferior surface, in its anterior and larger part, is fused with a mass of grey and white matter, called the sub-thalamic region, which connects it with the tegmentum of mid-brain; therefore it can be seen only in vertical sections. But the posterior part of the inferior surface is free, for it is the inferior aspect of the pulvinar.

Geniculate Bodies.—Lateral geniculate body is an indistinct, oval elevation on the most lateral part of the inferior aspect of the pulvinar. It is the principal lower centre for **sight.**

Medial geniculate body is the principal lower centre for **hearing.** It lies half an inch medial to the lateral body, and is closely connected with the mid-brain. It is a distinct, oval elevation, about the size of a barley-corn, under shelter of the pulvinar, at the upper end of the shallow groove on the side of the mid-brain.

The student should take some pains to find the geniculate bodies at this stage in order to be able to identify them without hesitation later.

To Find the Geniculate Bodies.—Place the brain upside

down; take away the hind-brain by a horizontal cut through the mid-brain (if that has not been done already); pull the uncus aside to expose the optic tract; and trace the edges of the tract backwards. The lateral edge ends at the lateral geniculate body, and the medial edge at the medial body.

Lateral geniculate body consists of alternate layers of grey and white matter. Receives fibres from the optic tract. Sends fibres, *via* the internal capsule and optic radiation, to the higher centre for sight in the occipital cortex. Is connected with the mid-brain by fibres of a bundle, called the **superior brachium quadrigeminum,** which extends from the lateral geniculate body to the superior corpus quadrigeminum, and is largely hidden in the groove between the pulvinar and medial geniculate body.

Medial geniculate body is separated from the pulvinar by the superior brachium. Consists of two nuclei enclosed in white matter. The nuclei receive fibres from the lateral lemniscus (p. 537) and fibres from the inferior corpus quadrigeminum through a bundle or ridge, called the **inferior brachium quadrigeminum,** which lies obliquely in the side of mid-brain between the inferior corpus and the medial geniculate body. The nuclei send fibres, *via* the internal capsule and auditory radiation, to the higher centre for hearing in the superior temporal gyrus; and they are connected with the medial geniculate body (and possibly inferior corpus quadrigeminum also) of the other side by fibres which form the medial root of optic tract.

CHARACTERS AND STRUCTURE OF THALAMUS.—Anterior end, small and rounded, is fairly close to the median plane. The part of the upper surface near it sometimes bulges to form a prominence called the **anterior tubercle.** The **pulvinar** is some distance from its fellow. Medial angle of pulvinar is prominent; and the free end or border, as it extends sidewards from that angle, slopes slightly forwards.

Superior surface of thalamus has a coating of white matter. Its lateral and medial parts are clearly defined, in well-hardened specimens, by an oblique groove that corresponds to the edge of the fornix. The habenular stria raises a ridge of ependyma along the anterior two-thirds of the medial margin of the surface.

Only a part of the **medial surface** (anterior two-thirds) is in the side-wall of the third ventricle. The posterior third is behind the plane of the ventricle, opposite the pineal body; it belongs largely to the pulvinar and becomes narrower as it approaches the medial angle of pulvinar. Ventricular part of the surface is limited inferiorly by a narrow, shallow groove, called the **hypothalamic sulcus,** which extends from the interventricular foramen to the aqueduct, and separates the medial surface of thalamus from the medial surface of the subthalamic region.

Subthalamic region consists of a quantity of grey and white matter which is fused with the **inferior surface** of thalamus and separates the thalamus from the tegmentum of mid-brain and also from one mamillary body and one half of the tuber cinereum.

A vertical sheet of white matter divides the posterior, larger part of thalamus into a **lateral nucleus** and a **medial nucleus** ; it splits anteriorly to enclose the rest, which is called the **anterior nucleus.** Thalamus is a very old part of cerebrum ; its oldest part comprises the anterior and medial nuclei.

CONNEXIONS OF THALAMUS.—Fibres connect thalamus with all parts of central nervous system.

Afferent Fibres.—Tracts of fibres that convey *ordinary sensory* impulses reach it from the spinal cord and brain-stem. *Visual* fibres end in the lateral geniculate body—which is part of it. *Olfactory* impressions are conveyed to it from the mamillary body by the mamillo-thalamic fasciculus. Fibres from the cortex descend in the corona radiata and internal capsule to it. Ansa lenticularis carries fibres to it from the lentiform nucleus.

Efferent Fibres.—Outgoing fibres pass to the corpus striatum—some of them directly through internal capsule, and some *via* ansa lenticularis. Other fibres form the ansa peduncularis, which connects the thalamus with the cortex of the insula and adjoining part of temporal lobe. And large numbers stream out of the lateral surface of thalamus into the internal capsule, and thence to the cortical sensory area—and, indeed, to all parts of the cortex ; they include a large group that connects the pulvinar with the middle part of the inferior parietal lobule.

Ansa peduncularis is a flat band of fibres that arises in the medial nucleus of thalamus. It runs at first horizontally forwards across the medial side of the mamillo-thalamic fasciculus, and then inclines downwards through the subthalamic region, on the lateral side of the anterior column of fornix, to reach the anterior perforated substance, through which it runs sidewards, below the "anterior" border of the internal capsule and below the lentiform nucleus, to end in the insula and temporal lobe.

Ansa lenticularis is a slender band that lies in the perforated substance above the ansa peduncularis. It is made of fibres that pass from lentiform nucleus to thalamus, from thalamus to globus pallidus, and from globus pallidus to subthalamic and red nuclei.

Posterior Commissure.—A slender band. Lies transversely in the posterior wall of the third ventricle below the pineal body, above the opening of the aqueduct. Connects the right and left corpora quadrigemina and medial longitudinal bundles.

Pineal Body.—About the size of a barley-corn ; conical in shape, with base directed forwards. Lies in the groove between superior corpora quadrigemina, enveloped in lower layer of tela chorioidea, below great cerebral vein and splenium of corpus callosum.

Base is connected with a hollow **stalk** which is divided into two laminæ. *Inferior lamina* curves downwards, round the front of the posterior commissure, into the grey matter around the aqueduct. *Superior lamina* splits into a right and a left half. Each half is called a **habenula,** and runs into the medial margin of the thalamus.

Trigonum Habenulæ.—A triangular depression bounded by the stalk of pineal body, pulvinar and superior corpus quadrigeminum. Grey matter in its floor is the **nucleus habenulæ.** A slender bundle,

called **fasciculus retroflexus,** arises in the habenular nucleus and descends through the tegmentum of mid-brain to end in a median collection of cells, called the *interpeduncular nucleus,* which lies in the posterior perforated substance.

Stria Habenularis.—A band of fibres that runs in an ependymal ridge along the medial margin of thalamus. *Traced backwards,* some of its fibres end in the nucleus habenulæ of its own side, and others cross in the upper lamina of pineal body (forming the **habenular commissure**) to end in the opposite nucleus. *Traced forwards,* the fibres join the anterior column of fornix. From there, some of them are carried backwards in the fornix to the hippocampus, and others descend in the column to the base of the brain and end in the anterior perforated substance close to the optic tract.

Tuber Cinereum.—A hollow eminence of grey matter between the optic chiasma and the mamillary bodies; seen both in third ventricle and in base of brain. Antero-inferiorly, it is continued as a funnel-shaped prolongation of grey matter, called the **infundibulum,** whose upper part also is hollow. Infundibulum descends through the hole in diaphragma sellæ and joins the hypophysis.

Hypophysis Cerebri.—*See* p. 56.

Tuber cinereum is connected by grey matter with surrounding parts: *Superiorly,* on each side, with the grey matter around the anterior column of fornix in the side-wall of the third ventricle; *posteriorly,* between and above the medial parts of the mamillary bodies, with the posterior perforated substance; *laterally,* above the optic tract, with the anterior perforated substance; and *anteriorly,* over the chiasma, with the lamina terminalis.

Lamina Terminalis.—A thin plate of grey matter that separates the ependyma of the third ventricle from the part of the longitudinal fissure situated above and in front of the chiasma. It is the remains of the original anterior wall of the anterior cerebral vesicle. *Superiorly,* it is connected by neuroglia with the lower edge of the rostrum of corpus callosum and with the front of the anterior commissure. *Inferiorly,* it reaches the chiasma near its lower edge and is reflected upwards over the front of the chiasma to be continuous with the tuber cinereum. *Laterally,* it is continuous with the paraterminal gyrus.

Mamillary Bodies.—A pair of pea-like bodies, each consisting of a central nucleus enclosed in white matter. Lie side by side in base of brain, behind tuber cinereum, between the two optic tracts.

Posteriorly, they are related to the posterior perforated substance. A number of fibres that pass to and fro between them and the tegmenta of mid-brain form a pair of bundles called the **mamillo-tegmental tracts**; each tract runs backwards in the perforated substance, and then downwards in the tegmentum.

Superiorly, the medial parts of the mamillary bodies are separated by a thin layer of grey and white matter from the ependyma of the floor of the third ventricle, while the lateral part of each is separated

by grey matter from the anterior part of lower surface of thalamus, and is connected with two large bundles of fibres—the anterior column of fornix and the mamillo-thalamic fasciculus.

Anterior column of fornix runs downwards and backwards in the side-wall of the third ventricle to reach the mamillary body, and its fibres end in the central nucleus. **Mamillo-thalamic fasciculus** is the same thickness as the column. It arises in the nucleus, and ascends to end in the anterior nucleus of thalamus. In a naked-eye dissection, the fibres of the fasciculus and of the column appear to be continuous and to loop round the nucleus like the lower loop of a figure 8.

Posterior Perforated Substance.—A plate of grey matter of triangular outline with the base forwards. Set behind the mamillary bodies in the interpeduncular fossa between the pia mater of that fossa and the ependyma of the third ventricle. On each side, it is continuous with the tegmentum of mid-brain; anteriorly, the grey matter above the mamillary bodies connects it with the tuber cinereum. In its centre, there is a circumscribed collection of cells called **interpeduncular nucleus.** In some brains, one or more slender white bundles, called **taeniæ pontis,** emerge from its substance, curve backwards round the basis pedunculi near the pons, sink into the cerebellum between its superior and middle peduncles, and end in the dentate nucleus.

Tegmental Subthalamic Region.—Consists of the substantia nigra and the tegmentum of mid-brain from the level where the tegmentum separates from its fellow till it reaches the thalamus. It contains the subthalamic nucleus, the uppermost parts of substantia nigra and red nucleus and various bundles of fibres that connect the thalamus and corpus striatum with the parts below, the largest of which is the medial lemniscus.

Subthalamic nucleus is a lens-like, brownish nucleus encapsuled in fibres. Lies close to the deep surface of the basis pedunculi immediately below the lateral part of thalamus. Receives fibres from the thalamus; and, being a subordinate automatic centre for the control of movements, it receives fibres (*via* ansa lenticularis) from globus pallidus, and sends fibres to the substantia nigra and to the tegmentum. Connected with its fellow by fibres that curve through the tegmenta and posterior perforated substance.

MID-BRAIN OR MESENCEPHALON

The student will fail to understand the important nerve-pathways between the cerebrum and the parts below unless he carefully studies the naked-eye connexions of the mid-brain.

Mid-brain is a short, thick isthmus that lies in the notch of the tentorium. It is the uppermost part of the brain-stem, and it connects the cerebrum with the cerebellum and pons. About an inch in length, and rather more in width.

Its *anterior surface* is visible in the base of the brain,

though, in a brain hardened *in situ*, it is largely concealed by the bulge of the pons, for in such a brain the mid-brain retains its vertical position. *Posteriorly*, it is hidden by the cerebellum. *On each side*, it is overlapped and hidden by the hippocampal gyrus. *Superiorly*, it divides to sink into the two halves of cerebrum. *Inferiorly*, the most of it sinks into the pons, but part of it is connected with the cerebellum.

It is divisible into a small posterior part called the **tectum** and a large anterior part divided into a pair of **cerebral peduncles.** Peduncles are partly joined together, and enclose a narrow, median channel, called the **aqueduct,** which tunnels the mid-brain lengthwise and connects the third ventricle with the fourth.

Tectum.—A plate of grey and white matter heaped up into four rounded eminences situated *on the back* of the mid-brain and called the **corpora quadrigemina**—a superior pair and an inferior pair.

Superior corpora quadrigemina lie in the space between the two pulvinars, overhung by the splenium; pineal body lies in the groove between them. They are **reflex centres for sight.** From each of them, a band or ridge of fibres, called the **superior brachium quadrigeminum,** stretches forwards and sidewards, above the medial geniculate body, to join the lateral root of optic tract and the lateral geniculate body. The brachium is at the surface, but is largely hidden in the groove between the medial geniculate body and the pulvinar. (The brain in use has probably been divided by a cut across the mid-brain. Look for the brachium in the cerebral part turned upside down.)

Inferior corpora quadrigemina lie in a concavity in the front of the cerebellum (called its anterior notch); pull back the margins of the notch to expose them fully. They are **reflex centres for hearing.** From each of them, a well-defined, rounded ridge, called the **inferior brachium quadrigeminum,** runs forwards, upwards and sidewards, in the side of the mid-brain, to the medial geniculate body. Inferior brachium is thicker and more evident than the superior brachium; but it has been divided by the cut across the mid-brain.

Cerebral Peduncles.—Each comprises basis pedunculi in front, tegmentum behind, and substantia nigra—a lamina of dark-coloured grey matter—between them.

Tegmentum.—A thick column of grey and white matter mixed, united to its fellow. In the midst of each there is a rod of grey matter, called the **red nucleus,** seen in cross-section as a reddish, circular patch about a quarter of an inch in diameter.

Posteriorly, the tegmentum is continuous with the tectum. *Anteriorly,* its larger part is in contact with substantia nigra, but a small portion, medially, appears in the interpeduncular fossa.

Lateral surface is free, and is overlapped by the cerebellum; the inferior brachium lies at the surface in its upper part; below that, its superficial constituent is a wide, short sheet of obliquely directed fibres, called the **lateral lemniscus,** which can be exposed if the cerebellum is pulled away and the surface-neuroglia scraped off the side of the mid-brain.

In the median plane, the tegmentum is continuous with its fellow. In their junction, near the tectum, there is the **aqueduct,** surrounded by a thick-walled tube of grey matter. The upper end of that **central grey matter** is continuous with the grey matter of floor and side-walls of the third ventricle; the lower end is continuous with the grey matter of the floor of the fourth ventricle. It contains the nuclei of the oculomotor and trochlear nerves and of the mesencephalic root of the trigeminal nerve; and in close relation to the front of it there is a pair of small, compact bundles—the *right* and *left medial longitudinal fasciculi*—whose fibres are connected with these nuclei.

Superiorly, the two tegmenta separate, and each is continued upwards as the subthalamic tegmental region to be continuous with the lower surface of the thalamus.

Inferiorly, the united tegmenta are continuous with the dorsal division of pons; and they are connected also with the cerebellum by a pair of large bundles of fibres called the *superior cerebellar peduncles.* Pull back the part of the cerebellum that overlaps the back of the mid-brain. The peduncles can then be seen. They appear as a pair of thick, rounded ridges that proceed upwards from the interior of the cerebellum and disappear under cover of the inferior corpora quadrigemina.

Basis pedunculi is the part of the peduncle seen in the base of the brain, and is quite separated from its fellow

by the interpeduncular fossa. It is composed wholly of white matter, its components being the motor fibres and cortico-pontine fibres continued down from the internal capsule. Its bundles of fibres are slightly twisted, and it resembles a flattened piece of thick rope.

Superiorly, each is continuous with internal capsule.

Inferiorly, it sinks into the ventral division of pons; as it descends, it narrows slightly, and approaches its fellow till, at the pons, the bases are close together.

The *deep surface* is separated from the tegmentum by the substantia nigra.

The *superficial surface* is overlapped and partly hidden by the uncus. Optic tract crosses its uppermost part, where it is continuous with the internal capsule. Lower down, the trochlear nerve curves forwards across it; and the basal vein and posterior cerebral and superior cerebellar arteries curve backwards.

Postero-laterally, it is bounded by a wide, shallow groove called **lateral sulcus** of mid-brain; upper end of groove lodges medial geniculate body; lower end is continuous with the groove (between superior and middle cerebellar peduncles) out of which the lateral lemniscus issues.

Medially, the basis is a boundary of the interpeduncular fossa, and is separated from tegmentum by a narrow, shallow **medial sulcus**, out of which the roots of the oculomotor nerve issue.

Arteries of mid-brain come from posterior communicating, posterior cerebral, and anterior choroidal. **Veins** end in the basal vein and great cerebral vein.

CONTENTS AND CONNEXIONS OF MID-BRAIN.—**Superior corpus quadrigeminum** consists of: (1) a white layer on the surface covering (2) a grey cap, and then (3) two strata of mixed white and grey matter.

It *receives*:—1. Fibres from optic tract through sup. brachium.

2. Fibres from the centre for sight in occipital cortex; they run in the optic radiation to the posterior part of internal capsule, and thence, under cover of lat. geniculate body, into sup. brachium.

3. Fibres from its fellow. 4. Fibres from substantia nigra.

5. Fibres that pass to it from basis pedunculi of the opposite side.

6. Fibres from spinal cord and brain-stem through the spino-tectal tract and the medial lemniscus.

It *sends*:—1. Fibres to substantia nigra.

2. Fibres into medial longitudinal fasciculus.

3. Tecto-bulbar and tecto-spinal tracts to motor nuclei in the brain-stem and spinal cord—chiefly of opposite side.

Superior brachium quadrigeminum is composed :—

1. Chiefly of fibres of the optic radiation on their way to superior corpus quadrigeminum and fibres of optic tract on their way to the nucleus of oculomotor nerve and to superior corpus quadrigeminum.

2. Fibres that connect that corpus with the lateral geniculate body.

Inferior corpus quadrigeminum consists of a nucleus enclosed in white matter.

It *receives* :—1. Fibres from both lateral lemnisci—chiefly from the lemniscus of the same side.

2. Fibres from the centre for hearing in temporal cortex ; they run in auditory radiation to posterior part of int. capsule, and thence, under cover of medial geniculate body, into inferior brachium.

It *sends* :—1. Fibres, *via* inferior brachium, to the medial geniculate body and to the thalamus.

2. Fibres to the motor nuclei of cranial nerves.

Inferior brachium quadrigeminum is composed of :—1. Fibres of ateral lemniscus on their way to medial geniculate body.

2. Fibres from inferior corpus quadrigeminum to medial geniculate body and to thalamus.

3. Fibres of auditory radiation to inferior corpus quadrigeminum.

Substantia nigra extends from the pons upwards into the subthalamic region, and from the lateral sulcus of the mid-brain to the medial sulcus, where its medial edge is pierced by the roots of the oculomotor nerve.

Substantia nigra is an important centre for the automatic regulation of muscular tone and of rhythmic and skilled movements ; its afferent and efferent fibres connect it with almost all parts of the central nervous system, especially globus pallidus, subthalamic nucleus, and red nucleus.

White matter of **tegmentum** includes numerous groups of fibres—some scattered and some in compact bundles—most of which convey ascending impulses.

Grey matter includes :—1. Scattered groups of cells among the white matter.

2. Grey matter around aqueduct. 3. Red nucleus.

Red nucleus is situated in the upper half of tegmentum and in the subthalamic region. It is encapsuled by fibres of the opposite superior cerebellar peduncle (which crosses in the lower half of tegmentum) ; and it is pierced by the roots of the oculomotor nerve.

It is a motor nucleus concerned with automatic skilled movements and the automatic regulation of muscular tone by which equilibrium is maintained.

It *receives* :—1. Fibres from the opposite dentate nucleus through the superior peduncle.

2. Fibres from cerebral cortex through corona radiata and internal capsule.

3. Fibres from globus pallidus.

It *sends* :—1. Fibres to cerebral cortex, thalamus, and grey matter in the brain-stem.

2. Rubro-spinal tract to motor nuclei of other half of spinal cord.

The groups of fibres of tegmentum are dealt with elsewhere :—Medial longitudinal bundle (p. 530) ; superior cerebellar peduncle

(pp. 508, 517); lateral and medial lemnisci (pp. 537, 553); spino-tectal and spino-thalamic fibres (pp. 551, 552); tecto-bulbar and tecto-spinal fibres (pp. 509, 548); rubro-spinal tract (p. 549); pallido-rubro-olivary tract (p. 528); fasciculus retroflexus (p. 505); roots of oculomotor and trochlear nerves and mesencephalic root of trigeminal.

Basis pedunculi is composed of :—1. Motor fibres from the cerebral cortex on their way to the motor nuclei of the opposite half of the brain-stem and spinal cord.

2. Cortico-pontine fibres on their way to nuclei pontis.

3. A bundle of the medial lemniscus in its medial margin.

Its superficial surface looks forwards and sidewards. Owing to its obliquity, its medial edge is continuous with the anterior part of the internal capsule and its lateral edge with the posterior part. Therefore, cortico-pontine fibres from the anterior part of the cerebrum occupy the medial fifth of the basis; those from the posterior and inferior parts are in the lateral fifth; the motor fibres occupy the intermediate three-fifths, and are arranged in the following order medio-laterally—head, upper limb, trunk, lower limb.

NUCLEI OF NERVES AND THEIR CONNEXIONS.—Nerves associated with the mid-brain are the oculomotor, trochlear, and the mesencephalic part of trigeminal.

Oculomotor nucleus is a multiple group of cells in the anterior part of the grey matter around the aqueduct at the level of superior corpus quadrigeminum, and it is partly united to its fellow.

From the nucleus, the **root-fibres** arch forwards through medial longitudinal fasciculus, through red nucleus and through the medial edge of substantia nigra; and they emerge through the floor of the medial sulcus of the mid-brain.

Communications.—Motor fibres from the lower part of the opposite motor area are sent to the nucleus by the opposite basis pedunculi.

To enable the two eyes to move in harmony: (1) nucleus is connected with trochlear and abducent nuclei by fibres of medial longitudinal fasciculus; (2) the fibres for obliquus inferior and rectus inferior and medialis arise from both oculomotor nuclei; (3) those for medialis are joined in the nucleus by fibres that ascend in medial longitudinal fasciculus from the abducent nucleus of the other side.

To associate movements of eyelids and eyebrow with movements of accommodation: the nucleus sends fibres, *via* medial longitudinal fasciculus, to the facial nerve to be distributed to orbicularis oculi and the frontal belly of occipito-frontalis.

For visuo-motor reflexes, the nucleus receives fibres from superior corpus quadrigeminum, and, *via* superior brachium, from the retina and the occipital visual centre.

To enable the eye to share in equilibration: the nucleus is connected with the cerebellum by fibres of the superior cerebellar peduncle, and with vestibular nuclei (and other sensory nuclei) by fibres of the medial longitudinal fasciculus.

Trochlear nucleus is a small group of cells in the anterior part of the grey matter of the aqueduct, opposite the upper part of inferior corpus quadrigeminum.

The **root-fibres** first curve backwards, then bend downwards, and finally turn sharply medially into the superior medullary velum (p. 516), *where they cross the median plane*, decussating with their fellows; they emerge through the upper part of the velum close to the opposite superior cerebellar peduncle.

Communications are similar to those of the oculomotor nucleus, but no fibres are sent to the facial nerve.

Mesencephalic nucleus of trigeminal is a long slender nucleus that lies in the lateral part of the grey matter of the aqueduct. The mesencephalic root descends along the medial side of the superior cerebellar peduncle into the pons (p. 531).

Optic Tract

Is a white band that begins at the chiasma, runs backwards and sidewards, first along the side of the tuber cinereum, and then across the upper end of the basis pedunculi, to end, near the geniculate bodies, by dividing into a lateral and a medial root, which pass into the lateral and medial geniculate bodies.

Lateral root contains all the visual fibres of the tract. Its fibres do not all end in the lateral geniculate body: a few run on in superior brachium quadrigeminum to the mid-brain and end in the superior corpus quadrigeminum and in the nucleus of the oculomotor nerve.

Traced forwards, the larger half of the fibres of the lateral root run into the optic nerve of the same side; the others cross in the chiasma to reach the other optic nerve.

Medial root consists of commissural fibres that connect the right and left medial geniculate bodies. Fibres arise in one medial geniculate body, run forwards in the tract, cross in the chiasma, run backwards in the tract and medial root of the other side, and end in medial geniculate body of that side (and possibly also, *via* inferior brachium, in inferior corpus quadrigeminum).

Relations.—First part of optic tract is rounded, and is visible in the base of the undissected brain. It separates the tuber cinereum and interpeduncular fossa from the anterior perforated substance and vallecula cerebri; its upper surface is in contact with the grey matter that connects the tuber with the perforated substance; its lower surface is some distance above cavernous sinus, and is crossed by the posterior communicating artery.

Second part is flattened, and is overlapped and hidden by the uncus. It clasps the basis pedunculi at the junction with the internal capsule. It lies just a little below the lentiform nucleus; and its

end is a little medial to the end of stria semicircularis in the roof of the inferior horn of the lateral ventricle.

PATH OF CONDUCTION OF LIGHT.—Visual nerve-fibres arise in the eyeball from the nerve-cells of the **retina,** and are carried in the **optic nerve** to the optic chiasma. At the **chiasma,** the fibres from the lateral (and larger) half of the retina run into the **optic tract** of the same side ; the fibres from the medial half cross in the chiasma and run into the other tract ; therefore, the right tract contains the fibres from the right halves of both retinæ, and the left from the left halves. The visual fibres of each tract are carried by its **lateral root** to the **lateral geniculate body,** in which nearly all of them end.

Fibres of the **second relay** arise in the **lateral geniculate body** and enter the most posterior part of internal capsule, whence they are carried in the **optic radiation** to the centre for sight in **occipital cortex.**

Injury to *optic nerve* = blindness of that eye ; to *chiasma* = blindness of medial half of each eye ; to one *optic tract* (say the *right*) = blindness of right half of each eye. The student can work out for himself the different effects on the field of vision.

Some of the fibres that cross in the chiasma make a bend forwards in the optic nerve before they enter the tract ; injury of the optic nerve near the chiasma may therefore implicate the medial half of the other retina.

A few, very slender fibres run from the geniculate body to the retina.

Optic radiation is a broad sheet of fibres in the white substance of the occipital lobe, with the inferior longitudinal bundle on its lateral side and the tapetum on its medial side—the tapetum separating it from the ependyma of the posterior and inferior horns of the lateral ventricle. *Traced backwards,* it spreads out to end in the cortex of the medial and lateral surfaces of the occipital lobe. *Traced forwards,* its bundles gather together to enter the retrolentiform part of the internal capsule.

It consists of fibres :—1. From lateral geniculate body to occipital cortex.

2. From occipital cortex to lateral geniculate body, pulvinar, and superior corpus quadrigeminum (from which relays are sent to oculomotor nuclei).

CEREBELLUM

Is the central organ for co-ordination of movements and maintenance of equilibrium ; it exercises its influence largely by regulating muscular tone.

Position.—In posterior cranial fossa, behind brain-stem, below tentorium cerebelli ; tentorium separates it from the occipital lobes, and, being tense, keeps the weight of the cerebrum off it. In relation to the surface of the head, the greater part of it is below a line drawn from the inion to the upper part of root of auricle.

Size and Connexions.—Forms about an eighth of the bulk of the adult brain, and one-twentieth in an infant. Measures more from side to side than from before backwards ; and its vertical measurement is far more in front than behind.

Connected with all three parts of the brain-stem—with mid-brain, by superior cerebellar peduncles ; with pons, by the middle peduncles ; with medulla oblongata, by the inferior peduncles.

Hemispheres, Vermis, and Notches.—It is divisible into a pair of **hemispheres** united by a thick, median portion called the **vermis.** Vermis is shorter than the hemispheres, leaving **notches** between them in front and behind. **Posterior notch,** short and narrow, is occupied by falx cerebelli when the brain is in the skull. **Anterior notch** is a long, wide groove occupied by the posterior parts of the brain-stem ; but, while the mid-brain is in close relation with cerebellum in the upper part of the notch, the pons and medulla oblongata are separated from the cerebellum by the cavity of the fourth ventricle.

Margin and Horizontal Fissure.—Circumferential margin curves from notch to notch ; it is at the level of the rim of the posterior cranial fossa, opposite the superior nuchal line. **Horizontal fissure** is the cleft that runs along or near the margin. Its anterior part widens to receive the middle cerebellar peduncle ; and, at the junction of the fissure and the anterior notch, the superior peduncle leaves the cerebellum, and the inferior peduncle enters it.

Surfaces.—Upper and lower, separated by the horizontal fissure. (Anterior part of the fissure is below the margin ; the most anterior part of the " upper " surface therefore actually looks downwards.)

Upper surface of hemisphere is sloping but even ; it is not marked off from vermis ; it slants upwards and medially into the upper surface of vermis, which forms a blunt, median ridge (usually called **superior vermis**) and rises to a height near the front. Greater part of superior vermis is related to the straight sinus, but its summit appears in the notch of the tentorium, behind and below the splenium of corpus callosum.

Pull back the anterior part of superior vermis and look for the lingula. **Lingula** is a thin, tongue-like, grey lamina,

about half an inch long, and ridged transversely. It lies between the superior peduncles (already seen, p. 508), and it lies on a very thin, white sheet called the **superior medullary velum**, with which it is fused.

Lower surface of hemisphere is uneven and rounded. Is related to the bony walls of the posterior cranial fossa and to the sigmoid sinus; is separated from its fellow by a deep, wide space called the **vallecula cerebelli.** Lower part of vermis (usually called **inferior vermis**) is wedge-shaped, and juts down into the vallecula; it is separated from each hemisphere by a deep, narrow groove called the **sulcus valleculæ.**

Antero-medial part of lower surface of hemisphere is a bulging prominence that resembles an enlarged tonsil and is called **tonsilla cerebelli**; its deeper part fits into a cup-shaped hollow (like a bird's nest) which is easily seen if the tonsil is pulled away. The semi-detached **flocculus** (seen already on base of brain) is the most anterior part of the lower surface, and is lateral to the anterior part of the tonsil. Its five or six small folia converge medially on a white ridge called its *stalk*. The flocculus lies on the lower surface of the middle peduncle immediately lateral to the 8th nerve and overlaps the nerve; and it is crossed by the 9th and 10th nerves on their way to the jugular foramen.

Arbor Vitæ.—Central white matter of cerebellum sends white sheets into the folia; and some folia give off secondary folia. Therefore, the cut surface of cerebellum, especially of vermis, has an arboraceous appearance to which the name **arbor vitæ** is given.

Dentate Nucleus and **Superior Cerebellar Peduncle** (*see also* pp. 516, 517):—

Dentate nucleus lies in the white substance of the medial part of the hemisphere. It is a corrugated lamina of grey matter, about the size of a thumb-nail, folded to resemble a bag with a wide mouth directed mainly forwards.

Superior cerebellar peduncle arises in the dentate nucleus, issues from its mouth, passes upwards out of the cerebellum on to the back of the pons and then into the mid-brain, crosses to the other side, and most of its fibres end in the red nucleus of that side.

Medullary Vela.—The white matter comes to the surface at the anterior notch between superior and

inferior vermis ; and part of it is projected out as two thin sheets, called *medullary vela*, which diverge upwards and downwards from each other and form a great part of the roof or posterior wall of the fourth ventricle.

Superior velum extends upwards and forwards between the superior peduncles ; trochlear nerves emerge through it. **Inferior velum** is much wider and thinner. It curves downwards, and its right and left halves end inferiorly in free, concave edges.

Vessels of Cerebellum—Arteries: Posterior inferior cerebellar (of vertebral) and anterior inferior cerebellar (of basilar) to *lower surface* ; superior cerebellar (of basilar) to *upper surface.*

Veins.—*Superior cerebellar* end in great cerebral vein, transverse sinus and superior petrosal sinus ; *inferior* end in occipital and inferior petrosal sinuses, and, from vermis, in straight sinus.

Minute nuclei in white substance of vermis are in pairs :—

(1) **Nucleus fastigii (roof nucleus)**, alongside median plane near roof of fourth ventricle. (2) **N. globosus** and (3) **n. emboliformis,** more laterally placed, near medial side of mouth of dentate nucleus.

They are connected with cerebellar cortex ; send fibres into superior peduncle to end in pons, mid-brain and thalamus.

Inferior medullary velum has a median part and a right and a left lateral part. The *median part* is prolonged out of the white substance in front of the anterior end of the inferior vermis ; it is very small, and is often absent. The *lateral part* is prolonged out of the white substance at the side of the root of the inferior vermis, and is a wide sheet, but so thin that it is translucent. It lines the bottom of the " bird's nest ". It is therefore curved and is under cover of the tonsil, which has to be torn away for its exposure. Medially and posteriorly, it sinks into the white substance. Laterally, it is continued into the stalk of the flocculus. Anteriorly, it curves downwards in front of the tonsil and ends in a free, lower edge. Its tonsillar surface is covered with pia mater ; its other surface is covered with the ependyma of the fourth ventricle, for it forms part of the roof of the ventricle.

Superior medullary velum fills in the angular interval between the superior peduncles and is attached to their dorsal edges. Superiorly, it ends at the groove between the inferior corpora quadrigemina. From that groove, a band of fibres descends to the upper part of the velum and produces a ridge on the surface called **frenulum veli**.

Trochlear nerve emerges through the velum between the frenulum and peduncle. The lingula covers the lower part of the superficial surface of the velum. Deep surface is lined with the ependyma of the fourth ventricle.

Dentate nucleus lies in the white substance above the " bird's nest ". It *receives* fibres from the cerebellar cortex and from the olivary nucleus. It *emits* most of the fibres of the superior peduncle.

Superior cerebellar peduncle arises mainly in the dentate nucleus. It contains also a few fibres from the cerebellar cortex and the nuclei of the vermis; and fibres of the anterior spino-cerebellar tract descend in it to the cerebellum.

Emerges through the mouth of dentate nucleus, runs upwards and forwards, leaves the cerebellum at the side of the anterior notch and joins the pons, in which its thick, *ventral border* is buried.

Continues upwards, sinking deeper into the dorsal part of pons and converging towards its fellow, to which its thin, *dorsal edge* is connected by the superior medullary velum. Here, it forms the upper part of the lateral boundary of the fourth ventricle, and lists medially to form part of the roof; therefore the unburied part of its *medial surface* is lined with ependyma. Its *dorso-lateral surface* is overlapped by the anterior part of the upper surface of cerebellum; and its upper part is covered with the lateral lemniscus.

At the upper border of pons, it disappears into the tegmentum of mid-brain, under cover of the inferior corpus quadrigeminum; and straightway it begins to cross to the other side, decussating with its fellow. The **decussation** takes place in front of the medial longitudinal bundles and the grey matter around the aqueduct; and it is completed at the level of the upper border of inferior corpus quadrigeminum.

The peduncle, having crossed, proceeds upwards in the tegmentum, meets the red nucleus and surrounds it, forming a white capsule around it. Most of the fibres end in the red nucleus; the rest of them proceed onwards and end in the thalamus. It is possible that some of them enter the internal capsule and proceed, *via* corona radiata, to the motor area; and, even if these do not exist, the cerebellum influences the cortex by relays of fibres from the red nucleus and the thalamus.

Divisions of Cerebellum.—Division for descriptive purposes has, in the past, been pushed too far and still tends to be so. Division into hemispheres and vermis is easy and useful, and is enough for most purposes. For the study of its embryology and morphology, the cerebellum may be divided into three lobes—superior, posterior and inferior. In the fully-developed cerebellum the **superior lobe** is bounded posteriorly by a curved or V-shaped groove, and comprises the anterior and larger part of superior vermis and the anterior part of upper surface of each hemisphere. The **inferior lobe** comprises the anterior and larger part of inferior vermis and the two flocculi, which are connected with the inferior vermis by the inferior medullary velum. The **posterior lobe** comprises all the rest.

PONS

Lies in anterior notch of cerebellum, behind clivus and dorsum sellæ and medial parts of two petrous temporal bones. Continuous, superiorly, with cerebral peduncles of mid-brain, and, inferiorly, with medulla oblongata.

Transverse sections show that it is divisible into a dorsal part and a ventral or basilar part.

Dorsal part is hidden by the cerebellum, and forms the upper part of the floor of the fourth ventricle.

Basilar part is the large, convex, white mass seen in the base of the brain. On each side of the median plane, it is raised up into a blunt, vertical ridge by the bundles of motor fibres descending in the interior. Groove between that pair of ridges is called the **basilar sulcus**, and it accommodates the basilar artery.

Upper border of each half overlaps basis pedunculi; superior cerebellar artery curves backwards along it.

Anterior inferior cerebellar artery runs laterally along *lower border*; and, at that border, in the groove between pons and medulla, the abducent, facial, and auditory nerves are attached.

On each side, the basilar part narrows to become continuous with the **middle cerebellar peduncle**; attachment of trigeminal nerve is taken as the plane where pons becomes peduncle. The peduncle sinks backwards into cerebellum between the lips of the anterior part of the horizontal fissure, and spreads out in the interior, above the dentate nucleus and the beginning of the superior peduncle.

Nerves associated with pons are the 5th, 6th, 7th, and 8th cranial. (*See also* p. 531.) **Fifth** is a mixed nerve whose roots are attached to the side of pons. It has motor and sensory nuclei in dorsal division of pons; but its roots have connexions also in mid-brain, medulla oblongata, and spinal cord. **Sixth** is motor. Its nucleus is low down in pons near dorsal surface; fibres traverse whole thickness of pons to emerge through its lower border, at the upper end of pyramid. **Seventh** is mixed. Its motor root arises from a nucleus placed low down in the middle of its own half of dorsal division of pons; after a devious course in pons it emerges through the lower border at upper end of inferior cerebellar peduncle. The sensory root enters immediately lateral to the motor root, but its nucleus is in medulla oblongata. **Eighth** is attached to inferior peduncle where peduncle joins pons, and its nuclei are in both pons and medulla.

Vessels.—Arteries: Small branches of basilar. **Veins** form a network which is drained into the basal vein, cerebellar veins, and superior petrosal sinus.

CONTENTS OF PONS.—Basilar Part.—Made of intersecting bundles of transverse and vertical fibres, with collections of grey matter, called **nuclei pontis**, packed amongst them

Vertical fibres are confined to the interior. In each half they are the downward continuation of basis pedunculi, which divides into bundles, called *pyramidal bundles*, when it enters pons. They,

therefore, have all descended from cerebral cortex through corona radiata, internal capsule, and basis pedunculi. They comprise :—

1. **Cortico-pontine fibres,** which end in the nuclei pontis.

2. **Motor fibres,** some of which pass across to the dorsal division of the other half of pons to end in motor nuclei there, but most of them re-assemble at the lower border of the pons to form the pyramid of the medulla oblongata.

Transverse fibres are both at the surface and in the interior. Traced laterally, deeper bundles emerge from among vertical bundles and join superficial bundles to form the **middle cerebellar peduncle.**

Most of them arise in nuclei pontis of one side, cross median plane, and end in cerebellar cortex ; a few are said to arise in cerebellar cortex and end in nuclei pontis on both sides of median plane.

On one or both sides, a number of superficial fibres may form an *oblique bundle* that begins on the inferior peduncle in a ridge of grey matter called the *nucleus of the circumolivary bundle* ; it passes upwards between the roots of facial nerve, and runs obliquely to the medial side of trigeminal nerve, where it mingles with the transverse fibres that proceed to the opposite half of cerebellum.

Dorsal Part.—Much smaller than basilar part. Continuous, *superiorly*, with the tegmenta of mid-brain, and, *inferiorly*, with medulla oblongata. Its *posterior surface* is largely free in the floor of fourth ventricle, and is therefore covered with ependyma.

In each half, its *most lateral constituents* are : (1) Inferiorly, **inferior cerebellar peduncle,** which ascends from medulla into pons, and then bends backwards into cerebellum ; (2) superiorly, **superior cerebellar peduncle,** with **lateral lemniscus** on its surface.

Remainder is made up of grey and white matter whose components are :—

(*a*) **Corpus trapezoideum** : A loose group of transverse fibres concerned with the conduction of sound, situated next to the basilar part in the lower half of pons. It is continuous, at the side of the pons, with the lateral lemniscus.

(*b*) **Medial lemniscus** (p. 553) : A broad, flat band of ascending fibres partly intersecting corpus trapezoideum. It is concerned with the conduction of ordinary sensations.

(*c*) **Dorsal nucleus of corpus trapezoideum** : A compact, little body of grey matter, on the dorsal surface of corpus trapezoideum and partly imbedded in it. A group of fibres, called its **pedicle,** runs backwards and medially from it to the abducent nucleus and to the medial longitudinal bundle.

(*d*) **Ventral nucleus of corpus trapezoideum** : Small groups of cells scattered through corpus trapezoideum and among the bundles of the lowest part of the lateral lemniscus.

(*e*) **Auditory striæ** : Delicate, transverse bundles of fibres at the junction of pons and medulla near the ependyma. In some specimens they are visible through the ependyma.

(*f*) **Substantia ferruginea** : A small collection of dark-coloured grey matter under the ependyma, and visible as a dark-blue spot or strip in the uppermost part of the floor of fourth ventricle.

(*g*) **Nuclei of nerves**—5th, 6th, 7th, 8th—and the fibres connected with them. (*See* p. 531.)

(*h*) **Medial longitudinal fasciculus :** A small bundle, near median plane and near posterior surface. It is continued up into mid-brain and down into medulla.

(*i*) **Various other tracts :** Rubro-spinal (p. 549); tecto-spinal (p. 548); pallido-rubro-olivary (p. 528); anterior spino-cerebellar (p. 552); spino-tectal (p. 551); spino-thalamic (p. 552).

MEDULLA OBLONGATA

Lowest division of brain. Continuous superiorly with the pons, and inferiorly, at the foramen magnum, with the spinal cord. Lies almost vertically, in the lower part of anterior notch of cerebellum, behind basi-occiput. Vertebral arteries lie at the sides of its lower part, in front of the nerve-roots; but, as they ascend, they converge to meet on the front of it at the middle of lower border of pons.

It is rather more than an inch in length, and about half of that in thickness. Lower end is nearly cylindrical and has the same girth as spinal cord; but, as it is followed upwards towards pons, it becomes uneven and thicker. Owing to that thickening, its upper half was once called the " bulb " (of the spinal marrow).

Lower half has a **central canal** continuous with that of spinal cord. The canal, traced upwards, inclines backwards, reaches the posterior surface half-way up medulla oblongata, and becomes continuous with the lower end of fourth ventricle; for the lower part of fourth ventricle is the expanded cavity of the upper half of medulla oblongata, and is so near the dorsal surface that nerve-cells and nerve-fibres have disappeared from its posterior wall or roof, which is merely ependyma strengthened by the layer of pia mater which covers it.

The *posterior part* of the upper half of the medulla oblongata, being only ependyma covered with pia mater, is destroyed when the arachnoid mater and pia mater are removed in the early stages of the examination of the brain. The posterior surface that the student sees in the upper half is therefore not the real posterior surface, but is the back of the *anterior part*, and forms the lower half of the floor or anterior wall of the fourth ventricle.

Superficial Characters.—Median fissures on the front and back of medulla oblongata divide its surface into right and left halves; and each of them is divisible into an upper half and a lower.

In upper half, the three most conspicuous structures were noted when the base of brain was examined—

namely, *pyramid*, *olive*, and *inferior cerebellar peduncle*. Besides them, there are *arcuate fibres* and the *spinal tract* of trigeminal nerve.

Pyramid is the bundle alongside anterior median fissure, and is composed of motor fibres from cerebral cortex.

After it enters the lower half, its larger and medial part breaks up into several bundles that cross to the other side, interlacing with the bundles of the other pyramid to form the **decussation of the pyramids**.

Having decussated, the bundles reunite to form a large bundle, called **lateral cerebro-spinal tract,** which descends in the interior of that half of spinal cord. The smaller, lateral part of the pyramid remains on the same side, and forms the **anterior cerebro-spinal tract,** which descends alongside the median fissure into the spinal cord, where its fibres gradually cross to the other side.

Olive is immediately lateral to pyramid. It is a smooth, oval, white elevation produced by underlying grey matter called **olivary nucleus.**

Inferior cerebellar peduncle is farther back, and separated from the olive by a shallow, vertical, fairly wide depression. It is a thick, round bundle that lies in the lateral boundary of the lower part of the fourth ventricle.

It begins half-way down the medulla oblongata at two little eminences called *cuneate* and *gracile tubercles* (p. 522) ; extends upwards to touch the lower border of the back of the pons ; and then, bending sharply backwards, between the superior and middle peduncles, it enters the cerebellum and spreads medially in it.

Spinal tract of trigeminal nerve is a long, tapering bundle that begins at that nerve in the pons and descends through pons and medulla oblongata into the upper part of spinal cord. In pons, it is situated deeply ; but it comes to the surface in the side of medulla. At first, it lies in the depression behind olive, and it is so closely related to inferior peduncle that it seems to be part of it ; but, lower down, it is marked off by indistinct sulci. Its nucleus is a long grey column applied to its deep surface.

Anterior external arcuate fibres form slender bundles that may or may not be visible to the naked eye. They emerge from anterior median fissure and run across pyramid, olive, and spinal tract to join inferior peduncle. They arise in the back of the opposite half of medulla from the

nucleus gracilis and *n. cuneatus*, and they arch forwards to the front. They convey afferent impulses to cerebellum.

In lower half of medulla oblongata, the structures at the surface are, from behind forwards, *fasciculus gracilis* (with *gracile tubercle*), *fasciculus cuneatus* (with *cuneate tubercle*), *spinal tract* of trigeminal, *posterior* and *anterior spino-cerebellar tracts*, *anterior cerebro-spinal tract*, and *decussating fibres* of pyramid.

Fasciculus gracilis is the bundle that lies alongside posterior median fissure. It is a sensory tract composed of fibres of posterior roots of spinal nerves continued up from spinal cord. It ends half-way up medulla oblongata in a small, distinct eminence, called the **gracile tubercle**, produced by the enlarged, upper end of a long, underlying nucleus called **nucleus gracilis**.

Fasciculus cuneatus is the bundle immediately lateral to gracilis, and it is marked off by shallow sulci on each side of it. It also is a sensory tract that ascends through spinal cord from posterior nerve-roots. It ends in a small, indistinct eminence, called **cuneate tubercle**, which is placed immediately above and lateral to the gracile tubercle, and is produced by the enlarged, upper end of **nucleus cuneatus**.

Spinal tract descends along the groove that marks the lateral margin of fasciculus cuneatus.

Spino-cerebellar fasciculi arise in the spinal cord, and convey afferent impulses to cerebellum. They are wide, thin bundles that occupy the side and part of the front of lower half of medulla oblongata. They are not marked off from each other at first, but half-way up medulla oblongata they separate. The **posterior** one inclines obliquely backwards across the spinal tract to join the inferior peduncle. (In some specimens the naked eye can detect it as an oblique, white band.) The **anterior** one disappears under cover of olive—only its posterior part remaining at the surface as a narrow strip along the posterior margin of olive. It reaches cerebellum by ascending in pons to the superior peduncle and descending in it.

Anterior cerebro-spinal tract lies along the anterior median fissure.

Blood-Vessels.—**Arteries** are small branches of vertebral. The **veins** form a network on the surface drained (1) by veins that enter inferior petrosal sinus, and (2) by a vein that passes through

anterior condylar canal to end in the pharyngeal plexus.

Nerves associated with medulla oblongata are the 5th to 12th cranial and 1st cervical.

Fifth belongs chiefly to pons, but is connected also with mid-brain, and sends its spinal tract downwards over the surface of a nucleus that extends from pons, through medulla oblongata, into the spinal cord.

Sixth belongs to pons. Its only association with medulla is that it emerges at the upper end of the pyramid.

The large, motor part of **seventh** belongs to pons ; but the nucleus of its sensory root lies in the upper end of medulla oblongata (being the uppermost part of one of the nuclei of 9th) ; and both roots, though attached to pons, are close to the inferior peduncle.

Eighth is really two nerves—cochlear and vestibular—united into a single trunk from internal auditory meatus to lower border of pons. There, the two nerves separate and clasp the inferior peduncle between them. **Cochlear** curves backwards round the side of the peduncle and ends in two nuclei that lie on the peduncle. **Vestibular** passes backwards between the peduncle and the spinal tract, into the substance of medulla to end in several nuclei that belong to both medulla and pons and lie in the floor of fourth ventricle ; and some of the fibres form a *descending root* that accompanies a prolongation of one of the nuclei downwards in the substance of medulla along the medial side of the back of inferior peduncle.

Ninth and **tenth** belong wholly to medulla oblongata. They share three nuclei. One nucleus lies partly in the grey matter around central canal and partly in floor of ventricle ; the other two are farther forward, and one of them is named *nucleus ambiguus*. The nerve-roots are a linear, vertical row of bundles attached to the side of the medulla in front of inferior peduncle. The root-fibres (motor and sensory) pass from and to the nuclei through the substance of the medulla.

The upper or cranial part of **eleventh** arises from the lower part of nucleus ambiguus, and its fibres emerge as a linear, vertical row of bundles through the side of medulla below the tenth.

Twelfth belongs wholly to medulla oblongata. Its nucleus is partly in the grey matter around central canal and partly in floor of ventricle. The fibres pass forwards through the substance of medulla and emerge in a linear row through the front of the medulla between the pyramid and the olive.

Uppermost fibres of anterior root of **first cervical** emerge below the twelfth cranial.

Anterior median fissure begins at the lower border of pons in a pit called **foramen cæcum,** and it is continuous inferiorly with the median fissure of spinal cord. Upper part of fissure is largely filled by emerging arcuate fibres. Lowest part is interrupted by the decussation of the pyramids, and the median vessel formed by the union of

right and left anterior spinal branches of vertebral lies in it in front of the decussation.

Posterior median fissure exists only in the lower half of medulla oblongata. Inferiorly, it is continuous with the median sulcus of spinal cord. Half-way up medulla oblongata, where central canal comes to the surface, the fissure ends, for its lips diverge to become continuous with the margins of floor of fourth ventricle. But in the upper half, on the floor of the fourth ventricle, there is a median furrow that runs downwards into the upper end of the central canal.

Spinal tract of V. is spread over the surface of its nucleus. About half-way down the medulla, an enlargement of the nucleus bulges out the tract to form an indistinct eminence—*trigeminal tubercle.*

The rootlets of the 9th and 10th nerves pierce the spinal tract; the rootlets of the 11th emerge in front of it.

Structure of Medulla Oblongata

The white matter is chiefly at the surface, where it is arranged into tracts already named; in the interior also there is a considerable quantity of white matter, including numerous tracts. The grey matter is chiefly the layer around central canal and the layer in the floor of fourth ventricle; but there are several separate collections, both scattered and compact. The fibres in the interior run in different directions—longitudinally, horizontally and obliquely—making a meshwork, called the **substantia reticularis,** in the looser parts of which there is grey matter.

IN LOWER HALF.—White matter is made up of:—

1. *Longitudinal fasciculi,* of which those on the surface have been named already, and those in the interior will be named when the upper half is dealt with.

2. Some root-fibres of the *last three cranial* nerves and of the *first cervical nerve.*

3. *Crossed fibres of pyramid,* inclining backwards and downwards to become the lateral cerebro-spinal tract.

4. *Internal arcuate fibres.*

Internal arcuate fibres convey sensory impressions. They arise, in the back of medulla oblongata, from nucleus gracilis and cuneatus; arch forwards around the grey matter of central canal; and cross to the other side, decussating with their fellows.

Having crossed, most of them bend upwards and form a large, flat band, called **medial lemniscus,** that lies alongside the median plane of the upper half, behind the pyramid; the rest of them

proceed forwards and form the bundles of external arcuate fibres already seen on the front of the medulla. The decussation is called the **decussation of lemnisci**; it takes place in front of central canal, above and behind the decussation of pyramids.

Grey matter includes :—1. Grey matter around central canal, which contains the lower parts of *hypoglossal nucleus* and of one *nucleus of vagus*.

2. *Nucleus gracilis*, under cover of fasciculus gracilis and gracile tubercle.

3 *Nucleus cuneatus*, under cover of fasciculus cuneatus and cuneate tubercle.

4. *Nucleus of spinal tract* of trigeminal, under cover of that tract.

5. *Lateral nucleus*, under cover of spino-cerebellar tracts -between them and the crossed fibres of pyramid; it gives origin to some fibres of the first cervical nerve and of accessory nerve.

IN UPPER HALF.—The fibres of hypoglossal and the fibres of vagus and glosso-pharyngeal, as they traverse the substance of medulla, divide each of the right and left halves into three areas—medial, lateral, posterior. Each area contains grey matter, and white matter whose fibres run in different directions. The horizontal and oblique fibres will be mentioned later under substantia reticularis.

Medial Area.—Longitudinal fasciculi are :—1. *Pyramid.*

2. *Medial lemniscus*, behind medial part of pyramid.

3. A small bundle, called *tecto-spinal tract*, which descends from superior corpus quadrigeminum of the other side, and at this level lies behind lemniscus.

4. A small bundle, called *medial longitudinal fasciculus*, lies behind the tecto-spinal tract, under cover of the grey matter of the floor of fourth ventricle; its fibres connect the nuclei of cranial nerves.

Grey matter comprises :—1. *Arcuate nuclei*—small collections on the surface of the pyramid.

2. *Medial accessory olivary nucleus*—a small grey band on the lateral surface of the lemniscus near the pyramid.

3. Upper part of *hypoglossal nucleus*, in the grey matter that covers medial longitudinal bundle.

Posterior Area.—Longitudinal fasciculi are :—

1. *Inferior cerebellar peduncle.*

2. *Spinal tract* of trigeminal (partly also in lateral area), at the surface immediately in front of the peduncle.

3. *Descending root of vestibular nerve*, near the floor of the ventricle close by the medial side of the peduncle.

4. A small bundle of descending fibres, called *tractus solitarius*, lies deeply in the medulla in front of the descending vestibular root. It is composed of fibres that convey the sense of taste; and it is derived chiefly from the ninth nerve, but also, at its upper and lower ends, from the seventh and the tenth.

The **grey matter** comprises :—1. The two *nuclei of cochlear nerve*, on the surface of the inferior peduncle close to the pons.

2. A ridge of grey matter called the *nucleus of the circumolivary bundle*, lower down on the surface of the inferior peduncle.

3. *Nucleus of spinal tract*, along the deep surface of that tract.

4. *Nucleus of the descending vestibular root* on the postero-medial surface of that root and partly mingled with it.

5. Lower part of *medial nucleus of vestibular nerve* lies in the uppermost part of the medulla, medial to the descending root.

6. *Nucleus of tractus solitarius*, along the medial side of that tract.

Lateral Area.—The largest and most conspicuous object is the **olivary nucleus,** which extends, from the olive at the surface, backwards and medially, behind the lateral part of pyramid, almost to the lemniscus. It sends a large bundle of fibres called the *olivo-cerebellar tract* to the inferior cerebellar peduncle of the other side.

Longitudinal fasciculi are :—

1. A bundle, called *pallido-rubro-olivary fasciculus*, descends from globus pallidus and red nucleus to the olivary nucleus, and lies on its surface and immediately behind it near the surface.

2. *Anterior spino-cerebellar tract* also is behind the nucleus, and so near the surface that part of it is seen at the posterior margin of olive.

3. *Posterior spino-cerebellar tract* is at the surface farther back, and is inclining backwards across the spinal tract to join the inferior peduncle.

4. *Rubro-spinal tract*, descending from red nucleus of the other side, lies more deeply—in front of nucleus of spinal tract.

5. *Anterior and posterior spino-thalamic tracts*, conveying sensory impressions from opposite half of the spinal cord, lie close together behind the deepest or most medial part of olivary nucleus (the anterior being more medial than the posterior).

6. *Spino-tectal tract* is medial to the spino-thalamic tracts. It conveys afferent impressions from the opposite half of spinal cord to the superior corpus quadrigeminum.

7. Scattered *ponto-spinal* and *olivo-spinal fibres*, descending from pons and from medulla oblongata itself.

8. *Spino-vestibular*, *spino-pontine* and *spino-rubral fibres*.

Grey matter of lateral area includes small, scattered groups of cells of unknown function, and certain definite nuclei :—

1. *Olivary nucleus*.

2. *Dorsal accessory olivary nucleus*, just behind the most medial part of the olivary nucleus.

3. A long column called *nucleus ambiguus*, situated a little behind the centre of the lateral area, gives origin to (*a*) the motor fibres of 9th nerve, (*b*) motor fibres of 10th for striped muscle, and (*c*) the fibres of upper (cranial) part of 11th.

4. Upper part of *dorsal nucleus of 9th and 10th* lies in the grey matter of floor of ventricle lateral to hypoglossal nucleus.

5. *Vomiting centre* is in or near upper part of dorsal nucleus.

6. *Cardiac centre* (inhibitory and accelerator) is a small nucleus situated dorso-medial to the middle of nucleus ambiguus.

7. *Vasomotor centre* is near the dorsal vagus nucleus at the level of the lower angle of fourth ventricle ; its fibres descend in the lateral area of medulla and spinal cord and end in the lateral grey column of the thoracic and upper two lumbar segments.

8. *Respiratory centre* appears to be a chain of small nuclei in both pontine and medullary parts of floor of fourth ventricle not far from median plane. Fibres descend from it to the nuclei of nerves that supply the muscles of respiration.

Substantia Reticularis.—In the upper half, it lies behind pyramid and olivary nuclei ; its meshwork character is more obvious than in the lower half. The part of it between hypoglossal fibres and median plane is wholly included in the medial area of medulla, and is called *substantia reticularis alba* because it contains very little grey matter. The rest is called *substantia reticularis grisea.*

Positions of **longitudinal fasciculi** and collections of **grey matter** in the substantia have been defined in the account of the areas.

Oblique and **horizontal fibres** are :—

1. Root fibres of 9th nerve and of parts of 10th, 11th and 12th.

2. Fibres to motor nuclei from the pyramid of the other side.

3. Fibres from sensory nuclei to the lemniscus and spino-thalamic tracts of the other side.

4. Fibres that connect nuclei with medial longitudinal bundle.

5. Vestibulo-spinal tract, running downwards and forwards from the lateral vestibular nucleus to the anterior part of spinal cord.

6. Uppermost internal arcuate fibres.

7. Olivo-cerebellar fibres, passing across to the inferior cerebellar peduncle from the olivary nucleus of the other side.

About three-quarters of the fibres of **pyramid** cross to the other side to form **lateral cerebro-spinal tract.** Most of the remaining fibres are continued as the **anterior cerebro-spinal tract** of the same side ; but a few (called homolateral fibres) join those that have crossed from the other side ; and a few others end in arcuate nuclei.

Arcuate Nuclei.—Small collections of grey matter on the front and medial side of pyramid, under cover of external arcuate fibres, to some of which they give rise.

In some specimens, on one or both sides, a bundle of fibres of the pyramid, called the **circumolivary bundle of pyramid,** curves backwards round lower end of olive, and ends in the **nucleus of circumolivary bundle.** This nucleus is an oblique ridge of grey matter that lies on the inferior peduncle behind the roots of vagus, and it gives origin to the oblique bundle of pons (p. 519).

Arcuate nuclei and the nucleus of the circumolivary bundle are outlying members of nuclei pontis; and the fibres of pyramid that end in them are wandering cortico-pontine fibres.

External Arcuate Fibres.—Two groups—posterior and anterior. **Posterior external arcuate fibres** arise in nucleus gracilis and cuneatus, and at once run up into the superficial part of the inferior cerebellar peduncle. Some **anterior external arcuate fibres** arise in arcuate nuclei. Others are continuations of internal arcuate fibres and have come forwards through medulla from nucleus gracilis and cuneatus of the other side; they emerge partly through pyramid and at its lateral edge, but chiefly through median fissure. They arch across pyramid, olive and spinal tract to join the peduncle.

(Some hold that the only external arcuate fibres are those that come from the arcuate nuclei.)

Olivary Nucleus.—A crumpled bag of grey matter filled with white matter. It lies in the upper half of medulla oblongata behind the lateral part of pyramid, and bulges out its thin, white covering to form the olive.

Hilum or mouth of the bag looks medially towards lemniscus. Out of it emerge the fibres of the **olivo-cerebellar tract.** They cross the median plane, decussating with their fellows; proceed onwards, some through the opposite olive and some around it (ensheathing it); incline backwards and traverse the spinal tract of trigeminal nerve, breaking the tract up into bundles; enter the deep aspect of the inferior cerebellar peduncle, of which they form the chief bulk; and the peduncle carries them into the cerebellum, where they end in the dentate nucleus and cerebellar cortex.

Some fibres run the opposite way—from cerebellum to olivary nucleus. The nucleus receives large numbers of fibres (*pallido-rubro-olivary fasciculus*) from the globus pallidus and the red nucleus, and is therefore a relay station between them and the cerebellum.

Accessory olivary nuclei are slender bars of grey matter, placed one behind the hilum and one medial to it.

Inferior Cerebellar Peduncle.—Lies postero-laterally in the upper part of medulla oblongata. It begins at the gracile and cuneate tubercles as a surface layer of posterior external arcuate fibres, which arise from the underlying nucleus gracilis and cuneatus. It extends obliquely upwards, in the lateral boundary of the lower part of fourth ventricle, gaining bulk as the olivo-cerebellar fibres from the opposite olive enter it. When it reaches the pons, it ascends for a very short distance in the lateral part of the back of the pons; then, bending sharply backwards between the middle peduncle on its lateral side and the superior peduncle on its medial side, it enters the cerebellum through the junction of the anterior notch and horizontal fissure. In the cerebellum, it bends medially and spreads fanwise over the dentate nucleus towards the vermis; and its fibres end in the dentate nucleus and cerebellar cortex.

Relations.—Deep aspect of the peduncle is related to substantia reticularis. Spinal tract of trigeminal and the roots of vagus and glosso-pharyngeal are immediately in front of it, superficially. At the lower border of pons, it is clasped by the vestibular and cochlear

nerves as they separate ; and the cochlear nuclei lie on it—one on its front, in the angle between the nerves, and one on its side under cover of the cochlear nerve as it curves on to the back of the peduncle. Lower down, behind the glosso-pharyngeal and vagus nerves, a protrusion of the ependyma of the ventricle (called the *lateral recess*) extends across it ; and the nucleus of circumolivary bundle lies on it.

Constituents.—1. Olivo-cerebellar fibres, from opposite olive.

2. Posterior external arcuate fibres, from nucleus gracilis and cuneatus of its own side.

3. Anterior external arcuate fibres, from arcuate nuclei of their own side and nucleus gracilis and cuneatus of opposite side.

4. Posterior spino-cerebellar tract from its own half of spinal cord.

5. A few fibres from vestibular nerve, and others that connect the cerebellum with the vestibular nuclei.

Medial Longitudinal Fasciculus.—*See* p. 530.

Continuity of Grey Matter of Medulla Oblongata and Spinal Cord

In order that the arrangement of grey matter in the medulla oblongata may be understood more fully, it is necessary to consider the arrangement in the spinal cord.

In the spinal cord, as in the brain-stem, the grey matter is inside. In each half of the spinal cord, the grey matter is a long, uneven column, compressed from side to side. The medial surfaces of the right and left columns are joined to the edges of a long strap of grey matter called the **grey commissure** ; and the commissure is tunnelled lengthwise in the median plane by the **central canal.** The part of each column in front of the commissure is called the **anterior grey column** ; and the part behind is the **posterior grey column.** Anterior column contains **motor** nuclei that give rise to the fibres of anterior roots of spinal nerves. Posterior column contains **sensory** nuclei, in which many of the fibres of posterior roots end. In transverse sections, the part of a column that adjoins the commissure is called its **base,** and the rest of it is its **head.** The grey matter at the edge of the " head " of the posterior column is more translucent (under the microscope) than the rest of the grey matter, and is called **substantia gelatinosa.** In each half, the two columns and the root-fibres of the nerves divide the white matter into three *white columns* —anterior, lateral, and posterior.

In the medulla oblongata, the grey matter around its central canal is a continuation of (1) the grey commissure and (2) the bases of the anterior and posterior grey columns. When the canal opens into the fourth ventricle, its grey matter is continuous with the grey matter spread over the floor of the ventricle—the medial part of the floor being continuous with the grey matter in front of the canal, and the lateral part with the back.

As the lateral cerebro-spinal tract passes obliquely backwards and downwards from the anterior part of medulla oblongata to the lateral white column of the spinal cord, it cuts through the anterior grey column and separates head from base. The **basal part** is continued upwards into medulla oblongata—at first, joined to the ventral

wall of the central canal, and, next, in the floor of the ventricle near the median plane—and in it there is the *nucleus of hypoglossal nerve*. The detached **head-part** also is continued upwards. It is divisible into two parts. The lateral part is the **lateral nucleus** ; gives origin to some fibres of the *first cervical nerve* and of the *lower* (spinal) *part of accessory nerve*, and then comes to an end. The medial part is called **nucleus ambiguus.** It extends to the upper end of medulla, and is pushed first by the pyramid and then also by the olive into the lateral area. It is the nucleus of the upper (cranial) *part of accessory*, of the *motor fibres of glosso-pharyngeal* and of the *motor fibres of vagus* that supply striped muscle.

As the central canal ascends into medulla oblongata and approaches its posterior surface, the fasciculus gracilis and cuneatus become thinner and wider, and the posterior grey column is bent over towards the lateral side. From the medial (now posterior) side of the column, the *nucleus gracilis* and *cuneatus* appear as ridges ; and the fasciculi end in them. Internal arcuate fibres arise in these two nuclei ; and, as they arch forwards, they cut through the modified posterior grey column and separate head from base. The **base** is first attached to the postero-lateral wall of the canal, and then is continued into the lateral part of the floor of fourth ventricle ; and it contains the *dorsal nucleus of vagus and glosso-pharyngeal* and the *vestibular nuclei*. The *nucleus of tractus solitarius* is a separated portion of the upward continuation of the base. The detached **head** (mainly **substantia gelatinosa**) is continued up to the pons as the *nucleus of spinal tract* of trigeminal, under cover of that tract.

Medial Longitudinal Fasciculus.—The white matter nearest the head of the anterior grey column of the spinal cord is called the *anterior intersegmental tract*. It is made up chiefly of many overlapping series of short fibres that run upwards and downwards to connect the nuclei in the grey matter of different segments of the spinal cord.

When the tract reaches the medulla oblongata, it lies on the medial side of the detached head of the anterior grey column. Above the level of the decussation of pyramids, it has come to lie behind the pyramid, close to the grey matter in front of the central canal. There, the decussation of lemniscus takes place in front of it, and it comes to lie behind the lemniscus under the grey matter of the floor of the ventricle, close to the median plane ; and is given the name **medial longitudinal fasciculus.**

That compact bundle enters pons and ascends through it, maintaining its close relation to the median plane and to the grey matter of the floor of the ventricle. Having entered mid-brain, it ascends in close relation to the front of the grey matter of the aqueduct. It ends in a nucleus in the posterior part of the side-wall of third ventricle.

Like the intersegmental tract with which it is continuous, it is composed of association fibres. They enter it from the nuclei of cranial nerves, divide, run upwards and downwards and leave it to end in the nuclei of other cranial nerves. They thus connect the nuclei of all the cranial nerves. The most numerous fibres are those that connect the vestibular nuclei with the motor nuclei, especially the 3rd, 4th, 6th, and 11th.

Nuclei of Nerves of Pons and Medulla Oblongata and their Connexions

The nerves are the 5th to the 12th cranial and a portion of the 1st cervical. The 8th has very special connexions, and it is taken after the others.

TRIGEMINAL.—Is connected with all three parts of the brain-stem, and with the spinal cord.

Sensory nuclei are an upper and a lower. **Upper nucleus** is a rounded body of grey matter situated half-way down the dorsal division of pons, in front of the buried edge of the superior cerebellar peduncle. **Lower nucleus** is a long column of grey matter which is the upward continuation of substantia gelatinosa of the spinal cord through medulla oblongata into pons, where its upper end is continuous with the upper nucleus; and it lies along the deep surface of spinal tract of V.

The lower nucleus receives the cruder impressions of pain, heat, touch, and pressure from the skin and mucous membranes; the fibres from the mandibular-nerve area enter its highest part and those from the ophthalmic area enter the lowest part. The upper nucleus receives the finer impressions from the skin and mucous membranes and all the impressions from the deeper parts.

Sensory fibres arise in the trigeminal ganglion. Each fibre divides, in the ganglion, into a peripheral branch and a central branch. The *peripheral branches* form the ophthalmic, maxillary, and mandibular nerves. The *central branches* form the sensory root, which passes to the pons.

Sensory root sinks backwards for half an inch through the junction of pons and middle cerebellar peduncle, and its fibres divide into superior and inferior branches. *Superior branches* are very short, and end at once in the upper nucleus. *Inferior branches* form the spinal tract, and end in the lower nucleus.

Spinal tract descends in the pons, with the vestibular nerve and inferior peduncle on its lateral side, and the facial nucleus and emerging fibres of the facial nerve on its medial side; having entered the medulla oblongata, it lies at the surface, and descends, as a tapering bundle, into the spinal cord to end at the level of the second cervical nerve. In medulla oblongata, it is at first in front of the inferior peduncle, is traversed by olivo-cerebellar fibres and the roots of 9th and 10th nerves (being broken into bundles by them), and is crossed by the posterior spino-cerebellar tract. Lower down, it is in front of the fasciculus cuneatus, between it and the spino-cerebellar tract.

Motor nuclei also are an upper and a lower. **Lower nucleus** is the main one. Lies in the pons close to the medial side of the upper sensory nucleus. **Motor root** arises in it, passes outwards alongside the sensory root, and finally joins the mandibular nerve. **Upper nucleus** is a column of cells in the grey matter on the side of the aqueduct of mid-brain. It has been claimed that these cells are sensory (comparable to ganglion-cells), for they are quite unlike motor cells in appearance; but the bundle of fibres that arise from them descends into the pons and joins the motor root.

Communications.—Nuclei are connected with the nuclei of other cranial nerves by fibres of the medial longitudinal bundle. Motor nuclei receive fibres from the motor area of the other side and from the red nucleus of the same side. Sensory nuclei send fibres across to the opposite spino-thalamic tracts and medial lemniscus. And they send fibres to the motor nuclei of the trigeminal and facial nerves—for short reflexes.

ABDUCENT.—Belongs wholly to the pons.

Nucleus is a small, round body of grey matter situated low down in the pons, near the posterior surface, lateral to the medial longitudinal bundle, and in the concavity of the loop of the facial nerve.

Root-fibres run forwards and slightly downwards through the whole substance of the pons; they pass across the medial side of the dorsal nucleus of corpus trapezoideum and pierce the lateral edges of the medial lemniscus and pyramidal tract to emerge at the lower border of pons.

Communications are similar to those of the trochlear nucleus (p. 512); but, in addition, it sends fibres upwards to join those of the oculomotor nerve that go to the opposite rectus medialis.

FACIAL.—Motor and secretory part belongs to the pons; sensory fibres end in medulla oblongata.

Motor nucleus is an ovoid mass of grey matter that lies low down in the pons, at the medial side of the spinal tract of V., on the back of the corpus trapezoideum, but partly separated from it by the dorsal nucleus of the corpus. **Secretory nucleus** (for salivary glands) is a small nodule behind and lateral to the lower part of the motor nucleus.

Motor root-fibres arise in these nuclei and form a loose bundle that passes backwards and medially to the posterior surface of pons, near the median plane; turns sharply upwards under the ependyma, along the postero-medial side of abducent nucleus; turns sharply in a lateral direction over the upper part of that nucleus; then, runs a slightly sinuous course forwards and sidewards and a little downwards, through the whole thickness of pons, passing between its own nucleus on its medial side and the spinal tract on its lateral side; and emerges through the lower border of pons antero-medial to the inferior peduncle. The loop which it makes round the abducent nucleus produces a slight, round elevation in floor of the fourth ventricle called the *facial colliculus*.

Sensory nucleus is the upper end of a grey column, called *nucleus of tractus solitarius*, that lies in the medulla oblongata.

The **sensory fibres** belong to the special sense of taste. They arise in the **ganglion** of the facial nerve. Each fibre divides into a peripheral branch and a central. *Peripheral branches* run outwards (*a*) in chorda tympani, for the anterior two-thirds of tongue, and (*b*) in the greater superficial petrosal nerve, for the palate. *Central branches* run inwards, first in the substance of facial nerve, and then alongside it as its **sensory root,** which enters the upper end of medulla oblongata, through or behind the spinal tract, immediately above the ninth nerve, and terminates in the sensory nucleus.

Communications.—Motor nucleus receives: (1) Fibres from motor

area of the opposite side and a few from the same side. (2) Fibres from its own sensory nucleus and from the nucleus of spinal tract—making a short reflex for automatic movement of facial muscles. (3) Auditory fibres from corpus trapezoideum, to initiate automatic contraction of stapedius.

Motor root is joined by fibres from the medial longitudinal bundle; some of them come from the oculomotor nucleus and are distributed to orbicularis oculi and frontal belly of occipito-frontalis (*see* p. 511); others come from the hypoglossal nucleus, and are distributed to orbicularis oris in order to harmonise the movements of the lips and tongue in speaking and chewing.

Both **motor** and **sensory nuclei** are connected with the nuclei of other cranial nerves by fibres of the medial longitudinal bundle.

Sensory nucleus sends fibres across to the opposite medial lemniscus to be carried to the thalamus, where new fibres arise and pass to the centre for taste in the hippocampal gyrus.

AUDITORY.—*See* p. 535.

GLOSSO-PHARYNGEAL AND VAGUS.—Have three nuclei in common—dorsal nucleus, nucleus ambiguus and nucleus of tractus solitarius. Glosso-pharyngeal has a special secretory nucleus (for parotid gland); and vagus has a special cardiomotor nucleus.

Secretory nucleus of IX is a small nodule that lies at the upper end of the medulla a little medial to the nucleus of the spinal tract. It sends **fibres** sidewards through the tract with the other fibres of the glosso-pharyngeal.

Cardiac nucleus of X (inhibitory and accelerator), very small, lies postero-medial to the middle of nucleus ambiguus. Its fibres accompany those of the vagus that arise in that nucleus.

Motor nuclei are (1) nucleus ambiguus, for striped muscle, and (2) part of the dorsal nucleus, for unstriped.

Nucleus ambiguus is a long column of grey matter that extends from the detached head of the anterior grey column of the spinal cord up to the upper end of medulla oblongata, where it lies midway between the median plane and the side of medulla, and midway between the olive and the back of medulla. Its upper part gives rise to the motor fibres of glosso-pharyngeal; its middle part to the fibres of vagus that supply muscles of pharynx and palate; and its lower part to the upper or cranial fibres of accessory nerve.

Dorsal nucleus is motor, secretory and sensory. It is a long column of cells whose lower part lies in the grey matter at the side of the central canal of medulla oblongata, and whose upper part lies under the ependyma of the vagal triangle of the floor of the fourth ventricle.

Secretory fibres of vagus and the **motor fibres** that supply the musculature of gullet, stomach and air-tubes arise in the motor part of the dorsal nucleus. They pass forwards and sidewards to emerge on the side of the medulla through the spinal tract. The fibres from nucleus ambiguus curve backwards and sidewards to join them in the substance of the medulla.

Sensory nuclei are the nucleus of tractus solitarius and part of the dorsal nucleus.

Nucleus of tractus solitarius receives the taste-fibres of the facial

(tongue and palate), glosso-pharyngeal (posterior third of tongue) and vagus (epiglottis). It is a long, slender column of cells that lies antero-medial to the descending root of the vestibular nerve, and is continuous inferiorly with the base of the posterior grey column of the spinal cord.

Sensory fibres arise in ganglia placed on the glosso-pharyngeal and vagus at the base of the skull. Each fibre at once divides into a central and a peripheral branch. *Peripheral branches* run onwards in the nerves. *Central branches* run inwards alongside the motor fibres, pierce the spinal tract of V., and enter the substance of the medulla.

The *taste fibres* turn downwards to form the tractus solitarius (which reaches down to the level of the fourth cervical nerve) and end in the nucleus of that tract—the fibres of glosso-pharyngeal ending in its upper part, and those of vagus in the lower.

The other fibres convey sensory impressions from dura mater, external auditory meatus, respiratory organs, and alimentary organs —from the posterior third of tongue downwards. They run backwards and medially to the dorsal nucleus. But those of the auricular branch of vagus come from skin and not from viscera, and they end therefore in the nucleus of the spinal tract.

Communications.—The nuclei are connected with nuclei of other cranial nerves by the medial longitudinal bundle. Motor nuclei receive fibres from the opposite pyramid. Sensory nuclei send fibres across to the opposite spino-thalamic tracts and medial lemniscus, and they carry these fibres to the thalamus ; new fibres arise in the thalamus and pass to the sensory area (post-central gyrus) and to the centre for taste in the hippocampal gyrus.

ACCESSORY.—Two portions– a spinal or lower, a cranial or upper.

Nucleus of spinal root is in the anterior grey column, behind the motor nuclei of the upper five cervical nerves.

Root-fibres curve backwards in the anterior grey column, appear in the bay between the anterior and posterior grey columns, run sidewards through the lateral intersegmental tract (p. 546), and through the lateral cerebro-spinal and posterior spino-cerebellar tracts, and emerge between the anterior and posterior roots of spinal nerves, behind lig. denticulatum. The uppermost fibres of the spinal root arise in the lateral nucleus of medulla oblongata.

Nucleus of cranial root is the lower part of nucleus ambiguus.

Root-fibres pass sidewards and emerge through the side of medulla in front of the spinal tract of V., and below the roots of vagus.

Communications.—The nuclei receive fibres from the opposite motor area through the pyramid of the opposite side and the lateral cerebro-spinal tract of the same side. They are connected with the nuclei of other cranial nerves (especially vestibular) by the medial longitudinal bundle, and with the nuclei of spinal nerves by the anterior intersegmental tract. Some fibres of the posterior roots of cervical nerves end in the spinal nucleus.

HYPOGLOSSAL.—Supplies muscles of tongue.

Nucleus is a long column that lies partly in the grey matter in

front of the central canal of medulla oblongata and partly in the floor of fourth ventricle close to the median plane.

Root-fibres pass forwards in the substance of the medulla to emerge through the groove between pyramid and olive.

Communications.—Nucleus receives fibres from the opposite pyramid, and sends fibres upwards to join those of the facial nerve that supply orbicularis oris (*see also* p. 533). It is connected with its fellow by commissural fibres, and with other nuclei by the medial longitudinal bundle.

AUDITORY NERVE.—In its connexions, it is the most complicated of all nerves. Belongs to both pons and medulla oblongata.

It is really two nerves united side by side—**cochlear** (hearing) and **vestibular** (equilibration). Extends from the internal auditory meatus to the lower border of pons, where its two constituents separate and clasp the inferior cerebellar peduncle between them.

Cochlear and vestibular nerves are most conveniently dealt with as distinct nerves, but some vestibular fibres join the cochlear in the internal ear; and in the brain-stem some mingling takes place.

Vestibular nuclei are superior, lateral, medial and inferior.

Medial nucleus is the principal one. Lies partly in pons and partly in medulla oblongata, under the ependyma of the ventricle—from the foveæ (pp. 539, 540) almost to the lateral boundary.

Inferior nucleus lies in medulla oblongata. It is a grey column that begins on the lateral side of the middle of the medial nucleus and extends downwards along the medial side of the inferior peduncle as far as the level of the decussation of the lemnisci (p. 525).

Lateral nucleus lies in the pons, lateral to the upper part of the medial nucleus and farther from the ependyma.

Superior nucleus is an extension upwards and backwards from the lateral nucleus.

Fibres of vestibular nerve arise in the **vestibular ganglion** placed on the nerve in the internal auditory meatus. The ganglion cells are bi-polar. They send *peripheral branches* through the bottom of the meatus to the utricle saccule and semicircular ducts of internal ear—*i.e.* the peripheral organs of equilibration. Their *central branches* form the vestibular nerve, which runs with the cochlear nerve to the lower border of the pons. There, the vestibular nerve passes backwards, between the inferior peduncle and spinal tract of V., into the substance of medulla oblongata, and its fibres divide into ascending and descending branches.

The *descending branches* partly end in the medial nucleus and partly form the descending root. The **descending root** runs downwards between inferior peduncle and the inferior nucleus—sending its fibres into that nucleus till it ends.

The *ascending branches* end in the lateral and superior nuclei, and, *via* the inferior peduncle, in the nuclei of the vermis and in the cerebellar cortex.

Communications.—The vestibular **nerve** is connected with the sensory root of the facial nerve in the meatus.

The nuclei have numerous connexions:—

1. Fibres pass to and fro, *via* the inferior cerebellar peduncles (chiefly the opposite peduncle), between the vestibular nuclei and the cortex of both halves of the cerebellum, which is the central organ for equilibration.

2. Fibres from the nuclei pass across to the opposite medial lemniscus; others join the corpus trapezoideum and are carried by the lateral lemniscus to the inferior corpus quadrigeminum.

3. Some fibres from the superior nucleus pass directly to the nuclei of the 6th, 4th and 3rd nerves. Others from the superior and lateral nuclei pass to the medial longitudinal bundle. They form a great part of that bundle and connect the vestibular nuclei with other nuclei. The most important fibres are :—

(*a*) Those that run to the nuclei of the 6th, 4th and 3rd nerves in order to engender automatic movements of the eyes when the semicircular ducts are stimulated by movements of the head (this accounts for the *nystagmus* seen in disease of the vestibular apparatus).

(*b*) Those that end in the vagus nucleus (accounting for the vomiting and disturbances of circulation in vestibular disease).

(*c*) Those that run to the nuclei of the accessory nerve and cervical nerves to regulate movements of the head.

4. The *vestibulo-spinal tract* is a bundle of fibres that arise in the lateral nucleus. It descends through medulla oblongata into the anterior part of the spinal cord to end in motor nuclei (as far down as the lumbar region of the cord) to regulate automatic movements throughout the body; and motor disturbances are therefore a sign of vestibular disease.

Cochlear nuclei are two small collections of grey matter—a ventral and a dorsal. **Ventral nucleus** is on the front of inferior cerebellar peduncle in the angle made by the vestibular and cochlear nerves as they separate. **Dorsal nucleus** is on the side of the peduncle under cover of cochlear nerve-fibres.

The **fibres of the cochlear nerve** arise in the **spiral ganglion**, which lies in the spiral canal of the cochlea of the internal ear. The ganglion-cells are bipolar. They send *peripheral branches* directly into the spiral organ—the essential peripheral organ of hearing. Their *central branches* pass through the holes in the bottom of the internal meatus and form the cochlear nerve, which accompanies the vestibular nerve to the lower border of the pons. There, the fibres of the cochlear nerve divide into *ventral* and *dorsal* branches, which end in the corresponding nuclei.

Communications.—The connexions of the cochlear nerve and its nuclei are links in the chain by which the impressions of sound are carried from the internal ear to the temporal cortex.

PATH OF CONDUCTION OF SOUND.—The neurons implicated are :—

1. Cells of spiral ganglion and their branches (*a*) to the spiral organ and (*b*) to form the cochlear nerve.

2. Cochlear nuclei and the fibres that arise in them to form the auditory striæ and the corpus trapezoideum.

3. Nuclei of corpus trapezoideum and the fibres that arise in

them to form the part of the lateral lemniscus that ends in the medial geniculate body.

4. Medial geniculate body and the fibres that arise in it to form the auditory radiation, which ends in the centre for hearing in the superior temporal gyrus.

1. The first set of neurons has been explained on p. 536.

2. The fibres from ventral cochlear nucleus and a few from the dorsal nucleus pass medially and slightly upwards, intersecting the vestibular nerve, into the substance of the pons to enter the corpus trapezoideum ; as part of that corpus, they cross the median plane and end in the trapezoid nuclei.

Most of the fibres of the dorsal cochlear nucleus curve on to the back of inferior cerebellar peduncle, run medially as auditory striæ, dip forwards through the junction of pons and medulla oblongata near the median plane, cross to the other side, and enter the corpus trapezoideum to end in its nuclei.

3. Fibres arise in the trapezoid nuclei, help to form the corpus trapezoideum, and then pass into the lateral lemniscus. The **lateral lemniscus** is a broad, flat band of fibres that emerges from the groove between superior and middle cerebellar peduncles, extends obliquely upwards and backwards over the surface of the superior peduncle, and disappears under cover of the inferior brachium quadrigeminum. Its fibres end in the inferior corpus quadrigeminum, medial geniculate body and substantia nigra.

Some fibres of the cochlear nuclei may pass through the corpus trapezoideum and enter the lateral lemniscus without relay; and some fibres from the dorsal cochlear nucleus take a shorter and straighter route through the substance of the pons and across the median plane to the opposite half of the corpus trapezoideum.

4. Fibres of the auditory radiation arise in the medial geniculate body, enter the retrolentiform part of the internal capsule, and pass thence to the centre for hearing in the lateral and upper surfaces of the superior temporal gyrus.

Some cochlear fibres that enter the corpus trapezoideum pass into the lateral lemniscus of the same side ; therefore each lateral lemniscus contains fibres from both sides. Inferior corpus quadrigeminum and substantia nigra send fibres to motor nuclei, and are therefore relay stations for reflex acts excited by auditory impressions. Automatic movements of the head and of the eyes, in response to auditory impressions, are instigated also by messages conveyed to the appropriate nuclei, *via* the medial longitudinal bundle, from the trapezoid nuclei.

FOURTH VENTRICLE

Is the cavity of the hind-brain, and is surrounded therefore by cerebellum, pons and medulla oblongata.

Looked at sideways in a median section, it is tent-shaped, with the peak directed backwards between the

medullary vela; but the floor of the tent is diamond-shaped in outline.

It is continuous, at the lower angle, with the central canal of medulla oblongata, and, at the upper angle, with the aqueduct of mid-brain, through which it communicates with the third ventricle. Each lateral angle is at the point where the inferior cerebellar peduncle reaches the pons. There, a narrow pocket of ependyma carries an extension of the cavity, called the **lateral recess,** sidewards over the peduncle, and onwards, behind the glosso-pharyngeal nerve, as far as the flocculus. Near the lateral end of each recess there is a slit in the ependyma and its covering of pia mater. That slit is the **lateral aperture of fourth ventricle.**

The **roof** or posterior wall of the ventricle is concealed by the cerebellum. It is formed chiefly of the medullary vela; but the lowest quarter of the roof consists of ependyma only. In that ependyma and in its covering of pia mater, there is a hole of variable width called the **median aperture of fourth ventricle.**

Through these apertures—a median and a right and left lateral—the cerebro-spinal fluid escapes into the subarachnoid space.

Convoluted bands of vessels called **choroid plexuses**—a right and a left—are developed in the pia mater of the lower slope of the roof, and bulge the ependyma into the cavity. Each of them runs medially from the lateral aperture along the lateral recess and then downwards along the median plane to the median aperture.

The **floor** or anterior wall is the back of the pons and the upper half of medulla oblongata; and under its carpet of ependyma there is a thick layer of grey matter.

On each side, the floor is **bounded** by the gracile and cuneate tubercles, the inferior and superior cerebellar peduncles—named from below upwards.

A **median sulcus** divides the floor into a right and a left half; and each half is divisible into an upper, pontine part, and a lower, medullary part.

At the junction of these two parts, slender cords, called **auditory striæ,** may be visible through the ependyma. They run transversely from the inferior peduncle, at the lateral angle, to the median sulcus; and they belong to the cochlear part of auditory nerve, which has been

seen already—clasping the inferior peduncle.

Low down in the *pontine part*, near the median sulcus, there is a low, round elevation that marks the position of a peculiar bend made by the motor root of the facial nerve around the abducent nucleus.

The *medullary part* of the floor is divided into three triangular areas by the diverging limbs of a Λ-shaped groove called the **inferior fovea** :—

1. **Hypoglossal triangle,** between the fovea and the median sulcus, overlies the upper part of the nucleus of the twelfth nerve.

2. **Vagal triangle,** between the limbs of the fovea, overlies the upper part of the dorsal nucleus of 10th (and 9th).

3. The lower part of the **vestibular area,** between the fovea and the auditory striæ, overlies the medullary part of the medial vestibular nucleus.

ROOF.—The *upper slope* is formed of :—(1) the superior medullary velum ; (2) the superior cerebellar peduncles—for they overhang the cavity as well as form the upper part of the lateral boundaries ; (3) the white matter below the nucleus dentatus.

The *apex* of the roof is the white substance of vermis where the vela are continuous with the core of the cerebellum.

The *lower slope* is more complicated. Its lateral part is formed superiorly of the lateral part of the inferior medullary velum and inferiorly of ependyma alone ; owing to the curvature of the velum, the peak of the lateral part of the roof is curved and points downwards. The median part of the lower slope is formed chiefly of ependyma alone, for the median part of the inferior velum is very short or even absent ; but, at a lower angle, the roof is completed by a small triangular plate of grey matter, called the **obex,** which also forms the posterior boundary of the upper end of the central canal and unites the two gracile tubercles.

A little pocket of ependyma often bulges down behind the obex.

Tela Chorioidea of Fourth Ventricle.—The layer of pia mater that covers the lower part of the roof extends upwards to the root of inferior velum and is there reflected backwards to become continuous with the layer that covers the cerebellum. These two layers of pia mater are closely applied to each other, forming a fold called **tela chorioidea of fourth ventricle.**

The **choroid plexuses** are developed between the layers. The vertical parts of the plexuses bulge the ependyma of the roof inwards into the cavity of the ventricle, and the bulgings protrude again at the median aperture. Their horizontal parts are connected across the median plane. Each of them bulges in the posterior wall of the lateral recess and protrudes again through the lateral aperture, which is on the antero-superior wall of the recess.

FLOOR.—Besides the auditory striæ, inferior fovea and the triangles, the following may be noted.

The elevation alongside the median sulcus is called **eminentia medialis.** Its lower part is the hypoglossal triangle. The rounded swelling at its middle, produced by the loop of the facial nerve and the abducent nucleus, is called the **facial colliculus.**

A shallow depression lateral to the colliculus is called the **superior fovea.** This fovea is continuous superiorly with a shallow groove called the **locus cœruleus** because its floor is dark-blue in colour owing to a patch of dark-coloured grey matter, called **substantia ferruginea,** that underlies the ependyma.

Between the lateral angle and the upper and lower foveæ there is a low, wide elevation, called the **vestibular area** because it is produced by the medial nucleus of the vestibular nerve ; the auditory striæ run across it.

Occasionally a narrow, translucent ridge of ependyma, called **funiculus separans,** can be seen slanting across the lower part of the vagal triangle. The strip between it and the gracile tubercle is called the **area postrema,** and its ependyma overlies the **nucleus postremus,** whose vascularity suggests importance, but its function is not known. Upper lateral part of the hypoglossal triangle is occupied by a circumscribed **nucleus intercalatus,** set between the hypoglossal and vagal nuclei ; its function is not known.

MENINGES OF BRAIN

Brain and spinal cord are enveloped in three fibrous membranes, named, from without inwards, dura mater, arachnoid mater, and pia mater.

Spinal meninges are described on pp. 287-289.

Pia Mater of Brain.—Thin, delicate, vascular sheet of areolar tissue ; closely invests the brain, dipping into all the clefts. Gives sheaths to the cranial nerves as they pierce it. Blood-vessels ramify in it before they sink into the brain-substance ; they carry pial sheaths into the brain-substance with them.

The folds of pia mater called **tela chorioidea** of third and fourth ventricles are described on pp. 489, 539.

Arachnoid Mater of Brain.—Delicate and transparent. Is adherent to pia over the tops of gyri. Bridges across the sulci and all inequalities of the surface of brain, except (*a*) longitudinal fissure, into which it is carried by the falx cerebri, and (*b*) stem of lateral sulcus, into which it is pushed by the lesser wing of sphenoid. Provides sheaths for the nerves as far as their exit from the skull.

Subarachnoid space is the collective name given to the intervals between pia and arachnoid at the sulci. It is

occupied by the larger blood-vessels and a delicate fibrous spongework of *subarachnoid tissue* whose meshes are filled with a liquid, called **subarachnoid fluid,** which is identical with cerebro-spinal fluid.

Subarachnoid space communicates with the cavities of the brain through the apertures in the roof and lateral recesses of the fourth ventricle. The lymph-spaces around the cerebral arteries open into it. It is prolonged into the arachnoid sheaths of nerves, and communicates with their lymph-channels, especially 1st, 2nd, and 8th ; it extends also into the pial sheaths which are carried into the brain-substance by the blood-vessels.

Subarachnoid Cisterns.—Wider intervals between arachnoid and pia mater in which the spongework is scanty. **Cerebello-medullary,** the largest, is the wide interval between the cerebellum and lower part of medulla oblongata. **Interpeduncular** contains the circulus arteriosus. **Cistern of lateral sulcus** contains the beginning of the middle cerebral artery.

Arachnoid villi are protrusions of arachnoid mater filled with subarachnoid tissue and fluid. They bulge into the venous sinuses, pushing and stretching the walls of the sinuses before them. They are microscopic at birth. They increase in size with age and become arachnoid granulations.

Arachnoid granulations are pedunculated, bud-like growths of the size of small peas which bulge into sinuses and even indent the bone. They are most plentiful along the superior sagittal sinus, forming a closely-set row along each side of it, bulging into it and into its lateral lacunæ, and are seen best in the cadavera of aged people.

Cerebro-Spinal Fluid.—A clear, watery liquid, with a yellowish tinge, that fills the cavities of the brain and spinal cord and the subarachnoid space.

Origin.—It is extracted in some way from the blood in the choroid plexuses by the ependyma that overlies the pia mater which encloses the plexuses ; and it is exuded by the ependyma into the ventricles. Most of it is taken from the plexuses in the central part and inferior horn of the lateral ventricles.

Circulation.—From the lateral ventricles it passes through the interventricular foramina into the third ventricle, where additional fluid is added to it from the plexuses in that ventricle. From the third ventricle it descends through the aqueduct into the fourth ventricle and is joined by fluid from the plexuses in its roof and recesses. From the fourth ventricle it escapes through the median and lateral apertures into the cerebello-medullary cistern, and there it receives the fluid from the parts of the choroid plexuses that bulge out through the apertures of the ventricle.

Having reached the subarachnoid space, the fluid spreads slowly upwards to the pons and cerebellum, and, around the mid-brain,

to the lower surface of the cerebrum and thence upwards over the other surfaces of the cerebral hemispheres.

The fluid is returned to the blood-stream by two routes:—

1. A small part of it passes into the arachnoid sheaths of the cranial nerves and is carried away by the perineural lymph-vessels; and ultimately it is carried into the innominate veins by the jugular lymph-trunks.

2. The greater part, having reached the arachnoid villi and granulations, passes through them by osmosis into the venous sinuses.

The subarachnoid space around the spinal cord also is filled with cerebro-spinal fluid and there is a modicum in the central canal. There is, however, no flow up and down apart from what may take place when posture is altered; but some is drained off by perineural lymph-vessels, as in the cranium; and diffusion upwards and downwards probably helps to keep the quality of the fluid constant.

Functions.—An important function depends on the fact that it passes into the pial sheaths that are dragged into the brain and spinal cord by the blood-vessels, and it follows the vessels to their ultimate distribution. In this way the nerve-cells are bathed in cerebro-spinal fluid; the waste-products of their activities pass into the fluid and are removed by diffusion through it.

The fluid has also a mechanical function. It is a liquid buffer; and, by its mobility, pressure on the brain and spinal cord is kept equal at all parts.

Dura Mater of Brain.—*See* p. 49.

SPINAL CORD

Position and Dimensions. — A pliable and almost cylindrical cord of nervous matter, about 18 inches long and half an inch thick. Lies in the upper two-thirds of vertebral canal. Its diameter is much less than that of the canal; the backbone can therefore be bent and twisted this way and that without any strain being put on the cord. Begins at foramen magnum, where it is continuous with medulla oblongata, at the level of mastoid process, and opposite a point midway between inion and spine of axis vertebra. It tapers to end in the small of the back opposite upper border of 2nd lumbar vertebra in the adult, but opposite 3rd lumbar spine (or even 4th) in an infant.

Enlargements.—Spinal cord is of uniform girth in the greater part of its length; but it is thicker towards each end where the large nerves that supply the limbs are attached to it, for there the grey matter of the interior has to be of correspondingly larger amount. These

thicker parts are called enlargements. **Cervical enlargement** begins near upper end, is thickest opposite 6th cervical vertebra, and fades away opposite 2nd thoracic. **Lumbar enlargement** begins opposite 10th thoracic vertebra, is thickest opposite 12th, and then rapidly subsides.

Divisions.—31 pairs of nerves are attached to the spinal cord—8 cervical, 12 thoracic, 5 lumbar, 5 sacral, and 1 coccygeal. They divide it into corresponding regions —**cervical region, thoracic region, etc.** Note (*a*) that cervical and coccygeal nerves are not the same in number as corresponding vertebræ; and (*b*) that the regions do not lie opposite similarly named regions of the vertebral column, for the cord is shorter than the column.

Each nerve is attached by two *roots*—an *anterior*, made of *motor* fibres, and a *posterior*, of *sensory* fibres. The part that gives attachment to the roots of any one pair of nerves is called a segment, and it is named after the nerve—**first cervical segment, second thoracic segment, etc.**

Segments and regions are not marked off from one another in any way except by the attachments of nerve-roots.

Right and **left halves** of the cord are incompletely separated from each other by a fissure, a sulcus, and a septum.

Anterior median fissure is narrow and fairly deep, but its depth is less than a third of the thickness of the cord.

Posterior median sulcus is a mere groove on the back.

Posterior median septum is a thin ribbon of neuroglia that extends forwards from the floor of the sulcus; its depth is half the thickness of the cord.

Substance.—**Grey matter** is in the interior. Has the form of a pair of long, uneven, fluted columns united, across the median plane, by a narrow strip of grey matter, called the **grey commissure,** immediately in front of the median septum. Commissure is tunnelled lengthwise by the **central canal,** which, in cross-sections, is visible to the naked eye as a black speck. The part of each column in front of the commissure is called the **anterior grey column**; it contains nuclei in which the *motor* fibres of spinal nerves arise. The part behind the commissure is the **posterior grey column**; it contains the nuclei in which most of the *sensory* fibres of spinal nerves end. These columns are called **horns** when seen in cross-sections.

The part of each horn that includes its free end is called its *head*, and the rest is its *base*. Head of the posterior grey column is much nearer the surface than the head of the anterior one is ; and the semi-translucent band of grey matter (Λ-shaped in section) that caps the edge of the posterior column is called **substantia gelatinosa.**

The fibres of the anterior roots of spinal nerves arise in the anterior grey column, pass forwards and emerge through a broad, linear strip on the front of each half of the cord. The fibres of the posterior roots arise in the spinal ganglia placed on the posterior roots in the intervertebral foramina ; the fibres enter the cord through the floor of a narrow, linear groove on the back of each half ; most of them end in the posterior grey column, but some are continued upwards to the nucleus gracilis and nucleus cuneatus of the medulla oblongata.

White matter is outside the grey. White matter of each half is almost completely separated from that of the other by the median septum and fissure. It is connected only by a narrow band, called the **white commissure,** which is in front of the grey commissure—between it and the floor of the fissure. In each half, the two grey columns and the two series of nerve-roots divide the white matter into three **white columns—anterior, lateral,** and **posterior.**

Some fibres in the white matter convey ascending impulses, and others descending. Some of them connect the grey matter of the spinal cord with spinal ganglia ; some of them connect it with the brain ; others are association fibres that connect the grey matter of different segments of the spinal cord itself. In each white column, most of the fibres are grouped into bundles called **tracts** (pp. 545, 547). Association or intersegmental tracts are next the grey matter ; sensory tracts are at the surface ; and tracts that descend from the brain are between. But very few of the bundles are sharply marked off from their neighbours ; for their fibres mingle on the way to and from the grey matter in the centre. The tracts are largest and least mingled in the upper part of the cord ; for ascending tracts are almost fully formed, and those that descend from the brain have only begun to send off fibres.

SMALLER FEATURES.—Tapering, lowest part of the cord is called the **conus medullaris.** **Central canal,** surrounded by a little grey matter, is continued down into the filum terminale for a distance of 1 to 3 inches, and then ends blindly; some slender nerve-bundles on the surface of the filum are vestiges of coccygeal nerves.

In the thoracic region, there is a longitudinal ridge on the lateral surface of the grey matter, opposite the grey commissure, called the **lateral grey column.**

In the *cervical region,* the anterior horn is thicker than the posterior; in *thoracic,* both are fairly slender; in *lumbar,* both are fairly thick, and the amount of white matter is relatively small, for descending fibres are nearly all exhausted and ascending fibres are as yet few.

Median fissure is deeper towards its lower end, and the **septum** is less deep, and the two are therefore nearly equal.

Posterior and lateral white columns are definitely separated in their whole depth, for the edge of the posterior grey column almost reaches the surface, and the posterior roots enter along a distinct groove. Anterior and lateral white columns are not marked off from each other at the surface, and the most lateral fibres of anterior nerve-roots are taken as the boundary between them. In the cervical and thoracic regions, the posterior white column is divided into two tracts (*fasciculus gracilis* medially and *fasciculus cuneatus* laterally) by a septum of pia mater whose position is indicated by a shallow, narrow groove on the surface.

Vessels of Spinal Cord.—**Anterior** and **posterior spinal arteries** descend from the cranial parts of the vertebral arteries. Are reinforced by **lateral spinal arteries** from deep cervical, ascending cervical and cervical part of vertebral, from intercostal arteries and from lumbar arteries. Spinal arteries anastomose freely in the pia mater before they send their branches into the cord. These branches carry sheaths of pia mater in with them. In the anastomosing network there are five longitudinal channels—one under cover of the linea splendens, the others in front of and behind the entrance of posterior nerve-roots.

Veins form a tortuous network in the pia mater. In the network there are six main longitudinal channels—in the median plane in front and behind; behind anterior nerve-roots; and behind posterior nerve-roots. Network communicates with the veins of the medulla oblongata and with the veins of the backbone; and, through the internal vertebral plexuses and intervertebral veins, the blood is drained into the vertebral and intercostal veins.

Membranes of Spinal Cord.—*See* p. 287.

Tracts of Spinal Cord

(*See also* pp. 547, 549)

POSTERIOR WHITE COLUMN contains the posterior intersegmental tract, fasciculus gracilis, fasciculus cuneatus and the semilunar tract.

Fasciculus gracilis and **cuneatus** make up nearly the whole column. Lie side by side—gracilis medially along the median septum, and cuneatus laterally. Are made of ascending branches of the fibres of posterior nerve-roots.

Semilunar tract is a small bundle of descending branches of the fibres of posterior nerve-roots. Lies partly in the substance of cuneatus and partly between cuneatus and gracilis.

Posterior intersegmental tract consists of intersegmental fibres and therefore lies close to posterior grey column and commissure.

LATERAL WHITE COLUMN contains :—(1) *Lateral intersegmental tract.* (2) *Ascending tracts*—postero-lateral, posterior and anterior spino-cerebellar, spino-tectal, lateral spino-thalamic, and some unnamed, scattered fibres. (3) *Descending tracts*—lateral cerebro-spinal, rubro-spinal, tecto-spinal, ponto-spinal, olivo-spinal.

Lateral intersegmental tract lies next the grey matter in the concavity bounded by anterior and posterior grey columns.

Postero-lateral tract, a small bundle, at the surface immediately in front of the posterior nerve-roots (or even around them). Its fibres are ascending branches of the fibres of these nerve-roots.

Posterior spino-cerebellar is the band that forms the posterior half of the surface of the lateral white column in front of the postero-lateral tract ; **anterior spino-cerebellar** forms the anterior half.

Spino-tectal is a small bundle that lies deep to the anterior part of the anterior spino-cerebellar. It ends in the opposite superior corpus quadrigeminum.

Lateral spino-thalamic lies deep to the anterior spino-cerebellar (and partly mingled with it), behind the spino-tectal.

Lateral cerebro-spinal is a large well-defined bundle. It lies far back in the lateral white column between the posterior spino-cerebellar and the lateral intersegmental.

Rubro-spinal lies in the centre of the lateral white column, in front of the cerebro-spinal. It arises in the opposite red nucleus.

Tecto-spinal arises in the opposite superior corpus quadrigeminum. Lies in front of the rubro-spinal, between the spino-tectal and the intersegmental.

Ponto-spinal consists of scattered fibres that descend from the nuclei pontis and the dorsal division of the pons to the anterior grey column of the spinal cord.

Olivo-spinal is a small bundle that descends from the olive and other nuclei of the medulla oblongata. Distinct only in cervical region, where it lies at the surface immediately lateral to the anterior nerve-roots. Little is known about it.

ANTERIOR WHITE COLUMN contains the anterior intersegmental, anterior spino-thalamic, vestibulo-spinal, and anterior cerebro-spinal.

Anterior intersegmental is folded round the anterior grey column. Continuous, superiorly, with the medial longitudinal fasciculus of the brain-stem.

Anterior spino-thalamic lies at the anterior surface opposite the head of anterior grey column.

Vestibulo-spinal is placed between the spino-thalamic and the

intersegmental—to a large extent mingled with both of them. It descends from the lateral nucleus of the vestibular nerve.

Anterior cerebro-spinal lies in the side-wall of the anterior median fissure in the upper half of the spinal cord.

ITINERANT TRACTS IN BRAIN AND SPINAL CORD

Itinerant (projection) fibres are, roughly, those that run from above downwards and from below upwards. Some of them carry efferent impulses; the others carry afferent impulses.

Efferent Tracts

Efferent tracts of fibres arise in the cerebral cortex, basal nuclei, cerebellum, and brain-stem. They convey impulses to the nerve-nuclei in the brain-stem and spinal cord, and do so either directly or by relays. The impulses conveyed are for:—1. The initiation and regulation of the activities of voluntary muscles.

2. The supervision of the nuclei of nerves that innervate the secretory apparatus and involuntary muscles.

Varieties of Impulses to Voluntary Muscles.—Some movements carried out by voluntary muscles are gross and extensive; some are fine, skilled and manipulative; and some are rhythmical. Many of these movements are brought about (or are stopped) by a conscious effort of the will; but many of them take place without such effort—some of them having been automatic since birth (*e.g.*, breathing), and others becoming so from frequent repetition (*e.g.*, walking). Even in a simple willed movement, we do not deliberately send out all the necessary impulses. Though we are aware of the action of the prime movers, we are not conscious of the controlled inhibition of the opposers, or of the simultaneous actions of the muscles (1) that fix the bones from which the prime movers arise, (2) that stiffen the other joints over which the prime movers pass, and (3) that co-operate with the prime movers to make the intended movement easier. Nor do we wittingly send out the impulses for an associated movement such as the wrinkling of the forehead that accompanies the voluntary upturning of the eyes. Thus, many of the impulses that bring about an intended act are automatic; and the impulses that regulate muscular tone and promote co-ordination among the muscles are all automatic.

PATHS OF MOTOR IMPULSES.—Fibres that convey efferent impulses are contained:—(1) In the tracts that descend to and from the corpus striatum and substantia nigra; (2) in cortico-pontine bundles; (3) in the three cerebellar peduncles; and (4) in the tracts that descend into the spinal cord.

It is not yet fully known which of the pathways are taken by the different impulses. Many of the pathways have been dealt with sufficiently in the account of the regions in which they lie. Only those that descend into the spinal cord are dealt with in the following paragraphs; and the chief of them is the tract that consists of pyramidal motor fibres.

Pyramidal motor fibres convey the impulses for voluntary

movements. They spring from the large pyramidal cells (Betz's) of the **motor area** in the precentral gyrus and paracentral lobule.

They enter the **corona radiata** and converge upon the internal capsule ; descend, as a compact, flat band, in the *genu* and lentiform part of the *posterior limb* of **internal capsule,** and in the middle three-fifths of the **basis pedunculi** ; through the **basilar part of pons,** where the compact band is broken up into *pyramidal bundles* which re-unite at the lower border of the pons and enter the **medulla oblongata** as the *pyramid.*

70-90% decussate in the lower part of medulla oblongata, and pass down in the **lateral white column** of the opposite half of the **spinal cord** as the *lateral cerebro-spinal tract,* and end around the cells of the **anterior grey column** from which the *motor roots of spinal nerves* arise.

[It has been suggested that they end around cells in the posterior grey column, and that a new relay of fibres arise there and pass to the anterior column. It is possible that, in like manner, the fibres for nuclei of cranial nerves end in intermediary nuclei—*e.g.*, substantia nigra and nuclei pontis—whence the impulses are relayed to the motor nuclei.]

A small number of the remaining 10-30% join the tract that has crossed from the other side ; but the majority of them descend in **anterior white column** of the same side as the *anterior cerebro-spinal tract* ; at different levels, they cross to the other side through the white commissure, and end like those of the lateral tract ; they have all crossed at the level of the mid-thoracic region ; this anterior tract is found only in Man and the higher Apes.

Fibres for the motor nuclei of cranial nerves arise in the lowest part of the **motor area** ; next are those for the upper limb ; then the trunk ; and those for the lower limb arise in the uppermost part of the area, which, owing to the obliquity of the precentral gyrus, is also its most posterior part.

In the **internal capsule,** the fibres for the *cranial nerves* lie in the genu ; those for the *upper limb, trunk* and *lower limb* lie, in that order from before backwards, in the posterior limb of the capsule.

In the **basis pedunculi,** the fibres for the cranial nerves are most medial, and those for the upper limb, trunk and lower limb follow, in that order, medio-laterally. Fibres are sent across to the other side to end in oculomotor and trochlear nuclei, red nucleus and substantia nigra.

In the upper part of the **pons,** fibres are sent across to the motor trigeminal nucleus and the abducent and facial nuclei of the other side ; and, in the **medulla oblongata,** to the motor vago-glosso-pharyngeal nuclei and the accessory and hypoglossal nuclei of the other side.

Tecto-spinal tract carries efferent impulses of visuo-motor reflexes. Arises in the superior corpus quadrigeminum, decussates in the mid-brain in front of the medial longitudinal bundles ; runs downwards, through the tegmentum, pons and medulla oblongata, in front of the medial longitudinal bundle of the opposite side and partly mingled with it ; is displaced laterally by the vestibulo-spinal tract ; and descends to the lower end of the spinal cord in

the lateral white column, giving off fibres that end in the anterior grey column.

Rubro-spinal tract conveys automatic impulses to regulate skilled movements and also the impulses to regulate muscular tone which the red nucleus has received from cerebellum—*via* its superior peduncle. Arises in the red nucleus; decussates in the mid-brain in front of these peduncles, descends through the tegmentum, dorsal part of pons and reticular substance of medulla oblongata, into the spinal cord. In the cord, it descends through the lateral white column, in front of the lateral cerebro-spinal tract; and its fibres end in the base of the anterior grey column.

Ponto-spinal tract probably conveys co-ordinating impulses. Consists of scattered fibres that arise in the nuclei pontis and in the dorsal division of the pons. They descend through the reticular substance into the lateral white column of the cord to end in the anterior grey column.

Vestibulo-spinal tract arises in the lowest part of the dorsal division of the pons from the lateral nucleus of the vestibular nerve. Descends obliquely through the reticular substance to the anterior part of the medulla oblongata, and thence into the spinal cord. In the cord, it lies in the anterior white column, near the surface; its fibres end in the anterior grey column—reaching down to the lumbar region. The vestibular nerve is concerned with equilibration, and, by means of this tract, its nucleus controls those automatic movements of the body which are initiated in response to stimuli that arise in the semicircular ducts of the ear.

Olivo-spinal tract is a small bundle of which little is known. Arises in or near the olive. Descends in the lateral white column, at the surface, near the anterior nerve-roots, and ends in the anterior grey column.

Afferent Tracts

Afferent tracts take up and carry onwards the sensory impressions which the sensory nerves bring to the central nervous system from the various parts of the body.

The sensory impressions are:—(1) The **ordinary sensations**; and (2) those that arise in **special sense** organs—taste, smell, sight, hearing and equilibration.

Ordinary sensory impressions of which we are conscious are *heat*, *cold*, *touch*, *pressure*, *pain*, and an unobtrusive *joint-*, *tendon-* and *muscle-sense* by which even a blind man is aware of the movements of his joints and their passive position (flexed, abducted, etc.) and of the posture and position of his whole body.

Tactile, painful and thermal sensations have been placed in two classes:—

1. **Crude** sensations of touch, pressure, pain, heat and cold; they reach our consciousness in the thalamus: and it is largely upon them that our feelings of mere *comfort* and *discomfort* depend.

2. **Finer** impressions, by which we distinguish among the degrees of intensity of these sensations and localise them exactly; these finer, discriminative impressions have to be carried to the cerebral cortex for our conscious appreciation of them.

Conduction of Impressions of Special Senses.—Tracts that convey impressions of *light*, *taste* and *sound*, and those of the special organ for the maintenance of *equilibrium* are dealt with under the optic tract and the cranial nerves attached to the pons and medulla oblongata. The paths taken by the impressions of *smell* have not yet been fully made out.

Conduction of Ordinary Sensory Impressions.—Nerve-fibres that conduct ordinary sensory impressions arise in spinal ganglia and in the ganglia of cranial nerves, and convey the impressions to the sensory nuclei of nerves in the posterior grey column of the spinal cord, and in the medulla oblongata and pons. From these nuclei, second relays of fibres convey the impressions (*a*) to the cerebellum, (*b*) to certain nuclei in the brain-stem and (*c*) to the cerebrum.

Impressions conveyed to the cerebrum are the only ones of which we are conscious. They are taken first to the thalamus; some of them are felt there; the others are carried by a third relay of fibres to the cortical sensory area.

I. **PATHS FROM TISSUES TO NUCLEI.**—Each ordinary sensory nerve-fibre arises from a ganglion-cell; and, while in the ganglion, it divides into a central branch and a peripheral branch.

Peripheral branches run outwards in the spinal and cranial nerves to be distributed throughout the body. Sensory impressions are received by their terminations; are conducted by them to the ganglia; and are sent on to the central branches.

Central branches of cranial nerves form the sensory roots. They enter the pons and medulla oblongata; and their nuclear connexions are described on pp. 531 *et seq.*

Central branches of spinal nerves form the posterior nerve-roots. They enter the spinal cord through the floor of a narrow groove; each of them divides into an ascending fibre and a descending fibre.

Descending fibres enter the semilunar tract, and soon end in the posterior grey column. It is not known what sensations they convey.

Ascending fibres end partly in the spinal cord and partly in the medulla oblongata. They may be classed into four groups:—

(*a*) A few that run forwards to the motor nuclei in the anterior grey column.

(*b*) Those that form the postero-lateral tract and end in sensory nuclei in the posterior grey column.

(*c*) Those that end in the sensory nuclei of the posterior column—either at once or after a short run in fasciculus cuneatus.

(*d*) The long fibres that form fasciculus cuneatus and gracilis and end in their nuclei in the back of the medulla oblongata.

Sensations Conveyed by these Four Groups.—(*a*) The fibres to anterior grey column convey joint-sense and muscle-sense for short reflexes such as the knee-jerk.

(*b*) The postero-lateral tract lies at the surface immediately in front of the posterior nerve-roots. It consists of slender fibres that ascend only for a short distance before they end in the grey matter. They convey crude sensations of pain and temperature, to be transmitted to the opposite lateral spino-thalamic tract.

(*c*) The other fibres that end in the posterior grey column convey :—

1. Finer sensations of pain and temperature, to be transmitted to the opposite lateral spino-thalamic tract.

2. Crude sensations of touch and pressure, to be transmitted to the opposite anterior spino-thalamic tract.

3. Joint-sense and muscle-sense, to be transmitted to the spino-cerebellar tracts and to scattered fibres that ascend to the brain-stem.

(*d*) Fasciculus gracilis and cuneatus convey two kinds of sensory impulses to the nucleus gracilis and cuneatus :—

1. Finer sensations of touch and pressure, to be transmitted to the opposite thalamus *via* internal arcuate fibres and the opposite medial lemniscus.

2. Joint-sense and muscle-sense, to be transmitted partly to the opposite thalamus (for conscious perception) by the same route, and partly to both halves of the cerebellum *via* external arcuate fibres and the inferior cerebellar peduncles.

II. A. **PATHS FROM NUCLEI TO BRAIN-STEM.**—(1) **Scattered fibres** from sensory nuclei of the spinal cord (and of the brain-stem itself) convey impressions of muscle-sense and joint-sense to the lateral vestibular nucleus, nuclei pontis, red nucleus and substantia nigra, to be reflected in their efferent fibres to the motor nuclei of nerves in order to regulate muscular tone and automatic movements.

(2) **Spino-tectal tract** arises in the posterior grey column, crosses to the other side in the white commissure, ascends in the lateral white column, deep to the anterior spino-cerebellar tract (and partly mingled with it), accompanies it through the reticular substance of the medulla oblongata and the dorsal division of the pons, and enters the mid-brain ; it is joined by fibres from the sensory nuclei of the cranial nerves of the other side ; and it ends in the superior corpus quadrigeminum.

That corpus is a reflex centre. Sensory impressions conveyed to it are reflected into efferent impulses carried by the tecto-spinal tract to the spinal cord, and, by other fibres, to motor nuclei of cranial nerves of the opposite side, by means of which the body and eyes are turned towards the cause of the sensory stimulation.

II. B. **PATHS FROM NUCLEI TO CEREBELLUM.**—Afferent tracts to each half of the cerebellum are :—

(*a*) Spino-cerebellar tracts, from the posterior grey columns.

(*b*) External arcuate fibres from nucleus gracilis and cuneatus of both sides.

(*c*) Fibres from sensory nuclei of cranial nerves, *via* the inferior and middle peduncles.

Cerebellum is the central organ for the automatic regulation of movements and the maintenance of equilibrium ; these tracts and fibres convey to it sensory impressions from joints, tendons and muscles to apprise it of the conditions that call for its controlling efferent impulses.

Arcuate fibres are described on pp. 521, 524, 528.

Posterior spino-cerebellar tract arises in the posterior grey column. It ascends at the surface of the lateral white column in front of the posterior nerve-roots, and it enters the lateral area of the medulla

oblongata, where it can be seen, by the naked eye, passing obliquely upwards and backwards across the spinal tract of the trigeminal nerve to join the inferior cerebellar peduncle. The peduncle carries it into the cerebellum to end in both halves of the superior vermis.

Anterior spino-cerebellar tract arises in both posterior grey columns. It ascends at the surface of the lateral area of the spinal cord and medulla oblongata in front of the posterior spino-cerebellar tract. Half-way up the medulla oblongata, it dips under cover of the olive and ascends in the substance of the medulla oblongata behind the olivary nucleus, and through the dorsal division of pons. At the upper border of the pons, it enters the superior cerebellar peduncle and runs downwards and backwards in it (and in the superior medullary velum) into the cerebellum to end in the cortex of the vermis.

II. C. **PATHS FROM NUCLEI TO THALAMUS.**—Sensations of *pain, heat and cold* are picked up by the **lateral spino-thalamic tract,** and *crude* sensations of *touch* and *pressure* by the **anterior spino-thalamic**—both of which **cross in the spinal cord**. Sensations from *joints, tendons* and *muscles* and *finer* sensations of *touch* and *pressure*, having been carried to nucleus gracilis and cuneatus, are picked up by internal arcuate fibres—which **cross in the medulla oblongata** to form the opposite medial lemniscus. Therefore, in a hemisection of the spinal cord, painful and thermal sensations are lost on the opposite side (below the level of the section) ; joint-sense and muscle-sense are lost on same side ; tactile sensations are wholly lost on neither side, but are partially lost on both.

Spino-thalamic tracts arise in the posterior grey column, and cross in the white commissure to the other side. The **anterior** tract ascends near the surface in the anterior white column, largely mixed with the vestibulo-spinal ; the **lateral** tract ascends in the lateral white column, deep to the anterior spino-cerebellar tract.

In the medulla oblongata, they ascend in the reticular substance behind the medial part of the olivary nucleus. At this level, the anterior tract (which carries tactile sensations) is the nearer to the medial lemniscus (which also is tactile). In the pons, they join the lemniscus ; and they accompany it through the tegmentum and subthalamic region to the thalamus.

In both medulla oblongata and pons, they are joined by fibres from the sensory nuclei of the cranial nerves of the other side.

Fasciculus gracilis and **cuneatus** are large, important tracts, and occupy nearly the whole of the posterior white column of the spinal cord ; but their fibres neither arise nor end in the cord.

Their fibres arise i nthe spinal ganglia and are carried into the cord by the posterior nerve-roots. They ascend in the posterior white column to the back of the medulla oblongata and end in the nucleus gracilis and cuneatus. The nucleus gracilis receives the fibres from the lower limb and the lower half of the trunk ; the nucleus cuneatus receives the fibres from the upper half of the trunk, the upper limb, the neck, and the parts of the head supplied by cervical nerves.

Fasciculus gracilis lies along the posterior median septum ;

fasciculus cuneatus—formed of fibres coming in at successive higher levels—lies along the lateral side of fasciculus gracilis, between it and the posterior grey column.

Internal arcuate fibres arise in the nucleus gracilis and cuneatus. They arch forwards and medially, and cross to the other side in front of the grey matter around the central canal of the medulla oblongata. As they cross, they decussate with the internal arcuate fibres of the opposite side. This decussation takes place farther back than the decussation of the pyramids, and at a higher level. The fibres from the nucleus gracilis (conveying impressions from the lower part of the body) cross at a lower level than those from the nucleus cuneatus. Having decussated, some of the fibres proceed onwards, as external arcuate fibres, to the front of the medulla oblongata, and then join inferior cerebellar peduncle (p. 528); but most of them turn sharply upwards and form the medial lemniscus.

Medial lemniscus is a broad, flat band that lies alongside the median plane of the medulla oblongata, with its surfaces looking medially and laterally. Its posterior edge is related to the tecto-spinal tract and the medial longitudinal bundle; its anterior edge is covered by the pyramid, and is exposed if the pyramid is cut across at its upper end and is pulled away.

As the medial lemniscus enters the pons, it is twisted so that its surfaces look backwards and forwards, and its anterior edge becomes the lateral edge in the pons. It ascends in the most anterior part of the dorsal division of the pons—some fibres of the corpus trapezoideum intersecting it. It can be exposed by the piecemeal removal of one half of basilar division of pons after the following cuts have been made:—(*a*) Two deep vertical cuts—one bisecting the basilar division, and the other close to the medial side of the trigeminal nerve. (*b*) Horizontal cuts, across the lower end of the basis pedunculi and the upper end of the pyramid.

A bundle of the most medial fibres of the lemniscus joins the basis pedunculi; but the bulk of the lemniscus enters the tegmentum behind the substantia nigra—at first in front of the superior cerebellar peduncle, then lateral to it, and finally postero-lateral to it and to the red nucleus. Some fibres end in the superior corpus quadrigeminum, but most of them run up through the subthalamic tegmental region to end in the thalamus.

In the medulla oblongata and pons, fibres are sent to it from the sensory nuclei of the cranial nerves of the other side.

The bundle that leaves the lemniscus to join the basis pedunculi enters the medial side of the basis at the upper border of the pons, curves on to the superficial surface of the basis, runs upwards, and either ends in the lentiform nucleus or runs on in the internal capsule and corona radiata to the cerebral cortex.

III. **PATH FROM THALAMUS TO CORTEX.**—The medial lemniscus and the two spino-thalamic tracts convey to the thalamus those sensory impressions of which we are conscious. They convey them from the opposite half of the body—the fibres of the tracts having crossed in the cord, and the fibres of the lemniscus in the medulla oblongata. Some of the cruder impressions are received

into consciousness in the thalamus. The others are carried to the cerebral cortex by fibres that arise in the thalamus.

These new fibres pass into the internal capsule, where they lie, at first, medial to the motor fibres for corresponding parts of the body; thence, they ascend in the corona radiata to the sensory area —post-central gyrus and paracentral lobule.

Three relays of fibres, therefore, are employed to carry most of the conscious sensory impressions: (1) Fibres of the posterior nerve-roots, which end in the cord and medulla oblongata; and sensory fibres of cranial nerves, which end in the medulla oblongata and pons. (2) Thence, spino-thalamic tracts and medial lemniscus to the opposite thalamus. (3) From thalamus to cortex.

Cruder impressions go no farther than the thalamus; yet, a third relay may be required to take them from a receptive part of the thalamus to a perceptive part of it.

SPINAL NERVES

Arranged in pairs. 8 cervical, 12 thoracic, 5 lumbar, 5 sacral, 1 coccygeal. 1st to 7th cervical leave vertebral canal *above* corresponding vertebræ; 8th cervical *below* the seventh vertebra. 1st thoracic to 4th sacral *below* corresponding vertebræ; 5th sacral and the coccygeal leave through the lower end of the vertebral canal, but their anterior primary rami turn forwards below corresponding vertebræ.

Typical nerve is attached to the spinal cord by two roots: an *anterior* or motor; a *posterior* or sensory, which has a *ganglion* on it. (*See also* p. 289.) Roots unite, immediately lateral to the ganglion, to form the **spinal nerve-trunk**. The trunk gives off a *meningeal branch* to the meninges and vessels of the spinal cord, and then divides into an *anterior* and a *posterior primary ramus*.

Posterior primary ramus passes backwards between transverse processes and divides into a *lateral* and *medial* branch.

Anterior primary ramus sends a *white ramus communicans* to a ganglion on the sympathetic trunk and receives a *grey ramus communicans* from it. It then proceeds sidewards and downwards on a plane in front of the transverse processes. During its course it gives off *muscular branches*; and about half-way on its course it gives off a *lateral cutaneous branch*, which divides into anterior and posterior branches. Finally, it ends as an *anterior cutaneous branch* on the front of the body.

From the division of the spinal nerve-trunk onwards, the typical arrangement is wholly retained only in the thoracic region. Anterior termination is much below the level of the origin of the nerve, but the belt of skin supplied is horizontal or nearly so, owing to the droop of the lateral cutaneous branch and the cutaneous part of the posterior primary ramus.

Posterior Primary Rami.—*See* p. 285.

ANTERIOR PRIMARY RAMI

Larger than posterior rami, except 1st and 2nd cervical. Distributed to the lateral and anterior parts of neck and trunk and to the limbs. Cervical anterior primary rami form the **cervical** and **brachial plexuses**; thoracic form the **intercostal nerves**; lumbar, sacral and coccygeal form **plexuses** of the same names.

CERVICAL NERVES

First runs forwards, lateral to the superior articular surface of atlas, medial to the vertebral artery and rectus lateralis; and descends in front of the transverse process of atlas to join the second.

Second pierces the posterior atlanto-axial membrane—postero-medial to the superior articular surface of the axis vertebra. It then crosses the atlanto-axial synovial joint, and runs sidewards, immediately above the line of that joint, under cover of obliquus inferior. Next, it curves forwards, under cover of the first slips of levator scapulæ and scalenus medius, round the lateral side of the vertebral artery (above the backward bend of the artery) to appear on the front of the artery, where it is joined by the anterior primary ramus of the first cervical nerve, at the medial side of the first slip of scalenus medius. It then descends over the scalenus medius to join the third nerve.

The *other six* appear behind the vertebral artery, and pass sidewards between intertransverse muscles.

Cervical anterior rami form cervical and brachial plexuses, but these *roots* of the two plexuses, before they join each other, receive grey communicating branches from cervical ganglia of sympathetic trunk, and give off muscular twigs.

Grey Rami Communicantes.—To the upper 4, from superior cervical

ganglion; to 5th and 6th, from middle ganglion; to 7th and 8th, from inferior ganglion.

Muscular Branches.—To the muscles of the neck. (*See* p. 348.)

CERVICAL PLEXUS

A looped plexus formed by the anterior primary rami of upper four cervical nerves—which increase rapidly in thickness from above downwards. **First** nerve descends to join the second. **Second** descends to join the third on the front of scalenus medius. **Third** is connected with the fourth by a strong communicating loop that overlaps levator scapulæ; and the **fourth** sends a slender branch down to join the fifth in the brachial plexus.

The plexus is *superficial to* scalenus medius; *deep to* sterno-mastoid, int. jugular vein and the fascia on scalenus medius.

Branches.—Communicating; cutaneous; muscular.

Communicating.—A branch from the first conveys fibres to the hypoglossal; most of these fibres leave the hypoglossal as *descendens hypoglossi* and the *nerves to thyro-hyoid and genio-hyoid* and the *meningeal branch.*

Cutaneous.—Lesser occipital, great auricular, anterior cutaneous of the neck, supraclavicular. (*See* p. 275.)

Muscular.—Descendens cervicalis; phrenic.

N. descendens cervicalis arises from c. 2, 3 by two separate roots which pass downwards and medially over the int. jugular vein; unite and join descendens hypoglossi to form the *ansa hypoglossi.* (*See* p. 298.)

Phrenic Nerve (*see also* pp. 329, 348, 605).—Arises chiefly from c. 4 (with small roots from 3 and 5). Descends over the front of scalenus anterior under cover of its fascia, crossing the muscle from lateral to medial border.

Right nerve leaves scalenus, descends in front of cervical pleura behind the beginning of innominate vein and appears in thorax on the lateral side of innominate vein.

Left nerve leaves scalenus higher up and crosses the first part of subclavian art. to lie between pleura and the end of subclavian vein; passes behind the commencement of innominate vein and enters thorax from under cover of that vein.

Each nerve, having entered the thorax, proceeds to the diaphragm along the medial surface of the pleura a little in front of the root of the lung.

Phrenic nerves contain both **motor** and **sensory** fibres. Give **branches** to pleuræ, pericardium, **diaphragm** (these ramify chiefly on abdominal surface) ; and to vena cava, suprarenal glands, and liver, through communicating twigs sent to the phrenic sympathetic plexuses.

BRACHIAL PLEXUS

Lies (1) in lower part of posterior triangle, (2) behind clavicle, and (3) in axilla. Formed mainly by the anterior primary rami of lower four cervical nerves and greater part of first thoracic ; but the fourth cervical sends a twig to join the fifth, and the second thoracic sends a twig to join the first.

These nerves are the **roots** of the plexus ; they unite to form three **trunks**—upper, middle and lower. Each trunk splits into two **divisions**—anterior and posterior. The divisions are re-arranged and united to form three **cords**—lateral, medial and posterior. The **branches** spring from the roots in the neck and from the cords in the axilla.

5th and 6th unite to form *upper trunk* ; 7th forms *middle trunk* ; 8th and 1st thoracic unite to form *lower trunk*. Trunks divide behind and below clavicle.

Anterior divisions of upper and middle trunks unite to form *lateral cord*. Anterior division of lower trunk forms *medial cord*. All three posterior divisions unite to form *posterior cord*. (1st TH. gives few or no fibres to posterior division.)

Cords arrange themselves, according to name, around the second part of axillary artery ; break up into large nerves at the junction of the second and third parts, opposite the infero-lateral border of pectoralis minor, a finger's breadth below and medial to the tip of the coracoid process.

Relations of the plexus are given on pp. 169, 277.

Branches of Roots.—Root of phrenic from 5th ; Nerves to subclavius, to the rhomboids, and to serratus anterior ; suprascapular.

Nerve to subclavius springs from 5th and 6th at their union ; descends in front of brachial trunks and subclavian vessels, to end in subclavius.

N. to the rhomboids springs from 5th, traverses scalenus medius, descends along the medial border of scapula,

under cover of levator scapulæ, rhomboideus minor and major, supplying all three. (*See also* pp. 173, 277.)

N. to serratus anterior springs from 5th, 6th, 7th—fibres from 5th to the upper part of the muscle, from 6th to the middle part, from 7th to the lower part. (*See also* pp. 169, 278.)

Suprascapular n. springs from 5th and 6th at their union. Runs sidewards and backwards across scalenus medius above brachial trunks; joins suprascapular artery and descends with it through the areolar tissue below trapezius and above serratus anterior and subscapularis to reach the upper border of scapula. Enters supraspinous fossa below suprascapular lig.; divides to supply supraspinatus and infraspinatus, and the shoulder-joint.

Branches of Cords.—*Lateral*: lateral pectoral, musculo-cutaneous, lateral root of median.

Medial: medial pectoral, medial cutaneous nerve of arm, medial cutaneous nerve of forearm, ulnar, medial root of median.

Posterior: Two subscapulars, nerve to latissimus dorsi, circumflex, radial.

Lateral pectoral n. (5, 6, 7 c.; lateral cord) passes forwards to supply pectoralis major.

Medial pectoral n. (8 c., 1 t.; medial cord) passes forwards through pectoralis minor, supplying it, and ends in pectoralis major. (*See also* pp. 169, 170.)

Musculo-cutaneous n. ((4), 5, 6, (7) c.; lateral cord) lies between axillary artery and coraco-brachialis, pierces coraco-brachialis opposite teres major, and descends between biceps and brachialis, supplying them; pierces deep fascia near elbow and becomes **lateral cutaneous nerve of forearm,** which supplies the skin on the front and back of radial side of forearm. (*See also* pp. 169, 183.)

Branch to brachialis sends a twig to the elbow-joint.

Nerve to coraco-brachialis from 7 c. (or 6 and 7 c.) is incorporated in the musculo-cutaneous and leaves it before it pierces coraco-brachialis.

Median n.—*Lateral root* (5, 6, 7 c.; lateral cord) lies on lateral side of axillary art. *Medial root* (8 c., 1 t.; medial cord) passes across the front of axillary art., to join lateral root. Median nerve-trunk lies along lateral side of axillary and brachial arteries as far as middle of

upper arm, crosses brachial art. there, and runs along its medial side to the cubital fossa. Leaves fossa between the two heads of pronator teres. Passes towards wrist between flexor sublimis and profundus, closely adherent to sublimis. Near wrist, it curves round the lateral side of sublimis tendons on to the front of them, and descends behind the flexor retinaculum to enter the palm, where it splits into medial and lateral divisions. (*See also* pp. 170, 183, 191, 198.)

Branches.—None in axilla or in upper arm.

In forearm.—**Muscular** and **articular:** Branches near elbow to pronator teres, flexor carpi radialis, palmaris longus, flexor sublimis. Filaments are sent to the elbow-joint from these muscular branches.

By means of its *anterior interosseous branch* it supplies flexor pollicis longus, pronator quadratus and the lateral half of flexor digitorum profundus, and the wrist-joint, inferior radio-ulnar joint and intercarpal joints.

Cutaneous: *Palmar branch* supplies skin of lateral and intermediate parts of palm.

In palm.—**Muscular**: Thenar muscles and lateral two lumbricals.

Cutaneous: Palmar surfaces of lateral $3\frac{1}{2}$ digits and dorsal surfaces of their middle and distal phalanges.

Ulnar n. (8 C., 1 T.; medial cord) lies between axillary artery and vein; descends along medial side of brachial artery to the middle of upper arm, where it diverges medially and pierces medial intermuscular septum. It runs towards elbow, crosses the back of medial epicondyle and enters forearm between the heads of flexor carpi ulnaris; traverses forearm, lying on flexor profundus. Above the wrist, it pierces the deep fascia and passes on to the flexor retinaculum, where the nerve divides into superficial and deep terminal branches. (*See also* pp. 170, 183, 192, 198.)

Branches.—None in axilla and upper arm.

In forearm.—**Articular**: to elbow.

Muscular: Flexor carpi ulnaris and medial half of flexor digitorum profundus.

Cutaneous: *Palmar branch* to medial third of palm; *dorsal branch* to medial third of back of hand and proximal phalanx of little finger and of half of ring-finger.

In palm.—**Muscular**: Palmaris brevis; three hypo-

thenar muscles; medial two lumbricals; eight interossei; adductor pollicis. **Cutaneous**: Little finger and half of ring-finger on palmar surface and on dorsal surface of their middle and distal phalanges.

Medial cutaneous n. of arm (1 T.; medial cord) passes behind the axillary vein to reach its medial side; pierces deep fascia, and supplies skin of medial side of upper arm.

Medial cutaneous n. of forearm (8 C., 1 T.; medial cord), runs downwards along axillary and brachial arteries to the middle of upper arm, where it pierces deep fascia. Gives a few branches to skin of upper arm. Divides near elbow into two branches to supply skin on front and back of ulnar side of forearm.

Subscapular nerves (5, 6 C.; posterior cord). *Upper* passes downwards and backwards behind medial cord and axillary vein, sinks into subscapularis and sends some filaments to the shoulder-joint. *Lower* runs downwards and sidewards behind the medial cord and axillary vein over subscapularis, supplying it, and, having crossed deep to subscapular vessels, it ends in teres major. (*See also* p. 170.)

N. to latissimus dorsi (6, 7, 8 C.; posterior cord) runs downwards and backwards, crossing behind the medial cord and axillary vein, and it ends in latissimus dorsi. (*See also* p. 170.)

Circumflex n. (5, 6 C.; posterior cord) leaves the axilla by passing backwards through quadrilateral space above the circumflex vessels; gives an *articular* branch to shoulder-joint, and then splits into two.

Posterior division gives branches to teres minor and deltoid, and becomes the *upper lateral cutaneous n. of arm*, which supplies skin over distal half of deltoid.

Anterior division curves around surgical neck of humerus, supplies deltoid and some of the overlying skin. (P. 177.)

Radial n. (5, 6, 7, 8 C., sometimes 1 T.; posterior cord). Descends behind axillary art., and then behind first inch of brachial art.; runs in the spiral groove of humerus to the lateral side; passes forwards through the lateral intermuscular septum, and, descending between brachialis and brachio-radialis, it crosses the capsule of the elbow-joint and enters the forearm.

In the forearm, it descends under cover of brachio-radialis to the distal third of the forearm; it then

inclines backwards, pierces the deep fascia, and runs downwards to the lateral side of the distal end of radius, where it ends by breaking up into diverging branches.

These branches are distributed to the skin of (1) the radial two-thirds of the back of the hand, (2) the radial side of the thenar eminence, (3) the backs of the proximal phalanges of thumb, index, medius and half of annularis. (*See also* pp. 170, 184, 191, 204.)

Branches.—Articular : to elbow, and, through its *posterior interosseous* branch, to wrist-joint and carpal joints.

Muscular : directly from its trunk—to triceps, anconeus, brachialis, brachio-radialis, extensor carpi radialis longus ; and, through the *posterior interosseous*, to the muscles of the back of the forearm.

Cutaneous (pp. 170, 180, 204) : to the back and lateral side of upper arm and back of forearm, and back of hand and digits.

Posterior interosseous arises from the radial a little above the elbow-joint. Passes through the supinator to the back of forearm and descends in it to end as *articular* branches to the wrist-joint, inferior radio-ulnar joint and intercarpal joints. (*See also* p. 208.)

Its *muscular* distribution is to :—supinator, extensor carpi radialis brevis, extensor digitorum, extensor digiti mimini, extensor carpi ulnaris ; abductor pollicis longus, extensor pollicis longus and brevis, and extensor indicis.

THORACIC NERVES

Anterior primary ramus of a typical thoracic nerve is an **intercostal nerve.** It emerges from an intervertebral foramen, gives a white ramus communicans to sympathetic trunk and receives a grey one from it.

It enters intercostal space and runs, below the vessels, between pleura and posterior intercostal membrane as far as the angle of the rib, where it slips in between ext. and int. intercostal muscles. It pierces the internal intercostal gradually, so that on front of chest it is behind internal intercostal. At the side of sternum it turns forwards through internal intercostal muscle, anterior intercostal membrane, pectoralis major and deep fascia, to end as a cutaneous nerve on front of chest.

At the back of the chest, as far as angle of rib, it lies a little below the rib, and is encountered when the intercostal space is opened from the back. On the side of the chest, it is under shelter of the lower edge of the rib.

It gives off *muscular branches*; less than half-way round, it gives off a *lateral cutaneous branch*; its terminal part is called the *anterior cutaneous branch*.

Only four of them are wholly typical—3, 4, 5 and 6.

First joins brachial plexus; but it gives off a small **intercostal nerve,** which has no lateral cutaneous branch, and sometimes no anterior cutaneous branch.

Second to eleventh are **intercostal.**

Second is peculiar in that its lateral cutaneous branch runs to the upper arm. It also sends a communicating branch to the first.

Third, fourth, fifth and **sixth** are typical.

Seventh to **eleventh** run part of their course in abdominal wall (p. 368).

Twelfth is **subcostal** and runs nearly its whole course in abdomen.

Distribution.—*See* p. 353.

LUMBAR NERVES

Anterior primary rami of lumbar nerves receive grey rami communicantes from sympathethic trunk; and first and second send white rami to it.

Upper four give branches to quadratus lumborum (from all 4), psoas major and iliacus (from 2, 3, 4), and psoas minor (1); and divide into a number of cords which cross one another, forming the *lumbar plexus*, as they are rearranged and re-unite to form the named nerves of that plexus. The fourth also sends a *descending branch* to unite with the fifth to form the lumbo-sacral trunk, which forms part of the sacral plexus.

LUMBAR PLEXUS

Formed by anterior primary rami of upper three lumbar and part of the fourth, and receives a communicating branch from the subcostal. It lies in the substance of psoas major, on the fronts of lumbar transverse processes. (*See also* pp. 379, 380.)

The nerves that arise from the plexus are ilio-hypogastric, ilio-inguinal, genito-femoral, lateral cutaneous, obturator, femoral.

Ilio-hypogastric and **ilio-inguinal Nerves.**—*See* p. 369.

Genito-femoral n. (1, 2 L.) pierces psoas major, descends over its anterior surface; divides into two:—(1) **Genital branch** runs downwards over external iliac art., passes through the deep inguinal ring, and supplies cremaster or lig. teres uteri. (2) **Femoral branch** descends along lateral side of ext. iliac and femoral arteries, pierces deep fascia to supply skin of proximal part of front of thigh. (*See also* pp. 218, 380.)

Lateral cutaneous n. of thigh (2, 3 L.) appears at lateral border of psoas; runs across iliacus to anterior superior iliac spine; enters thigh behind the lateral end of inguinal ligament, and supplies skin of buttock and antero-lateral surface of thigh. (*See* pp. 211, 380.)

Obturator n. (2, 3, 4 L.) emerges through the postero-medial margin of psoas at the back part of the pelvic brim, and passes into the pelvis. Runs downwards along side-wall of pelvis near the brim, in front of obturator vessels. Leaves pelvis through the anterior part of obturator foramen, and divides in the foramen into two branches. (*See also* pp. 234, 381, 387.)

Branches.—*Muscular*: to obturator externus; gracilis, adductor longus, brevis and magnus.

Articular: to hip-joint and knee-joint.

Vascular: to femoral artery.

Cutaneous (occasional): to skin of medial side of thigh through subsartorial plexus (p. 219).

Accessory obturator nerve (3 L. or 3 and 4 L.), only occasionally present (29 per cent.). Descends along the medial border of psoas, enters the thigh in front of the superior ramus of pubis. May end in pectineus or in hip-joint, or may be a substitute for the obturator nerve to a varying extent.

Femoral n. (2, 3, 4 L., behind origin of obturator) appears at the lateral border of psoas below iliac crest; gives branches to psoas and iliacus; descends between them; leaves abdomen behind inguinal ligament, and breaks up into branches about an inch below inguinal lig.

Branches in Thigh.—*Muscular* and *articular*: pectineus, sartorius, rectus femoris, all three vasti, and articularis genu. Branch to rectus femoris supplies hip-joint. Branches to vasti are continued to knee-joint.

Cutaneous: *intermediate cutaneous* to lower two-thirds

of front of thigh and front of knee; *medial cutaneous* to lower two-thirds of front and medial side of thigh, front of knee and upper part of medial side of leg; *saphenous* to front of knee, medial side of leg and hinder half of medial side of foot.

Lumbo-Sacral Trunk.—A thick cord formed by the whole anterior primary ramus of L. 5 and the descending branch of L. 4. Runs downwards and sidewards over ala of sacrum (grooving the bone slightly) and passes into the pelvis, where it runs sidewards and backwards across the upper part of pelvic surface of sacro-iliac joint to join the anterior primary ramus of the first sacral nerve. (*See also* pp. 381, 387.)

SACRAL AND COCCYGEAL NERVES

Anterior primary rami receive grey rami communicantes from sympathetic trunk.

Fifth sacral and **coccygeal** are described on pp. 387, 388.

Upper four sacral emerge through the anterior sacral foramina and soon unite with one another and with lumbo-sacral trunk to form the *sacral plexus*; but the 4th sends a branch down to join the 5th in the *coccygeal plexus*.

SACRAL PLEXUS

Formed by lumbo-sacral trunk and anterior rami of upper three sacral nerves and part of fourth.

These roots of the plexus converge upon lower part of greater sciatic foramen, uniting with one another; and the plexus ends in two terminal nerves, called sciatic and pudendal. The other nerves spring from the back and the front of it. The upper part of the plexus lies on the sacrum and sacro-iliac joint; the lower part on piriformis. (*See also* p. 388.)

Divisions.—Lumbo-sacral trunk and 1, 2 and 3 S. split into dorsal and ventral divisions. *Dorsal divisions* give rise to nerves to piriformis, gluteal nerves, perforating cutaneous, upper roots of posterior cutaneous and lateral popliteal part of sciatic; *ventral divisions* give rise to pelvic splanchnic nerves, to nerves for quad. fem. and obt. int., lower roots of posterior cutaneous, upper roots of pudendal and medial popliteal part of sciatic.

Nerves that spring from the Front of Sacral Plexus.—Pelvic splanchnic, and nerves to quad. fem. and obt. int.

Nerve to quadratus femoris (4, 5 L., 1 S.) leaves pelvis below piriformis and descends to supply the hip-joint, inferior gemellus and quadratus femoris.

Nerve to obturator internus (5 L., 1, 2 S.) leaves pelvis through greater sciatic foramen below piriformis; supplies gemellus superior, and enters ischio-rectal fossa through lesser sciatic foramen to supply obturator internus—entering it on its perineal surface.

Pelvic splanchnic (2, 3, 4 S.) pass to the sympathetic plexuses and are distributed by them to viscera.

Nerves that spring from the Back of Sacral Plexus.—Branches to piriformis, coccygeus and levator ani; sup. and inf. gluteal; posterior cutaneous; perforating cutaneous (pp. 222, 389); perineal of 4 S. (pp. 389, 394).

Nerves to piriformis from 1 and 2 S.; to **coccygeus** and **levator ani** from 3 and 4 S.

Superior gluteal n. (4, 5 L., 1 S.) leaves pelvis through greater sciatic foramen, above piriformis; extends sidewards and forwards between gluteus medius and minimus, supplying them, and ends in tensor fasciæ latæ.

Inferior gluteal n. (5 L.; 1, 2 S.) leaves pelvis below piriformis, on the posterior surface of sciatic nerve or along its medial side, and supplies gluteus maximus.

Posterior cutaneous n. of thigh (1, 2, 3 S.) leaves pelvis with inferior gluteal. Passes downwards under cover of gluteus maximus; then, along middle of back of thigh, under the deep fascia, to the back of the knee; there, it pierces popliteal fascia and descends in superficial fascia of back of leg as far as middle of calf. (*See also* p. 229.)

Branches: To skin of—(1) lower part of buttock; (2) perineum and external genital organs (by a *perineal branch*); (3) back and medial side of thigh; (4) upper half of calf.

Terminal Branches of Sacral Plexus.—Pudendal (p. 403) and sciatic.

Sciatic nerve (4, 5 L.; 1, 2, 3 S.) leaves pelvis through greater sciatic foramen, between its lower margin and piriformis; traverses gluteal region and upper part of thigh and ends at middle of thigh by dividing into lateral and medial popliteal nerves. (*See also* pp. 225, 388.)

Direct Branches.—To semitendinosus, semimembranosus, long head of biceps and adductor magnus (from its medial popliteal part); to short head of biceps (from its lateral popliteal part). No articular or cutaneous branches arise from its trunk.

When the two terminal branches of sciatic arise directly from the sacral plexus, the medial popliteal nerve appears below piriformis, but the lateral popliteal pierces it. When this occurs, the posterior cutaneous also is divided; ventral part (2, 3 S.) accompanies the medial popliteal; dorsal part (1, 2 S.) accompanies the lateral popliteal.

Lateral popliteal n. (4, 5 L.; 1, 2 S.). Begins at the middle of back of thigh; enters popliteal fossa through its upper angle; proceeds along the medial side of biceps; passes through the lateral angle of the fossa, and on to the back of head of fibula; enters the substance of peroneus longus on the lateral side of neck of fibula, where it divides into terminal branches—anterior tibial and musculo-cutaneous. (*See also* p. 232.)

Branches.—Lateral cutaneous, of calf; sural communicating; genicular (including recurrent); terminal branches.

Lateral cutaneous n. of calf arises in fossa; supplies skin on antero-lateral part of upper half of leg.

Sural communicating branch pierces deep fascia and joins the sural branch of the medial popliteal.

Two lateral genicular branches supply the lateral part of the knee-joint.

Recurrent genicular nerve arises at termination of lateral popliteal; supplies tibialis anterior and superior tibio-fibular joint and knee-joint.

Musculo-cutaneous n. emerges from peroneus longus, descends into the distal third of the leg, where it pierces the deep fascia and divides into two branches which proceed into the foot. (*See also* p. 244.)

Branches.—*Muscular* to peroneus longus and brevis from the trunk. *Terminal branches* supply skin in distal third of leg and in dorsum of foot and on the toes.

Anterior tibial n. emerges from peroneus longus and descends through the front of the leg to the dorsum of foot, where it divides into medial and lateral branches.

Branches.—*Trunk* supplies extensor digitorum longus, peroneus tertius, ext. hallucis longus, tibialis anterior, ankle-joint. *Medial branch* runs forwards to supply skin of contiguous sides of first and second toes. *Lateral branch* turns laterally and ends under ext. digitorum brevis by supplying it and neighbouring joints. (*See also* p. 243)

Medial popliteal n. (4, 5 L.; 1, 2, 3 S.). Begins at the middle of back of thigh; traverses the popliteal fossa and ends at the distal border of popliteus by becoming the posterior tibial. (*See also* p. 230.)

Branches.—1. *Muscular* branches to both heads of gastrocnemius, plantaris, soleus and popliteus.

2. Three *genicular* branches to the knee-joint.

3. *Sural n.*, a cutaneous nerve, runs downwards in the calf and then forwards along the lateral border of the foot to the little toe.

Posterior tibial n. is the continuation of the medial popliteal into the leg. It begins at the distal border of the popliteus and descends through the leg to end under cover of the flexor retinaculum by dividing into the lateral and medial plantar nerves. (*See also* p. 249.)

Branches.—(4) *Muscular* to soleus, tibialis posterior, flexor hallucis longus and flexor digitorum longus.

(5) *Articular* to ankle-joint.

(6) *Median calcanean* pierce the flexor retinaculum to supply the skin of the back and the sole of the heel.

Medial plantar n. (*see also* p. 255) corresponds to median in hand. Gives four *digital* branches—to the medial side of big toe and contiguous sides of big toe and next three; *cutaneous* branches to medial part of sole; *muscular* to abductor hallucis and flexor digitorum brevis from its trunk, to flexor hallucis brevis from its first digital branch, and to the first lumbrical from its second digital branch.

Lateral plantar n. (*see also* p. 256) corresponds to ulnar nerve in hand. It accompanies lateral plantar artery to base of fifth metatarsal, where it divides into superficial and deep branches. From its trunk it supplies flexor digitorum accessorius and abductor digiti minimi, and the skin of the sole. *Superficial branch* supplies flexor digiti minimi brevis, third plantar and fourth dorsal interossei, skin of the sole and lateral side of little toe and the

contiguous sides of fourth and fifth toes. *Deep branch* accompanies plantar arch, and supplies remaining interossei, adductor hallucis and lateral three lumbricals.

CRANIAL NERVES

Olfactory Nerve (1st, special sense).—About 20 separate filaments ensheathed in meningeal tubes. Their fibres arise from cells in olfactory mucous membrane of upper part of nose. In the mucous membrane, the fibres form plexuses from which the nerves pass through cribriform plate of ethmoid to end in olfactory bulb (pp. 465, 484).

Optic Nerve (2nd, special sense).—Begins at eyeball, passes backwards through optic foramen and joins chiasma. Fibres arise in retina and are spread out on its inner surface; converge and pierce retina, choroid and sclera 1 mm. below and 3 mm. medial to posterior pole of eyeball. At chiasma some fibres enter optic tract of same side; remainder cross in chiasma to the other tract. (*See also* pp. 69, 513.)

Oculomotor Nerve (3rd).—*Motor* to most of muscles of orbit and eyeball. Fibres arise in grey matter around aqueduct of mid-brain (p. 511); arch forwards through tegmentum; emerge through medial sulcus of mid-brain, pierce pia mater and combine to form the nerve-trunk. The nerve passes downwards, forwards and sidewards in interpeduncular cistern; pierces arachnoid and the dura mater of roof of cavernous sinus; runs forwards in lateral wall of sinus; divides into an upper and a lower branch which enter orbit through superior orbital fissure. (*See also* pp. 58, 70.)

Relations. — **In interpeduncular cistern,** at first the posterior cerebral artery is above it and superior cerebellar is below it, and it then passes between posterior communicating artery and medial side of uncus. It **pierces arachnoid** and **dura mater** lateral to posterior clinoid process, in the angular interval bounded by the margins of tentorium after they have crossed each other. **In cavernous sinus,** it lies above the other nerves in its lateral wall, receives communicating filaments from ophthalmic nerve and from the sympathetic plexus around internal carotid; near the anterior end of sinus, it is crossed, on its lateral side from below upwards, by the trochlear nerve.

Trochlear Nerve (4th).—*Motor* to superior oblique of orbit.

Slenderest of cranial nerves. Arises in grey matter of aqueduct (p. 511); passes downwards and backwards in mid-brain; **crosses median plane**; emerges through upper part of superior medullary velum; pierces pia mater; curves laterally across superior cerebellar peduncle, and then forwards round side of mid-brain; appears at base of brain between posterior cerebral and superior cerebellar arteries; pierces arachnoid and dura mater at the point where attached and free borders of tentorium cross each other; courses forwards in lateral wall of cavernous sinus, below oculomotor; receives filaments from ophthalmic and sympathetic; crosses oculomotor from below upwards on its lateral side; passes through superior orbital fissure, above rectus lateralis; crosses medially, above levator palpebræ, and sinks into the upper border of obliquus superior near its origin.

Trigeminal Nerve (5th).—Wide distribution (p. 58), by means of its three divisions—*ophthalmic* (p. 59), *maxillary* (p. 310) and *mandibular* (p. 307).

Abducent Nerve (6th).—*Motor* to rectus lateralis of orbit. Almost as slender as trochlear. (*See* pp. 58, 61, 70.)

Arises from a nucleus low down in back of pons (p. 532); passes forwards through the whole thickness of pons to emerge through its lower border at upper end of lateral margin of pyramid; pierces pia mater; curves upwards behind anterior inferior cerebellar artery; passes upwards, forwards and sidewards in subarachnoid space between pons and clivus of skull; pierces arachnoid and inner layer of dura about midway between jugular tubercle and posterior clinoid process; continues upwards, forwards and slightly sidewards between the layers of dura, crossing inferior petrosal sinus to reach medial end of upper border of petrous temporal; there, it crosses the petro-sphenoid joint beneath a slender fibrous band (*petro-sphenoid lig.*, which sometimes is ossified); curves round the lateral side of ascending part of internal carotid and enters cavernous sinus; runs forwards along lateral side of horizontal part of internal carotid in lateral wall of sinus, receiving filaments from ophthalmic nerve and sympathetic, and enters orbit through superior orbital fissure, between heads of rectus lateralis, below oculomotor and nasociliary nerves, above ophthalmic veins; runs forwards along ocular surface of rectus lateralis, and enters its substance.

Facial Nerve (7th).—*Motor* to stapedius, stylo-hyoid, posterior belly of digastric, and muscles of scalp, auricle and face (including buccinator and platysma). *Secretory* to the lacrimal and salivary glands. *Sensory* (taste) to tongue and palate. Has a motor and a sensory root.

Motor root is the main part, and includes the secretory

fibres. Arises in pons (p. 532). After a devious course in pons, it emerges through lower border of pons close to the inferior cerebellar peduncle. Passes into internal auditory meatus with the auditory nerve. At the far end of meatus it enters a bony canal which conducts it through the substance of temporal bone—first sidewards above internal ear, then backwards in medial wall of middle ear, and then downwards behind middle ear—to stylo-mastoid foramen, where it leaves skull.

The nerve then curves forwards round the lateral side of the styloid process and internal jugular and sinks into the parotid gland, where it divides into terminal branches that pierce the deep fascia and radiate from the ends and anterior border of parotid.

Its first bend (where it reaches middle ear) is called its **genu**; and its **ganglion** is placed on the bend.

Branches outside Skull.—All muscular. (1) Nerves to stylo-hyoid and posterior belly of digastric (p. 301). (2) Posterior auricular (p. 261). (3) Terminal (p. 265).

Sensory Root.—Sensory fibres arise in the ganglion and split into central and peripheral branches. *Peripheral branches* are distributed by petrosal nerves and chorda tympani. *Central branches* run inwards in facial nerve, detach themselves at bottom of internal meatus to form the **sensory root,** which runs to lower border of pons between facial and auditory nerves, and ends in a nucleus in medulla oblongata. At the lower border of the pons, it is imbedded in the surface-neuroglia, and it is therefore inconspicuous.

Relations of Facial N.—Its roots pierce pia mater at lower border of pons, carrying off sheaths; they accompany the auditory nerve to int. meatus, lying above it. At first, they ascend a short distance, behind the anterior inferior cerebellar artery, and then run sidewards, above flocculus, between the middle cerebellar peduncle and petrous temporal, to reach the meatus. At the lateral end of meatus the two roots unite, and the nerve-trunk pierces arachnoid and dura, passes through a small hole in the bone and enters the canal in which it runs its course in skull. At first, the canal passes sidewards across the roof of vestibule of internal ear to reach the anterior part of the medial wall of middle ear. There, it makes a right-angled bend (*genu*), and runs backwards in the medial wall of middle ear to the aditus ad antrum, making a rounded ridge just above fenestra vestibuli—and also in lowest part of medial boundary of the aditus, below lateral semicircular canal. There, it bends again to descend vertically behind middle ear, in front of the sigmoid sinus, to reach the stylo-mastoid foramen.

On its exit from skull, the posterior belly of digastric is *behind* and

below it, rectus lateralis and internal jugular are *medial*, parotid gland is *anterior* and *lateral*.

After a short descent, it curves forwards round the lateral side of styloid process (which, there, separates it from internal jugular), sinks into parotid, in whose substance its terminal branches spread forwards superficial to posterior facial vein and external carotid artery, or between vein and artery.

Branches in Facial Canal.—Greater superficial petrosal and a root of lesser petrosal (p. 60); nerve to stapedius; chorda tympani.

Nerve to stapedius arises behind middle ear, and runs forwards to enter stapedius at once.

Chorda tympani is given off a short distance above stylo-mastoid foramen; ascends and enters middle ear through posterior wall; runs forwards, opposite upper edge of tympanic membrane, on medial side of neck of malleus; leaves in front of upper part of membrane; appears at medial end of squamo-tympanic fissure; runs downwards and forwards on medial side of spine of sphenoid and on medial side of pterygoideus lateralis, and joins lingual. Chorda contains taste-fibres which are carried by lingual to anterior two-thirds of tongue, and secretory fibres for submandibular and sublingual glands which are relayed in submandibular ganglion.

Communications.—1. Sensory root with vestibular nerve.

2. Greater superficial petrosal with tympanic plexus.

3. *Ext. petrosal n.* from sympathetic plexus around middle meningeal artery runs along greater superficial petrosal to join the ganglion.

4. Twig to join auricular branch of vagus arises near chorda.

5. Chorda with otic ganglion.

6. Trunk with IX nerve near stylo-mastoid foramen.

7. Posterior auricular with great auricular, lesser occipital and auricular branch of vagus.

8. Terminal branches (*a*) in parotid with one another and with great auricular and auriculo-temporal; (*b*) in face, very freely with one another and with branches of trigeminal.

Auditory N. (8th).—Special sense. (*See* pp. 523, 535.)

Glosso-Pharyngeal Nerve (9th).—*Motor* to stylo-pharyngeus. *Secretory* to parotid. *Sensory* to middle ear and its extensions, to pharynx, and to posterior third of tongue (taste as well as common sensation).

Attached by a row of 4 or 5 roots to upper end of medulla oblongata in front of inferior cerebellar peduncle.

Motor and **secretory** fibres arise in medulla and emerge in the roots. **Sensory** fibres arise in two small *anglia* (*upper* and *lower*) placed on the nerve-trunk in jugular foramen; divide into central and peripheral branches. *Peripheral* branches run on into the branches of the nerve; *central* branches pass into the roots to end in nuclei in medulla (p. 533).

From medulla, the nerve passes to jugular foramen, and through it into neck.

Relations in Skull.—Roots pierce pia mater, and unite to form a single trunk which passes sidewards, in front of flocculus, across jugular tubercle, to reach jugular foramen, where it pierces arachnoid and dura at the notch on anterior margin of jugular foramen directly below internal meatus. Traverses jugular foramen, lodged in a groove on petrous temporal immediately in front of jugular fossa, enclosed in its own sheath of dura, antero-lateral to vagus and accessory, which separate it from inferior petrosal sinus.

Enters neck ; its chief relations there are given on p. 341.

Branches and **Tympanic Plexus.**—*See* pp. 341, 342.

Vagus Nerve (10th).—Widespread distribution. *Motor* to musculature of heart, trachea, bronchi and a great part of alimentary tract. *Secretory* to glands of alimentary tract and to liver, pancreas and kidney. *Sensory* to dura mater, external auditory meatus, respiratory and alimentary organs (including *taste* to epiglottis).

Attached to the side of medulla oblongata below glosso-pharyngeal by a row of roots. Leaves skull by jugular foramen. Has two *ganglia* on its trunk—*upper*, in jugular foramen ; *lower*, immediately below skull.

Motor and secretory fibres arise in medulla oblongata, and emerge in the roots. **Sensory fibres** arise in the ganglia, and each divides into a central and a peripheral fibre. *Peripheral* fibres run on in the branches of the nerve. *Central* fibres run into the roots, and end in medulla oblongata (p. 533).

The roots unite and the nerve passes to jugular foramen, where the cranial root of accessory nerve blends with it. Descends through neck in carotid sheath, behind and between carotid arteries and internal jugular vein. At root of neck, it passes in front of subclavian artery and enters thorax. Descends in superior mediastinum along the side of trachea (the left also crossing left side of aortic arch), and reaches the back of the bronchus, where it breaks up into a network called *posterior pulmonary plexus*. From that plexus, it emerges again as one or more cords which pass to the œsophagus—the left on the front, the right on the back—and break up again to form a network, called *œsophageal plexus*, around œsophagus in posterior mediastinum. From that plexus, the two *gastric nerves* (*anterior* and *posterior*) emerge ;

they descend with œsophagus through the opening in diaphragm—one on the front and the other on the back, each containing fibres of both vagi—and are distributed to abdominal viscera with the sympathetic nerves.

Relations at Skull.—Roots pierce pia mater, pass behind vertebral artery, and unite to form the nerve-trunk—a flat band that passes sidewards, with 9th and 11th nerves, in front of flocculus, across jugular tubercle (sometimes grooving it), to reach jugular foramen. There, it pierces arachnoid and dura mater; descends through the foramen, between sigmoid and inferior petrosal sinuses, postero-medial to glosso-pharyngeal, and enclosed in a dural sheath with accessory. Immediately below skull, where internal carotid is in front of internal jugular, the nerve lies in the medial part of the interval between vein and artery. Hypoglossal nerve, at first medial to vagus below skull, twists round it—first behind it, then lateral—to gain the front of it; and is adherent to it on the lateral side.

Further relations of vagus in neck and in thorax are given on pp. 329, 342, 606, 609.

Branches.—Meningeal; auricular; pharyngeal; superior laryngeal; cardiac; recurrent laryngeal; anterior pulmonary; and branches from its plexuses.

The branches that arise **in the neck** are described on pp. 343, 344.

Cardiac Branches.—Two arise in the neck (p. 344); and one or more spring from the right vagus in the superior mediastinum and run down along the trachea to the deep cardiac plexus.

Anterior pulmonary are two or three branches that arise from vagus above root of lung and enter the anterior pulmonary plexus.

Communications of Vagus.—1. *By its trunk or its ganglia*: (*a*) With hypoglossal. (*b*) With accessory. (*c*) With glosso-pharyngeal. (*d*) With superior cervical ganglion of sympathetic trunk. (*e*) With first cervical.

2. *By auricular branch*: With facial, tympanic and posterior auricular.

3. *By its plexuses.*

Plexuses of Vagus.—Pharyngeal (p. 344), cardiac (p. 579), pulmonary, œsophageal, gastric. Efferent fibres of vagus to glands and involuntary muscle of viscera and vessels are relayed in minute ganglia in the plexuses.

Pulmonary plexuses supply the structures of the lung-root, and send branches into lung to supply its substance and the pulmonary pleura. **Anterior** lies on front of root. Formed by anterior pulmonary branches, supplemented by fibres from cardiac plexus. **Posterior**—much larger—lies on back of root. Formed by trunk of vagus breaking into a network; supplemented by filaments from 2nd, 3rd and 4th thoracic ganglia of sympathetic trunk.

Œsophageal plexuses surround œsophagus in thorax; supply it and the back of pericardium. Formed, *in superior mediastinum*, by branches of right vagus and left recurrent laryngeal and of upper

thoracic ganglia of sympathetic trunks; *in posterior mediastinum*, by both vagi, after their escape from posterior pulmonary plexuses, and by branches from splanchnic nerves.

Gastric plexuses lie on front and back of stomach, and each contains fibres of both vagi. **Anterior** is formed by the *anterior gastric nerve*; it supplies the stomach, and sends branches to the duodenum, liver and pancreas. The *posterior gastric nerve*, when it enters the abdomen, splits into two branches. One branch forms the **posterior gastric plexus** on the back of the stomach. The other branch ends in the cœliac plexus, whence its fibres are sent to—stomach and intestines; liver, pancreas and spleen; kidneys and suprarenal glands.

Accessory Nerve (11th).—Motor. Two portions:—(1) A *cranial root*, accessory to vagus, from medulla oblongata, to supply the musculature of a great part of the alimentary and respiratory tracts. (2) A *spinal root*, from spinal cord, to supply sterno-mastoid and trapezius.

Fibres of **spinal root** arise in the anterior grey column behind the upper 5 cervical nerves (p. 534); emerge from the side of spinal cord; unite to form one or two cords which ascend through foramen magnum, and turn sidewards to jugular foramen. Fibres of **cranial root** arise in medulla oblongata from the lower part of *nucleus ambiguus*; emerge as a vertical row of bundles through the side of medulla oblongata below vagus; run sidewards to jugular foramen, and join the spinal root.

The accessory nerve, so formed, pierces arachnoid and dura, and enters jugular foramen in company with vagus.

In the jugular foramen, its two roots separate again:—

(1) **Cranial root** communicates with the upper ganglion of the vagus, and joins the vagus at the lower ganglion and is distributed by the vagus (*q.v.*).

(2) **Spinal root** is commonly referred to, in the neck, as the *accessory nerve*. (*See* p. 276.)

Hypoglossal Nerve (12th).—*Motor* to muscles of tongue.

Fibres arise in medulla oblongata (p. 534) from a long nucleus that lies in grey matter around central canal and in floor of fourth ventricle; emerge as a vertical row of bundles between olive and pyramid. Bundles unite to form two cords, which pass through separate apertures in arachnoid and dura mater, and unite at the external orifice of the anterior condylar canal.

The nerve enters the neck, descends between internal carotid and internal jugular into the carotid triangle; then, forwards through the carotid triangle into the

ubmandibular region, and through it to reach the ongue. (*See* pp. 298, 320, 345.)

Branches of Hypoglossal Nerve.—*See* pp. 345, 346.

Communications of Nerve-Trunk.—1. With the lower ganglion of agus.

2. With superior cervical ganglion.

3. Fibres from C.1 join it and leave it as its meningeal branch, escendens hypoglossi and nerves to thyro-hyoid and genio-hyoid.

4. With pharyngeal plexus, by the lingual branch of vagus.

5. With the lingual, at the anterior border of hyo-glossus.

AUTONOMIC NERVOUS SYSTEM

Is the part of peripheral nervous system concerned with the nnervation of involuntary muscle and glandular epithelium through-ut the body. Though the name suggests self-government, yet, ike the rest of peripheral system, it is connected with the central ervous system and is under control of the cerebrum.

Consists chiefly of the ganglia and fibres of the **sympathetic system** –gangliated trunks with their rami communicantes and other ranches, and sympathetic plexuses with their ganglia—and that s the part that has been longest known, for it is nearly all separately efinable by dissection. But many autonomic fibres are com-ponents of cranial and spinal nerves: branches of these nerves onvey these fibres to blood-vessels, hair-muscles, and skin-glands of ead and neck, limbs and walls of trunk; and the roots of these erves convey them to and from central nervous system. There is, esides, a subsidiary portion, called "para-sympathetic system", vhich is distributed by certain cranial and sacral nerves.

Autonomic fibres are both afferent and efferent.

Afferent Impulses.—Afferent fibres are like those of cerebro-spinal erves. They arise in the ganglia of spinal and cranial nerves and ach divides into a central and a peripheral fibre. Their **central ibres** are carried into the spinal cord and brain-stem by the posterior oots of spinal nerves and the sensory roots of cranial nerves; and ew relays carry the impulses upwards. Their **peripheral fibres** for ead, neck, limbs and parietes run to their destinations in the ranches of cranial and spinal nerves. Those for viscera and blood-essels in the interior nearly all arise in spinal ganglia. They pass rom a ganglion into the nerve-trunk, thence into the anterior rimary ramus, thence *via* a white ramus communicans (a few by a rey) into the sympathetic trunk, and onwards by its branches to he plexuses, which distribute them to viscera and blood-vessels. Though they may meet a sympathetic ganglion on their way to iscera, they pass through it without interruption.

Efferent Impulses (motor and secretory).—Efferent sympathetic ibres arise in the lateral grey column of the spinal cord. Pass ut in the anterior roots of the thoracic and upper two lumbar erves, and onwards in the nerve-trunks to the anterior primary

rami; thence, by white rami communicantes, to the sympathetic trunk, and either end in ganglia of the trunk or are carried by branches of the trunk to end in ganglia of the plexuses. In the ganglia, new relays of fibres arise and carry the impulses to their destinations.

Second relays that arise in a ganglion of a plexus are distributed by branches of the plexus. Those that arise in a ganglion of the sympathetic trunk take different routes:—(1) Some pass into such branches of the trunk as the splanchnic to be distributed in the interior of the body. (2) The others enter a grey ramus communicans, run in it to the anterior primary ramus of a spinal nerve, and are distributed by branches of both rami of that nerve to blood-vessels, etc., in its area—head or neck, limbs or body-wall. A few fibres run inwards in the posterior root to supply blood-vessels of meninges.

Note: (*a*) Efferent autonomic fibres differ from cerebro-spinal efferents in that they do not carry impulses to their destinations. They end in ganglia; and new relays carry the impulses to the blood-vessels, viscera, etc.

(*b*) Afferent autonomic fibres for the limbs and parietes escape connexion with the sympathetic system; but the efferent fibres must end in the sympathetic system for relay.

(*c*) The fibres of white rami may run up or down for some distance in the sympathetic trunk before they end in it or leave it; the fibres that arise in the trunk may run up or down some distance before they enter a grey ramus communicans or one of its other branches of distribution. The trunk is made up of these ascending and descending fibres: no fibre passes merely from one ganglion of the trunk to another.

(*d*) Efferent fibres are under the control of the cerebrum by fibres that arise in the subthalamic region near the side of the third ventricle; they descend through the brain-stem into the spinal cord and probably end around cells in the lateral grey column.

SYMPATHETIC SYSTEM

1. A pair of long, slender bands, called **sympathetic trunks,** placed, an inch from the median plane, alongside the front of vertebral column, from axis vertebra to coccyx. Each consists of strands of nerve-fibres that connect a longitudinal series of ganglia; it gives off numerous branches, and it is connected with the spinal nerves by rami communicantes.

2. **Grey rami communicantes** are slender bundles that pass from ganglia of sympathetic trunk—one to the anterior primary ramus of each spinal nerve. **White rami communicantes** are slender bundles that pass to ganglia of sympathetic trunk from the anterior rami of certain spinal nerves—all thoracic and upper two lumbar.

3. Three large plexuses, in which ganglia are imbedded:—**cardiac plexus,** on lower end of trachea; **cœliac plexus,** around cœliac artery and on crura of diaphragm; **hypogastric plexus,** between common iliac arteries, on left common iliac vein and fifth lumbar vertebra.

4. Small plexuses, which contain minute ganglia; they accompany and surround blood-vessels and lie also in the walls of viscera.

Rami Communicantes

A white ramus contains:—(*a*) **Efferent fibres** proceeding from the spinal cord to a sympathetic ganglion to be relayed to any part the of body. (*b*) *Peripheral* branches of **afferent fibres** proceeding from a spinal ganglion to the sympathetic to be distributed (without relay) to viscera and blood-vessels in the interior.

A grey ramus contains:—(*a*) **Efferent fibres** that arise in a ganglion of sympathetic trunk and pass to a spinal nerve to be distributed by its branches to blood-vessels and cutaneous glands and cutaneous muscles—and possibly to certain muscle-cells in voluntary muscles. (*b*) A few afferent fibres.

Sympathetic Trunk

Begins in superior cervical ganglion, below base of skull. Descends *behind* internal and common carotids, *in front of* cervical transverse processes and longus capitis and cervicis. (*See* p. 346.)

Enters thorax in front of the neck of first rib. Descends *in front of* the neck of the second rib on to the heads and radiate ligaments of the succeeding ribs. Leaves the heads of the ribs at a variable level below the fifth to descend over the bodies of the lower vertebræ. (*See* p. 354.)

Enters abdomen behind the medial arcuate lig. and descends in the groove between the vertebræ and the anterior border of psoas major. (*See* p. 378.)

Enters pelvis in front of ala of sacrum. Descends over *medial* edges of sacral foramina. Ends by joining its fellow in *ganglion impar* on pelvic surface of coccyx. (*See* p. 386.)

Ganglia of Sympathetic Trunk

Superior Cervical Ganglion.—An inch long, spindle-shaped, between int. carotid art. and longus capitis, opposite 2nd and 3rd vertebræ.

Communications: with 9th, 10th and 12th cranial nerves.

Branches: 1. *Grey rami communicantes* pass behind vagus to join the anterior primary rami of the upper four cervical nerves where these rami lie between transverse processes behind internal jugular.

2. *Internal carotid nerve* springs from the upper end of the ganglion and breaks up around the internal carotid artery to form the *internal carotid plexus.*

That plexus: (*a*) Sends two *carotico-tympanic* twigs to tympanic plexus. (*b*) Gives off *deep petrosal*, which joins greater superficial to form n. of pterygoid canal. (*c*) Supplies hypophysis. (*d*) Gives a communicating branch to naso-ciliary whose long ciliary branches carry filaments of it to the dilator pupillæ. (*e*) Sends a *root to ciliary ganglion* either independently or through the communication with naso-ciliary; these fibres are the second relay, and they pass, without interruption, through ciliary ganglion, into short ciliary nerves to supply blood-vessels in the eyeball. (*f*) Communicates

with 3rd, 4th, 6th, and ophthalmic nerves and trigeminal ganglion. (*g*) Sends secondary plexuses on to branches of int. carotid.

3. *External carotid branches* form plexuses on ext. carotid and its branches. Plexus on the facial artery gives a root to submandibular ganglion; these fibres pass through the ganglion and supply submandibular and sublingual glands. Plexus on middle meningeal gives fibres to otic ganglion; these pass through the ganglion into auriculo-temporal to supply parotid; inside skull, this meningeal plexus sends the occasional *external petrosal nerve* to the ganglion of facial nerve.

4. *Pharyngeal branches* join branches of 9th and 10th, and of external laryngeal nerves on wall of pharynx; they help to supply mucous membrane and glands.

5. *Superior cardiac nerve* communicates with other cardiac nerves and with the laryngeal nerves, and it descends in front of the inferior thyroid artery. *Right* nerve crosses subclavian artery and descends along trachea to the deep cardiac plexus; *left* nerve descends between carotid and subclavian arteries, crosses the left side of the aortic arch and ends in the superficial cardiac plexus.

Middle Cervical Ganglion.—Small; may be absent, and then the branches arise from the trunk. Lies on the inferior thyroid artery opposite the 6th cervical vertebra. (*See* p. 347.)

Branches: 1. *Grey rami communicantes* pass backwards between the slips of origin of longus capitis and scalenus anterior to join the anterior primary rami of 5th and 6th c. nerves.

2. *Thyroid branches* accompany inf. thyroid art. to thyroid gland.

3. *Middle cardiac nerve* descends to the deep cardiac plexus.

4. *Ansa subclavia* is a branch which descends in front of subclavian artery, giving twigs to it and its branches, turns round it to ascend behind it and join the inferior cervical ganglion. It communicates with the phrenic nerve.

Inferior Cervical Ganglion (*see* p. 347).—Irregular in shape. Lies between 7th c. trans. process and neck of 1st rib, in front of 8th cervical nerve, behind common carotid and vertebral arteries.

Branches: 1. *Grey rami communicantes* arise behind vertebral artery, pass backwards, above and below seventh transverse process to join the anterior primary rami of 7th and 8th c. nerves.

2. *Vertebral plexus* accompanies the vertebral artery to the brain, and gives plexuses to its branches.

3. *Inferior cardiac nerve* descends to the deep cardiac plexus.

Conventionally, cervical grey rami are arranged—4, 2 and 2. But there may be more than eight, and the number of cervical nerves connected with each ganglion varies greatly. The rami from the middle ganglion sometimes pierce longus cervicis; those from the inferior ganglion may pierce scalenus anterior.

Thoracic Ganglia.—Typically 12 in number. They send *grey rami communicantes* to the intercostal nerves; and they receive *white rami communicantes* from them.

Upper five ganglia send branches to aorta, vertebræ and their ligaments; 2nd, 3rd, 4th send branches also to cardiac, œsophageal and posterior pulmonary plexuses.

Greater splanchnic n. arises from 5th to 9th ganglia; descends along the lateral side of vena azygos or inferior v. hemiazygos; pierces crus of diaphragm, and ends in cœliac ganglion. Gives branches to aortic and œsophageal plexuses from its trunk and from the *splanchnic ganglion.* (*See also* p. 355.)

Lesser splanchnic n. arises from 10th and 11th ganglia, pierces crus, and ends in cœliac ganglion. *Lowest splanchnic n.* arises from last ganglion, pierces crus, and ends in renal plexus.

Lumbar Ganglia.—4 to 8. Send *grey rami communicantes* to the anterior primary rami of lumbar nerves. Receive *white r. communicantes* from anterior primary rami of 1st and 2nd lumbar nerves. Send irregular branches to aortic plexus and hypogastric plexus. (*See also* p. 379.)

Sacral Ganglia.—Usually 4. Send *grey r. communicantes* to anterior primary rami of sacral and coccygeal nerves: branches to pelvic plexuses, and to form a plexus around the median sacral artery.

Sympathetic Plexuses

Cardiac Plexus.—Divided into a superficial and a deep part.

Superficial cardiac plexus lies in concavity of aortic arch, in front of bifurcation of pulmonary trunk. Formed by sup. cervical cardiac branch of left sympathetic and inf. cervical cardiac branch of left vagus. *Cardiac ganglion* is placed on their union.

Branches: (1) to deep plexus; (2) to left ant. pulmonary plexus; (3) along pulmonary trunk to plexus around right coronary art.

Deep cardiac plexus is deep to the arch of aorta, on the bifurcation of trachea. Formed by:—

1. The three cervical cardiac branches of right sympathetic.
2. Middle and inf. cervical cardiac branches of left sympathetic.
3. Cardiac branches of 2nd, 3rd and 4th thoracic symp. ganglia.
4. The two cervical cardiac branches of right vagus.
5. Superior cervical cardiac branch of left vagus.
6. Cardiac branches of both recurrent laryngeal.
7. Thoracic cardiac branches of right vagus.
8. A contribution from superficial plexus.

Branches: to coronary and anterior pulmonary plexuses.

Anterior coronary plexus, formed by branches from superficial and deep plexus; accompanies right coronary art.; supplies right atrium and ventricle. **Post. coronary plexus,** from deep plexus, accompanies left coronary art., supplies left atrium and ventricle.

Cœliac Plexus.—A large plexus that lies on aorta around cœliac artery and on crura of diaphragm, behind lesser sac of peritoneum, stomach, pancreas and inferior vena cava.

Is formed by branches of cœliac ganglia (which are imbedded in it) and by branches of vagi. Sends large plexuses into suprarenal glands; is continued downwards over aorta as **aortic plexus,** which receives filaments from lumbar parts of sympathetic trunks.

Subordinate plexuses from cœliac and aortic plexuses accompany and surround all branches of abdominal aorta and all their branches, and get corresponding names, and are joined by branches of vagi.

A few minute ganglia are placed in plexuses around larger arteries. In plexuses around vessels in walls of viscera, there are ganglia too small to be found by naked-eye dissection ; efferent fibres of vagi end in them to be relayed. Plexus on testicular or ovarian artery is derived from aortic and renal plexuses. Renal plexus is joined by the lowest splanchnic nerve.

Cœliac Ganglion.—Largest peripheral ganglion in the body. An inch in diameter. Irregular and lobulated. Lies on crus of diaphragm, medial to suprarenal gland, near cœliac artery. Right ganglion is overlapped by vena cava ; left is overlapped by pancreas, and is crossed by splenic art. Branches of cœliac plexus are derived from it. Greater and lesser splanchnic nerves end in it.

Hypogastric Plexus.—Lies behind peritoneum, between common iliac arteries. Formed by a continuation of aortic plexus and by branches which descend from sympathetic trunks. It divides into a *right* and a *left pelvic plexus.* (*See* p. 386.)

Each **pelvic plexus** passes to the internal iliac artery and surrounds it ; divides into plexuses which accompany its branches. They are joined by branches from sacral part of sympathetic trunk, and also by the *pelvic splanchnic nerves.*

PARASYMPATHETIC SYSTEM

1. Fibres of **oculomotor nerve** that end in **ciliary ganglion** and are relayed to *ciliary muscle* and *sphincter pupillæ.*

2. Fibres of facial nerve that end : (*a*) in **spheno-palatine ganglion** and are relayed to *lacrimal gland* ; (*b*) in **otic ganglion** and are relayed to *parotid gland* ; (*c*) in **submandibular ganglion** and are relayed to *submandibular* and *sublingual glands.*

3. Fibres of **glosso-pharnygeal nerve** that end in **otic ganglion** and are relayed to *parotid gland.*

4. Afferent and efferent fibres of **vagus** that supply *viscera.* The efferent fibres are relayed in **microscopic ganglia** in the viscera. The afferent fibres arise in the lower ganglion of the vagus. Their peripheral branches pass to the viscera without relay.

5. *Pelvic splanchnic nerves* arise from the **second** and **third** or **third** and **fourth** sacral nerves ; they join the sympathetic plexuses in the pelvis and help to supply *urogenital organs* and *the lower part of alimentary canal.* Their efferent fibres are relayed in **microscopic ganglia** in the viscera. Their afferent fibres arise in spinal ganglia of 2 and 3 S. (or 3 and 4), and pass without relay to the viscera.

Apparently there are good grounds for separating the sympathetic and parasympathetic systems — which, in some respects, are antagonistic to each other, *e.g.*, sympathetic supplies dilator of pupil, while parasympathetic supplies sphincter. But the parasympathetic may be merely a part of the sympathetic. Visceral branches of sacral nerves are comparable to the fibres of white rami communicantes that end in ganglia of the plexuses ; and it is possible that the parasympathetic fibres of cranial nerves do not arise in the brain-stem but come into cranial nerves by communicating branches that connect them with the sympathetic.

ORGANS OF THE SENSES

THE EYE

EYEBALL.—Lies in anterior part of orbit. Almost spherical—about an inch in diameter.

Three concentric coats enclosing three of the refracting media :—

Outer or *fibrous coat* comprises sclera and cornea.

Middle or *vascular coat* comprises choroid, ciliary body and iris.

Inner or *nervous coat* is the retina.

Refracting media, from before backwards, are cornea, aqueous humor, lens and vitreous body.

Cornea is the transparent anterior sixth of eyeball. More convex than sclera. Curvature diminishes with age. About half an inch wide. Separated from the iris by a space called the *anterior chamber* of the eye.

Consists from before backwards of : (1) Stratified epithelium, (2) anterior elastic lamina ; (3) fibrous tissue ; (4) posterior elastic lamina ; (5) mesothelium.

At the edge of the posterior elastic lamina its posterior fibres radiate into the iris as its *pectinate ligament* and enclose intervals called the *spaces of irido-corneal angle*, which communicate with the anterior chamber and with the sinus venosus scleræ.

Cornea has no blood-vessels. Is nourished by lymph. Ciliary nerves supply it.

Sclera (White of the Eye).—Dense fibrous tissue. Forms posterior five-sixths of eyeball. Visible part is covered with conjunctiva.

Overlaps margin of cornea, and is directly continuous with its substance. In the deeper part of their junction there is a circular canal called **sinus venosus scleræ ;** the sinus communicates by small openings with scleral veins and anterior chamber.

Ciliary arteries and nerves supply the sclera.

Tendons of *recti* and *obliqui* are inserted into it, and numerous nerves and vessels pierce it (p. 66).

Choroid.—Lines sclera and separates it from retina. Attached to sclera by pigmented areolar tissue—loosely, except where sclera is pierced by optic nerve.

Consists chiefly of fine, pigmented areolar tissue containing nerve-plexuses, meshworks of capillaries, networks of arteries and, superficially, whorls of veins from which the venæ vorticosæ spring.

Ciliary body connects choroid with iris. Comprises ciliary processes internally, ciliary muscle externally.

Ciliary processes resemble choroid in structure; they are ridges or folds, 70 in number, radially arranged to form a flat ring; central ends, free and rounded, lie behind periphery of iris.

Ciliary muscle is a muscular ring that lies deep to anterior part of sclera. Triangular in antero-posterior section. Consists of radial and circular fibres. *Radial fibres* arise from corneo-scleral junction and pectinate lig., radiate backwards and inwards to ciliary processes and choroid. *Circular fibres* form a ring, internal to radial fibres, at periphery of iris; well developed in hypermetropic eyes, poorly developed in myopia. *Nerve-supply*: short ciliary—relayed from oculomotor through ciliary ganglion. It draws choroid forwards and slackens suspensory ligament of lens, so that lens can become more convex in accommodating for near vision.

Iris.—Contractile, coloured, circular curtain placed vertically behind cornea, in front of lens. Peripheral margin is continuous with ciliary body, and is separated from the cornea by the *irido-corneal angle*. Has a central aperture, called **pupil,** whose margin rests against lens.

Consists of non-striped muscle, areolar tissue, vessels and nerves. Covered anteriorly with endothelium; posteriorly with two layers of columnar pigmented cells continuous with part of the retina. In blue eyes, pigment is limited to these layers; in dark eyes, it is also scattered through areolar tissue of iris.

Muscles: *Sphincter pupillæ*, arranged round pupil. Contracts pupil. Nerve-supply—same as ciliary muscle.

Dilatator pupillæ radiates from sphincter to periphery of iris. Enlarges pupil. Supplied by sympathetic, through long ciliary.

Retina.—*Pigmented layer* externally, attached to choroid, and continued forwards, over ciliary body, to iris.

Retina proper, internally, in contact with vitreous. Divided into: (1) *optic part* which contains nervous elements and ends behind ciliary body in wavy border called *ora serrata*; (2) *ciliary part*—a thin layer of columnar cells continued from ora serrata, over ciliary body, to iris.

Macula lutea is a small yellowish spot, on retina, at posterior pole of eyeball: its central part is depressed and called *fovea centralis*.

The **optic disc**, upon which optic nerve-fibres converge to leave eyeball, is 1 mm. below and 3 mm. to nasal side of posterior pole; its circumference is raised up and its centre is depressed (optic cup). The disc is the "blind spot" of the eye.

Blood-Vessels.—Arteria retinæ centralis enters optic nerve in the optic foramen; appears at the centre of optic disc; divides into *upper* and *lower branches*, which ramify laterally and medially. **Veins** correspond. Fovea centralis has no blood-vessels.

Vitreous body occupies the posterior four-fifths of eyeball. Transparent and jelly-like. Consists of loose, fibrous **vitreous stroma** and liquid **vitreous humor** enclosed in a transparent **hyaloid membrane** and traversed antero-posteriorly by *hyaloid canal*. Lens lies on anterior surface in a concavity called *hyaloid fossa*. Hyaloid membrane is adherent to retina at the optic disc. Its anterior part is

thickened and thrown into radial ridges or folds, and is called the *ciliary zonule.* Ciliary processes lie in and adhere to furrows between the folds. The zonula divides near equator of lens into two layers. Posterior layer covers the floor of hyaloid fossa. Anterior layer is stronger; it is a flat, fibrous ring attached to capsule of lens immediately in front of its equator, and forms its **suspensory ligament.** Behind suspensory lig. a series of sacculated lymph-spaces, called **zonular spaces,** encircles equator of lens.

Lens.—Transparent, biconvex, circular. 4 mm. in thickness, 9 to 10 mm. in width. Lies on anterior surface of vitreous, behind the iris and pupil. *Posterior surface* more convex than *anterior.*

Consists of concentric laminæ of elongated cells or fibres enclosed in elastic **capsule of lens. Cortical substance,** near surfaces, is friable; **nucleus lentis,** at centre, is dense and hard.

When the eye is at rest the lens is more flattened owing to tension put upon its capsule by the suspensory lig. When the eye looks at a near object, the ciliary muscle pulls forwards the choroid and ciliary processes and adherent zonule and thus slackens the suspensory ligament; and the lens, being elastic, becomes more convex owing to the removal of the tension on its capsule.

Anterior chamber of eye is the space bounded anteriorly by cornea, posteriorly by iris and central part of lens.

Posterior chamber is bounded anteriorly by the iris, posteriorly by the suspensory lig. and adjoining part of lens, circumferentially by the free ends of the ciliary processes.

The chambers communicate through the pupil; and both of them are filled with a clear liquid called the **aqueous humor.**

Eyelids and Lacrimal Apparatus.—*See* pp. 268, 270.

ORGAN OF HEARING

EXTERNAL EAR

Comprises auricle and external auditory meatus.

Auricle.—**Lateral Surface.**—1. Large depression about its middle is the *concha*; it leads into external auditory meatus.

2. *Helix*: folded rim; begins as *crus helicis* in concha, and ends in the *lobule.*

3. *Tubercle*: morphological apex of ear, seen or felt on helix below and behind top of ear.

4. *Antihelix*: elevation in front of helix; it divides superiorly into *crura antihelicis*, which enclose *triangular fossa.*

5. *Scaphoid fossa*: depression between helix and antihelix.

6. *Tragus* overlaps anterior part of concha and is separated from crus helicis by *anterior notch.*

7. *Antitragus* projects over concha from behind and below, and it is separated from tragus by *intertragic notch.*

8. **Medial** or **cranial surface** bears corresponding elevations and depressions, *eminentia conchæ*, *fossa antihelicis*, etc.

Cartilage of **auricle** supports auricle, all except lobule (which is composed of fat and fibrous tissue); is continuous with cartilage of meatus; connected to zygoma and mastoid process by *ant.* and *post. ligaments*; anterior, posterior and superior (extrinsic) auricular muscles are inserted into it; various intrinsic muscles and ligaments pass from one point of it to another.

Lymph-vessels of auricle end in glands behind it and on surface of parotid, and thence to glands alongside ext. jugular vein.

Nerves: *motor*, facial. *Sensory*, auriculo-temporal, great auricular, lesser occipital and, sometimes, greater occipital.

External Auditory Meatus.—Barely wide enough to admit a pencil. Begins at bottom of concha or "well of the ear"; runs medially for an inch; and is closed at the far end by the *tympanic membrane*, which is set obliquely. Its course is sinuous; it is straightened out as much as it can be when the auricle is pulled upwards and backwards.

Medial two-thirds has rigid bony walls—being bounded above by squamous temporal, and below, behind, and in front by tympanic plate.

Lateral third is movable, and is kept partly shut by the pressure of head of mandible exerted through parotid gland. (Test this by putting a finger in the ear and then opening the mouth.) It is formed by a plate of cartilage folded to form a gutter, and is completed above and behind by fibrous tissue; continuous with cartilage of auricle; attached to margin of osseous part of meatus by fibrous tissue.

In a new-born child there is no osseous part, as tympanic plate is only an incomplete ring. In infant, external meatus is therefore very short; and it is also very narrow.

Skin is firmly adherent to the walls of the meatus, and its epidermis extends on to tympanic membrane. Its *ceruminous glands* are modified sweat-glands and secrete cerumen or ear-wax.

Lymph-vessels end like those of auricle, and in glands *in* parotid.

Nerves are auriculo-temporal and auricular branch of vagus.

Meatus is 24 mm. in length from bottom of concha (35 mm. from tragus); owing to obliquity of tympanic membrane its anterior and inferior walls are longer than posterior and superior. Forms an irregular sinuous bend: lateral part (7 mm.) is directed medially, forwards and slightly upwards; middle part (5 mm.) medially and backwards; medial part (12 mm.), medially, forwards and slightly downwards. Widest at lateral end, narrows towards osseous meatus, widens there, but narrows again as it passes medially; *isthmus* or narrowest part is 30 mm. from tragus.

TYMPANUM OR MIDDLE EAR

Middle ear or tympanum is the drum of the ear ; and the tympanic membrane is the drum-head.

Tympanic cavity is the space enclosed ; and it is the narrow cavity in the temporal bone between tympanic membrane and internal ear. Height and length are about 15 mm. Its medial and lateral walls bulge into it, so that at its middle it is only 2 mm. in width, but increases to 4 mm. at bottom and 6 mm. at top.

Lined with mucous membrane.

Communicates—posteriorly, with a cavity called tympanic antrum through a wide opening at its upper part called *aditus* ; anteriorly, through pharyngo-tympanic tube, with nasal part of pharynx.

Contains tympanic ossicles (*malleus*, *incus* and *stapes*) with their ligaments and muscles ; chorda tympani nerve ; tympanic plexus.

A portion of the cavity, called **epitympanic recess,** is above the level of the tympanic membrane, and contains the greater part of incus and the upper half of malleus.

Boundaries are roof, floor and four walls—anterior, posterior, medial and lateral.

Roof is the thin sheet of bone, called tegmen tympani, which separates it from the middle cranial fossa.

Floor is the thin bone (1) of the floor of jugular fossa, posteriorly, and (2) of the posterior wall of the ascending part of carotid canal, anteriorly. These parts separate the cavity from the bulb of jugular vein and from internal carotid.

Tympanic branch of 9th nerve ascends through the bone between fossa and canal, enters tympanic cavity between floor and medial wall, and breaks up to form tympanic plexus on medial wall.

Carotid part of floor is pierced by carotico-tympanic nerves passing from carotid plexus to tympanic plexus, and by tympanic branch of carotid artery.

Posterior wall presents, from above downwards :—

1. *Aditus ad antrum*, which leads from epitympanic recess into tympanic antrum.

2. *Fossa incudis*, a depression which lodges the short process of incus.

3. *Pyramid*, a small, conical, hollow eminence, at the junction of posterior and medial walls, perforated at its apex by tendon of stapedius.

4. *Posterior canaliculus of chorda*, near posterior edge of tympanic membrane close to its top, for the entrance of chorda tympani into the cavity.

Anterior Wall.—Roof and floor slope towards each other anteriorly, so that anterior wall is merely the openings into two canals, placed one above the other and separated by a thin bony septum. Lower

canal is the bony part of pharyngo-tympanic tube. Upper canal lodges tensor tympani muscle.

Medial wall is the lateral surface of internal ear. In a dried skull, the tympanic membrane and the contents of the middle ear have been removed. The bone seen through the meatus is part of the medial wall of middle ear or lateral wall of internal ear.

Presents:—1. A rounded bulging, called the *promontory*, usually visible through meatus in a dried skull; produced by the first coil of cochlea of internal ear; grooved by tympanic plexus.

2. *Fenestra vestibuli*, an oval aperture above and behind promontory; leads into vestibule of internal ear; is closed by foot-piece of stapes.

3. A ridge produced by the canal for the facial nerve as it runs backwards in the upper part of medial wall, immediately above fenestra vestibuli, towards the lower margin of aditus. The canal afterwards descends behind posterior wall to end at stylo-mastoid foramen.

4. A thin, curled ledge of bone, called *processus cochleariformis*, is prolonged backwards from the septum above pharyngo-tympanic tube as far as upper margin of fenestra vestibuli; it supports tensor tympani; its posterior end is turned like a pulley for tendon of tensor to play over as it bends laterally to its insertion.

5. *Sinus tympani*, a depression behind the promontory, opposite ampulla of posterior semicircular canal.

6. *Fenestra cochleæ*, a round aperture at bottom of a depression below and behind promontory; communicates with scala tympani of cochlea; and is closed by membrane called *secondary tympanic membrane*.

Lateral Wall.—Small, upper part is formed by squamous temporal; by far the greater part is formed by tympanic membrane, whose circumference is fixed to a circular groove, around the medial end of meatus, called *tympanic sulcus*. The groove and the bony ridge or rim on which it runs are deficient superiorly, leaving a shallow concavity called the *tympanic notch*.

The medial end of the petro-tympanic fissure is just in front of the upper end of the bony rim; it lodges anterior process of malleus and transmits tympanic branch of maxillary artery. In the fissure, or just in front of it, there is the *anterior canaliculus* by which chorda tympani leaves the tympanum and runs along the lateral wall of the pharyngo-tympanic tube to gain the base of the skull.

Tympanic Membrane.—Placed obliquely, so that its lateral surface looks downwards and forwards as well as sidewards. Circumference is thickened, except at tympanic notch, and is called *the fibro-cartilaginous ring*. Nearly the whole of the membrane is tense. But a small V-shaped patch below the notch is lax. Lax or flaccid part is bounded in front and behind by bands which raise up slight ridges of mucous membrane on medial surface. The ridges are

called *anterior* and *posterior malleolar folds*; they pass from the ends of the notch to the lateral process of malleus. Handle of malleus is imbedded in the membrane and draws it medially so that medial surface is convex. Maximum convexity is the *umbo*—although that name is often given to maximum concavity on lateral surface.

Tympanic membrane consists of a layer of fibrous tissue (absent from flaccid part), lined laterally with epidermis, medially with mucous membrane.

Arteries: deep auricular and tympanic of maxillary, stylo-mastoid of posterior auricular.

Veins: into external jugular, sigmoid sinus, veins of dura, plexus on pharyngo-tympanic tube.

Nerves: auriculo-temporal and auricular branch of vagus to skin surface; tympanic of glosso-pharyngeal to mucous surface.

Mucous membrane lines tympanic cavity; is continuous with pharynx through pharyngo-tympanic tube; extends back to line antrum and mastoid air-cells; envelops ossicles, muscles, and nerves, and, in so doing, is cast into folds which bound little pouches.

Nerves: tympanic plexus. *Lymph* to glands in infratemporal fossa.

Tympanic Antrum and Pharyngo-Tympanic Tube

Tympanic Antrum.—Almost as large at birth as in adult. Diameters about 9 mm. **Situated** half an inch **medial to suprameatal triangle,** but is much nearer the surface in a child. *Bounded superiorly* by tegmen tympani, *medially* and *posteriorly* by petrous, *laterally* by squamous below supramastoid crest, *inferiorly* by mastoid temporal. Sigmoid sinus is behind it; jugular fossa is below it. Anteriorly it communicates with epi-tympanic recess of tympanic cavity by the **aditus,** whose medial wall overlies ampullæ of superior and lateral semicircular canals, above and behind canal of facial nerve.

At puberty or earlier, **mastoid air-cells** begin to develop as diverticula of antrum into the mastoid temporal, and extend into mastoid process and into bone adjoining mastoid temporal.

Pharyngo-Tympanic Tube.—Trumpet-shaped. An inch and a half long. Leads from the anterior wall of tympanic cavity medially, forwards, and downwards, to open on the lateral wall of the nasal part of pharynx in front of its centre, about the middle of posterior border of medial pterygoid plate, on a level with the posterior end of inferior concha and half an inch behind it.

Osseous part, half an inch long; in substance of temporal bone between tympanic plate and petrous temporal, below canal for tensor tympani, lateral to carotid canal and artery, postero-medial to upper part of mandibular joint. Medial end is found on base of skull behind and medial to spine of sphenoid; and chorda tympani runs along its lateral wall to reach the medial side of that spine.

Cartilaginous part, an inch long; fixed in groove between greater

wing of sphenoid and petrous temporal on inferior surface of skull.

Tensor palati arises from its antero-lateral surface and separates it from middle meningeal art., otic ganglion, mandibular nerve and pterygoideus medialis. Postero-medial surface is in relation to mucous membrane of pharyngeal recess and levator palati; that muscle partly arises from it, and is at first medial to it and then below. Upper border of superior constrictor is below.

Cartilage is a triangular plate, curled to form upper, lower and medial walls, while lateral wall is formed by fibrous tissue. Apex of plate is fixed to medial end of osseous part. Base is curved and free; bounds pharyngeal orifice above, below and behind, forming prominent curved ridge, above and behind, called *the tubal elevation*, gives origin to salpingo-pharyngeus muscle, which descends in salpingo-pharyngeal fold in side-wall of cavity of pharynx. During deglutition the tube is opened by the muscles attached to it.

Mucous membrane lines tube. Thin in osseous part. Thick and folded in cartilaginous part, where it contains mucous glands and some lymphoid tissue—most abundant at pharyngeal orifice. Covered with epithelium—cubical in bony part; columnar and ciliated in cartilaginous part to promote flow of mucus towards pharynx.

Nerves: from tympanic plexus and pharyngeal branch of sphenopalatine ganglion.

Tympanic Ossicles and Muscles

Malleus.—Largest; 8 to 9 mm. long. Rounded **head,** supported by constricted **neck,** lies in epitympanic recess and is attached to roof by ligament; articulates, by synovial joint, with incus medially. *Anterior process* projects forward from neck and is connected by ligament to fibrous tissue in petro-tympanic fissure. Chorda tympani, as it passes forwards through tympanic cavity, crosses medial side of neck. **Manubrium** or handle extends downwards, medially and backwards, and is imbedded in the upper half of tympanic membrane; tensor tympani is inserted into medial side of its upper end. *Lateral process* juts sidewards from upper end of manubrium, and malleolar folds are attached to it.

Incus.—Shaped like a molar tooth with widely-diverging fangs. **Body** lies in epitympanic recess; articulates laterally with malleus. **Short process** juts backwards into fossa incudis and is attached there by ligament. **Long process** extends downwards; lower end turns medially and ends in a knob, called *lentiform nodule*, which articulates with head of stapes by a synovial joint.

Stapes.—Stirrup-shaped. **Head** articulates with incus. Stapedius is inserted into the back of the *neck*. Diverging **limbs**—**anterior** and **posterior**—pass medially and join ends of **base** or foot-piece, which is oval and fits into fenestra vestibuli, and is held there by the *annular lig. of base of stapes*.

Tympanic Muscles.—**Tensor tympani** *arises* from cartilage of pharyngo-tympanic tube and adjoining greater wing of sphenoid;

passes through canal above bony part of tube; enters upper, anterior part of tympanic cavity; turns laterally round pulley-shaped end of cochleariform process, to be *inserted* into upper end of handle of malleus. Draws malleus and tympanic membrane medially, and makes the membrane more tense. *Nerve*, mandibular, through otic ganglion.

Stapedius *arises* from the walls of interior of pyramid. Tendon emerges from apex of pyramid and is *inserted* into posterior surface of neck of stapes. Tilts anterior end of foot-piece laterally and posterior end medially. *Nerve*, from facial.

INTERNAL EAR

Lies in petrous temporal between medial wall of middle ear and bottom of internal auditory meatus. Its parts are (*a*) dense bone called *bony labyrinth*, which encloses a small cavity and several narrow, curved canals; and they contain (*b*) *membranous labyrinth* —two small sacs and several curved tubes or ducts.

Bony Labyrinth: Vestibule; 3 semicircular canals; cochlea.

Vestibule.—A small oval cavity, $6 \times 4 \times 3$ mm. Between internal meatus and middle ear. Fenestra vestibuli is in its lateral wall. Bottom of meatus, perforated by branches of vestibular nerve, is its medial wall. Facial nerve, having pierced bottom of meatus, passes sidewards above it. Communicates anteriorly with cochlea, posteriorly with semicircular canals. Postero-inferiorly, a narrow canal, called *aqueduct of vestibule*, runs from it to open on posterior surface of petrous temporal.

Semicircular Canals.—Behind and above vestibule. Each forms two-thirds of a circle and is ampullated at one end.

Superior is vertical, lies across long axis of petrous, and produces arcuate eminence on its anterior surface. Ampulla opens into upper part of vestibule. Posterior end joins non-ampullated end of posterior canal to form *crus commune*, which opens into medial part of vestibule.

Posterior is vertical, parallel to posterior surface of petrous. Upper end joins crus commune. Lower end is the ampullated end and enters postero-inferior part of vestibule.

Lateral arches horizontally in lateral direction. Lateral end is ampullated and opens immediately below ampulla of superior; other end opens above ampulla of posterior.

Lateral canal of one ear is nearly in same plane as that of the other; posterior canal of one ear is nearly parallel to superior of the other.

Cochlea.—Like a snail-shell laid on its side. Base at bottom of internal meatus. Apex points sidewards and forwards, and is close to canal for tensor tympani. 9 mm. across base; 5 mm. from base to apex.

It is a bony, tapering canal, 30 mm. long, coiled spirally $2\frac{1}{2}$ or $2\frac{3}{4}$ times around a horizontal central pillar, called **modiolus**, which falls short of apex by 1 mm. The bulge of the basal or first coil produces the promontory on medial wall of tympanum.

Osseous spiral lamina, a thin, flat shelf, winds round modiolus like the thread of a screw; it projects half-way across cochlear canal, dividing it into **scala vestibuli** on its apical side, **scala tympani** on basal side. The lamina begins at floor of vestibule and ends near apex in a process, called *hamulus*, which assists to bound an aperture called *helicotrema*. A membrane, called *basilar lamina*, stretches from free edge of osseous lamina to outer wall of tube, completing septum between scalæ (but the scalæ communicate with each other through helicotrema).

Scala tympani begins, on medial wall of middle ear, at fenestra cochleæ, which is closed by secondary tympanic membrane. Near fenestra is opening of *aqueduct of cochlea*, which runs through petrous for 10 to 12 mm., and opens at anterior margin of jugular foramen. Through it, scala tympani communicates with subarachnoid space; and it transmits a vein. Scala vestibuli begins in vestibule.

Modiolus is channelled by a large number of *longitudinal canals* for cochlear nerves and vessels. The canals run for varying distances longitudinally and then turn towards attached edge of the osseous lamina, where they dilate and join one another to form *spiral canal of modiolus*, which lodges spiral ganglion. From this spiral canal, numerous small canals conduct nerves and vessels to the free edge of the lamina spiralis to enter the spiral organ.

Membranous Labyrinth.—Comprises utricle, saccule, three semicircular ducts and cochlear duct. Lies in bony labyrinth but does not nearly fill it. Contains a clear liquid called *endolymph*, while *perilymph* occupies space between it and walls of bony labyrinth.

Utricle.—Small sac, lying in postero-superior part of vestibule, receives the ends of semicircular ducts.

Sacculus.—Smaller than utricle, lies in antero-inferior part of vestibule. *Ductus re-uniens*, a short canal from lower part of saccule, opens into cochlear duct near its vestibular end. *Endolymphatic duct* leaves posterior part of saccule; is joined by short *utriculo-saccular duct* from utricle; traverses aqueduct of vestibule; ends under dura mater, on posterior surface of petrous, as a dilatation called *endolymphatic sac*.

Semicircular ducts, within bony semicircular canals, attached to the convex sides of the canals; are each ampullated at one end; and they open into utricle by five openings.

Cochlear Duct.—Spiral tube inside bony canal of cochlea on apical side of scala tympani. Both ends are blind. Basal end lies in vestibule. Apical end is fixed to apex of cochlea and helps to bound helicotrema.

Spiral organ, the essential end-organ of hearing, is placed in cochlear duct, on apical side of basilar lamina.

Artery: Int. auditory from basilar. **Veins** join inf. petrosal sinus. **Nerves**: *Cochlear* to cochlear duct and spiral organ. *Vestibular* to utricle, saccule and semicircular ducts; but its filaments to saccule and posterior duct accompany cochlear nerve.

Internal Auditory Meatus.—8 mm. long, 3 to 5 mm. wide. Situated in petrous temporal, medial to internal ear. Opens into

posterior cranial fossa by an oblique aperture on the posterior surface of petrous temporal. Its *fundus* or bottom is a plate of bone which separates it from vestibule and cochlea, and is perforated by (1) facial nerve, (2) the filaments of vestibular and cochlear parts of auditory nerve, and (3) the internal auditory vessels.

NASUS (NOSE)

External Nose.—Skeleton is (1) nasal bones and frontal processes of maxillæ, (2) upper and lower cartilages. Skin is thin and movable over upper part; thick over the lower part, and is adherent to the underlying cartilage and fibrous tissue of the **ala**—which is the expanded mobile wing that bounds the *nostril* laterally.

Nerves: to muscles, from facial; to skin, (1) infratrochlear and external nasal branches of naso-ciliary and (2) infra-orbital.

Lymph-vessels end in lymph-glands (*a*) on surface of parotid, (*b*) below mandible.

Cartilages of Nose.—**Septal cartilage**: a broad quadrangular sheet; *postero-superior border* attached to the perpendicular plate of ethmoid; *postero-inferior*, to vomer and maxillæ; *antero-superior*, to nasal bones above, to fibrous tissue below, continuous with upper nasal cartilage in the middle; *antero-inferior*, to the septal process of lower nasal cartilage.

Upper Nasal Cartilage.—Triangular. *Superior border* attached to nasal bone and frontal process of maxilla; *inferior*, to the lower cartilage; *anterior* continuous with septal cartilage above but separated from it by a fissure below.

Lower Nasal Cartilage.—Large, oval, lies above anterior part of nostril. *Septal process* turns backwards in lower part of septum.

Small Cartilages of the Ala.—Small flakes in upper part of ala.

Lower part of ala and free edge of septum are devoid of cartilage.

Cavity of Nose.—Extends from the nostrils to the posterior apertures (p. 39), which open into nasal part of pharynx.

Divided by median septum into right and left half. The term "cavity of nose" refers usually to one or other of the halves. Septum usually bulges to one side, making the halves unequal in width.

Length is two inches along floor; three inches along roof. *Height* is two inches in the middle; but, owing to slope of posterior and anterior parts of roof, it is reduced to an inch at the posterior aperture, and less than that at nostril. *Width* is half an inch or less across the floor; and it is a mere slit near the roof—except posteriorly where it widens to receive the opening out of sphenoidal sinus.

Osseous boundaries, communications and relations (*see* p. 72).

Osseous *lateral wall* is supplemented by the cartilages; osseous

septum by septal cartilage and septal process of the lower cartilage.

Divisions.—Common meatus is the narrow interval that separates septum from conchæ.

Inferior meatus is the space below and lateral to inferior concha. *Naso-lacrimal duct* opens into its anterior part.

Middle meatus is the space below and lateral to middle concha. On its lateral wall there is a large, rounded bulging, called **bulla ethmoidalis,** which is bounded in front and below by a curved groove called **hiatus semilunaris.**

Several sinuses open into the middle meatus :—

Middle ethmoidal sinuses, on the surface of the bulla.

Anterior ethmoidal sinuses, into the upper part of the hiatus.

Frontal sinus, into the upper part of the hiatus.

Maxillary, into the lower part of the hiatus.

Superior meatus is the narrow space below and lateral to superior concha. *Posterior ethmoidal sinuses* open into it.

Spheno-ethmoidal recess is the space above and behind posterior part of superior concha. *Sphenoidal sinus* opens into it.

Atrium of middle meatus is the wide space in front of that meatus ; its junction with meatus is separated only by thin bone from lacrimal sac ; it is limited superiorly by a ridge called *agger nasi.*

Vestibule is the dilated part above nostril. Lined with skin, and hairs grow on the lower part of it.

Remainder of nasal cavity is lined with mucous membrane and is divided into **olfactory region** (the region of superior concha and corresponding part of septum) and **respiratory region.**

Mucous Membrane.—Thick, very vascular, continuous with that of pharynx and sinuses in neighbourhood, adherent to periosteum and perichondrium. In respiratory region it is covered with ciliated columnar epithelium and contains numerous glands ; in olfactory region, yellowish, more delicate, covered with non-ciliated columnar epithelium, contains tubular, branched *olfactory glands.*

Arteries, spheno-palatine, ethmoidal, greater palatine.

Veins form plexuses, especially dense over conchæ.

Lymph-vessels end in glands behind pharynx, in infratemporal fossa and below mandible, and thence to glands in carotid triangle.

Nerves : (1) **Special sense :** olfactory. (2) **Ordinary sensation :** *Septum*—spheno-palatine ; anterior ethmoidal. *Lateral wall*—anterior ethmoidal ; spheno-palatine and twigs from greater palatine and anterior superior dental.

PARANASAL SINUSES.—*See* pp. 62, 312.

RESPIRATORY SYSTEM

Air drawn into the two **lungs** by the movements of inspiration passes successively through the cavities of **nose, pharynx, larynx, trachea**, and through the two **bronchi**, into which the trachea divides.

Nasal cavities are in the head. Pharynx, in the head and the neck. Larynx, in the neck. Trachea in the neck and the thorax. Bronchi in the thorax. Lungs, in the thorax and in the root of the neck.

Each lung is covered by a membrane called **pleura.**

Nose.—pp. 72, 591. **Pharynx.**—p. 621.

LARYNX

The organ of voice, situated below hyoid bone and tongue, between carotid sheaths, and (reckoning tip of epiglottis as upper end) in front of 3rd, 4th, 5th, 6th cervical vertebræ, separated from them by pharynx and prevertebral muscles. In relation antero-laterally with thyroid gland and depressors of hyoid, and overlapped by sterno-mastoid. In fœtus it is opposite 3rd and 4th c. vertebræ. Gradually extends downwards till puberty. Position varies with movements of the head and during deglutition and vocalisation.

CARTILAGES OF LARYNX

Unpaired: thyroid, cricoid, epiglottic. **Paired:** arytenoid, corniculate, cuneiform.

Thyroid Cartilage.—A pair of quadrilateral **laminæ.** *Anterior borders* fused below, but separated by **thyroid notch** above. Very prominent above, in men, forming the **laryngeal prominence** (Adam's apple). *Posterior border*, free and rounded, extends upwards and downwards as **sup.** and **inf. horns.** Sup. horn is connected with greater horn of hyoid by lateral thyro-hyoid lig.,

in which a small nodule of cartilage is developed—*cartilago triticea.* Inf. horn articulates with side of cricoid. *Superior border* convex; *inferior border* nearly horizontal. **Oblique line** begins on *lateral surface* in front of the root of the superior horn; extends downwards and forwards to end behind middle of inf. border. *Medial surface* is smooth.

Extrinsic muscles attached:—Inf. constrictor from oblique line and from surface behind it; stylo-pharyngeus and palato-pharyngeus to posterior border; sterno-thyroid to oblique line, and thyro-hyoid from it.

Cricoid Cartilage.—Below thyroid cartilage. Shaped like a signet-ring, with its broad *lamina* behind and narrow *arch* in front.

Lamina: posterior surface shows a pair of hollows for origins of posterior crico-arytenoid muscles. Superior border has a pair of facets for arytenoid cartilages separated by a median notch.

Arch: narrow in front, broadens to join lamina behind; facet for inf. horn of thyroid on junction with lamina, near lower border. Sup. border slopes upwards and backwards. Inf. border is in the same horizontal plane as the inferior border of the lamina.

Extrinsic Muscles.—Inf. constrictor to the side. Some fibres of œsophagus to median ridge on the back.

Epiglottic Cartilage.—Placed behind median thyro-hyoid lig., hyoid bone and back of tongue; in anterior boundary of inlet of larynx. Shaped like a leaf; *upper end* free; *lower end* or stalk is attached by **thyro-epiglottic lig.** to receding angle between laminæ of thyroid. *Margins* are enclosed in ary-epiglottic folds of mucous membrane. *Post. surface* is covered with mucous membrane; lower part is bulged backwards to form *epiglottic tubercle. Ant. surface*: upper part is free and covered with mucous membrane; lower part is separated by pad of fat from median thyro-hyoid ligament, and is connected with body of hyoid bone by loose fibrous tissue called **hyo-epiglottic ligament.**

Glosso-epiglottic fold is a ridge of mucous membrane raised up in median plane between epiglottis and back of tongue.

Pharyngo-epiglottic folds of mucous membrane are a pair of ridges that extend from margins of epiglottis to pharynx at sides of back of tongue. **Epiglottic vallecul**æ are the pair of shallow depressions that separate glosso-epiglottic from pharyngo-epiglottic folds.

Arytenoid Cartilages.—On upper border of lamina of cricoid. Each is a three-sided pyramid. *Surfaces*: medial, antero-lateral and posterior. *Apex*, above, supports corniculate cartilage. *Base* articulates with lamina of cricoid. Anterior angle of base is prolonged forwards as the **vocal process**; lateral angle is enlarged for insertions of posterior and lateral crico-arytenoid muscles, and is called **muscular process.**

Corniculate Cartilages: small nodule on apex of each arytenoid, in ary-epiglottic fold.

Cuneiform Cartilages: small rod-shaped piece of cartilage in each ary-epiglottic fold, in front of apex of arytenoid.

Thyroid, cricoid and bases of arytenoids are hyaline and begin to ossify after 20, and are completely ossified at advanced age.

Other cartilages are yellow fibro-cartilage.

JOINTS, LIGAMENTS AND MEMBRANES

Crico-Thyroid Joint.—Synovial. Inferior horn of thyroid connected with side of cricoid by *articular capsule*, strengthened posteriorly. **Movements:** rotatory around a transverse axis, and gliding movements.

Crico-Arytenoid Joint.—Synovial. Base of arytenoid connected with upper border of lamina of cricoid by *articular capsule*, thickened posteriorly to arrest forward movement. **Movements:** rotatory around a vertical axis, and gliding in all directions.

Thyro-Hyoid Membrane.—Attached superiorly to deep aspect of *upper* border of hyoid bone, inferiorly to superior horns and upper margin of laminæ of thyroid.

Median portion is thickened and is called **median thyro-hyoid lig.,** which is attached to *upper* margin of body of hyoid and to margins of notch of thyroid. Posterior surface is separated from epiglottis by fat. Upper part of anterior surface is separated by *bursa* from hyoid bone; lower part is crossed by the suprahyoid anastomosis.

Deep surface of *lateral part* of membrane is lined with mucous membrane of pharynx; superficial surface is related to thyro-hyoid muscle. It is pierced by internal laryngeal nerve and superior laryngeal vessels. Its *posterior margin* is thickened to form the **lateral thyro-hyoid lig.,** which connects the tips of greater horn of hyoid and superior horn of thyroid.

Crico-Thyroid Lig.—Triangular in outline. Attached by its base to upper border of middle part of cricoid arch; by its apex to the deep surface of the thyroid near its lower border. Deep surface is lined with mucous membrane. Superficially, its basal angle is overlapped by crico-thyroid muscle; the middle part is subcutaneous and is crossed by crico-thyroid anastomosis.

Crico-Vocal Membrane—A thin, triangular sheet that slopes upwards and medially from upper border of cricoid.

Anterior margin is partly continuous with the crico-thyroid lig. and is partly attached to the thyroid cartilage.

Lower margin is fixed to the upper border of the side of cricoid.

Posterior part of *upper margin* is attached to lower surface of vocal process; its anterior part is a free edge called *vocal ligament.*

Medial surface is lined with mucous membrane.

Lateral surface is covered: (1) by thyro-arytenoid and lateral crico-arytenoid, which separate it from the thyroid cartilage;

(2) by crico-thyroid, which overlaps it where it joins crico-thyroid lig. in the crico-thryoid interval.

Vocal ligament is the free and thickened part of the upper margin of the crico-vocal membrane. Composed of yellow elastic fibres. Attached anteriorly to thyroid near receding angle, posteriorly to the tip of vocal process of arytenoid. Is covered with mucous membrane, which it raises up as a ridge called the *vocal fold*.

Vestibular ligament is a loose, weak band of fibres situated a little above vocal lig. Extends from thyroid, near angle, to antero-lateral surface of arytenoid. Is covered with mucous membrane, and raises it up as a ridge called the *vestibular fold*.

Crico-tracheal ligament is a fibrous ring that connects lower border of cricoid with upper end of trachea.

INTERIOR OF LARYNX

Inlet of Larynx.—Large. Looks backwards and upwards into laryngeal part of pharynx. *Bounded anteriorly* by epiglottis ; *postero-inferiorly* by **interarytenoid fold** of mucous membrane ; *at each side* by the **ary-epiglottic fold** of mucous membrane—a wide fold which stretches between arytenoid and edge of epiglottis.

(*Piriform fossa* is the space in the pharynx that separates ary-epiglottic fold from lamina of thyroid and thyro-hyoid membrane.)

Vestibule of larynx is the uppermost part of cavity of larynx. It extends from the inlet to the vestibular folds. Its walls are the epiglottis, the ary-epiglottic folds and the interarytenoid fold.

Vestibular Fold.—A blunt ridge of mucous membrane raised up by vestibular lig. Extends from angle of thyroid, at attachment of thyro-epiglottic lig., backwards along the side of cavity of larynx, as far as cuneiform cartilage. **Rima vestibuli** is the interval between the right and left vestibular folds.

Vocal Fold.—A sharp, prominent ridge of mucous membrane raised up by vocal lig. and firmly bound to it. Extends from angle of thyroid to vocal process of arytenoid. Lies below vestibular fold, and nearer median plane.

Vocal fold is *made tense* by crico-thyroid ; *slackened* by thyro-arytenoid ; *abducted* by posterior crico-arytenoid ; *adducted* by lateral crico-arytenoid.

Rima glottidis is the interval that separates right vocal fold and base of arytenoid from the left. Narrower than rima vestibuli, and therefore all the folds can be seen from above.

Rima is opposite the middle of anterior border of thyroid cartilage. Length in men is nearly an inch, and about two-thirds of that in women. Equal in two sexes up to puberty. Rapidly increases in boys at puberty and the voice "breaks".

Sinus of larynx is a depression on the side-wall of the cavity

of the larynx between vestibular fold and vocal fold.

Saccule of larynx is a diverticulum of mucous membrane that extends from the sinus upwards between the vestibular fold and the lamina of the thyroid cartilage.

Mucous Membrane.—Two parts. One part lines cavity of larynx, and is continuous inferiorly with mucous membrane of trachea. It is smooth; and it is even, except where it forms the vestibular and vocal folds and the sinus between them.

The other part covers the back of larynx and forms, therefore, the mucous membrane of anterior wall of laryngeal part of pharynx. It is continuous above and at the sides with the rest of mucous membrane of pharynx, with that of œsophagus inferiorly, and with that of cavity of larynx at the inlet of larynx. It lines piriform fossa, clothes the muscles on the backs of cricoid and arytenoids, covers the upper part of epiglottis, and forms the outer layers of ary-epiglottic and interarytenoid folds.

At all parts the mucous membrane is loosely bound down except over epiglottis and vocal folds; on the folds, it is also very thin and its cells squamous. **Mucous glands**: scattered all over, especially plentiful over epiglottis, around cuneiform cartilages, in vestibular fold, and in sinus and saccule; *absent from vocal fold.*

INTRINSIC MUSCLES OF LARYNX

Crico-Thyroideus.—Lies on the lower part of exterior of larynx. **Arises** from lower border and lateral surface of cricoid. Directed backwards and upwards to be **inserted** into inf. horn and inf. border of lamina of thyroid. **Nerve**: ext. laryngeal. It pulls and rotates thyroid downwards and forwards (or cricoid upwards and backwards), and so makes vocal folds tense.

Crico-Arytenoideus Posterior.—**Origin**: posterior surface of lamina of cricoid. Fibres pass upwards and sidewards, converging to be **inserted** into muscular process of arytenoid. **Nerve**: *this and succeeding muscles by recurrent laryngeal.* It rotates arytenoid so that vocal process and fold are swung sidewards and rima glottidis is widened.

Crico-Arytenoideus Lateralis.—**Origin**: upper border of lateral part of arch of cricoid. Directed upwards and backwards to be **inserted** into muscular process. It rotates arytenoid so that vocal process is swung medially and rima glottidis is narrowed.

Thyro-Arytenoideus.—**Origin**: lower part of deep surface of lamina of thyroid near angle. **Insertion**: antero-lateral surface of arytenoid. Draws arytenoid towards thyroid and so relaxes vocal fold. *Vocalis* is a deep slip of the thyro-arytenoid that lies along the lateral side of the vocal ligament, and is partly attached to it; and it may tighten a segment of the ligament in the production of a high note.

Thyro-Epiglottideus.—Some of upper fibres of thyro-arytenoideus which curve upwards into ary-epiglottic fold to reach the edge of epiglottis. It shortens ary-epiglottic fold and pulls tubercle of epiglottis against arytenoids during deglutition.

Arytenoideus Transversus.—The only unpaired muscle in larynx. Passes from the back of one arytenoid to the back of the other. Draws posterior parts of arytenoid cartilages together, and thus helps to close the inlet of larynx during swallowing.

Arytenoideus Obliquus.—Superficial to transversus. Extends from muscular process of one arytenoid to apex of other, and then onwards as **ary-epiglottideus,** in ary-epiglottic fold, to edge of epiglottis. It draws arytenoids together; shortens ary-epiglottic fold and approximates arytenoids and epiglottis; therefore acts as a sphincter of the inlet of larynx during swallowing.

Nerves and Vessels of Larynx

Nerves.—Internal laryngeal supplies mucous membrane on the back, and on the inside down to vocal fold. External laryngeal supplies crico-thyroid. Recurrent laryngeal supplies other muscles, all on their outer surface; and mucous membrane up to vocal fold.

Vessels.—Sup. laryngeal of sup. thyroid art. Inferior laryngeal of inf. thyroid. Lymph-vessels from upper part end in glands in carotid triangle; from lower part in glands on front and sides of larynx and trachea.

TRACHEA AND BRONCHI

Trachea begins at lower border of cricoid cartilage, opposite lower border of 6th c. vertebra. Ends by dividing into two bronchi opposite sternal angle and the interval between 3rd and 4th thoracic spines. Lies in median plane, except lower end, which is slightly to the right. Upper half is in neck, lower half in sup. mediastinum. Length in men, 4 to 5 in.; in women, $3\frac{1}{2}$ to 4 in.

Relations.—*See* pp. 326, 605.

Bronchi extend sidewards and downwards from bifurcation of trachea, and each enters hilum of its lung, opposite 5th thoracic spine. Right bronchus is wider, more vertical, and only about half the length (an inch) of left. Left bronchus is longer (two inches) and more horizontal, because (1) end of trachea is slightly to right of median plane, (2) hilum of left lung is farther from median plane than that of right, and because (3) heart, bulging more to left side, pushes left bronchus up.

Relations.—**Right bronchus** gives *eparterial bronchus* to upper lobe and divides into branches for middle and lower lobes of lung. Pulmonary art. is below and anterior to main stem, and passes between eparterial branch and remaining *hyparterial* part to reach the back of the branches within lung. Upper pulmonary vein is anterior; lower is below. Posterior pulmonary plexus and bronchial vessels are posterior. Superior vena cava and ascending aorta are anterior. Vena azygos is behind and above.

Left bronchus divides into branches for upper and lower lobes of lung. Pulmonary art. at first anterior, curves round supero-lateral border to reach postero-lateral surface. Upper pulmonary vein is anterior; lower is below. Arch of aorta is above. Posterior pulmonary plexus and bronchial vessels, œsophagus, and descending aorta are posterior.

Trachea is a tube of fibro-elastic membrane kept patent by 15 to 20 cartilaginous rings, which are deficient posteriorly and are replaced by **musculus trachealis,** composed of transverse plain fibres, supplied by recurrent laryngeal n. **Mucous membrane** contains many mucous glands, much lymphoid tissue, and is lined with columnar ciliated epithelium. Structure of **bronchi** is similar.

Within the lungs the bronchi give off dorsal and ventral branches. Branches of pulmonary veins are anterior to them; branches of pulmonary artery are posterior.

Arteries to trachea, from inferior thyroid. **Veins** end in thyroid plexus and inferior thyroid. **Lymph-vessels** end in glands on front and sides and at bifurcation. **Nerves,** from recurrent laryngeal and from cervical and upper thoracic sympathetic ganglia.

Arteries to bronchi: two *left* from descending aorta; one *right* from first right aortic intercostal or upper left bronchial or aorta. **Veins:** *right* ends in v. azygos, *left* in superior v. hemiazygos. **Lymph-vessels** end in adjacent glands. **Nerves,** from vagus and sympathetic, through pulmonary plexuses.

CAVITY OF THORAX AND PLEURÆ

Cavity of thorax is divided into a pair of **pleural cavities** and an intervening region, called **mediastinum,** occupied by structures in and near the median plane, collectively called *mediastinal septum.* Each pleural cavity is enclosed by pleura and contains a lung.

Each **pleura** has two parts—*pulmonary* and *parietal*—continuous with each other over root of lung.

Pulmonary pleura is adherent to the lung-substance, covers the surfaces and lines the fissures.

Parietal pleura much thicker, lines the walls of pleural cavity. It is divided into four parts—*costal, diaphragmatic, mediastinal, cervical.*

1. **Costal pleura** lines ribs and intercostal spaces.

2. **Diaphragmatic pleura** covers great part of diaphragm.

3. **Mediastinal pleura** extends from anterior to posterior wall of thorax and covers mediastinal septum; part which covers side of pericardium is called **pericardial pleura.** It is reflected over root of lung and becomes continuous with pulmonary pleura around hilum of lung.

Pleura on the lower surface of root is drawn downwards as a fold called **pulmonary lig.** The two layers of this lig. are closely applied; they are continuous *superiorly* with the pleura which clothes front and back of root of lung, *medially* with pericardial pleura, *laterally* with pulmonary pleura below hilum, and *inferiorly* with each other, forming a free lower border.

4. **Cervical pleura** reaches to level of neck of first rib posteriorly, but, owing to obliquity of rib, it lies in root of neck anteriorly, extending nearly two inches above first cartilage, and nearly an inch above sternal third of clavicle. It is covered by the suprapleural membrane; protected laterally by scalenus medius, antero-laterally by scalenus anterior. In relation anteriorly with subclavian art., its branches, and structures related to the artery.

Surface of pleura is smooth and glistening. Pleural cavity is only a capillary interval between the pulmonary and parietal pleura. It contains a little lymph—just enough to lubricate surfaces.

Lower border of lung does not extend so far down as pleura does; lower part of costal pleura is therefore in contact with diaphragmatic, and capillary interval between them is called the **costo-diaphragmatic recess.** Similarly, anterior margins of lungs may fall short of pleura, and lower part of ant. margin of left lung always does so; the unoccupied space is called the **costo-mediastinal recess.**

Lines of pleural reflexion are lines along which costal pleura becomes continuous with mediastinal pleura anteriorly and posteriorly, and with diaphragmatic pleura inferiorly.

Diaphragmatic line, in mid-axillary line, is two inches or less above costal margin; and at the back the **pleura falls below the level of vertebral end of 12th rib.**

Pleura is held in position along line of diaphragmatic reflexion by a fibrous ribbon, called *phrenico-pleural fascia*, which connects it to uncovered part of diaphragm and to costal cartilages.

Blood-vessels; bronchial and pulmonary to pulmonary pleura; intercostal and pericardiaco-phrenic to parietal pleura. **Lymph-vessels**; from pulmonary pleura to glands in hilum of lung; from parietal to glands in back part of thorax, in root of neck, and along int. mammary art. **Nerves**: phrenic and intercostal to parietal; sympathetic, through pulmonary plexuses, to pulmonary.

MEDIASTINUM

Mediastinum is the region between the two pleural sacs.

Divided by pericardium into four:—

1. **Middle mediastinum,** occupied by pericardium with its contents, and by phrenic nerves and pericardiaco-phrenic vessels.
2. **Anterior mediastinum,** in front of pericardium—between it and body of sternum. *Contains* areolar tissue, lymph-glands and lymph-vessels, small blood-vessels, and lowest part of thymus.
3. **Posterior mediastinum,** behind pericardium and diaphragm, in front of the lower 8 thoracic vertebræ.
4. **Superior mediastinum,** above the other three mediastina.

Bounded in front by manubrium, behind by the upper 4 thoracic vertebræ, and below by an oblique plane drawn between lower borders of manubrium and 4th thoracic vertebra.

Contents of Superior Mediastinum

1. Arch of aorta and its three branches.
2. Upper right aortic intercostal artery.
3. Thoracic parts of innominate veins and extra-pericardial part of superior vena cava.
4. Arch of vena azygos.
5. Trachea and œsophagus.
6. Thoracic duct and mediastinal lymph-trunks.
7. Vagi, phrenics, left recurrent laryngeal nerve and cardiac nerves.
8. Thymus.
9. Lymph-glands, especially at bifurcation of trachea.
10. Sterno-hyoids and sterno-thyroids on the back of manubrium, and longus cervicis muscles on the backbone.

Position of the chief structures:—*Œsophagus* is on the front of the backbone.

Trachea is in front of œsophagus.

Arch of aorta is first in front of trachea opposite the lower half of manubrium, and then on the left side of trachea and œsophagus.

Innominate and *left common carotid* arteries are opposite upper half of manubrium, first in front of trachea and then on its sides.

Left subclavian artery is farther back than the carotid—on the left side of trachea.

Right innominate vein and *superior vena cava* are to the right of innominate artery and the beginning of aortic arch.

Left innominate vein is in front of carotid artery, trachea and innominate artery, near the upper border of manubrium.

Thymus is in front of the vessels, in the median plane.

Vena azygos arches forwards across the right side of the lower end of trachea.

Thoracic duct ascends along the left border of œsophagus.

Right vagus is on the right side of trachea; and *right phrenic* is on the lateral side of right innominate vein and superior vena cava.

Left vagus and *phrenic* are first in the fat on the left side of trachea and then on the left side of aortic arch.

Left recurrent laryngeal curves medially below the arch and then ascends in the groove between œsophagus and the left border of trachea.

Thymus.—A pair of elongated, slender lobes united and ensheathed by fascia.

Behind manubrium and sterno-hyoids and sterno-thyroids; overlapped below by pleuræ. *In front of* left innominate and inf. thyroid veins; aortic arch, innominate and left common carotid arteries. It extends up into neck, lying on these two arteries and trachea; and inferiorly it reaches the front of pericardium. (*See also* pp. 324, 676.)

Right Innominate Vein.—Begins in neck, where it lies between medial part of clavicle and pleura (p. 340).

In thorax, first cartilage is *anterior* to it; phrenic nerve, pleura, lung are *lateral*; innominate art. is *medial*; trachea is posteromedial, separated by fat. It lies in a groove on medial surface of pleura and lung, so that they are slightly posterior and anterior as well as lateral, and overlap it in front at its termination opposite the lower border of the first cartilage.

Tributaries: vertebral and first posterior intercostal vein and right lymphatic duct *in neck*; int. mammary and inf. thyroid veins *in thorax*.

Innominate veins have no valves.

Left Innominate Vein.—Also begins in neck, between clavicle and pleura (p. 340).

In thorax, it passes to the right and slightly downwards, near upper border of manubrium, to end at lower border of first right cartilage close to sternum by joining right vein to form sup. cava.

It is *behind* thymus, sterno-thyroids and manubrium. It is *in front of* left common carotid and innominate art., and in front of trachea and pretracheal fascia, which are behind and between those arteries. It is just *above* the arch of aorta.

Tributaries: vertebral, first posterior intercostal and thoracic duct *in the neck*; internal mammary, inferior thyroid and left superior intercostal *in the thorax*.

Inferior thyroid veins run downwards for a short distance in thorax, in front of trachea and innominate artery, behind thymus. They end in respective innominates; or they may join into one trunk which may end in either innominate.

Venæ comitantes of int. mammary art. unite, opposite the third cartilage or a little lower, to form one trunk, which lies on medial side of its artery, and ends in innominate vein at the inlet of thorax.

Left superior intercostal vein, formed by 2nd and 3rd posterior intercostal veins. Descends to aortic arch; then passes forwards and upwards across left side of aortic arch and root of left subclavian artery, to end in left innominate. Pleura and phrenic nerve are lateral to it; other nerves that cross aortic arch are medial to it.

Superior Vena Cava.—Has no valves. Begins behind lower border of first right cartilage close to sternum by the union of two innominates. Descends vertically and pierces pericardium opposite second cartilage. Ends in upper and back part of right atrium opposite third cartilage.

Part in superior mediastinum lies in a groove on the medial surface of lung, so that pleura and lung are behind, lateral, and in front—the anterior part separating it from int. mammary vessels, and from structures in first intercostal space and edge of manubrium. Phrenic nerve and accompanying vessels are lateral to it, between it and pleura. End of ascending aorta and origin of innominate art. are medial to it. Trachea and cardiac nerves are behind and medial, separated by fat. V. azygos enters its posterior surface immediately above pericardium.

(Part of sup. v. cava in fibrous pericardium is covered on front and sides with serous pericardium. Asc. aorta is medial and anterior. Pericardium separates it from pleura and lung in front; from phrenic nerve and pericardiaco-phrenic vessels, pleura and lung laterally; from upper right pulmonary vein, right pulmonary art. and bronchus, posteriorly.)

As the **vena azygos** arches forwards to join vena cava, it grooves the lung just above the hilum, so that pleura and lung are above as well as lateral. Root of lung is below. Œsophagus, vagus and trachea are medial.

Arch of Aorta.—Lies in superior mediastinum opposite lower half of manubrium. Crosses lower part of mediastinum from right side of breast-bone to left side of backbone. Begins behind right margin of sternum, opposite second right cartilage; passes first to the left and then backwards; and ends at lower border of left side of 4th TH. vertebra. Curved with a concavity downwards, and curved with a concavity to the right and backwards.

First inch almost transverse. Lies *in front of* lowest inch of trachea, pretracheal fascia and deep cardiac plexus; *behind* lower half of manubrium and lower end of thymus, overlapped equally by right and left pleura and lung.

Remainder directed backwards, with trachea and œsophagus *medial* to it, and left pleura and lung *lateral* to it—making a broad groove on medial surface of lung just above hilum.

In addition, on its *medial* side, there are left recurrent laryngeal nerve between trachea and œsophagus, and thoracic duct on left

margin of œsophagus ; and, on its *lateral* side, four nerves descend across it between it and pleura—the left phrenic and two nerves going to superficial cardiac plexus and the left vagus, in that order from before backwards—and the left superior intercostal vein passes forwards and upwards over it.

Upper surface gives off three branches—innominate, left common carotid and left subclavian. The left innominate vein is above the arch, in front of these branches.

Below the arch are :—1. Bifurcation of pulmonary trunk.

2. Root of left lung.

3. Lig. arteriosum, in the substance of fibrous pericardium, stretching from root of left pulmonary artery to the arch.

4. Superficial cardiac plexus, in front of ligamentum arteriosum.

5. Recurrent laryngeal branch of left vagus, hooking round arch behind the attachment of lig. arteriosum.

Innominate Artery.—Arises from aortic arch opposite the centre of manubrium, in front of trachea. Extends upwards and to the right into neck, to end behind the upper part of right sterno-clavicular joint, on the right side of trachea, by dividing into right common carotid and subclavian.

No other branches, except occasional thyreoidea ima.

In thorax, the manubrium, sterno-hyoid and sterno-thyroid, and thymus are *anterior to it* ; left innominate vein crosses it, deep to thymus ; inf. thyroid vein or veins cross it to join right innominate. Trachea and pretracheal fascia are *posterior*. Lower part of right innominate vein and beginning of sup. cava are *on its right side*. Left common carotid is *on its left side*.

Left Common Carotid Artery.—Arises from aortic arch, in front of trachea, close to the left side of the origin of innominate.

Extends upwards and to the left, passing from anterior surface of trachea to its left side, and enters neck behind left sterno-clavicular joint. No branches in thorax.

Manubrium, sterno-hyoid, sterno-thyroid, thymus and left innominate vein are *in front*.

On its right side are innominate artery below, trachea above.

Behind it : trachea below ; recurrent laryngeal n. and edge of œsophagus and subclavian art. (which is also to the left) above.

On its left side, in front of subclavian artery, are phrenic, vagus and cardiac nerves ; pleura and lung.

Left Subclavian Artery.—Arises from aortic arch behind and to the left of carotid, a little distance from it.

Ascends in a groove on medial surface of lung, and enters neck opposite sterno-clavicular joint, some distance behind the joint.

No branches in thorax.

Anterior and medial are the vagus, phrenic and cardiac nerves and left common carotid. *Medial to it* at first is the trachea, and higher up the recurrent laryngeal n. and œsophagus. *Posterior to it* medially, are œsophagus below, thoracic duct and longus cervicis above ; and posterior to it, laterally, are pleura and lung. Pleura and lung are *lateral to it*, and, since it lies in a groove, they are slightly anterior and posterior as well ; and left superior intercostal vein often crosses its root.

Trachea.—In median plane, but its lower end inclines to the right. Ends by dividing into two bronchi at the level of the sternal angle, opposite the interval between 3rd and 4th thoracic spines.

Anterior to it there are :—1. Manubrium.

2. Sterno-thyroids, at its upper part.

3. Anterior margins of pleuræ and lungs, overlapping lower part.

4. Thymus, deep to all these.

5. Left innominate vein, crossing obliquely, deep to thymus.

6. Inferior thyroid veins, descending to innominates.

7. Aortic arch, on lowest inch of trachea.

8. Innominate and left common carotid, arising on front of trachea and passing upwards and sidewards, deep to left innominate vein.

9. Pretracheal fascia.

10. Lymph-glands and deep cardiac plexus at bifurcation.

11. Superior vena cava and lower end of right innominate vein are anterior but also to the right, a little distance away, separated by fatty areolar tissue.

On the left side there are :—(1) Pleura and lung, separated by—

(2) Aortic arch at the lowest inch of the trachea.

(3) Above arch, the left subclavian is on side of trachea, but passes on to œsophagus higher up, and then—

(4) Left carotid lies on side of trachea.

(5) Vagus and phrenic, descending in the interval between carotid and subclavian, and passing on to the arch.

(6) Cardiac branches of vagus and sympathetic—those to deep cardiac plexus are first on left side of trachea and then anterior, those to superficial plexus accompany phrenic and vagus.

On its right side there are :—1. Pleura and lung.

2. Vagus passing downwards and backwards to reach back of bronchus.

3. Cervical cardiac branches of sympathetic, of vagus and of recurrent laryngeal n., descending along the side of trachea, but gaining the front of it at the lower end.

4. Vena azygos arching forwards across the lower end.

Posterior to trachea there are :—1. Œsophagus.

2. Prevertebral fascia and longus cervicis muscles.

3. Backbone.

4. Left recurrent laryngeal n., in groove between left margin of trachea and œsophagus.

Œsophagus.—*Behind* the trachea on *the front* of the backbone and the longus cervicis muscles.

On its right side are pleura and lung, separated only by v. azygos where it arches forwards at the junction of the superior and posterior mediastina.

On the left side, pleura and lung are related to a rather less extent. For (1) thoracic duct, having come from behind œsophagus, runs up along its left side ; (2) aortic arch intervenes between it and pleura in the lowest part of superior mediastinum ; and (3) the left subclavian in uppermost part. Left recurrent laryngeal n. ascends between its left border and trachea.

Right Phrenic Nerve.—Enters thorax, accompanied by pericardiaco-phrenic vessels, on lateral side of right innominate vein,

and descends through superior mediastinum with pleura and lung *lateral to it*, innominate vein and sup. cava *medial to it*. [In middle mediastinum it has pleura and lung *lateral to it*, pericardium and termination of inf. vena cava *medial to it*, root of lung and pulmonary lig. *posterior to it*, some distance away.]

Left Phrenic Nerve.—Passes from behind left innominate vein and enters thorax, in front of subclavian artery, on the medial surface of pleura.

In its whole thoracic course, like the right nerve, pleura and lung are lateral to it, and pericardiaco-phrenic vessels accompany it.

In superior mediastinum, it lies to the left of trachea, at first in the interval between carotid and subclavian arteries, where it crosses vagus, superficially, (latero-medially); lower down, it crosses aortic arch, on the lateral side of left superior intercostal vein, in front of vagus and superficial cardiac nerves.

[In middle mediastinum, it is between pericardium and pleura, a little in front of lung-root and pulmonary lig.]

Phrenic nerves give branches to parietal pleuræ and pericardium; pierce *diaphragm*; *supply it* and give twigs to structures below it. The root of phrenic from 5th cervical nerve sometimes descends into thorax before it joins the phrenic trunk.

Right Vagus Nerve.—Leaves the neck by passing downwards and backwards between innominate artery and vein.

As it enters the thorax, it inclines medially in the fat behind the innominate artery to reach the anterior part of the right side of trachea. Runs downwards and backwards over side of trachea, with pleura and lung and arch of azygos vein lateral to it; and breaks up into posterior pulmonary plexus on the back of the root of the lung.

While on trachea it gives:—1. Branches to œsophagus.

2. Branches which descend to the deep cardiac plexus.

3. Branches to the anterior pulmonary plexus.

Left Vagus Nerve.—Escapes from behind the left innominate vein at the inlet of thorax, and enters thorax in front of subclavian artery. Descends along the medial side of the pleura, to the left of trachea, at first in the groove between subclavian and carotid arteries, where it is crossed superficially, from left to right, by phrenic nerve. Lower down it crosses aortic arch deep to (*i.e.* medial to) the left superior intercostal vein, and behind the phrenic and the two nerves which go to the superficial cardiac plexus.

From the arch it passes to the back of the root of the left lung to break up into the posterior pulmonary plexus.

As it crosses the arch, it gives off:—1. The recurrent laryngeal.

2. Branches to the anterior pulmonary plexus.

Left recurrent laryngeal nerve arises as vagus crosses aortic arch. Turns medially below arch, behind attachment of lig. arteriosum; reaches groove between trachea and œsophagus, in which it ascends to neck. As it lies in groove, the arch is anterior to it and to its left, below; above that, the subclavian artery is first anterior and then on its left side; and common carotid is anterior at thoracic inlet.

It gives branches to:—1. The deep cardiac plexus as it hooks round aorta.

2. Trachealis muscle and œsophagus as it ascends in the groove.

Cardiac Nerves.—The two cervical cardiac branches of right vagus, and the three cervical cardiac branches of right sympathetic trunk, having crossed subclavian artery, are joined by cardiac branches of right recurrent laryngeal, and all pass downwards and medially, behind innominate art., to the trachea, and, together with thoracic cardiac branches of right vagus and right sympathetic trunk, they descend over trachea to the **deep cardiac plexus** on its bifurcation.

Similar cervical cardiac branches of left vagus and sympathetic enter thorax and run down in front of subclavian artery. The uppermost branch of sympathetic and lower branch of vagus accompany phrenic and vagus across aortic arch, and end in superficial cardiac plexus; the others reach the trachea between subclavian and carotid arteries, and descend over it to deep plexus, which is joined also by branches of left recurrent laryngeal and by thoracic cardiac branches of left sympathetic trunk.

Thoracic cardiac branches of sympathetic trunk spring from 2nd, 3rd and 4th thoracic ganglia, run downwards and medially over the backbone to reach œsophagus, cross the side of œsophagus to reach trachea and join cardiac plexus.

Thoracic duct emerges from behind the œsophagus and ascends along its left border. Aortic arch is anterior and on its left, below. Pleura is on its left and subclavian artery is anterior, above.

An exceedingly slender **mediastinal lymph-trunk** ascends into neck along each margin of œsophagus.

Contents of Posterior Mediastinum

Descending thoracic aorta and its branches. Œsophagus. Vagi. Azygos and hemiazygos veins. Thoracic duct. Lymph-glands alongside aorta. Areolar tissue and fat.

Aorta is first on the left side of the vertebral bodies, and then on the front of them.

Œsophagus is first on the right side of aorta, and then on the front of it.

Vagi form a plexus around the œsophagus.

Azygos vein is on the front of the vertebral bodies to the right of the aorta.

Thoracic duct is between vena azygos and aorta.

Hemiazygos veins are on the vertebral bodies, at first vertically behind the left side of the aorta and then cross behind it.

Descending Thoracic Aorta.—Begins, as a continuation of aortic arch, at left side of lower border of body of 4th TH. vertebra.

Runs downwards and slightly forwards and to the right, from the left side of the backbone on to the front of it.

Ends in the median plane by passing through the aortic opening of diaphragm and becoming continuous with the abdominal aorta, at the lower border of 12th thoracic vertebra.

Relations.—*Anterior to it*, from above downwards, are:—1. Root of left **lung**. 2. Pericardium, which separates it from left atrium;

at and below root of lung the left vagus emerges from posterior pulmonary plexus and crosses in front of it to reach œsophagus. 3. Œsophagus and vagi, which separate it from the lower part of pericardium. 4. Diaphragm, which separates it from lesser sac of peritoneum and caudate lobe of liver.

Posterior to it are. 1. Left pleura and lung, slightly, at upper part. 2. Lower eight thoracic vertebræ and ant. longitudinal lig. 3. Transverse parts of hemiazygos veins, opposite 8th and 9th vertebræ. 4. Roots of intercostal and subcostal arteries. 5. Vertical parts of hemiazygos veins are behind it rather than to the left of it.

On its left side are left pleura and lung, and close by it, farther back and covered with pleura, are the vertical parts of hemiazygos veins, with splanchnic nerves immediately lateral to them.

On its right side, all the way, are thoracic duct and vena azygos, the duct being between vein and aorta. In front of duct and vein, the œsophagus is on right side of aorta opposite 5th, 6th and 7th vertebræ; below that, the œsophagus gets in front of aorta, and aorta is separated from right pleura by the fat and areolar tissue that lie in front of thoracic duct and azygos vein.

Branches: Nine pairs of intercostals, one pair of subcostals, a few phrenic, two left bronchial, one right bronchial (which may arise elsewhere), small œsophageal, pericardial and mediastinal.

Intercostal and subcostal arteries, clinging to the vertebræ, pass sidewards and backwards out of the mediastinum. (*See* p. 356.)

Phrenic are small branches to the posterior part of diaphragm.

Œsophageal, pericardial and **mediastinal** are small irregular branches to œsophagus, to the posterior part of pericardium, and to the areolar tissue, fat and lymph-glands in posterior mediastinum.

Two **left bronchial arteries** arise from descending aorta near its beginning; they run sidewards and downwards to the back of the left bronchus and accompany it into lung.

One **right bronchial artery** arises from the first right aortic intercostal after it has crossed œsophagus; it runs forwards across the right side of œsophagus to the back of the right bronchus and follows it into lung. It may arise from the upper left bronchial or from the aorta, and it then crosses behind the œsophagus to reach the right bronchus.

Œsophagus.—Enters the posterior mediastinum on the right side of aorta. Remains on its right side opposite 5th, 6th, 7th TH. vertebræ; then inclines forwards to lie on the front of aorta; and before it passes through the œsophageal opening in diaphragm, opposite 9th thoracic spine, it is slightly to the left of aorta, but still in front.

Relations.—In close relation, all around it, there is the *œsophageal plexus* formed by the two vagi.

Anterior to it, from above downwards, are: (1) left bronchus; (2) right pulmonary art.; (3) pericardium, which separates it from left atrium; (4) diaphragm.

On left side of œsophagus there are descending aorta above, left pleura and lung below. Left pulmonary ligament is usually attached to the left side of the œsophagus; but it may be attached to the pericardium in front of the œsophagus.

Right pleura and lung are *on its right side* until it has come to lie anterior to aorta, where it is overlapped on the right by pericardium and diaphragm.

Posterior to it, opposite 5th, 6th, 7th vertebræ, the thoracic duct and vena azygos ascend vertically, upper five right aortic intercostals cross behind vein and duct. Below that level the aorta is posterior, and the lower part, which protrudes to the left of the aorta, is supported posteriorly by pleura and lung.

Nerves that connect the two posterior pulmonary plexuses pass in front of œsophagus and behind it, opposite the bronchi.

Vagi.—Left vagus emerges from the posterior pulmonary plexus as one or two cords which pass over the right margin of the descending aorta to reach the front of the œsophagus, where they break up to form the anterior part of the œsophageal plexus.

Right vagus emerges from the posterior pulmonary plexus as one or two cords which cross in front of vena azygos and break up into a plexus on the back of œsophagus.

Œsophageal Plexus.—Surrounds œsophagus. Formed by the vagi and filaments from the greater splanchnic nerves. Gives branches to the œsophagus and the back of the pericardium.

The **anterior and posterior gastric nerves** arise from the front and the back of it, and descend through the œsophageal opening of the diaphragm; each carries branches of both vagi and of the greater splanchnics to the abdomen.

Vena azygos has right subcostal and intercostal arteries behind it; thoracic duct and descending aorta to its left; pleura on its right; diaphragm and œsophagus in front. (*See also* p. 358.)

Inferior Hemiazygos Vein.—Arises from the back of the left renal vein. Enters thorax by piercing the left crus of diaphragm. Ascends in front of the bodies of the lower thoracic vertebræ, and in front of the left subcostal and intercostal arteries. It is close to the left side of the descending aorta and rather behind it. The splanchnic nerves descend close by its lateral side. It is covered by pleura antero-laterally, and may be excluded from mediastinum while it ascends. At the level of the 9th vertebra it turns abruptly to the right, behind aorta and thoracic duct, and ends in v. azygos.

Receives left subcostal, lower three or four left intercostals, and a few posterior mediastinal veins.

If its abdominal part is atrophied, it begins in thorax by the union of left ascending lumbar vein and left subcostal vein, on the side of 12th thoracic vertebra, under cover of diaphragm.

Superior Hemiazygos Vein.—Begins at the vertebral end of the 9th intercostal space. Runs obliquely downwards and forwards over the left side of the bodies of 5th to 8th vertebræ and intercostal arteries. At the 8th vertebra, it turns abruptly to the right, behind aorta and thoracic duct, and ends in v. azygos.

It is covered with pleura. Descending aorta is medial to it and in front of it. Upper roots of greater splanchnic nerve are lateral to it.

Communicates with the left superior intercostal vein and with the inferior hemiazygos vein and may end in it.

Receives left bronchial vein and the 4th to the 7th or 8th left intercostal veins.

Thoracic Duct.—Springs from the upper end of cisterna chyli, which lies in the abdomen on the front of the upper two lumbar vertebræ along the right side of abdominal aorta (p. 378).

Enters the thorax through the aortic opening of diaphragm. Ascends over the front of the vertebral column till, at the level of the 5th thoracic vertebra, it inclines to the left to ascend, in the *superior mediastinum*, along the left border of œsophagus.

In the posterior mediastinum, the descending aorta is on its *left side* throughout; and vena azygos on its *right side*.

Right subcostal and intercostal arteries and the ends of the hemiazygos veins are *behind* it, between it and the anterior longitudinal lig. and vertebral bodies. *In front of* it, there are:—first, the diaphragm; next, the fatty tissue that separates the aorta and vena azygos from the right pleura; and then, the œsophagus and vagi from the level of the 8th vertebra to the 5th.

Descending Lymph-Trunks.—These are a pair of vessels that run down from lymph-glands in the lower intercostal spaces, cross the vena azygos and aorta superficially, and pass through the aortic opening of the diaphragm to end in cisterna chyli.

PULMONES

Lungs.—Soft, spongy, pliable; float in water; exceedingly elastic, so that they shrink to one-third when thorax is opened. Dark and mottled in adult, pink in early life. Pyramidal in shape.

Apex.—Rounded; includes that part which lies above level of anterior end of first rib, behind and above sternal third of clavicle; its summit lies in front of neck of first rib, nearly an inch above level of clavicle. Grooved by subclavian artery on medial side and front.

Base.—Semilunar in outline, concave; rests on diaphragm, which separates *right* lung from liver, *left* lung from liver, stomach and spleen.

Costal Surface.—Large and convex; includes the bulky, posterior part of lung. **Posterior border** is an ill-defined line between the costal surface and the posterior part of the medial surface opposite the heads of the ribs; it extends from the level of the 7th cervical spine to the level of the 10th thoracic spine.

Anterior border.—Shorter than posterior; begins at apex, curves downwards and medially, becomes sharp about an inch below summit, behind sterno-clavicular joint; extends to middle of sternal angle, and then down to

xiphi-sternal joint. The anterior border of left lung, near its lower end, has a wide notch, called *cardiac notch*, which leaves part of the front of pericardium uncovered by lung.

Medial Surface.—Divided into *vertebral area*, adapted to sides of bodies of vertebræ, and *mediastinal area*, in relation to mediastinal septum. Mediastinal area presents **hilum**, not covered with pleura, where bronchi, pulmonary vessels, bronchial vessels, lymph-vessels, nerves enter and leave lung. Below hilum a thin strip, not covered with pleura, extends to inferior border and marks attachment of pulmonary lig. Below and in front of hilum there is a wide hollow for heart and pericardium.

Inferior border.—Limits base. Blunted where it separates base from mediastinal surface. Thin and sharp elsewhere, and falls considerably short of pleural reflexion. Corresponds to a line drawn from xiphi-sternal joint to a point half an inch from 10th thoracic spine; line is slightly convex downwards, reaching lowest level at mid-axillary line about four inches above costal margin.

Lobes and Fissures of Lung.—Left lung is cleft into two lobes by **oblique fissure**, which cuts into it as far as hilum and appears on all its surfaces. Begins about 2½ in. below the summit, opposite 3rd thoracic spine; ends a little behind lower end of anterior border, opposite 6th or 7th cartilage, about two inches from median plane.

Upper lobe includes apex and anterior border and greater part of mediastinal area, and is the part under consideration when the front of the living chest is examined. **Lower lobe,** bulkier, includes almost whole base and greater part of the back, and is examined from the side and the back.

Right lung is cleft by two fissures into three lobes. **Oblique fissure** is like that of the left. **Transverse fissure** begins at ant. border, at the level of 4th costal cartilage; extends sidewards and slightly upwards to meet oblique fissure about its middle, opposite mid-axillary line.

Lower lobe includes slightly less of base than in left lung. **Upper lobe** is smaller than in left lung because the middle lobe is cut off from it. **Middle lobe** is wedge-shaped, and it includes lower part of ant. border and greater part of pericardial hollow.

Differences between Right and Left Lung.—Right lung, tri-lobed; larger in ratio of 11 to 10. Shorter, owing to

greater upward bulging of right lobe of liver; wider, because heart bulges less to right side. Base more concave, because of liver; pericardial hollow shallower; cardiac notch small or absent. Different markings on mediastinal area.

Arteries of Lungs.—Pulmonary convey blood for aëration. Bronchial supply lung-substance, and their blood is returned both by bronchial and by pulmonary veins.

Lymph-vessels end in glands within lung and in hilum.

Nerves, from vagus and sympathetic, through pulmonary plexuses.

Relations of Medial Surface of Lung and Mediastinal Pleura

Pleura intervenes between lung and structures mentioned below: i.e. *the structures exposed by removal of lung, pleura (and pericardium) in a dissection of thorax from the side.*

Vertebral Area.—*On both sides,* it is related to intercostal vessels, roots and trunks of splanchnic nerves; and *on left side,* in addition, to the vertical parts of the hemiazygos veins.

Mediastinal Area.—**On Right Lung.**—1. *Pericardium and heart* are in the wide concavity in front of the hilum and pulmonary ligament.

2. Upper end of *inferior vena cava* is in the "thumb-print" impression at the lowest part of the pericardial hollow, just in front of the pulmonary ligament.

3. A wide, shallow, vertical groove for *superior vena cava* begins in the pericardial hollow in front of the hilum, about its middle, and runs upwards. Its upper end divides into two grooves for the ends of the innominate veins—the *right* behind, the *left* in front.

4. The area in front of this vena-caval groove is related to the *thymus* and to the end of *ascending aorta* and the beginning of the *aortic arch.*

5. *Right phrenic nerve* and *pericardiaco-phrenic vessels* make a narrow groove in the floor of the impressions for right innominate vein, superior vena cava, pericardium and inferior vena cava.

6. *Arch of vena azygos* makes a clean-cut, horizontal groove immediately above the hilum.

7. The area above this groove and behind the groove for superior vena cava is for the *trachea, right vagus* on the side of trachea and *œsophagus* behind trachea.

8. The strip behind the hilum and pulmonary ligament is related to the *œsophagus* and to the *vena azygos* behind œsophagus.

On Left Lung.—1. *Pericardium, heart, pulmonary trunk* and middle part of *ascending aorta* are related to the floor of the wide concavity in front of the hilum and pulmonary ligament.

2. *Descending thoracic aorta* makes a wide, shallow, nearly vertical groove behind the hilum and pulmonary ligament.

3. Lower part of *œsophagus* makes a small impression in front of the lowest part of this aortic groove.

4. *Arch of aorta* makes a wide, horizontal groove above the hilum and above the pericardial hollow. Above the hilum, this groove is distinct; and, here, the pleura and lung are related not only to the aorta but also to the *left vagus*, *left phrenic nerve* and *pericardiaco-phrenic vessels*, two *cardiac nerves*, and to the *left superior intercostal vein*. Above the pericardial hollow, the groove is indistinct or absent, for, there, the arch is separated from the pleura by fatty tissue and the remains of the *thymus*.

5. *Left subclavian artery* makes a well-marked vertical groove that runs up from the aortic groove in line with the front of the hilum.

6. The area behind the subclavian groove is related to the *œsophagus*, to the *thoracic duct* on the left side of œsophagus, and to the *left recurrent laryngeal nerve* in front of œsophagus.

7. The area in front of the subclavian groove is small; it is related to the *left common carotid* and to the *left phrenic* and *vagus* (between the two arteries). The arteries and the nerves and the fat around them separate the pleura from the left side of the *trachea*.

8. The *left phrenic nerve* and *pericardiaco-phrenic vessels* make a narrow groove (*a*) between the impressions for carotid and subclavian arteries, (*b*) across the groove for aortic arch, and (*c*) in the pericardial hollow a little in front of the hilum.

Relations of Cervical Pleura and Apex of Lung.—*See* p. 327.

ROOT OF LUNG

Composed of pulmonary artery, two pulmonary veins, bronchus, bronchial artery and veins, lymph-vessels and glands, and pulmonary plexuses—all surrounded by pleura at their entrance into lung.

Relations of these to one another.—*From before backwards*: anterior pulmonary plexus; upper pulmonary vein; pulmonary artery; bronchus; bronchial vessels and posterior pulmonary plexus. *From above downwards, on right side*: eparterial bronchus, artery, hyparterial bronchus, lower vein; *on left side*: artery, bronchus, lower vein.

Relations of Whole Root.—Right Root: *Anterior*: vena cava superior, phrenic nerve. *Superior*: arch of vena azygos. *Posterior*: the posterior lip of the hilum. *Inferior*: pulmonary ligament.

Left Root.—*Anterior*: phrenic nerve. *Superior*: aortic arch. *Posterior*: posterior lip of hilum; descending aorta. *Inferior*: pulmonary ligament.

DIGESTIVE SYSTEM

ALIMENTARY CANAL. DIGESTIVE GLANDS. ACCESSORY PARTS

ALIMENTARY canal comprises :—(1) *Mouth*, (2) *oro-pharyngeal isthmus*, (3) *pharynx*, in the head and neck ; (4) *œsophagus* begins in neck, traverses thorax and ends in abdomen ; (5) *stomach*, (6) *small intestine*, (7) *large intestine* occupy abdomen and pelvis. Small intestine is divided into duodenum, jejunum, ileum. Large intestine is divided into cæcum, with vermiform appendix, ascending colon, right colic flexure, transverse colon, left colic flexure, descending colon, pelvic colon, rectum and anal canal.

Digestive glands are: (1) the *salivary*—parotid, submandibular, sublingual ; (2) *liver*, (3) *pancreas* ; besides (4) small glands in walls of all parts of alimentary canal.

Accessory parts are *teeth*, *gums*, *palate*, *tongue*, *tonsils* and *peritoneum*.

CAVITY OF MOUTH

Mouth is divided into vestibule and cavity proper.

Vestibule of mouth is the space that separates lips and cheeks from teeth and gums.

Communicates with cavity proper through opening behind last molar tooth. Behind that opening the coronoid process and tendon of temporal muscle may be felt ; and lateral to it, the anterior edge of masseter.

Parotid duct opens into vestibule opposite second upper molar ; and numerous mucous glands open into vestibule. In median plane, mucous membrane is raised, between lips and gums, as folds called the *frenula of the lips*.

Lips are composed of :—(1) Skin ; (2) superficial fascia ;

(3) orbicularis oris; (4) submucous tissue, with vessels and mucous *labial glands*, palpable by the tongue; (5) mucous membrane, covered with stratified epithelium.

Philtrum is the vertical groove in middle of upper lip.

Arteries.—Labial branches of facial; branches of mental also to lower lip.

Nerves.—Branches of facial supply muscles; infra-orbital, buccal and mental branches of trigeminal supply skin and mucous membrane.

Lymph-vessels of both lips end in glands immediately below body of mandible; from median part of lower lip, in glands below chin.

Buccæ (Cheeks) resemble lips. (1) Skin. (2) Superficial fascia, containing the zygomaticus major, risorius, platysma muscles; parotid duct, surrounded by mucous *molar glands*; vessels, and branches of facial and trigeminal nerves. (3) Buccinator, covered with the bucco-pharyngeal fascia, and pierced by parotid duct. (4) Submucosa, with mucous *buccal glands*. (5) Mucous membrane, covered with stratified epithelium.

Buccal pad is an encapsuled mass of fat that lies on buccinator partly under masseter and partly in front of it. Relatively larger in child. Assists cheek to resist atmospheric pressure during sucking.

Arteries of the cheek.—Buccal branch of maxillary; branches of facial, mental and infra-orbital.

Lymph-vessels from ant. part of cheek end in glands below mandible; from posterior part, in glands on surface of parotid and inside it.

Nerves.—Branches of facial to muscles. Labial branches of infra-orbital and buccal and mental branches of mandibular, to skin and mucous membrane.

Cavity Proper of Mouth.—Bounded *in front* and *at the sides* by teeth and gums; *above* by hard and soft palate; *below* by tongue and sublingual region. Opens *posteriorly*, through the isthmus, into pharynx.

Sublingual region is region below tip and sides of tongue. Anteriorly, the mucous membrane stretches across from side to side, covering sublingual glands and upper borders of genio-glossi. At sides of tongue it is reflected from upper part of mylo-hyoid on to stylo-glossus and upper part of hyo-glossus, and covers lingual nerve as it enters submandibular region.

Frenulum of tongue—a median fold of the mucous

membrane which extends from the floor of the mouth to the under surface of the tongue.

Sublingual papilla—on each side of the attachment of frenulum to floor; submandibular duct opens on it.

Sublingual fold—a ridge which runs sidewards and backwards from the papilla. Produced by sublingual gland, which underlies it, and whose ducts open on the crest of the fold.

Lymph-vessels from floor of mouth end in glands within tongue and below mandible and chin.

Palate

Hard Palate.—Palatine processes of maxillæ and horizontal parts of palatine bones, covered inferiorly with periosteum, dense fibrous tissue, mucous membrane (covered with stratified epithelium) and numerous mucous *palatine glands* in posterior part of submucous tissue. Greater palatine vessels and nerve run forwards in the fibrous tissue near alveolar margin; long sphenopalatine nerves enter it behind incisor teeth.

Soft Palate.—Stretches downwards and backwards, as a movable fold, from hard palate almost to post. wall of pharynx, blending laterally with side-walls of pharynx.

Structures of soft palate (passing from pharyngeal to oral surface):—1. Mucous membrane with ciliated epithelium.
2. A layer of muscle (see below and p. 624).
3. Palatine aponeurosis.
4. Another layer of muscle.
5. Thick layer of mucous glands—much the thickest layer in the palate.
6. Mucous membrane with stratified epithelium.

Uvula hangs down from the middle of the free edge of soft palate. Consists of the posterior part of musculus uvulæ and mucous glands enclosed in a tube of mucous membrane.

Arteries of palate:—Greater and lesser palatine; ascending palatine; ascending pharyngeal.

Lymph-vessels of palate end in glands in infratemporal fossa and within parotid and thence to deep glands in neck.

Nerves: *Motor*, to tensor from mandibular through otic ganglion; to others from pharyngeal plexus (ultimately from accessory). *Sensory*: palatine and spheno-palatine branches of spheno-palatine ganglion; glosso-pharyngeal.

Muscles of Soft Palate.—Palato-glossus (p. 618); palato-pharyngeus (p. 624). Musculus uvulæ; levator palati; tensor palati.

Musculus Uvulæ.—A pair of small slips that spring from the posterior nasal spine, run backwards side by side in the substance of soft palate, unite into one and enter the uvula to be inserted into its mucous membrane. They lie between the layers of palato-pharyngeus. **Nerve :** accessory, through pharyngeal plexus (possibly facial, *via* greater petrosal and palatine).

Levator Palati.—**Origin** (fl.) : lower surface of petrous temporal near apex, medial surface of cartilage of pharyngo-tympanic tube.

Insertion (fl.) : palatine aponeurosis—many fibres also joining the opposite muscle between the layers of palato-pharyngeus.

Nerve : accessory or facial, the same as m. uvulæ.

It occupies the interval above superior constrictor, and crosses its upper border and pierces pharyngo-basilar fascia to enter palate.

Tensor Palati.—**Origin** (fl.-tend.) : sphenoid bone from scaphoid fossa to spine, and from lateral surface of pharyngo-tympanic tube.

Insertion (tend.) : palatine aponeurosis and palatine crest.

Nerve : mandibular, through otic ganglion. (*See also* p. 304.)

Palatine aponeurosis lies in the substance of the anterior two-thirds of the soft palate and stiffens it. It is attached to the palatine crests near the posterior edge of the bony palate. It is firm and strong anteriorly but fades away postero-inferiorly. It is continuous with pharyngo-basilar fascia laterally.

Oro-Pharyngeal Isthmus.—Bounded above by soft palate, below by tongue, on each side by *palato-glossal arch.*

The arch is a fold of mucous membrane which extends from oral surface of soft palate, near base of uvula, to middle of side of tongue, and encloses palato-glossus muscle. The tonsil lies behind the arch.

LINGUA (TONGUE)

Tongue is divided by a thin median septum of fibrous tissue into right and left halves, composed of :—

1. **Muscles**—*extrinsic* and *intrinsic.*
2. Finely divided **fat,** among the muscles.
3. **Glands**—*mucous,* at the sides and back ; *serous,* near the vallate papillæ ; *sero-mucous* (anterior lingual), among the muscles on the inferior surface near the apex.
4. A covering of **mucous membrane.**

Dorsum Linguæ.—Divided into two.

(1) **Pharyngeal part** looks backwards into pharynx. Covered with smooth mucous membrane, studded with pitted nodules produced by underlying lymphoid follicles, collectively named *lingual tonsil.* Connected with the

epiglottis by a median ridge of mucous membrane called glosso-epiglottic fold.

(2) **Oral part** looks towards palate. Its mucous membrane is roughened by papillæ of various kinds (see next page). It is separated from pharyngeal part by a V-shaped groove, called *sulcus terminalis*, whose apex points backwards and is called *foramen cæcum*.

Apex and margins of tongue, in front of palato-glossal arches, are free and in contact with teeth.

Inferior surface of free part of tongue is covered with smooth mucous membrane and is connected with floor of mouth by the frenulum. On each side, the deep vein can be seen through mucous membrane. More laterally, there is a fringed fold, called the **fimbriated fold**; the deep artery is under cover of it.

Root of tongue is the fixed part connected by muscles and mucous membrane to hyoid bone, mandible, pharynx, epiglottis, and palate.

Extrinsic Muscles.—Stylo-glossus, hyo-glossus and genio-glossus (p. 315); supplied by the hypoglossal nerve. Palato-glossus, supplied by the accessory nerve through the pharyngeal plexus. These muscles alter the shape of the tongue and move it bodily in different directions.

Palato-glossus lies in palato-glossal arch, and it also forms lowest muscular stratum of soft palate.

Origin (fl.): lower surface of palatine aponeurosis, blending with the muscle of the opposite side.

Insertion (fl.): posterior part of side of tongue, and mingles with transverse fibres of tongue.

Elevates tongue; constricts oro-pharyngeal isthmus.

Intrinsic Muscles.—Superior and inferior longitudinal, transverse and vertical—all supplied by the hypoglossal nerve.

Superior longitudinal muscle lies under the mucous membrane of dorsum of tongue, and extends from tip to back.

Inferior longitudinal muscles lie, one on each side, in the lower part of the tongue, deep to hyo-glossus. Posterior fibres of each are connected with the hyoid bone.

The fibres of the **transverse muscle** extend from the median septum, through the substance of the tongue, to the sides and dorsum.

The fibres of the **vertical muscle** extend from the dorsum, downwards and laterally, to the sides.

These muscles alter the shape of the tongue and curve it in different directions.

Arteries of Tongue.—Lingual—chiefly. Very little anastomosis across median plane. **Lymph-vessels** mostly go to nearest glands: (*a*) from tip and lower surface to glands below chin; (*b*) from posterior third to glands behind angle of mandible in uppermost part of carotid triangle; (*c*) from remainder, to glands below mandible and glands in lower part of carotid triangle. **Veins.**—*See* p. 319.

Nerves.—Hypoglossal, to intrinsic and extrinsic muscles, except palato-glossus. Lingual (common sensory), including chorda tympani (taste), to the mucous membrane of the anterior two-thirds. Glosso-pharyngeal (common sensory and taste), to the mucous membrane of the posterior third. A few branches from internal laryngeal (common sensory) to dorsum, near epiglottis.

Papillæ of Tongue.—(1) **Vallate papillæ** about 10 in number, arranged in form of V, anterior and parallel to sulcus terminalis. Each is a short cylinder surrounded by circular trench, outer wall of which is raised up as a collar. Serous glands open into trench, and taste-buds lie in its walls. (2) **Fungiform papillæ** are more numerous; bright red in living subject; furnished with taste-buds; each is a rounded head attached by narrower base; found chiefly at apex and margins. (3) **Filiform papillæ** in great numbers, arranged posteriorly in rows parallel to sulcus terminalis, transverse and then irregular anteriorly. (4) **Folia linguæ**, five or six vertical folds, studded with taste-buds, on margins of tongue in front of palato-glossal arches.

TEETH AND GUMS

Each **tooth** has: a **crown**, covered with enamel; **neck**, surrounded by gum; **root**, imbedded in jaw. Each encloses a **cavity** containing **pulp**, composed of fine fibrous tissue, vessels and nerves, which enter through *foramen in apex* of root. Crown is chisel-shaped in *incisor* teeth, conical in *canine*; has two tubercles in *premolar*, a larger labial and smaller lingual; three or four tubercles in upper *molar*, four or five in lower molar.

Deciduous Teeth (Milk Teeth).—2 incisors, 1 canine, 2 molars, in each half of each jaw. *Medial upper is the largest of incisors.* Incisors and canine have single roots. Roots of upper molars are divided into three fangs, of lower into two. Distinguished from permanent teeth by small size, constricted necks, and, in the molars, by wide divergence of fangs. **Periods of eruption**: very variable; lower set precedes upper. *Begins* between *6th* and *9th months* after birth, *completed* about *24th month.* Appear in following order: medial incisors, lateral incisors, first molars, canines, second molars.

Permanent Teeth.—2 incisors, 1 canine, 2 premolars, 3 molars. Premolars replace deciduous molars. Permanent molars have no forerunners in deciduous dentition. The upper medial incisor is

largest of incisors and lower medial is smallest, with the result that teeth of the two jaws are not directly opposite, but each tooth of upper jaw touches two lower teeth, except third upper molar, which touches only third lower molar, and, being smaller, it does not extend farther back than the lower molar.

Root of incisors, canines, lower and second upper premolars are single. Root of first upper premolar is bifid. Roots of canine teeth are longer than those of others. Roots of upper molars are divided into three—two lateral, one medial. Lower molars into two, an anterior and a posterior, and each of these may be bifid at apex.

Periods of Eruption.—*First molar* about *6th year*; medial incisors, 7th; lateral incisors, 8th; first premolar, 9th; second premolar, 10th; canine, 11th; *second molar*, *12th*; third molar (wisdom tooth), 17th to 25th year.

Vessels and Nerves.—**Maxillary teeth** are supplied by superior dental branches of maxillary and infra-orbital nerves and vessels; their lymph-vessels end in glands on the surface of parotid and below mandible. **Mandibular teeth** are supplied by inferior dental branch of mandibular nerve and inferior dental branch of maxillary artery; and their lymph-vessels end in glands below mandible and in carotid triangle.

Gingivæ or **Gums.**—Attached to alveolar margins of jaws and surround necks of teeth. Consist of dense but vascular fibrous tissue, covered with mucous membrane.

SALIVARY GLANDS

PAROTID. SUBMANDIBULAR. SUBLINGUAL

Parotid Gland.—The largest. Lies in the hollow below the auricle, behind the mandible, enveloped in sheath prolonged from cervical fascia. Extends superficially up to zygomatic arch, and downwards beyond angle of mandible; overlaps sterno-mastoid and masseter; upper part of the masseter-overlap may be isolated and called **accessory parotid.** (*See also* p. 299.)

Parotid duct arises at anterior border. Runs forwards over masseter and then sharply medially through the fat of the cheek to pierce buccinator and mucous membrane opposite second upper molar.

Submandibular Gland (*see also* p. 316).—Lies between the bellies of digastric (which it overlaps), on hyo-glossus and mylo-hyoid, below the mucous membrane of the mouth, under cover of the mandible and pterygoideus medialis, and is supported inferiorly by skin, fasciæ and platysma. **Submandibular duct** arises from medial surface

and passes forwards, superficial to hyo-glossus and genio-glossus, deep to mylo-hyoid and sublingual gland, and opens at the side of the frenulum of the tongue.

Sublingual Gland (*see also* p. 317).—Smallest salivary gland. Lies above mylo-hyoid, between genio-glossus and mandible near symphysis, under sublingual fold in floor of mouth, upon which its **ducts** (8 to 20) open.

PHARYNX

A fibro-muscular tube lined with mucous membrane. Lies behind the nose, mouth, and larynx, and communicates freely with them, as it has no proper anterior wall. Extends from base of skull to 6th c. vertebra, where, at level of lower border of cricoid, it is continuous with œsophagus. Upper end is about level of zygoma and of junction of nasal bone with cartilage.

Attached superiorly to basi-occipital and petrous temporal; *anteriorly*, from above downwards, to: (1) pharyngo-tympanic tube; (2) medial pterygoid plate; (3) pterygo-mandibular ligament; (4) mylo-hyoid line and mucous membrane of mouth; (5) root of tongue and hyoid bone; (6) thyroid and cricoid cartilages.

Cavity of pharynx is divided into nasal, oral, and laryngeal parts, and is widest in the nasal part.

Nasal part is behind the cavity of nose, above and behind the soft palate. Belongs not to digestive but to respiratory tract. It communicates with oral pharynx through an opening called the *pharyngeal isthmus*.

Floor (the soft palate), movable; other walls, rigid. *Anteriorly*, the naso-pharynx communicates with nasal cavities through the posterior apertures of nose.

Side-wall measures a little over an inch each way; presents, in front of its centre, the pharyngeal opening of the *pharyngo-tympanic tube*, on a level with the inferior nasal concha and half an inch behind it.

Upper and posterior margins of the opening form a thick, curved prominence called the **tubal elevation**. From the posterior margin, a ridge of mucous membrane, called **salpingo-pharyngeal fold**, runs downwards on the side-wall of pharynx and gradually fades away. The elevation is produced by the curled, pharyngeal end of the cartilage of the tube; the fold is raised up by a slip of muscle

called salpingo-pharyngeus. Behind the elevation and the upper part of the fold there is a narrow vertical slit that leads into a flat pocket of mucous membrane called **pharyngeal recess**. The recess extends sidewards for half an inch or more between the tube and the prevertebral muscles, above upper edge of superior constrictor, below foramen lacerum and petrous temporal.

Roof and posterior wall form continuous slope, opposite posterior part of body of sphenoid, basi-occiput and the upper two cervical vertebræ. Under the mucous membrane, opposite basi-occiput, there is a collection of lymphoid tissue called **naso-pharyngeal tonsil**; it is small or absent in adult, but is well marked in child, and "adenoids" is a pathological enlargement of it. *Pharyngeal bursa* is a small median pit in the mucous membrane that covers this tonsil.

Pharyngeal Isthmus. — Oblique interval between soft palate and back of pharynx. May be wide enough to admit two fingers; may be too narrow to admit one. Bounded on each side by *palato-pharyngeal arch*. The arch is a ridge or fold of mucous membrane raised up by a muscular slip called palato-pharyngeus; it begins at posterior edge of soft palate, curves downwards and backwards on the side-wall of pharynx between nasal and oral parts, and gradually fades away.

Oral Part of Pharynx.—Behind mouth and tongue; communicates with mouth through oro-pharyngeal isthmus. Common to respiratory and digestive systems.

Posterior wall is smooth.

Side-wall is occupied by the tonsil.

The tonsil is an oval mass of lymphoid tissue that occupies the triangular space above back of tongue, below soft palate, between palato-glossal and palato-pharyngeal arches.

Medial surface is covered with mucous membrane which invades the substance of tonsil to line a number of deep, narrow crypts, called *tonsillar pits*—the widest of which is in its upper part and is called the *intra-tonsillar cleft*. Lateral surface is clothed with a fibrous sheet called its *capsule*. The capsule is attached by loose areolar tissue to the pharyngo-basilar fascia on the inner surface of the superior constrictor, and also by a fibrous band to the sheath of the stylo-glossus—which keeps the

tonsil in place during swallowing. One or more veins from the palate may descend over the lateral surface of the capsule; and the superior constrictor separates the tonsil from the facial artery at the point where the artery begins to arch downwards.

Upper end often invades lateral part of soft palate. Lower end is continuous with lingual tonsil.

Chief artery to tonsil is the tonsillar branch of facial, which enters the lower part of its lateral surface. *Veins* pierce superior constrictor and end in pharyngeal plexus. *Lymph-vessels* end in glands behind and below angle of mandible. *Nerves*: from glosso-pharyngeal, pharyngeal plexus and lesser palatine.

Laryngeal part of pharynx lies behind the larynx. Upper part is common to digestive and respiratory tracts. Lower part (narrowest part of pharynx), opposite cricoid, belongs to digestive system alone, and its anterior and posterior walls are in contact except when food is passing.

Posterior and *side-walls* are smooth and featureless.

Anterior wall is the back of the larynx, and presents epiglottis, arytænoids, inlet of larynx, ary-epiglottic folds, piriform fossa and cricoid. (*See* p. 593 *et seq.*)

Posterior and Lateral Relations of Pharynx.—Separated *posteriorly* from prevertebral muscles by retropharyngeal areolar tissue.

Related *laterally* to :—1. Infratemporal fossa and its contents.

2. Styloid process and its muscles.

3. Common, ext. and int. carotid, sup. thyroid, asc. pharyngeal, lingual, facial, asc. palatine and tonsillar arteries.

4. Lingual, glosso-pharyngeal, int. and ext. laryngeal nerves, pharyngeal branches of vagus and sympathetic. 5. Thyroid gland.

Walls of Pharynx.—1. Bucco-pharyngeal fascia, and, under it, there are the pharyngeal plexuses of veins and nerves.

2. Muscles. 3. Pharyngo-basilar fascia.

4. Mucous membrane (epithelium ciliated in nasal part, stratified in others), in which are many mucous glands and much lymphoid tissue—most abundant in the various tonsils and at the end of pharyngo-tympanic tube.

Lymph-vessels from upper part to glands behind pharynx; from lower part to glands on common carotid, opposite larynx.

Nerves: pharyngeal plexus; int. laryngeal to back of larynx; pharyngeal branch from spheno-palatine ganglion to roof of pharynx.

Muscles of Pharynx.—Constrictors, stylo-pharyngeus, palato-pharyngeus, salpingo-pharyngeus.

Superior Constrictor.—Arises from pterygoid hamulus, pterygo-mandibular lig., posterior end of mylo-hyoid

line, mucous membrane of mouth and side of tongue (fl.).

Fibres radiate to **insertion** in *median fibrous raphe* in posterior wall of pharynx, highest fibres reaching pharyngeal tubercle of occipital bone (fl.).

Nerve: accessory, through pharyngeal plexus.

Middle Constrictor.—Fan-shaped. **Arises** from both horns of hyoid bone and from stylo-hyoid ligament (fl.).

Radiates to **insertion** into median raphe (fl.).

Nerve: accessory, through pharyngeal plexus.

Inferior Constrictor.—**Arises** from oblique line and inf. horn of thyroid cartilage and side of cricoid cartilage (fl.). Sweeps backwards and upwards to **insertion** into raphe (fl.).

Nerve: accessory, through pharyngeal plexus and through external and recurrent laryngeal nerves.

Sup. constrictor is overlapped posteriorly and inferiorly by middle constrictor. Pharyngo-tympanic tube, tensor and levator palati, and pharyngo-basilar fascia occupy the interval between its upper border and base of skull. Pterygoideus medialis and stylo-pharyngeus are in relation to its external surface; palato-pharyngeus to its internal surface.

Posteriorly the **middle constrictor** overlaps superior constrictor and is overlapped by inferior constrictor. At the side, stylo-pharyngeus enters pharynx between it and sup. constrictor; and hyo-glossus, post. belly of digastric, stylo-hyoid are in relation to it.

Inf. constrictor overlaps lower part of middle constrictor. Int. laryngeal vessels and nerve pierce thyro-hyoid membrane, between their borders, under thyro-hyoideus. Lower border is nearly horizontal, mingles with fibres of œsophagus posteriorly; and inferior laryngeal vessels and nerve pass upwards under cover of it at the side. Sterno-thyroid overlies it near origin.

Stylo-pharyngeus lies first on outer surface of sup. constrictor and then between mucous membrane of pharynx and the other two constrictors.

Origin (fl.-tend.): styloid process, near root.

Insertion (fl.): posterior border of thyroid cartilage; side of pharynx, mingling with constrictors and palato-pharyngeus.

Nerve: glosso-pharyngeal.

It elevates larynx and pharynx.

Palato-pharyngeus lies in soft palate; in palato-pharyngeal arch; and between mucous membrane and constrictors of pharynx.

Origin (fl.): in palate by two layers separated by

levator palati and musculus uvulæ. *Upper layer* is continuous with its fellow; *lower layer* is attached to post. border of bony palate and to palatine aponeurosis.

Insertion (fl.): post. border of thyroid cartilage; wall of pharynx, mingling with constrictors.

Nerve: accessory, through pharyngeal plexus.

Raises larynx and pharynx; constricts pharyngeal isthmus.

Salpingo-pharyngeus arises from the lower part of the pharyngo-tympanic tube, runs down in the salpingo-pharyngeal fold, and mingles with palato-pharyngeus.

Pharyngo-Basilar Fascia.—Lines inner surfaces of pharyngeal muscles; separates them from mucous membrane; some of their fibres are inserted into it. It is thick above, especially opposite gap between base of skull and sup. constrictor, over whose upper border it is connected with bucco-pharyngeal fascia. It is attached above to basi-occiput and petrous temporal. Its lower part becomes thin and is gradually lost. It is thickened in posteriorly to form a *median raphe* that extends downwards from pharyngeal tubercle.

Deglutition

Voluntary Stage: 1. Breath drawn in and held.

2. Lips and cheeks usually, but not necessarily, pressed against the teeth and gums by orbicularis oris and buccinator.

3. Jaws closed by masseters, temporals and medial pterygoids.

4. Tongue and hyoid bone slightly elevated by mylo-hyoids.

5. Tongue, hyoid bone, and larynx are forcibly and suddenly raised, so that the tongue is pressed against the roof of the mouth, and the bolus of food is driven back through the oro-pharyngeal isthmus into the pharynx.

Tongue is raised by *mylo-hyoids* and *stylo-glossi*, assisted by palato-glossi, and, indirectly, by the elevators of the hyoid bone. It is pulled backwards by the stylo-glossi as well as upwards; and it is thickened vertically by contraction of its intrinsic longitudinal and transverse fibres. Hyoid bone is raised by digastrics, stylo-hyoids, genio-hyoids, mylo-hyoids, and hyo-glossi. Larynx is pulled up with the hyoid bone, and also, independently, by stylo-pharyngei and palato-pharyngei and by thyro-hyoids, so that it is overlapped anteriorly by the hyoid bone.

Involuntary Stage: 1. As soon as the bolus has passed through the oro-pharyngeal isthmus, the palato-glossi contract and draw the palato-glossal arches together to shut the isthmus and prevent the bolus from returning into the mouth.

2. Palato-pharyngei contract and draw the palato-pharyngeal arches towards each other to help to close the pharyngeal isthmus and prevent the bolus from passing up into the naso-pharynx and nose. Palato-pharyngeal arches, thus approximated, form an

inclined plane under which the bolus slips downwards and backwards.

3. To close the pharyngeal isthmus and shut off the naso-pharynx completely: The uvula is drawn up by the uvular muscle; the soft palate is stretched by the tensores palati and pulled upwards and backwards by the levatores into contact with the postero-superior wall of naso-pharynx. (This can be seen if one peers into the mouth of a person yawning—or into one's own mouth in a mirror.)

4. Pharynx is drawn up over the advancing bolus by salpingo-pharnygei, stylo-pharyngei and palato-pharyngei; and the overlapping constrictors seize upon it, and, by peristaltic contraction, send it on to the œsophagus.

5. To close the inlet of the larynx :—(*a*) Larynx is forcibly pulled upwards (*see* p. 625) and jammed against the lower part of the epiglottis and the back of the tongue.

(*b*) Arytenoid cartilages are drawn forwards from posterior wall of pharynx by thyro-arytenoid muscles; and the ary-epiglottic folds are shortened by the ary-epiglottic muscles within them.

(*c*) Arytenoid cartilages and posterior parts of ary-epiglottic folds are drawn together by the transverse and oblique arytenoid muscles to close the posterior-inferior part of the inlet.

(*d*) The ary-epiglottic and thyro-epiglottic muscles pull on the epiglottis; its upper part is fixed to the tongue and pharynx by the glosso-epiglottic and pharyngo-epiglottic folds; but its lower part is pulled backwards, so that it bulges backwards and its tubercle fits into the angle between the anterior parts of ary-epiglottic folds, and completely closes the inlet. The bolus then glides over pharyngeal surfaces of epiglottis, ary-epiglottic folds, arytenoid cartilages and cricoid, into the œsophagus.

6. Œsophagus by peristaltic contraction propels it to stomach.

From the raising of the tongue onwards, the movements are so rapid that they are almost simultaneous.

ŒSOPHAGUS

A muscular tube, lined with mucous membrane. About ten inches long. Extends from end of pharynx, opposite 6th c. vertebra and lower border of cricoid, through lower part of neck, superior and posterior mediastina; pierces diaphragm and enters stomach opposite 9th thoracic spine, four inches behind 7th costal cartilage, an inch to the left of median plane.

Distance from incisor teeth to commencement is 6 in.; to left bronchus 9-10 in.; to termination 16 in.

Slightly constricted at beginning, and at diaphragm, and where left bronchus crosses it—opposite fourth thoracic spine.

Direction is curved in conformity with vertebral column; and it deviates to the left of median plane in

neck and upper part of thorax, and again at lower part of thorax.

Relations in *neck* and *thorax* are given on pp. 326; 605, 608.

Its most important relations are to:—1. **Backbone,** which is close behind it, except at its lower part.

2. **Trachea** and **left bronchus,** immediately in front of its upper half.

3. **Pericardium** and **left atrium** of heart, in front of its lower part.

4. **Aorta,** first on its left side, and then behind it.

5. **Right pleura** and **lung,** close to its right side.

6. **Left pleura** and lung, closely related at upper part of thorax, and again at the lowest part.

7. **Vagi,** in a plexus around its lower part.

Abdominal Part of Œsophagus.—Half an inch or less. Encircled by a collar of lymph-glands. Gastric nerves on front and back. Œsophageal branches of left gastric artery (with corresponding veins), along right side. Clothed on left side and in front with peritoneum, and separated from the back of left lobe of liver by the lip of œsophageal opening of diaphragm. In contact with diaphragm posteriorly, with left phrenic vessels between it and diaphragm.

Walls of Œsophagus.—*Muscular coat*:—Striped fibres at upper end only. External longitudinal layer attached to cricoid above, continuous with longitudinal fibres of stomach below. Internal circular layer continuous with inf. constrictor above, with circular and oblique coats of stomach below.

Submucous coat contains many mucous glands.

Mucous membrane is covered with stratified epithelium.

Arteries: from inferior thyroid, descending thoracic aorta, left gastric. **Lymph-vessels** end in those glands that lie near it in neck, thorax and abdomen. **Nerves:** from recurrent laryngeal, sympathetic trunks, greater splanchnics and vagi.

CAVITY OF ABDOMEN

Abdomen contains remaining parts of digestive system. Divided into abdomen proper and pelvis.

Walls of its cavity are lined with serous membrane,[1] called **peritoneum**; the peritoneum provides also partial or complete coverings for most of the abdominal viscera, and forms free folds in connexion with some of them.

[1] *Serous membrane* consists of a sheet of simple squamous epithelium spread over the surface of a layer of areolar tissue of varying thickness; the epithelial surface is kept moist with lymph. *Mucous membrane* consists essentially of epithelium (of any variety except simple squamous) spread over the surface of a membrane of loose areolar tissue, in or under which there are numerous mucous glands that pour their secretion of *mucus* on to the epithelial surface to keep it moist.

Between peritoneum and the fascial lining of the muscles of abdominal wall, there is some loose areolar tissue, called *extraperitoneal tissue*. It contains fat, especially on posterior wall of abdomen proper, in pelvis, and in peritoneal folds, into which it extends to reach viscera. Fat is absent from the part of diaphragm covered with peritoneum.

Abdomen proper includes the part supported by the false pelvis; and its upper part is under shelter of ribs. During expiration it reaches up to xiphi-sternal joint in median plane, and on each side almost to the nipples in front and almost to the scapulæ behind, and is slightly higher on right side than left. It is *bounded superiorly* by diaphragm; *anteriorly* by recti and aponeuroses of obliqui and transversi abdominis; *on each side* by fleshy parts of obliqui and transversus, and by ilium and iliacus; *posteriorly* by lumbar vertebræ, crura of diaphragm, psoades, quadrati lumborum.

Cavity of abdomen proper is divided into 3 zones (*costal, umbilical, hypogastric*), by two horizontal planes: (1) *subcostal*, which touches lowest part of 10th costal cartilage and passes through 3rd L. vertebra; (2) *intertubercular*, which passes through tubercles on iliac crests (*i.e.* highest points of crests **seen from the front**), and through 5th L. vertebra.

Zones are each divided into three regions by *right* and *left* vertical planes, each of which corresponds to a line drawn upwards from **mid-inguinal point.** This division into nine regions is, however, of little or no practical value.

Another plane (much more useful) is the **transpyloric plane,** which passes horizontally through mid-point between upper margins of sternum and of pubic symphysis. It is about a hand's breadth below xiphi-sternal joint; and it cuts the pylorus of stomach, the lower margin of liver at median plane, the kidneys at or above the middle of hilum, neck of pancreas and origin of portal vein, aorta at the origin of sup. mesenteric art., and the 1st L. vertebra.

Pelvis is bounded by bones, ligaments and membranes of the true pelvis. (*See* p. 381.)

Relations of organs in abdomen are exceedingly variable, not only in different people, but in the same person at different periods of life. They vary also from hour to hour, owing to changes in posture of the body and to varying degrees of distension of hollow viscera. And pendulum-like variations occur with every breath.

Relations given are those considered to represent the average conditions found in dead adult bodies lying in the supine position.

STOMACH (VENTRICULUS OR GASTER)

Most dilated part of alimentary canal.

Position and Shape.—Lies obliquely in upper, left part of abdomen, behind anterior wall, liver and diaphragm, largely under shelter of ribs, from which it is separated by diaphragm and lower part of left pleura and lung.

Piriform in outline (large end uppermost) with anterior and posterior surfaces separated by blunt borders. Curves obliquely from above downwards and to the right, with lower part tilted forwards, so that :— (1) anterior surface looks largely upwards, and posterior largely downwards; (2) one border, called **lesser curvature,** is concave and looks to the right, upwards and backwards; opposite border, convex and very much longer, is called **greater curvature.** Œsophagus enters stomach not at very upper end but on right side an inch or more below top. Curvatures begin on opposite sides of entrance; therefore greater curvature includes the whole upper end.

Divisions.—1. **Cardiac** portion is the part adjoining œsophageal orifice.

2. **Fundus**: large, rounded, upper end, above the level of the œsophageal orifice.

3. **Body.** 4. **Pyloric antrum**: slightly dilated part at greater curvature, near lower end.

5. **Pyloric canal**: narrow part between antrum and lower end—an inch long; nearly cylindrical; enlarges very little even when stomach is full.

6. **Pylorus**: the lower end; looks to the right; is continuous with duodenum, *i.e.* first part of small *intestine*; is encircled by a groove called *pyloric constriction*; has its muscular coat thickened to form *pyloric sphincter.*

PERITONEAL CONNEXIONS.—Peritoneum covers the surfaces of the stomach; and the two layers meet at curvatures and proceed as so-called "folds" to be connected with other organs.

Fold from lesser curvature proceeds, as **lesser omentum,** to liver.

Fold that leaves greater curvature is divided into three parts, which, however, are continuous with each other :—

1. From part of fundus near œsophagus to diaphragm—**gastro-phrenic ligament.**

2. From left side of fundus to hilum of spleen—**gastro-splenic ligament.**

3. From horizontal part of greater curvature—the **greater omentum,** the two layers of which extend as far as pelvis, double back on themselves and ascend to be attached to transverse colon.

Peritoneum on anterior surface of stomach is continued on to anterior surface of duodenum; that on posterior surface extends on to first inch of first piece of duodenum, and is then reflected on to front of neck of pancreas. Peritoneum leaves uncovered a small "bare area" on posterior surface adjoining œsophageal orifice;

there, the stomach is in direct contact with crus of diaphragm, and sometimes with left suprarenal gland.

RELATIONS.—**Œsophageal orifice** is four inches behind 7th left costal cartilage, an inch from median plane, at level of 9th thoracic spine. Left lobe of liver, *in front*. Diaphragm and phrenic vessels, *behind*. Œsophageal branches of left gastric vessels are *on the right*.

Fundus rises to the level of fifth left rib below nipple, and is separated by diaphragm from pericardium and heart.

Pylorus lies in transpyloric plane, an inch to the right of median plane, *behind* quadrate lobe of liver, *in front of* neck of pancreas. Right gastric vessels run along *upper border*, between layers of lesser omentum. Right gastro-epiploic vessels run along *lower border*, between layers of greater omentum. Pylorus is recognised by position, by thickened muscular coat, and by the *prepyloric vein*, which descends over its anterior surface, under cover of peritoneum, from right gastric vein to right gastro-epiploic.

Anterior surface of stomach is related to liver to the right, diaphragm to the left, and ant. abdominal wall between these. Gastric nerves and blood-vessels ramify over it under peritoneum. Diaphragm separates it from left pleura and lung and from ribs.

Posterior surface is related to structures in the " stomach-bed ".

1. Body of pancreas.
2. Small part of left kidney above pancreas.
3. Left suprarenal, on the top and medial side of kidney.
4. Diaphragm, above all these.
5. Splenic artery, along upper border of pancreas.
6. Spleen, to the left of kidney and pancreas.
7. Transverse mesocolon, stretching down from pancreas.

Spleen is separated from stomach by the gastro-splenic lig. All the others are behind the lesser sac of peritoneum, which separates them from stomach. Gastric nerves and vessels ramify over the surface under cover of peritoneum.

Right and left gastric vessels run along **lesser curvature,** between layers of lesser omentum. Right and left gastro-epiploic vessels run between layers of greater omentum, near lower part of **greater curvature.** Transverse colon lies just below greater curvature ; but body of full stomach extends downwards in front of it ; when stomach is empty and intestines are distended, the transverse colon may be rolled up in front of stomach.

Cardiac notch separates the end of œsophagus from fundus. **Angular notch** is on lesser curvature, opposite pyloric antrum.

Arteries of stomach :—Left and right gastrics and gastro-epiploics ; short gastric of splenic. **Lymph-vessels** : To the glands round about it :—around cardia ; in gastro-phrenic lig. ; alongside vessels in omenta and gastro-splenic and lieno-renal ligs. ; on the back-wall alongside left gastric art., and, close to pancreas, alongside splenic and hepatic arteries and bile-duct and in the angle between first

and second parts of duodenum. **Nerves:** Gastric from the vagi; and branches from cœliac plexus accompany the arteries.

Structure.—Serous, peritoneal coat. Muscular coat: three layers. *Ext. longitudinal fibres*: continuous with those of œsophagus and duodenum. Best marked at lesser curvature; thin and irregular elsewhere. *Middle circular fibres*: V-shaped loops, open towards fundus above; complete circles near pylorus; increased at pylorus to form sphincter. *Internal oblique fibres*: V-shaped loops passing from fundus, near œsophagus, towards pyloric end; complete circles round fundus. Both middle and inner layers are continuous with circular fibres of œsophagus. **Mucous coat:** very thick; thrown into folds in empty stomach. In the empty state, the mucous membrane along lesser curvature is cast into two prominent, longitudinal folds. The deep gutter between them is converted into an *internal gastric canal* when their edges meet. Liquid and the first mouthfuls of food travel along that gutter or canal.

SMALL INTESTINE

DUODENUM. JEJUNUM. ILEUM

Duodenum differs from the rest in having no mesentery, and by being attached to back-wall by areolar tissue—all except its first inch. About ten inches long; bent in form of letter C, enclosing head of pancreas.

First Part.—Two inches long; very movable. Begins at pylorus opposite 1st L. vertebra in transpyloric plane an inch to the right of median plane; curves backwards, slightly to the right and upwards, across portal vein and vena cava, to neck of gall-bladder near right end of porta hepatis.

Second Part.—Three inches long; descends in front of renal vessels and medial margin of kidney, to end on right psoas, opposite third lumbar vertebra, a little above the level of umbilicus.

Third Part.—About four inches long; begins on right psoas, and runs to the left almost transversely, in front of vena cava and aorta.

Fourth Part.—About an inch long; ascends obliquely, along the left side of aorta and head of pancreas, to end on left psoas, opposite 2nd L. vertebra, by bending abruptly forwards to join jejunum, forming **duodeno-jejunal flexure.**

RELATIONS.—First Part.—*Peritoneum* covers anterior surface and first inch of posterior surface. Greater omentum is connected with first inch of lower border, and lesser omentum with still more —sometimes nearly the whole—of upper border.

Anterior: quadrate lobe of liver. *Inferior*: head of pancreas. *Posterior*: lesser sac of peritoneum is behind its first inch, separating it from neck of pancreas; inferior v. cava is behind remainder, but is separated from it by portal vein, gastro-duodenal art. and bile-duct; owing to the backwards curve of duodenum, the vena cava, etc. are medial rather than behind. *Superior*: Opening into lesser sac, separating it from caudate process of liver; but hepatic artery, portal vein, bile-duct, proceeding to and from lesser omentum, are between duodenum and the opening.

Second Part. — *Peritoneum* covers anterior and right lateral surfaces, except where transverse colon covers it. *Anterior*: gall-bladder at upper part; trans. colon in middle, overhung by liver and gall-bladder; coils of jejunum, and sometimes right colic vessels, at lower part. *Lateral*: right colic flexure and liver. *Medial*: head of pancreas; bile-duct and pancreatic duct pierce it on postero-medial aspect, just below its middle. *Posterior*: right renal vessels, pelvis of ureter, kidney near its hilum, psoas.

Third Part. — *Peritoneum* covers ant. surface, except where mesenteric vessels cross. *Anterior*: sup. mesenteric vessels and root of mesentery near junction with fourth part; coils of jejunum to the right of that; transverse colon and mesocolon farther forward. *Superior*: head of pancreas. *Inferior*: coils of jejunum. *Posterior*: right psoas, ureter, testicular or ovarian vess., inf. v. cava, aorta and inf. mesenteric art.

Fourth Part.—*Peritoneum* covers anterior and left surfaces. *Anterior*: jejunum and transverse colon. *Medial*: head of pancreas. *Lateral*: jejunum. *Posterior*: left testicular or ovarian artery, sympathetic trunk and psoas.

Duodeno-jejunal flexure lies an inch below transpyloric plane, an inch to left of median plane, on left psoas and inf. mesenteric vein and to the left of aorta; medial to left testicular vein, ureter and kidney; below body of pancreas; behind transverse colon; below and behind transverse mesocolon, which encloses branches of middle colic vessels and separates the flexure from the lesser sac and stomach. A fibro-muscular band, called **suspensory muscle of duodenum,** passes from the flexure, upwards behind the pancreas, to the diaphragm, and holds the flexure in place.

Peritoneum between the back-wall and lateral side of fourth part of duodenum may be pinched up to form two folds, under cover of which are **sup.** and **inf. duodenal recesses.** To left side of these the inf. mesenteric vein may raise another fold, bounding a **para-duodenal recess,** which is more important (*see* p. 451).

Arteries to duodenum: Superior and inferior pancreatico-duodenal; duodenal branch of hepatic. **Lymph-vessels:** To glands near at hand—in angle between first and second parts and around the bile-duct and around the stem of superior mesenteric artery. **Nerves:** From sympathetic and vagi; accompany arteries.

Jejunum begins at duodeno-jejunal flexure, at left side of 2nd L. vertebra ; is about 8 ft. long, and is succeeded, without any hard-and-fast line of demarcation, by **ileum**, which is 12 ft. long, and ends by joining large intestine at upper end of cæcum, in right iliac fossa, opposite point of intersection of intertubercular and right vertical planes.

Jejunum and ileum form coils found in all parts of abdomen below liver and stomach, and in pelvis—jejunum mostly to the left and above, ileum mostly to the right and below. Greater omentum and transverse colon and mesocolon hang down in front of them.

Terminal part of ileum ascends from pelvis and crosses ext. iliac art. to join large intestine.

Coils are freely movable, because they are connected to the posterior wall of abdomen by a wide fold of peritoneum called **the mesentery** (p. 647).

Diverticulum Ilei.—A blind diverticulum, at right angles to ileum ; about two inches long ; of same diameter as ileum ; present in about 2 per cent. of bodies ; found about three feet from lower end of ileum. End is usually free, but may be adherent to umbilicus. Due to persistence of proximal end of vitello-intestinal duct.

Arteries to jejunum and ileum, from the superior mesenteric. **Lymph-vessels** go to glands in mesentery, except some from end of ileum that go to adjacent glands on back-wall. **Nerves ;** sympathetic plexuses accompany arteries ; include branches from vagi.

Structure of Small Intestine.—*Serous coat*: complete in jejunum and ileum ; incomplete in duodenum.

Muscular coat : outer longitudinal layer, inner circular.

Mucous membrane : thrown into permanent **circular folds**, which may be circular, spiral or crescentic. Begin an inch from pylorus. Large and closely set in duodenum and upper part of jejunum. Diminish in size and number till almost absent in lower part of ileum ; hence, wall of ileum is thinner and less vascular.

Mucous membrane is thickly covered with minute projections, called **intestinal villi,** which give it a velvety appearance.

Solitary nodules of lymphoid tissue are scattered through small intestine (and large intestine as well) underneath mucous membrane. **Aggregated nodules** are found opposite line of mesenteric attachment. Half to three inches long ; about half an inch broad. Seen best in young subject ; atrophy after middle age. Largest and most numerous in lower part of ileum.

Differences between the Jejunum and the Ileum.—

Jejunum.—(A) **While in abdomen and unopened:** 1. *Occupies* upper and left part of intestinal area.

2. *Walls*, thicker, more vascular and therefore redder.

3. *Lumen*, wider and often empty—hence the name **jejunum**.

4. Fat in mesentery is not so abundant near intestine at its upper part as it is lower down, and vessels close to the gut are more readily seen, with semi-translucent intervals (" *windows* ") between them.

(B) **When opened**: 5. *Circular folds*, larger and more closely set (and *villi* are larger).

6. *Aggregated nodules* absent.

LARGE INTESTINE

Begins in right iliac fossa as a blind head, called **intestinum cæcum**, with which **vermiform appendix** is connected. Cæcum is succeeded by colon at the level of intertubercular plane; ileum opens into large intestine at their junction, and the opening is guarded by ileo-colic valve. Colon is divided into: (1) **ascending colon**, which proceeds upwards on right half of back-wall of abdomen to inferior surface of liver, where it makes a bend, called **right colic flexure**, on anterior surface of kidney, and becomes (2) **transverse colon**, which arches across abdomen to lower part of spleen, on the front or the lateral border of left kidney, makes a sharp bend, called **left colic flexure**, and becomes (3) **descending colon**, which runs down left half of posterior wall of abdomen into the iliac fossa **near** the medial side of the anterior superior iliac spine, and then medially to end at medial margin of psoas major by becoming (4) **pelvic colon**, which hangs down as a loop into pelvis, and ends at the middle of middle piece of sacrum by becoming continuous with **intestinum rectum**; and rectum is succeeded by **anal canal**.

Cæcum.—About two and a half inches long and three inches wide. Lies in right iliac fossa above lateral half of inguinal lig.; completely clothed with peritoneum, but has no mesentery. Anterior abdominal wall is *anterior*, and is sometimes separated by greater omentum and coils of ileum. Ilio-psoas muscle, lateral cutaneous, femoral and genito-femoral nerves, and testicular vessels are *posterior*. Ileum is *medial*. Relation to vermiform appendix is variable.

Vermiform Appendix.—About four inches long, a quarter of an inch thick. Springs from postero-medial wall of cæcum an inch below entrance of ileum. May hang down into pelvis, or be directed upwards behind cæcum, or upwards and to left; in female it touches ovary when it lies in pelvis. Ensheathed in peritoneum

and has a small mesentery (attached to left side of mesentery of ileum) by which its artery reaches it. One can find a hidden appendix by tracing downwards the anterior tænia of ascending colon.

Ileo-Colic Valve.—Is opposite the intersection of intertubercular and right vertical planes. Ileum enters postero-medial wall of junction of cæcum and colon ; the mucous and circular muscle layers of its walls telescope walls of large intestine so as to produce a valve with two lips—superior and inferior. Opening is slit-like, long axis antero-posterior. Lips meet at the ends of the slit and are prolonged on to anterior and posterior walls of gut by raised-up folds of mucous membrane called *frenula*. Tonic contraction of muscle fibres of ileum in the valve enable them to act as an **ileo-colic sphincter.**

Ascending Colon.—Continuous with cæcum at intertubercular plane ; extends upwards, and, curving round lateral border of kidney, ends by bending at right angles (right colic flexure) to join transverse colon, on front of kidney, immediately below transpyloric plane, under cover of liver, diaphragm and ribs.

Peritoneum covers its front and sides, leaving posterior surface in direct contact with back-wall.

Relations.— *Anterior* : ant. abd. wall ; sometimes greater omentum and small intestine. *Lateral* : abd. wall. *Medial* : small intestine ; psoas, kidney. *Posterior* : iliacus, ilio-lumbar lig., quadratus lumborum, transversus abd., diaphragm at tip of last rib ; lateral cutaneous, ilio-inguinal, and ilio-hypogastric ; iliac branches of ilio-lumbar vessels, and fourth lumbar art. when it is in front of quadratus ; right kidney.

Right Colic Flexure.—Lies on kidney. Covered with peritoneum, except posteriorly. Liver is above and lateral and anterior ; duodenum is medial.

Transverse Colon.—Begins at right colic flexure opposite a point immediately lateral to upper end of linea semilunaris ; arches across abdomen with its convexity downwards and forwards, passing immediately above the level of umbilicus ; ends on back-wall, at lateral border of left kidney immediately above transpyloric plane, below spleen, by bending sharply (left colic flexure) to join descending colon.

Relations.—First few inches, nearly transverse ; covered with peritoneum, except posteriorly ; lies in contact with second part of duodenum and head of pancreas, behind liver and gall-bladder.

Remainder is movable, and enclosed in peritoneum, which is continuous, below, with ascending or posterior layers of greater omentum, and, above, with transverse mesocolon, which suspends it. *Anterior surface* is related to cavity of lesser sac and descending layers of greater omentum. *Posterior surface*, to coils of small intestine, third and fourth parts of duodenum, upper end of mesentery, duodeno-jejunal flexure. *Upper border* is related to greater

curvature of stomach anteriorly and its own mesocolon posteriorly.

Terminal part lies on left kidney, below pancreas, behind stomach or greater omentum.

Left Colic Flexure.—Higher, deeper and more lateral than right flexure. Lies on back part of diaphragm and lateral border of kidney, below colic surface of spleen, behind stomach or left edge of greater omentum. Peritoneum covers it, except posteriorly; and it is attached by *phrenico-colic lig.* to diaphragm, opposite 11th rib in mid-axillary line.

Descending Colon.—Much narrower than ascending. Begins above transpyloric plane about four inches from median plane. Passes downwards and slightly medially along lateral border of kidney, and then vertically to the iliac crest; then, onwards in left iliac fossa to the medial side of the anterior superior iliac spine, and, finally, medially, to end at the brim of the pelvis, a little above the inguinal lig. by joining the pelvic colon.

Relations.—Peritoneum clothes it on front and sides, to a greater extent than ascending (except when distended), but leaves posterior surface in contact with back-wall. *Anterior*: coils of small intestine. *Medial*: kidney above, psoas below. *Lateral*: diaphragm, transversus abdominis, small intestine. *Posterior*: diaphragm, transversus abd., quadratus, iliacus and psoas; ilio-hypogastric, ilio-inguinal, lateral cutaneous, femoral and genito-femoral nerves; iliac branches of ilio-lumbar vessels; testicular and external iliac vessels.

Its lower part—from iliac crest to pelvic brim—was formerly called the *iliac colon.*

Pelvic Colon.—May be as long as transverse colon or longer; usually much shorter. Begins at medial border of left psoas; forms a loop which lies in pelvis; ends on pelvic surface of middle piece of sacrum by becoming rectum. Occasionally very short and takes a straight course. Enclosed in peritoneum and suspended by pelvic mesocolon. Coils of small intestine lie above and alongside it. It lies on bladder, or uterus and bladder.

Structure of Large Intestine.—**Serous, peritoneal coat:** complete over cæcum, vermiform appendix, transverse colon and pelvic colon; incomplete over others. *Appendices epiploicæ* are little pouches of peritoneum filled with fat found over all parts of large intestine called colon.

Muscular coat: *Outer longitudinal fibres* are in form of three equidistant bands, called **tæniæ coli**, between which the longitudinal stratum is absent or exceedingly thin. At one end the tæniæ converge upon root of vermiform appendix; at the other they spread out to unite together by their edges, and become continuous with longitudinal layer of rectum. They are one-sixth shorter than potential length of colon, which is therefore puckered up into three rows of sacculations. *Inner circular fibres* form a continuous layer.

Mucous coat: thrown into numerous crescentic folds. Lymph-

nodules are scattered in the submucous tissue, and are especially numerous in vermiform appendix.

Arteries of Colon, etc.: To *cæcum* and *vermiform appendix*, from sup. mesenteric and ileo-colic; *asc. colon*, ileo-colic and right colic; *transverse colon* and *flexures*, right, middle and left colic; *desc. colon*, left colic; to *pelvic colon*, from left colic and sup. rectal. **Lymph-vessels:** Go to lymph-glands that lie alongside the various parts and alongside the branches and stems of blood-vessels that supply them—ileo-colic, right, middle and left colic—and thence to glands at the root of sup. mesenteric artery and other glands near aorta. **Nerves:** Through plexuses that accompany arteries—from sympathetic, supplemented by vagi for upper part and by pelvic splanchnics for lower part.

Differences between Large and Small Intestines and between the several Parts of Colon.—*Large intestine* is distinguished from *small* by appendices epiploicæ, tæniæ coli, sacculations, absence of villi.

Ascending colon has larger calibre than *descending* colon. *Transverse* and *pelvic* cola differ from others in having complete peritoneal covering; and transverse differs from pelvic in having not one but two lines of peritoneal attachment—greater omentum and transverse mesocolon.

Peritoneal Recesses.—**Retrocæcal recess:** a fossa that extends upwards behind cæcum and lower end of colon. When this recess is present, the vermiform appendix often lies in it. **Ileo-cæcal fold:** a fold with a medial free edge, attached to ileum above, cæcum laterally, and vermiform appendix or its mesentery below. **Inferior ileo-cæcal recess:** a fossa between this fold and the mesentery of appendix. **Superior ileo-cæcal recess** is behind the **vascular fold of cæcum,** which stretches across front of upper part of ileo-cæcal junction.

Recess of pelvic mesocolon: a fossa between the end of left common iliac artery and pelvic mesocolon at the apical part of the A-shaped attachment of pelvic mesocolon.

Intestinum Rectum.—Five inches long. Begins at middle piece of sacrum. Follows curve of sacrum and coccyx, lying behind bladder, seminal vesicles, vasa deferentia and prostate *in male*; behind uterus and vagina *in female*. Ends an inch beyond tip of coccyx (on level with apex or lower end of prostate in male and upper angle of perineal body in female), by bending backwards to become anal canal. Lower part is dilated—*ampulla recti*—bulging forwards rather than sidewards.

Peritoneum covers anterior surface and sides of *upper third*; covers ant. surface of *middle third*, and is reflected

on to bladder (or vagina), forming bottom of *recto-vesical* (or *recto-vaginal*) *pouch*, three inches from anus (and about an inch above base of prostate, in male). *Lowest third* is below the level of peritoneum, imbedded in fat and fascia.

Anal Canal.—An inch and a half long. Directed backwards and downwards from end of rectum, through pelvic floor, to open on exterior as anus. Circular fibres thickened to form *sphincter ani internus*. Surrounded by sphincter externus and levatores ani, which keep its sidewalls in apposition.

RELATIONS OF RECTUM.—**At sides**: pelvic colon or ileum, separated by peritoneum, *in upper third*; coccygeus, levator ani, and rectal vessels, lower down. Ureter is some distance away.

Posterior: lower part of sacrum, coccyx, ano-coccygeal body, at median plane; lower part of piriformis, coccygeus, levator ani, on each side. Between it and this bed are: median sacral vessels, sympathetic trunks, lower lateral sacral vessels, 3rd, 4th and 5th sacral nerves and coccygeal nerve, besides areolar tissue.

Superior rectal artery, at first posterior, divides to pass down along its sides, and to sink into its substance about its middle.

Anterior, in male: *Upper two-thirds*—peritoneum and pelvic colon or ileum. *Lower third*—bladder, with seminal vesicles and vasa deferentia intervening; prostate below bladder.

Anterior, in female: *Upper two-thirds*—peritoneum and pelvic colon or small intestine separate it from uterus and upper part of vagina. *Lower third*—middle part of vagina.

A muscular band (*recto-urethral muscle*), on each side of median plane, extends forwards from ant. surface of rectum at lower end of ampulla, to be attached to apex of prostate and to the urethra as it emerges from prostate, or to the back of the vagina.

RELATIONS OF ANAL CANAL.—*Posterior*: ano-coccygeal body. *Lateral*: levator ani, ext. sphincter ani, ischio-rectal fossa.

Anterior: the fatty, fibro-muscular mass called the perineal body—which separates it, *in the female*, from the lower third of the vagina, and, *in the male*, from the transverse perineal muscles and the bulb of the penis.

Lower half of anal canal is lined with skin. Mucous membrane of upper half is thrown into longitudinal folds, called *anal columns*, separated by grooves. *Anal valves* are little folds pinched up at the lower ends of the grooves; they bound little pockets called *anal sinuses*. The tearing down of one of these folds may be the starting-point of a painful fissure.

Curvatures of Rectum.—Antero-posterior flexure. Three lateral flexures above ampulla, two concave to left and the middle one to

right, each having corresponding fold in interior, called a *horizontal fold of rectum*, including mucous, submucous and part of muscular coat. Middle fold is the biggest, and is at the level of lowest part of peritoneum on side of rectum.

Arteries to rectum and anal canal, from sup., middle and inf. rectal and median sacral. **Veins** go partly into *portal system*, through sup. rectal, and partly into *systemic veins* through middle and inf. rectal and median sacral. **Lymph-vessels** from rectum and anal canal mostly go to neighbouring glands in pelvis and thence to glands alongside aorta, **but some from anal canal** run forwards in perineum and then upwards **to glands in groin. Nerves :** sympathetic through plexuses on arteries ; 2nd, 3rd and 4th sacral through pelvic splanchnic nerves and inf. hæmorrhoidal nerve.

LIVER (HEPAR)

Size and Position.—Largest gland in body, measuring $7 \times 6\frac{1}{2} \times 6$ in. About 50 oz. in weight. Lies in uppermost part of abdomen, chiefly on right side of median plane, only its thin, left part being on the left. Mostly under shelter of ribs,—reaching up to xiphi-sternal joint and 8th thoracic spine in the middle, and almost to nipples and the scapulæ, being slightly lower on the left ; but it is exposed in subcostal angle and along right costal margin.

Shape and Surfaces.—Resembles a 4-sided pyramid laid on one side, with edge-like **apex** looking to the left, **base** looking to right, and 4 **surfaces—anterior, posterior, superior** and **inferior**. Inferior surface is related to viscera, and is marked off from base and other surfaces by a definite **inferior border**—least definite posteriorly. Other surfaces and base are separated by ill-defined, blunt margins, and are all closely related to diaphragm.

Lobes.—Right and **left.** Separated, on *anterior* and *superior surfaces*, by attachment of a wide, long fold of peritoneum called **falciform lig.** ; on *inferior surface* by a deep cleft called **fissure for lig. teres** ; on *posterior surface* by a deeper cleft called **fissure for lig. venosum.** Right lobe forms great bulk of liver ; on its inferior surface there is a circumscribed area called **quadrate lobe** ; another, on its posterior surface, is called **caudate lobe.**

Porta Hepatis.—A deep, wide, transverse cleft, 2 in. long, placed far back on inferior surface in right lobe, bounded in front by quadrate lobe, behind by caudate lobe and a ridge of liver substance, called *caudate process*, that connects lower end of caudate lobe with the rest of

right lobe. Left end of porta is joined at right angles by the fissures. Lips or boundaries give attachment to part of lesser omentum. *Transmits* portal vein, hepatic art., common hepatic duct, nerves and lymph-vessels.

Portal vein enters it near its right end. Inside porta, the two branches of vein diverge to their lobes. Branches of hepatic artery are in front of them. Right and left hepatic ducts are in front of the arteries, and unite to form common hepatic duct.

EXTERNAL CHARACTERS AND RELATIONS OF LIVER.—**Apex**: A convex, sharp edge. Lies between diaphragm and stomach opposite a point a little below left nipple.

Base or **right surface**: Quadrilateral, convex. Lies against diaphragm opposite 7th to 11th ribs (in mid-axillary line), and against fascia transversalis for half an inch below ribs. Overlapped (diaphragm intervening) by pleura down to level of 10th rib, and by lung also down to 8th.

Superior surface: Quadrilateral. Concave in middle; convex on each side (especially on right) fitting into domes of diaphragm. Diaphragm separates it from pericardium and heart in the middle, and from pleura and lung on each side. Falciform lig., attached to it near median plane, partly separates it from diaphragm.

Anterior surface: Triangular, slightly convex. Related to anterior wall of abdomen in subcostal angle (xiphoid process and sheaths of recti), and to diaphragm on each side. Falciform lig., attached to it a little to right of median plane, partly separates it from wall of abdomen; pleura overlaps down to level of a line drawn from xiphi-sternal joint to 10th rib in mid-axillary line; lung overlaps down to a line from the joint to the 8th rib.

Inferior or **visceral surface**: Quadrilateral, uneven. Looks backwards and to the left as well as downwards. Divided by fissure for lig. teres into separate portions that belong to right and left lobes.

Fissure for lig. teres, deep and narrow, extends from left end of porta to a notch on inferior border at lower end of hepatic attachment of falciform lig., opposite a point a little below transpyloric plane, midway between median line and linea semilunaris.

Part that belongs to left lobe lies on the front of stomach and lesser omentum. **Tuber omentale**—the rounded bulging related to lesser omentum—is to the left of upper part of fissure. **Gastric impression**—the concave remainder—is below and to the left of tuber.

Part that belongs to right lobe presents quadrate lobe, fossa for gall-bladder, impressions made by duodenum, right flexure of colon, kidney and suprarenal gland.

Fossa for gall-bladder begins at a wide, shallow notch on inferior

border, opposite upper end of linea semilunaris; extends, tapering, to the right end of the porta.

Quadrate lobe extends from inferior border to porta, between fissure for lig. teres and fossa for gall-bladder. Crossed from left to right and upwards by pylorus and first part of duodenum. Related, above them, to lesser omentum; and to transverse colon, below them.

First part of duodenum ends at neck of gall-bladder, and the beginning of second part makes a **duodenal impression** immediately to the right of the upper or posterior part of fossa for gall-bladder.

Colic impression, made by right flexure, is behind inferior border, to the right of the lower part of fossa for gall-bladder.

Renal impression, made by right kidney and suprarenal gland, is the wide concavity above and behind colic impression, and occupies the remainder of the surface. Uppermost medial part is for lower part of suprarenal gland.

Posterior Surface.—Triangular, uneven; markedly concave from side to side, as liver is moulded on the thick, median ridge made of the vertebral bodies, crura of diaphragm and psoas muscles.

Divided by fissure for lig. venosum into separate parts that belong to right and left lobes. Outside diaphragm, left pleura and lung overlie left lobe; right pleura overlies almost the whole of the right lobe and lung overlaps down to a line drawn horizontally from both thoracic spine.

Fissure for lig. venosum, deep and narrow, extends vertically from upper surface to lower surface, where it is continuous with fissure for lig. teres at left end of porta. Upper part of lesser omentum passes into it to be attached to its bottom, where the two layers of omentum are continuous with the peritoneum that lines the two sides of the fissure.

Part that belongs to left lobe is very small. Shallow notch, immediately to the left of the fissure, is the **œsophageal impression** made by anterior lip of œsophageal opening of diaphragm. To the left of that, the surface thins down to an edge; and, just above the edge, the posterior part of upper surface gives attachment to a fold of peritoneum called *left triangular lig. of liver.*

Part that belongs to right lobe, large and convex, presents caudate lobe, fossa for inferior v. cava, "bare area", and impression for suprarenal gland.

Fossa for inferior vena cava is a deep, wide, vertical groove on back of liver, about an inch to the right of median plane of body.

Caudate lobe, in median plane, on diaphragm above aortic opening, opposite thoracic aorta and lower thoracic vertebræ. Separated from diaphragm by a recess of the lesser sac of peritoneum. Lies between fissure for lig. venosum and fossa for vena cava. Bounded above by lig. venosum and left hepatic vein as they arch from the top of the fissure to join left side of vena cava. Bounded below by porta. The lower end of caudate lobe is, however, free,

juts down behind lesser omentum, and is notched by cœliac art. Part to the left of notch is called *papillary p ocess.* Part to the right is continuous with **caudate process,** which is a narrow ridge of liver substance that separates porta from fossa for v. cava, and forms the upper boundary of the opening into the lesser sac.

Bare area is the large, convex area to the right of fossa for v. cava. Peritoneum is reflected from liver to diaphragm at its upper and lower margins; it is therefore in direct contact with diaphragm. **Suprarenal impression** is a small triangular depression at its lower corner, close to vena cava.

Lig. venosum.—Slender, fibrous remnant of ductus venosus of fœtus. Arises from left branch of portal vein, runs upwards along floor of fissure on back of liver, curves to the right above caudate lobe to fuse with vena cava at the entrance of left hepatic vein.

Lig. teres of liver.—Long and slender. Remnant of umbilical vein of fœtus. Runs in free edge of falciform lig. from umbilicus to notch on inferior border of liver; then, backwards in its fissure to the porta to join left branch of portal vein. Slender vessels run along it—viz., the hepatic branch of superior epigastric art. and small veins that connect portal vein with veins around umbilicus.

PERITONEAL CONNEXIONS.—Peritoneum clothes and adheres to liver except at bare area and fossæ for vena cava and gall-bladder. Along certain lines, it is reflected off liver, forming folds that connect it with neighbouring parts. Those folds are lesser omentum and falciform, coronary, right and left triangular ligaments.

Coronary lig. is merely the layers of peritoneum reflected on to diaphragm from upper and lower margins of bare area. Its upper and lower layers are therefore separated by the vertical width of that area. The upper layer intercepts the hand passed backwards over right lobe of liver. The lower layer is often reflected on to upper end of right kidney as well as on to diaphragm. The two layers meet at the right corner of bare area; and the parts of them reflected to diaphragm from that corner are called the **right triangular lig.**

Left triangular lig. is a definite fold, well seen when left lobe of liver is pulled down. One border is attached to back part of upper surface of left lobe; another, to diaphragm in front of œsophageal orifice; the third is a free edge that looks to the left.

Falciform Lig.—Long, wide, triangular. Folded between liver and abdominal parietes mainly to the right of median plane.

Attached: By *one border* to diaphragm and anterior wall of abdomen down to umbilicus, in median plane; in an exactly median incision the knife may therefore pass between its two layers. By *another border* to upper and anterior surfaces of liver between right and left lobes; attachment begins on left side of median plane, near the upper end of fissure for lig. venosum and the right side of

sophageal notch, and slants to the notch for lig. teres. *Third rder* is a free edge that extends from umbilicus to the notch for lig. res; at this edge, the two layers of the ligament are continuous ith each other and enclose lig. teres between them.

Lesser Omentum.—Wide fold, hidden by left lobe of liver, hich has to be lifted up before it can be seen.

Attached to: (1) First inch or more of first part of duodenum;) lesser curvature of stomach; (3) diaphragm, for half an inch tween œsophagus and upper end of fissure for lig. venosum;) bottom of that fissure; (5) lips and right end of porta hepatis. *Right border* is a free edge at which the two layers are continuous ith each other. It stretches from right end of porta to duodenum id forms the anterior boundary of the opening into the lesser sac, hich separates it from inferior v. cava.

Between Layers.—(1) Fat, lymph-vessels and lymph-glands, rves. (2) *At right free border*—Bile-duct; hepatic art. medial the duct; portal vein behind both; cystic and common hepatic icts near porta. (3) *Near stomach*—Right and left gastric ssels.

Relations.—*Anterior*: Tuber omentale; posterior part of quadte lobe. *Posterior*: Lower end of caudate lobe juts down behind into cavity of the lesser sac. The cavity and posterior wall of e sac separate it from: (1) Crura of diaphragm; (2) aorta, beveen crura; (3) tuber omentale of pancreas, on aorta; (4) cœliac tery, above tuber; (5) cœliac plexus, around artery and on crura;) phrenic arteries on the crura; and (7) inferior v. cava, on right us.

Lines of Reflexion of Peritoneum.—Make one continuous, intricate ne. Not important. Begin at right side of falciform lig.:—Along s attachment, upwards and backwards, almost to upper end of ssure for lig. venosum; towards the right, first in front of top of audate lobe, then in front of vena cava, and then along upper argin of bare area (upper layer of coronary); round right corner bare area (right triangular lig.); towards the left, first along wer margin of bare area (lower layer of coronary), and then in ont of vena cava (upper boundary of opening into lesser sac); wards, between v. cava and caudate lobe (right boundary of cess of the sac); towards the left, along the top of caudate lobe pper boundary of recess); down along the bottom of fissure for g. venosum (upper part of posterior layer of lesser omentum); wards the right, along the posterior lip of porta (lower part of sterior layer); round the right end of porta (free edge of lesser mentum); towards the left, along the anterior lip of porta, and wards along the bottom of fissure for lig. venosum (anterior layer omentum); towards the left, along the back part of the upper rface of left lobe (posterior layer of left triangular lig.); round e attachment of the free edge of that lig.; towards the right nterior layer) to the upper end of fissure for lig. venosum; forwards

and downwards along the attachment of the left lamina of falciform lig., which is continuous with the right lamina at the notch for lig. teres on the inferior border of liver.

Blood-Vessels.—Hepatic art. and portal vein convey blood to the liver; and hepatic veins remove it.

Nerves.—Vagal branches from stomach to liver through lesser omentum; branches from cœliac plexus accompany hepatic artery.

Lymph-Vessels.—End in glands in lesser omentum, in gastro-phrenic lig., on back-wall above pancreas, and in thorax in front of pericardium and behind it.

Vesica Fellea or **Gall-Bladder.**—Pear-shaped; three inches long; holds one or two oz. Lies on visceral surface of liver. Lower end or **fundus** is the large end, covered with peritoneum, projects beyond liver and lies against ant. abdominal wall opposite upper end of right linea semi-lunaris. *Ant. surface* is adherent to liver. *Post. surface* is clothed with peritoneum and lies against beginning of transverse colon below, and second part of duodenum above. Upper end or **neck** is narrow; lies near right end of porta; is continuous with cystic duct.

Cystic Duct.—One inch long. Bent and twisted. Runs backwards and medially, and joins common hepatic duct to form the bile-duct.

Common Hepatic Duct.—An inch or less. Formed in the porta hepatis by the union of right and left hepatic ducts from right and left lobes of liver.

Bile-Duct.—Three to four inches long. Begins, near the porta hepatis, by the union of cystic and common hepatic ducts.

Descends between layers of lesser omentum at its free margin, in front of portal vein, lateral to the hepatic art. Next, behind first part of duodenum, in front of porta vein, lateral to gastro-duodenal artery; lastly, in front of inf. v. cava or right renal vein, lateral to the main pancreatico-duodenal vein, in a groove on the back of head of pancreas, where it meets pancreatic duct.

Bile-duct passes obliquely through postero-medial wall of duodenum about its middle, expanding to form an *ampulla*. The ampulla is joined by the pancreatic duct and it bulges the mucous membrane inwards to form an eminence called the *duodenal papilla*. The papilla is con cealed by one of the circular folds, which forms a " hood " over it; and a *longitudinal fold* of mucous membran

escends from the papilla. The ampulla opens on the ummit of the papilla by a constricted orifice.

Structure.—Walls of ducts and gall-bladder are made of non-riped muscle mixed with fibrous tissue, and are lined with mucous embrane. **Spiral valve** is the name given to a series of short dges of mucous membrane arranged spirally around wall of neck f gall-bladder and adjoining part of cystic duct.

PANCREAS

An elongated gland that lies obliquely across upper art of posterior wall of abdomen, partly in loop of uodenum, partly behind stomach. Divided, from right o left, into head, neck, body and tail.

Head lies in loop of duodenum. *Posterior surface* rests gainst inf. v. cava, right renal vessels, left renal vein, nd slightly on aorta. A pancreatico-duodenal vein scends between pancreas and v. cava; and bile-duct is mbedded in a groove at lateral side of that vein. *Ant. urface*: covered with transverse colon—either wholly in irect contact, or partly separated by peritoneum above nd below. Lower part of head (*uncinate process*) curves o left, behind sup. mesenteric vessels, to overlap aorta, nd also extends upwards behind neck, from which portal ein separates it. Pancreatico-duodenal vessels run in roove between duodenum and pancreas.

Neck, about an inch long but ill-defined. Connects he front of upper part of head with the body. Lies in ranspyloric plane about an inch to the right of median lane. Portal vein and uncinate process are *behind* it. *nteriorly* it is separated from pyloro-duodenal junction y peritoneum and the cavity of the lesser sac.

Body extends to the left and upwards to the spleen.

Anterior surface: covered with peritoneum of the sser sac, and stomach rests on it; transverse mesocolon attached to its *lower border*; a prominence on the pper part of body, at median plane, near neck, is called *ber omentale*, for it rises above the level of the pyloric nal to abut against lesser omentum, which separates from liver; cœliac art. juts forwards above the tuber; nd splenic art. runs sinuously to the left along the *upper rder* of anterior surface.

Inferior surface: covered with peritoneum; rests

upon duodeno-jejunal flexure, coils of jejunum, and left end of transverse colon.

Posterior surface is in relation with :—(1) aorta and origin of sup. mesenteric art. ; (2) left crus of diaphragm ; (3) left sympathetic trunk and psoas ; (4) left kidney ; (5) splenic vein, running from left to right, between it and all those structures ; (6) inf. mesenteric vein, entering splenic ; (7) left renal vessels, below splenic vein, may be wholly behind pancreas, or may be, partly, at a lower level ; (8) lower part of cœliac plexus and suprarenal gland, above splenic vein ; (9) suprarenal vein and inf. suprarenal art., behind splenic vein, near kidney.

Tail is the left end of pancreas—thickened rather than attenuated. It is related to a depression on the spleen below the lateral part of its hilum.

Pancreatic Duct.—Lies in the substance of the gland. Begins at tail ; runs in the body to the neck, receiving numerous tributaries ; bends down in the substance of the head, and ends in the ampulla of the bile-duct.

Accessory Pancreatic Duct.—Arises in lower part of head ; crosses in front of main duct, and gives it a communicating branch ; enters duodenum nearly an inch above and in front of main duct.

Arteries : Sup. and inf. pancreatico-duodenal ; several branches from splenic ; a few from hepatic. **Lymph-vessels** end in the numerous glands that lie round about it. **Nerves ;** from splanchnic and vagi, through plexuses which accompany the arteries.

PERITONEUM

Peritoneum is the large continuous sheet of serous membrane which lines the abdominal walls (except where viscera are in direct contact) and is reflected on to the viscera, giving them partial or complete coverings. It passes directly on to some viscera, holding them against the posterior abdominal wall. Other viscera are connected by " folds " to the parietes and to one another. Where a fold is " attached " to parietes or to an organ the two layers which compose it separate from each other.

Three different kinds of names are given to folds, more or less arbitrarily : omenta ; mesenteries ; ligaments.

Lesser Omentum.—*See* p. 643.

Greater Omentum.—Hangs down from stomach like an apron. Has four layers. *Anterior* two layers descend from greater curvature of stomach as far as pelvis ; turn

back and run upwards, as the *posterior* two layers, to transverse colon; separate to enclose it; meet again and proceed to lower border of pancreas, as *transverse mesocolon*. At pancreas, the two layers separate finally—the one passing upwards over structures on posterior wall of abdomen, the other downwards.

Lower part of cavity of lesser sac is enclosed between the anterior and posterior layers, and these layers are continuous with one another at right and left borders of omentum, as well as at lower border. Left border, traced upwards, becomes continuous with gastro-splenic and lieno-renal ligaments.

Ant. surface is in relation to ant. abdominal wall. Transverse colon is hidden by the anterior two layers immediately below stomach; and all four layers are in front of small intestine.

Right and left gastro-epiploic vessels, lymph-glands and lymph-vessels lie between the anterior two layers near stomach. Near right and left borders there are anastomoses between branches of gastro-epiploic and colic arteries.

The ant. two layers are occasionally adherent to transverse colon, and below that level the cavity of the lesser sac may be obliterated.

The Mesentery.—A wide, broad fold that attaches jejunum and ileum to posterior wall of abdomen. Its posterior border or root, about six inches long, is attached to post. wall from left side of 2nd L. vertebra to right iliac fossa above sacro-iliac joint. Greatest width of mesentery from intestine to parietes is about eight inches.

Its root begins at duodeno-jejunal flexure; crosses third part of duodenum, aorta, inf. v. cava, right ureter, genito-femoral n., testicular or ovarian vessels and psoas; ends at ileo-cæcal junction.

Between Layers of Mesentery.—1. Jejunum and ileum at the free border.

2. Fat and fibrous tissue.

3. Superior mesenteric vessels and their jejunal and ileal branches.

4. About 200 lymph-glands, with corresponding afferent and efferent lymph-vessels (called *lacteals*).

5. A multitude of nerves—in plexuses—derived from sympathetic and vagi.

Fat between layers at upper part of mesentery is less abundant near intestine than it is lower down; vessels can more easily be seen through it near the intestine, and intervals between vessels are more or less translucent.

Mesentery of Vermiform Appendix.—A small triangular fold which encloses the vermiform appendix in one border; its artery in

another (which is a free edge); and is attached by the third border to the lower part of the left lamina of *the* mesentery.

Transverse Mesocolon.—A broad fold that connects transverse colon to posterior wall along lower border of body of pancreas and sometimes across front of head. Forms part of posterior wall of the lesser sac.

Anterior surface is in relation to stomach; *posterior*, to small intestine. Between layers are middle colic vessels, branches of right and left colic; lymph-glands and lymph-vessels; nerves.

Pelvic Mesocolon.—Attached along a ∧-shaped line. Lateral limb extends along left iliac arteries from middle of external to middle of common; medial limb, from middle of common iliac art. to middle of middle piece of sacrum. Between its layers are:—Pelvic colon. Lowest left colic vessels, which enter at lateral limb of attachment. Superior rectal vessels, which enter at medial limb. Lymph-vessels and lymph-glands. Nerves.

Falciform, Coronary and **Triangular Ligs.**—*See* p. 642.

Phrenico-Colic Lig.—A triangular fold attached by one border to left flexure of colon, by another to diaphragm opposite 11th rib in mid-axillary line. Third is free and looks forwards. Spleen rests on upper surface.

Gastro-Splenic Lig.—Two layers that pass from greater curvature, at left border of stomach, to lips of hilum on gastric surface of spleen.

Continuous with gastro-phrenic lig., above; with anterior two layers of greater omentum, below.

Encloses left gastro-epiploic and short gastric branches of splenic artery, accompanied by veins, lymph-vessels, lymph-glands and nerves.

Forms part of the left boundary of the lesser sac.

Anterior or medial surface is in relation to the stomach; posterior surface is in relation to the gastric surface of the spleen.

Lateral or posterior layer passes over the spleen, adherent to its surfaces, and comes into relation again with the medial layer, and the two pass from the hilum to the left kidney as the **lieno-renal ligament,** which helps to form the left boundary of the lesser sac. Between the layers of lieno-renal lig. are splenic vessels, with lymph-vessels, lymph-glands and nerves.

The layers separate at the kidney and pass to right and left.

Gastro-Phrenic Lig.—Two layers which pass to the diaphragm from the uppermost part of the greater curvature of the stomach.

Lig. Hepato-Colicum.—Present occasionally. Attached superiorly to liver and gall-bladder; inferiorly to beginning of transverse

colon ; posteriorly to lesser omentum and duodenum ; free border is directed to the right and forwards.

Right and left gastro-pancreatic folds are occasional ridges of peritoneum raised up by hepatic and left gastric arteries as they run to duodenum and œsophageal end of stomach.

Umbilical folds and the **fold of the epigastric artery** are ridges of peritoneum raised up on ant. abdominal wall by the median and lateral umbilical ligs. and the inf. epigastric arteries.

Vaginal process of peritoneum is a diverticulum which precedes testis in its passage from abdomen to scrotum.

Sacro-Genital Fold.—A small fold that curves forwards from the sacrum to the upper end of the seminal vesicle. When the bladder is empty the anterior ends of the right and left folds meet.

Recto-uterine fold, the corresponding fold in the female, is connected with the cervix uteri, and may meet its fellow across the back of the cervix.

Recto-Vesical Pouch.—Is the depression between rectum and bladder. Floor (three inches from the surface of the perineum) is formed by peritoneum passing from the front of the rectum on to the upper part of the base of the bladder.

Recto-Uterine or **Recto-Vaginal Pouch.**—Is the deep, wide depression that separates the rectum from the uterus and the uppermost part of the vagina. Floor (three inches or less from the perineum) is formed by peritoneum passing off the front of the rectum on to the posterior wall of the vagina.

Vesico-Uterine Pouch.—Is the recess between bladder and uterus. Its floor is the peritoneum passing off the front of the uterus (at junction of body and neck) on to the upper border of the base of the bladder.

Broad Ligament of Uterus.—Stretches from the side of the uterus to the side-wall of the pelvis an inch below the ureter and the internal iliac artery.

Ovary is attached to its upper surface near the side-wall of the pelvis ; uterine tube is contained in its free edge.

Borders and Surfaces.—**Anterior border** is a free edge where the two layers of the lig. are continuous with each other.

Medial four-fifths of the free edge contains the uterine tube.

Lateral fifth is called the **infundibulo-pelvic lig.** Contains ovarian vessels and nerves. Ascends to end by spreading out and becoming continuous with the peritoneum on the external iliac vessels.

Posterior border or **root** is attached to the top of the side of the vagina and to the fat on the upper surface of levator ani ; and the

two layers separate—the one passing downwards, the other upwards on the floor of the pelvis.

Ureter passes downwards and forwards below the root, close to the vagina. Uterine vessels, having reached the root, bend forwards and upwards between the layers, and run medially above the ureter.

Medial border is attached to the side of the uterus; and the two layers separate to become continuous with the peritoneum that clothes the two surfaces of the uterus.

Lateral border is attached to the obturator fascia on the side-wall of the pelvis, an inch or less below (or in front of) the ureter; and the layers separate—the one passing downwards on the side-wall of the pelvis, the other upwards towards the sacrum. Umbilical artery and obturator nerve and vessels cross the line of attachment.

Lower surface is related to a loop of intestine, and to the bladder when full. Lig. teres uteri raises up a ridge on it.

Upper surface is related to the ovary and to the ileum or to the pelvic colon.

Uterine tube pierces the upper layer of the lig. near the side-wall of the pelvis. Near that, there is a linear gap into which the mesovarian border of the ovary fits, and through which the ovarian vessels and nerves enter the ovary. The edges of the gap are continued backwards as two exceedingly short layers, called the **mesovarium,** which are continuous with the epithelial covering of the ovary. At the uterine end of the ovary, the end of the mesovarium is continuous with a ridge raised up on the upper surface of the broad lig. by the lig. of ovary.

Mesosalpinx is the portion of the broad lig. between the uterine tube and the attachment of the ovary (*salpinx* = a tube).

Contents of Broad Ligament:—

1. Fat and fibrous tissue.
2. Lymph-vessels and lymph-glands.
3. Uterine tube in the free border.
4. Lig. teres uteri, bulging out the lower layer.
5. Lig. of ovary, bulging out the upper layer.
6. Ovarian vessels and nerves in the infundibulo-pelvic lig.
7. Uterine vessels and nerves near the uterus.
8. Ep-oöphoron and par-oöphoron—minute tubules in mesosalpinx.

PERITONEAL CAVITY

Space enclosed by peritoneal membrane; only potential till abdomen is opened, or unless distended with liquid or gas. In the male, the peritoneum is a closed sac. In female, the uterine tubes open into it, and it therefore communicates with the exterior through the uterine tubes, uterus and vagina.

Peritoneal cavity is divided into two :—

I. **Greater sac of peritoneum**—the space opened into when anterior abdominal wall is cut through. Greater omentum, transverse colon and mesocolon divide it into an upper, anterior portion and a lower posterior. These are continuous with each other round the lower and lateral borders of greater omentum. Lower portion is further divided into a right and a left part by the mesentery.

II. **Lesser sac of peritoneum** is a diverticulum from the greater sac. Its upper part is behind the greater sac ; its lower part extends into the greater sac.

Its *anterior wall* is :—1. Peritoneum on the back of the caudate lobe of the liver.

2. Posterior layer of lesser omentum.

3. Peritoneum on the posterior surface of the stomach.

4. The second layer of the greater omentum.

Posterior wall :—1. Third layer of greater omentum.

2. Peritoneum on anterior surface of transverse colon.

3. Anterior layer of transverse mesocolon.

4. The continuation of that layer upwards over pancreas, upper part of left kidney, left suprarenal gland, cœliac art. and its branches, cœliac plexus and crura of diaphragm.

The part of the lesser sac between caudate lobe and diaphragm is a small recess bounded on right and above by reflexion of peritoneum from caudate lobe on to diaphragm, and on left side by attachment of lesser omentum to diaphragm. *Upper boundary* of the lesser sac, to the left of this recess, is the peritoneum reflected from diaphragm on to back of stomach below its "bare area", and the lower layer of the gastro-phrenic ligament. *Upper part of left border or boundary* is the right or medial layers of the gastro-splenic and lieno-renal ligaments. *Lower part of left boundary*, the *lower boundary* and *lower part of right boundary* are formed by continuity of the second and third layers of greater omentum. *Right boundary above omentum* is the reflexion of peritoneum from the neck of first part of duodenum on to front of neck of pancreas. Above that the right boundary is deficient, the lesser sac communicating here with greater sac. And the highest part is the right boundary of the recess mentioned above.

Opening into Lesser Sac.—A short peritoneal canal which unites the cavities of lesser and greater sacs, behind the right border of lesser omentum, opposite upper part of first L. vertebra, an inch to the right of median plane.

Anterior are: Portal vein, hepatic artery and bile-duct, in the free border of lesser omentum.

Posterior: Vena cava inferior and right crus.

Superior: Caudate process of caudate lobe of liver.

Inferior: First part of duodenum; and portal vein, hepatic artery and bile-duct, on their way to and from the lesser omentum.

Splenic, left gastric and hepatic arteries begin behind the posterior wall of the lesser sac and end in front of the anterior wall, between the layers of the omenta. Left gastric ends in front of the lesser sac, having turned round its upper border at the œsophageal end of the stomach. Hepatic comes to lie in front of the opening into the lesser sac by turning round the right border of the sac at its junction with the inferior wall of the opening. Splenic artery runs behind the lesser sac to the kidney; its branches pass into the lieno-renal lig., and lie therefore on the left boundary of the sac; and its short gastric and gastro-epiploic branches pass over the part of the left boundary formed by the medial layer of the gastro-splenic ligament, to reach the stomach, which lies on the anterior wall of the lesser sac.

Continuity of Peritoneal Membrane as seen in Section or traced in Cadaver

Continuity of the peritoneal membrane in the greater and lesser sacs may be traced in vertical and transverse directions.

Vertical Direction.—Greater sac: Begin at anterior layer of lesser omentum. Follow that layer to lesser curvature; over antero-superior surface of stomach to greater curvature; as first layer of greater omentum to its lower border; upwards as fourth layer of omentum to transverse colon; over posterior surface of transverse colon, and then upwards and backwards to lower border of pancreas as posterior layer of transverse mesocolon. From there downwards for a little, over posterior wall, to root of mesentery; downwards and forwards as right lamina of mesentery, round intestine, and back to posterior wall as left lamina of mesentery. From there downwards over posterior wall to pelvis, over rectum on to bladder in male, on to vagina and uterus and then to bladder in female. From bladder on to anterior abdominal wall, over which it is traced uninterruptedly to lower surface of diaphragm. From diaphragm to liver as upper layer of coronary lig., if on right side of falciform lig.; or as upper layer of left triangular lig., if on left side. Over upper and anterior surfaces of liver, round lower border of liver, and over lower surface to porta hepatis; and from there to starting-point on lesser omentum.

Lesser Sac.—Begin at posterior layer of lesser omentum. Follow, successively, that layer, peritoneum on posterior surface of stomach, second layer of greater omentum, third layer, peritoneum on anterior surface of transverse colon, anterior layer of

transverse mesocolon, peritoneum on pancreas and crura. Reflected on to upper end of caudate lobe, downwards over that lobe and on to starting-point on lesser omentum ; or, alternatively, from a point more to the left, from diaphragm directly on to lesser omentum or on to back of stomach.

Transverse Directions :—1. **At Level of 4th Lumbar Vertebra.**—**Greater sac** : Begin at median plane on anterior abdominal wall. Follow peritoneum to the left over anterior and lateral walls of abdomen ; over sides and front of descending colon, onwards to root of mesentery ; left layer of mesentery, round intestine, right layer ; back to posterior wall. Then, over posterior wall, over sides and front of ascending colon to lateral wall of abdomen, and then back to starting-point.

Lesser Sac.—Four layers of greater omentum ; first and fourth, continuous at lateral borders ; second and third, continuous at lateral borders, and enclose cavity of lesser sac.

2. **At Level of Pylorus.**—Trace to left and slightly upwards. **Greater sac** : Begin at pylorus. Follow successively : peritoneum on anterior surface of stomach ; lateral layer of gastro-splenic ligament ; over gastric, diaphragmatic, renal surfaces of spleen ; lateral layer of lieno-renal ligament ; over kidney to left side of diaphragm, over diaphragm to falciform ligament ; left layer of falciform ligament ; round liver to falciform ligament again ; right layer of falciform ligament ; over right side of diaphragm to kidney ; over kidney and first part of duodenum to pylorus.

Lesser Sac.—Begin at pylorus, pass over posterior surface of stomach, medial layers of gastro-splenic and lieno-renal ligaments ; to the right over the pancreas. Reflexion on to posterior surface of first inch of duodenum, and over it to pylorus.

3. **Immediately above Pylorus.**—Greater and lesser sacs are continuous here. **Greater sac** : Begin on the front of free border of lesser omentum and pass to left. Anterior layer of lesser omentum ; peritoneum on anterior surface of stomach ; gastro-splenic ligament, spleen, lieno-renal ligament, kidney, diaphragm, falciform ligament, liver, diaphragm—all as in preceding section—over upper part of right kidney and on to vena cava in posterior wall of opening into lesser sac.

Lesser Sac.—Continue over vena cava to right crus ; on to pancreas, medial layers of lieno-renal and gastro-splenic ligaments, posterior surface of stomach, posterior layer of lesser omentum, and round right free border of lesser omentum, on to the front of it, to the starting-point for the greater sac.

UROGENITAL SYSTEM

URINARY ORGANS

THE two **kidneys** extract constituents of *urine* from blood circulating in them ; pass it onwards by the **ureters** to the **bladder,** where it accumulates till it is expelled to the exterior through the **urethra.**

Kidneys lie in the upper part of abdomen proper. Ureters, in abdomen proper and in pelvis. Bladder, in pelvis. Urethra, in pelvis and perineum ; and, in the male, it traverses penis also.

Kidney (**Ren**).—Reddish brown, bean-shaped, smooth. About $4\frac{1}{2}$ in. long, $2\frac{1}{2}$ in. broad, $1\frac{1}{4}$ in. thick. Weighs about $4\frac{1}{2}$ oz. Relatively much larger in new-born than in adult.

Upper end, nearer median plane than *lower end,* and usually bulkier. *Anterior surface* looks forwards and sidewards. *Posterior surface* looks backwards and medially. *Lateral border* is convex ; *medial,* concave.

Hilum is the vertical slit on medial border. Transmits ureter and renal vessels and nerves.

Renal sinus—the space in interior into which the hilum leads—contains : (1) fat and fibrous tissue, (2) calyces and pelvis of ureter (p. 657), and (3) renal vessels and nerves.

Renal papillæ are 12-15 little nipples that jut from the walls of the sinus into the calyces. Their apices are perforated by the tubules that carry the urine out of kidney into calyces.

Position.—Kidneys lie on upper part of posterior wall of abdomen behind peritoneum, opposite 12th TH. and upper 3 L. vertebræ. Right kidney reaches usually to level of upper border of last rib, left kidney to upper border of last space ; but they may be on same level, or

left may be lower. Lower end is a little above the level of back part of iliac crest (which is opposite 4th L. vertebra), and immediately above level of umbilicus (which is opposite the disc between 3rd and 4th); subcostal plane (which is at level of 3rd) therefore cuts lower end of right kidney and just misses the left. Hilum of right kidney is two inches and lateral border four inches, from median plane, and the left a little nearer. Transpyloric plane cuts left at middle of hilum, right a little higher. Vertical plane passes through kidney near its lateral border.

In marking out the position of kidney, avoid numerous points of reference. Take a point at or below transpyloric plane, about two inches from median plane, as representing middle of hilum, and map out the outline of a kidney. On the back, carry the transpyloric plane round, and proceed as on the front.

RELATIONS.—A condensation of retroperitoneal tissue, called *renal fascia* encloses kidney, together with suprarenal gland and a variable amount of *renal fat*, which is applied chiefly to its ends and borders. The two layers of fascia fuse immediately beyond suprarenal and fat at upper end, and beyond the fat at lateral border of kidney; but, inferiorly, they are lost in the fat near the iliac crest. Medially, the anterior layer is lost in the fat in front of vena cava and aorta; posterior layer fuses with fascia of psoas. The fat outside the fascial sheath is called *paranephric fat*.

Lower part of the *back* of **each kidney** lies on psoas, quadratus and transversus; upper part lies on crus of diaphragm, arcuate ligaments and the part of diaphragm that arises from them. Subcostal vessels and subcostal, ilio-hypogastric and ilio-inguinal nerves lie between it and quadratus lumborum, in that order from above downwards. Behind quadratus there are sacro-spinalis, serratus posterior inferior and latissimus dorsi, and then fasciæ and skin; behind diaphragm there are **pleura,** 12th rib, sacro-spinalis, etc.—the pleura being a most important posterior relation of kidney.

Otherwise, except in regard to suprarenal gland, the kidneys differ in their relations.

Right Kidney: *Anterior*: Suprarenal gland, at upper end and upper part of medial border; second part of duodenum, on medial part along hilum; right colic flexure and a branch of right colic artery, at lower end—all in direct contact. Liver, at upper part and part adjoining lateral border—separated by peritoneum.

Medial: Suprarenal gland; inferior vena cava; ureter (which may be posterior).

Lateral: Ascending colon, at lower part; liver, at upper part.

Left Kidney: *Anterior*: Suprarenal gland, as on right kidney. Pancreas, across it above middle; splenic vein, behind pancreas; splenic artery along upper border of pancreas. Ascending branch of left colic artery, across lower end. The foregoing are in direct contact. Stomach above pancreas, left part of transverse colon and a coil of jejunum below pancreas—separated by peritoneum. Spleen, at area adjoining upper part of lateral border—partly separated by peritoneum, partly connected by lieno-renal ligament.

Lateral: Spleen, at upper part; left colic flexure and descending colon, at lower part. *Medial*: At upper part—suprarenal gland and vein and inferior suprarenal artery. At lower part—ureter (which may be behind); left testicular or ovarian vein, medial to ureter; inferior mesenteric vein, medial to testicular or overlapping it.

Fibrous capsule of kidney is continuous with the fibrous lining of the sinus. At base of each papilla, the outer coat of calyx is continuous with fibrous lining of sinus; the mucous coat is reflected over papilla to its apex to become continuous with the walls of the uriniferous tubules.

Kidney on section presents to naked eye a peripheral part or *cortex*, which is granular and streaked, and a *medulla*, which lies next sinus. Medulla is made up of pyramids and columns. **Renal pyramids** are dark, conical bodies in which kidney tubules show as faint striations. Apices of pyramids are directed towards sinus, and several combine to form one renal papilla. **Renal columns** are the granular strips between pyramids. They are continuous with cortex; in them the larger blood-vessels may be seen.

Two of the main branches of **renal art.** at hilum are in front of ureter and behind the veins. A third branch is behind ureter. *Accessory renal arteries* may enter kidney above or below hilum. Since the kidney is a purifier of the blood, its blood-vessels are far larger than is necessary for its mere nutrition. **Nerves** to kidney, from renal plexus, ultimately from vagi and 10th, 11th, 12th thoracic nerves. **Lymph-vessels** end in glands alongside aorta and vena cava.

Ureter.—Whitish tube made of non-striped muscle mixed with fibrous tissue, ensheathed in fibrous tissue and lined with mucous membrane.

Begins in renal sinus as a dilatation, called **pelvis of ureter,** formed by union of calyces. Pelvis issues from hilum, descends along medial margin of kidney (or partly behind it), narrowing till, at lower end of kidney, it becomes ureter proper.

Ureter proper, about ten inches long—half in abdomen proper, half in pelvis—passes downwards and very slightly medially on psoas, to enter pelvis by crossing the origin of external iliac art. In the pelvis it pursues an arched course with its convexity backwards and side-

wards, and it enters the bladder at its postero-lateral angle, an inch and a half from the neck of the bladder and two inches from its fellow.

Ureters pierce bladder wall very obliquely so that their orifices are only an inch apart; and the obliquity of the passage serves the purpose of a valve.

In a great part of its course, it is under cover of peritoneum, and is so closely adherent in the pelvis that it is liable to be stripped up with the peritoneum.

It is usual to say that ureter enters pelvis where it crosses the iliac artery; but ureter and internal iliac artery have to cross the medial surface of psoas before they reach the bony brim.

Calyces and Pelvis of Ureter.—**Lesser calyces**, about 10, are short, funnel-like tubes that lie near the walls of renal sinus and receive the urine—the wide part of each embracing one or more renal papillæ. **Greater calyces** are two short, wide tubes—an *upper* and a *lower*—formed by union of lesser calyces; and they unite to form pelvis.

Pelvis of ureter is a funnel-shaped tube whose wide end lies in renal sinus near the hilum, and whose extra-renal, tapering part lies on psoas.

RELATIONS OF PELVIS URETERIS.—**Inside Kidney**: Branches of renal vessels are both in front of it and behind it.

Outside kidney: Psoas is *posterior*. Renal vessels and second part of duodenum are *anterior* to right pelvis. Renal vessels and pancreas are *anterior to* upper part of left pelvis; peritoneum and jejunum, to lower part.

RELATIONS OF URETER PROPER.—A. IN ABDOMEN.—

Right ureter: *Posterior*: psoas, genito-femoral nerve, iliac art. *Medial*: vena cava. *Anterior*: third part of duodenum, peritoneum; and, under cover of that—right colic, ileo-colic and testicular or ovarian vessels, and superior mesenteric vessels in root of mesentery.

Left ureter: *Posterior*: same as right. *Medial*: left testicular or ovarian vein, which separates it from inferior mesenteric vein. *Anterior*: peritoneum; and under cover of that—testicular or ovarian artery and left colic vessels.

B. IN PELVIS.—Each passes backwards and slightly downwards over upper part of side-wall of pelvis till it reaches the level of ischial spine, and then turns downwards and medially in the fat on the floor of pelvis to reach bladder, where its terminal part is surrounded by a plexus of veins. Till it approaches bladder it is immediately under cover of peritoneum, through which it may be seen shining. In any surgical procedure in pelvis the ureter is the

structure whose relation to the field of operation has to be kept constantly in mind.

In Female.—On side-wall of pelvis :—Internal iliac artery is immediately *above and behind* the ureter. *Lateral*: psoas and obturator internus, with the following structures intervening—ext. iliac vein, between it and psoas; and, lower down, obturator nerve, umbilical art., obturator and vaginal and uterine vessels. *Medial*: peritoneum, separating it from overlapping, terminal part of uterine tube. *Below and in front*: peritoneum, separating it from ovary, which intervenes between ureter and broad lig.

On floor of pelvis :—It runs downwards and forwards in fat *above* levator ani and passes close by lateral fornix of vagina; it is *beneath* peritoneum and crosses below the broad lig. at the vagina, and, as it does so, the uterine vessels pass medially above it.

In Male.—On side-wall :—Internal iliac art. is immediately *above and behind* ureter. Peritoneum is *below and medial*. *Lateral*: psoas and obturator internus; external iliac vein, obturator nerve, umbilical art., obturator and inferior vesical vessels.

On floor: As it turns downwards and forwards it lies in the fat *above* levator ani, *beneath* peritoneum, but vas deferens crosses above it, between it and peritoneum, near the bladder, and at the bladder it is overlapped by the upper end of seminal vesicle.

Arteries: from renal, testicular, colic, vesical, middle rectal.

Nerves: from renal, testicular and hypogastric plexuses.

Lymph-vessels end in glands nearest it in abdomen and pelvis.

Urinary Bladder.—Lies in anterior, lower part of pelvis; till puberty, partly in abdomen also.

When empty and hardened, it has an apex, a superior surface, a pair of infero-lateral surfaces and a base or posterior surface. Surfaces are triangular, and are separated by borders.

Apex lies behind upper margin of pubic symphysis an inch or more from the skin. A fibrous cord—*median umbilical lig.*—extends from the apex to the umbilicus between peritoneum and transversalis fascia, and raises up a ridge of peritoneum; its vesical end usually contains a small cavity.

Superior surface *is the only surface covered with peritoneum, except* (in male) *a small part of base.* Pelvic colon and ileum rest on it, in male; uterus and intestine, in female. Lateral border is behind and medial to umbilical artery, but comes into contact as bladder fills. Ureters enter its posterior angles. Peritoneum descends a short distance on base, near median plane, before reflexion on

to rectum, in male. In female, it is reflected from posterior border of superior surface on to uterus at junction of cervix and body.

Fundus (Base) looks backwards and is separated from rectum by vasa deferentia, seminal vesicles and fascia *in male*, by cervix uteri, vagina and fascia *in female*. Vasa and vesicles cover base, except a small triangular area covered with peritoneum between the vasa, immediately below the upper border.

Infero-lateral surface, on each side, is in relation to pubis, levator ani and obturator internus, separated by fasciæ of bladder and of these muscles, and by fat in retro-pubic space. Rounded, anterior border, between these surfaces, is separated from symphysis by a pad of fat.

Vesical plexus of veins lies on fundus and infero-lateral surfaces, in and under cover of fascia.

Neck is the lowest part of bladder, and the urethra begins there. Pubo-vesical or pubo-prostatic ligaments connect it with lower part of back of pubis. Owing to obliquity of pubis in erect posture, the neck, *in the male*, is a little below level of upper margin of symphysis and 2½ in. behind it. It rests upon and is partly continuous with base of prostate, but is partly separated from it by a circular groove filled with fat, fascia and veins. *In female*, it rests on the fascia that covers the sphincter urethræ at the level of a line drawn from lower margin of symphysis to lower end of sacrum.

As bladder fills, the neck remains stationary. Upper wall rises, and, with other surfaces, increases in area and becomes more convex. Infero-lateral surface comes into relation with greater area of side-wall of pelvis, and with obturator vessels and nerve and vas deferens. Borders become rounded and finally obliterated ; bladder rises up out of pelvis, stripping peritoneum off anterior abdominal wall, so that bladder is in direct contact with fascia transversalis for an inch and a half or more above pubis.

Bladder-wall is composed of : (1) partial covering of peritoneum ; (2) fascial envelope ; (3) muscular coat, circular fibres of which, at neck, form a *sphincter* ; (4) submucous layer of areolar tissue which binds mucous membrane to muscle—loosely, except at trigone ; (5) mucous membrane, covered with transitional epithelium.

Interior of Bladder.—Mucous membrane is smooth when bladder is full ; wrinkled when it is empty, except at **trigonum vesicæ,** where it is always smooth owing to its greater elasticity and to its closer attachment to the muscular wall of the bladder. Trigone is situated

on the inner surface of posterior wall. Orifices of ureters are at the upper angles; **internal orifice of urethra** is at the lower angle. Sides of trigone are an inch each when bladder is empty, an inch and a half when full. **Uvula vesicæ** is a bulging forwards immediately above urethral orifice, opposite and due to the median lobe of prostate, enlargement of which increases the size of uvula till it may block the orifice. *Interureteric ridge* of mucous membrane, between orifices of ureters, is raised up by an underlying bar of muscle; similar ridges may extend from urethral orifice to orifices of ureters. During life mucous membrane is straw-coloured, except over trigone, where it is pink, because the vessels show through it more readily.

Arteries: superior and inferior vesical. **Veins** form a plexus drained into internal iliac. **Nerves**: through plexuses that accompany arteries, come ultimately from upper lumbar and 2nd, 3rd and 4th sacral. **Lymph of bladder** goes to glands between it and pubis and along its sides, and thence to glands alongside iliac arteries.

Female Urethra.—Exceedingly dilatable. 1½ inches long; curves downwards and forwards from neck of bladder, below and behind pubic symphysis. Passes through pelvic fascia, sphincter urethræ and perineal membrane. Lies in close contact with anterior wall of vagina, or imbedded in it, and ends in front of vaginal opening, between labia minora, an inch behind clitoris. Its *external orifice* has firm, raised margins.

A group of minute glands at each side of lower part of urethra represents prostate. Their slender **para-urethral duct** runs down in submucous coat, and opens at the side of external orifice.

Male Urethra.—About 8 in. long, conveys not only urine but also secretions of testes, vasa deferentia, seminal vesicles, prostate, bulbo-urethral glands and urethral mucous glands. Describes an ∽-shaped curve, and is divided into prostatic, membranous and spongy parts.

Prostatic part, 1¼ in. long. Begins at neck of bladder and tunnels prostate from its base to anterior border above apex. Widest and most dilatable division of urethra; widest in middle. *Urethral crest* is a longitudinal elevation of mucous membrane in its floor or posterior wall. Prostatic ducts open in groove (*prostatic sinus*) on each side of crest. At most prominent part of crest, about its middle, there is the mouth of *prostatic utricle*—a diverticulum of mucous membrane that leads upwards and backwards for half an inch into substance of prostate behind median lobe. Ejaculatory ducts open at the margins of the mouth of utricle.

Membranous Part.—Shortest part of urethra, and narrowest and least dilatable except external orifice; half an inch long. Lies an inch behind and below symphysis, with the bulbo-urethral glands behind it. Begins at the lower end of the prostate, pierces the fascia on the pelvic surface of the sphincter urethræ, passes obliquely through that muscle and pierces the perineal membrane to join the spongy part.

Spongy Part.—Enters deep surface of bulb of penis; traverses corpus spongiosum; opens at extremity of glans penis as **external orifice of urethra,** which is the narrowest and least dilatable point of the canal. Dilated in floor in bulb (*intrabulbar fossa*), and again in roof in glans (*terminal fossa*). Lies nearer dorsal surface in bulb, nearer lower surface in glans. Ducts of bulbo-urethral glands open into it an inch in front of perineal membrane.

Urethra is made of elastic fibrous tissue mixed, in upper part, with non-striped muscle; it is lined with mucous membrane, in which there are little recesses called *lacunæ urethrales*. **Lymph-vessels** mostly go to glands alongside iliac arteries, *but some from spongy part go first to deep glands in groin.*

MALE GENITAL ORGANS

Essential reproductive fluid is secreted by the two **testes,** which lie in the **scrotum.** From each testis, fluid passes into a tube, much coiled at first, called **epididymis,** straighter afterwards and called **vas deferens,** which ascends from scrotum, traverses inguinal canal, descends to back of bladder, where it joins duct of **seminal vesicle** to form **ejaculatory duct.** Ejaculatory duct pierces prostate and opens into **urethra,** which receives also the secretions of **prostate,** which lies below bladder, and of **bulbo-urethral glands,** which lie in perineum. **Penis** is traversed by and supports urethra.

Scrotum.—Pendulous bag below and behind body of penis. Composed of skin, muscle and fasciæ. Divided into a pair of compartments, each of which is lined with the parietal layer of a serous membrane called tunica vaginalis testis.

Skin, dark and covered sparsely with hair. Has a median ridge, called *raphe of scrotum,* which extends from scrotum backwards to anus and forwards on to penis.

Superficial fascia, devoid of fat and largely replaced by a thin sheet of muscle, called **dartos** muscle, which sends an imperfect *septum* into the scrotum to divide it into a pair of chambers.

In the wall of each chamber there are (besides skin and dartos) three complete layers derived from ant. abdominal wall, and named, from without inwards :—*ext. spermatic fascia*, from aponeurosis of obliquus externus ; *cremasteric muscle and fascia*, from obliquus internus ; *internal spermatic fascia*, from fascia transversalis.

Skin and superficial fascia (with dartos) are common to both chambers.

Blood-vessels : scrotal branches of int. and ext. pudendal. **Nerves :** scrotal, of perineal ; perineal branch of post. cutaneous of thigh ; ilio-inguinal. **Lymph-vessels** end in superficial glands in the groin.

Testis.—Whitish in colour, oval in shape. 1½ in. long, 1 in. broad, ¾ in. thick from side to side. Long axis directed upwards, forwards and sidewards. Lateral surface looks sidewards and backwards. Left testis rather lower than right. Epididymis and lower end of spermatic cord are attached to posterior border, through which vessels and nerves enter testis.

Tunica vaginalis testis, a closed sac of serous membrane derived from peritoneum, lines wall of scrotal chamber (*parietal layer*), and is reflected from posterior wall to give a covering (*visceral layer*) to epididymis and testis, and to the front and sides of spermatic cord immediately above testis. From the lateral side, it is tucked in between the epididymis and testis, lining a narrow recess called the **sinus of epididymis.**

Epididymis lies along posterior border of testis, lateral to lower end of spermatic cord and was deferens, with which it is in direct contact. Its upper end or **head** is enlarged, overhangs and lies in direct contact with upper end of testis, with which it is connected by efferent ducts. **Body** is separated from the testis by the sinus of epididymis. **Tail** or lower end is attached by areolar tissue to the testis near its lower end.

Epididymis is an exceedingly coiled tube—**canal of epididymis**—about 20 feet long, which is continuous with the vas deferens at the tail of the epididymis.

Structure of Testis.—Beneath serous covering is a dense, white fibrous coat, called **tunica albuginea,** whose posterior part is thick and is thrust into testis as **mediastinum testis,** from which **septa** pass to the tunica albuginea on the surfaces and ant. border,

and imperfectly divide testis into compartments, each of which is occupied by a **lobe** made of **convoluted seminiferous tubules,** which secrete semen. These coiled tubules, about 600 in number, each about two feet long, unite to form **straight tubules,** which enter mediastinum and join one another to form **rete testis.** From the rete, 15 to 20 **efferent ducts** pass out of mediastinum into head of epididymis, where each is coiled on itself to form a little cone, called a **lobule of epididymis,** before it enters the canal of epididymis.

Arteries: Testicular art., from aorta, anastomoses in cord with the artery to vas deferens and the artery to cremaster.

Veins: Form a pampiniform plexus, from which the testicular vein arises. Right vein ends in v. cava inferior; left vein, in renal.

Lymph-vessels: *Ascend to glands alongside aorta and vena cava.*

Nerves: From aortic and renal plexuses; ultimately from 10th TH. segment to testis, 11th and 12th TH. and 1st L. to epididymis.

Appendices testis are small sessile or pedunculated bodies found on head of epididymis or on upper end of testis. One is a remnant of para-mesonephric duct and corresponds to fimbriated end of uterine tube; the other may be a mesonephric tubule, or upper end of mesonephric duct.

Paradidymis—a small collection of coiled tubules found above head, in front of spermatic cord—is a remnant of mesonephros.

Aberrant ductules are slender, twisted diverticula from the canal of epididymis near its lower end; derived from mesonephros; the most constant of them is a foot long.

Vas deferens is direct continuation of canal of epididymis. Ascends in spermatic cord to the deep inguinal ring; passes into pelvis and runs along its side-wall, beneath peritoneum, almost to the level of the ischial spine; turns medially to reach upper border of base of bladder; descends over base, dilating to form an elongated bag called *ampulla*; narrows behind neck of bladder and joins duct of seminal vesicle to form ejaculatory duct.

It begins at lower end of epididymis; runs upwards over the back of testis along medial side of epididymis; ascends to the superficial inguinal ring and traverses inguinal canal as a constituent of spermatic cord, in posterior part of which it is readily palpable in living or dead subject, owing to firm, cord-like character. Leaves the other constituents of cord at the deep inguinal ring; passes medially and backwards, behind inf. epigastric vessels, across ext. iliac vessels, and enters pelvis. In pelvis, it runs backwards and medially, across umbilical art., obturator nerve and vessels, vesical vessels and ureter, to reach sacro-genital fold, near level of ischial spine, where it turns sharply medially, over upper end of seminal vesicle, to reach base of bladder. From the deep inguinal ring to bladder it lies beneath peritoneum, through which it can be seen. At bladder it enters pelvic fascia; runs downwards

on back of bladder, close to median plane and its fellow, medial to seminal vesicle, in front of rectum. Here, it is dilated to form *ampulla*, in which semen accumulates. Lower end of ampulla narrows and joins duct of seminal vesicle to form ejaculatory duct.

Blood-vessels: special artery from inferior vesical; branches from middle rectal to ampulla. **Nerves**: from pelvic sympathetic plexus. **Lymph-vessels** end in glands around iliac arteries.

Spermatic cord extends from the deep inguinal ring to the posterior border of testis. Its constituents are: (1) vas deferens with its artery; (2) the structures essential to the nutrition of the testis, viz., (*a*) testicular artery, (*b*) pampiniform plexus of veins, (*c*) lymph-vessels and (*d*) sympathetic nerves—all enclosed in coats (external spermatic fascia, cremasteric muscle and fascia, and internal spermatic fascia) prolonged over them and over the testis from the layers of the abdominal wall.

The cremasteric vessels and nerve accompany and supply the coats.

RELATIONS.—In Inguinal Canal.—The ilio-inguinal nerve lies in front of it in medial part of canal. *Posterior*: Posterior wall of canal (*see* Walls of Inguinal Canal). Behind that, the extraperitoneal fat containing inferior epigastric vessels at lateral end of canal, and lateral umbilical lig. at medial end. *Anterior*: Anterior wall of canal. In front of that, the superficial fascia containing superficial epigastric vessels at the lateral end of the canal. *Inferior*: Inguinal lig. separating it from femoral sheath and its contents.

Between Inguinal Canal and Testis.—*Anterior*: skin; superficial fasciæ; the two branches of superficial ext. pudendal vessels; testis. *Posterior*: Deep fascia on the upper medial angle of pectineus and upper ends of adductor longus and gracilis; deep ext. pudendal vessels; posterior wall of scrotum.

Seminal vesicles lie on the back of the bladder, enclosed in pelvic fascia. Each is a branched, sacculated tube, blind at one end; it is 6 in. long, coiled to form a piriform body, 2 in. long, which tapers to lower end, where tube is narrowed down to form a slender *duct*.

Long axis is directed upwards, backwards and sidewards; medial border looks, therefore, more upwards than medially when bladder is empty, but is more vertical when bladder is full. **Lower ends** lie above base of prostate behind neck of bladder, and are separated from each other only by the narrow, lower ends of the vasa deferentia. **Upper ends** are two inches or more apart. Upper end of each lies *below* vas deferens; it overlaps entrance of ureter into bladder

anteriorly ; *posteriorly*, it is in relation to levator ani, at the side of rectum, opposite ischial spine. **Lateral border** is supported by levator ani. Vas deferens lies along **medial border. Anterior surface** is related to bladder ; **posterior surface** is related to rectum.

Blood-vessels : from vesical and middle rectal. **Nerves :** from 2, 3, 4, L. through hypogastric plexus. **Lymph-vessels** end in glands alongside iliac arteries.

Ejaculatory duct is formed by the union of vas deferens and the duct of seminal vesicle immediately above base of prostate. It is ¾ in. long, and very slender ; lies close to its fellow, near median plane ; pierces prostate to open into prostatic urethra at the mouth of prostatic utricle. Its lower part passes by the side of the utricle.

Vas deferens, seminal vesicle and ejaculatory duct are all made of non-striped muscle ensheathed in fibrous tissue and lined with mucous membrane. Epithelium which covers the mucous membrane is ciliated in vas deferens.

Prostate lies below bladder ; in front of lowest inch of rectum, through which it can be felt by finger-tip. Firm in consistence ; partly glandular, partly fibro-muscular. Fibrous condensation at surface is called its **capsule.**

Has an *apex* or lower end, *base* or upper surface, an *anterior* surface or *border*, a *posterior surface* and a pair of *lateral surfaces*. An inch and a quarter in length and rather more in width at its base.

Urethra traverses it from base to anterior border near apex. Ejaculatory ducts traverse its upper half, behind urethra. Ducts of its glandular substance open into prostatic sinuses at the sides of urethral crest. Prostatic utricle extends upwards and backwards, from urethra, into its substance for half an inch.

Two lateral lobes and a **median lobe,** not marked off from one another. Median lobe is merely that part which separates urethra in front from ejaculatory ducts and prostatic utricle behind ; its antero-superior part bulges into interior of bladder, producing a slight elevation above the back of urethral orifice, called *uvula vesicæ*. Part behind ejaculatory ducts is sometimes called *posterior lobe*.

RELATIONS.—Encased in a **sheath** of pelvic fascia. Thickened bands of fascia—pubo-prostatic ligaments—pass from back of pubis to be connected with sheath and with fascia at neck of bladder. *Prostatic plexus of veins* (most dense anteriorly, where it receives deep dorsal vein of penis) lies in and under sheath.

Base is partly continuous with neck of bladder and is partly separated by a circular groove which lodges veins. **Apex** is an inch and a half above level of anus, and rests on the fascia that covers sphincter urethræ. **Anterior border,** blunt and rounded, is separated from retropubic space by pubo-prostatic ligaments; from lowest part of symphysis by fibro-fatty tissue and a plexus of veins. **Lateral surfaces** are markedly convex and are supported by levatores ani; and anterior borders of levatores clasp prostate near its apex. **Posterior surface** is flat and rests against lowest inch of rectum.

Arteries: from inferior vesical and middle rectal. **Venous plexus** is drained into int. iliac. **Nerves:** from pelvic sympathetic plexuses. **Lymph-vessels** end in glands on walls of pelvis in front of bladder and alongside the arteries.

Bulbo-urethral Glands.—*See* p. 396.

Urethra.—*See* p. 660.

Penis.—(1) **Root:** buried in the perineum. (2) **Body:** partly concealed at lower part of symphysis; mainly free. (3) **Glans:** the slightly enlarged and conical extremity, whose basal, oblique rim is called the *corona glandis*. (4) **Neck:** constricted part behind glans. (5) **Prepuce:** the loose fold of skin reflected forwards from junction of body and neck to cover neck and variable extent of glans; *frenulum* is the secondary fold that connects lower part of prepuce with glans below orifice of urethra.

Body of penis comprises a pair of **corpora cavernosa** united side by side, and a single **corpus spongiosum** lying in the groove along lower surface of the other two corpora —all encased in fasciæ and skin.

Each corpus is made of erectile tissue enclosed in a thin coat of dense fibro-elastic tissue.

Erectile tissue consists of a fine spongework of fibro-elastic tissue, the spaces of which are lined with endothelium and filled with blood. Distension of these spaces with blood causes erection.

Corpora cavernosa are fused together. Fused part of their coats is called the **septum**, and is interrupted by slits.

Posteriorly, the corpora separate and form **root of penis,** which lies in perineum on lower surface of perineal membrane. At the root, the corpora cavernosa diverge from each other and are called **crura penis.** Each crus extends backwards and sidewards; is adherent to side of pubic arch and to adjoining part of perineal membrane; is covered by ischio-cavernosus; and tapers to a point

posteriorly. Corpus spongiosum extends backwards, expanding to form the **bulb of penis**, which is adherent to the perineal membrane and is covered by the bulbo-spongiosus muscles.

Anteriorly, the corpus spongiosum greatly expands to form **glans penis**; corpora cavernosa separate, and their blunt, anterior ends are imbedded in glans.

Urethra enters deep surface of bulb and traverses whole length of corpus spongiosum, and in glans lies nearer the lower surface than the upper.

Skin of penis is devoid of hairs, except near pubis. On glans, it is exceedingly thin and adherent; on the body of penis, it is thin and freely movable.

Superficial fascia of penis is thin and loose; it is continuous with both membranous and fatty layers of fascia of abdominal wall; contains no fat; is absent from glans; superficial dorsal vein lies in it and is visible through skin.

Deep fascia surrounds the three corpora as a fibrous sheath; dorsal nerves and arteries and deep dorsal vein lie deep to it. *Suspensory lig. of penis* is a triangular, fibrous band fixed by apex and posterior border to the front of symphysis, while its base divides into right and left layers that blend with the sheath at the sides of the penis.

Smegma præputii is a material, with characteristic odour, found between prepuce and glans. It consists of desquamated and broken-down epithelial cells, and secretion of sebaceous glands on glans and prepuce.

Arteries: *On each side*: Artery of bulb traverses and supplies half of corpus spongiosum. Deep art. traverses and supplies corpus cavernosum. Dorsal artery runs forwards on dorsum beneath fasciæ and supplies fasciæ and skin; its terminal branches end in prepuce, frenulum and glans. These three pairs come from int. pudendal, and are cut in a transverse section of penis. Additional branches to skin and fasciæ come from superficial ext. pudendal of femoral, and they also are cut in section near pubis.

Veins correspond. But dorsal veins are not right and left: they are median in position—a *superficial*, which divides to end, on each side, in superficial ext. pudendal; and a *deep*, beneath deep fascia, which ends in prostatic plexus.

Nerves: *To skin and fasciæ*: dorsal nerve; scrotal, of perineal and ilio-inguinal; perineal branch of post. cutaneous of thigh. *To substance of corpora*: (1) sympathetic filaments with the arteries; (2) filaments which come from sympathetic plexus around prostate descend to enter root of penis; (3) a branch from dorsal nerve to corpus cavernosum, and a branch from perineal nerve to corpus spongiosum.

Lymph-vessels go to glands in groin.

FEMALE GENITAL ORGANS

A pair of **ovaries** shed *ova* into peritoneal cavity. Ova pass into a pair of **uterine tubes,** where they may be fertilised and begin development. From uterine tube the fertilised ovum is sent, after a few days, into **uterus** to continue development; and, when intra-uterine development is completed, it is expelled, through **vagina,** to the exterior at **pudendum muliebre** (vulva).

Ovaries, uterine tubes and uterus lie in the pelvis. Vagina lies partly in pelvis and partly in perineum.

Ovary.—Smooth and pink in young nulliparæ; grey, shrunk and puckered in elderly multiparæ.

About the size and shape of a very large almond.

Lies on the side-wall of pelvis, between ureter and broad ligament. It is connected with the broad lig. by an extremely short fold, called *mesovarium*, the squamous epithelium of which is continuous with the cubical epithelium that covers the ovary; between the two layers of mesovarium, the vessels and nerves pass into the ovary.

Tubal end lies near the ext. iliac vessels, and the terminal part of uterine tube curves round it.

Uterine end is connected by the ligament of the ovary with the uterus.

Free border is separated from ureter only by peritoneum.

Mesovarian border is attached to the broad lig. Vessels and nerves enter at this border through a cleft called the *hilum*.

Medial surface, largely overlapped by terminal part of uterine tube, is related to pelvic colon or ileum.

Ovary lies on side-wall of pelvis, and its **lateral surface** is separated by peritoneum from the umbilical artery, obturator vessels and nerve and obturator internus muscle.

Arteries: ovarian from the aorta; branches from the uterine.

Veins form a pampiniform plexus from which the ovarian vein issues at the pelvic brim and ascends to end in the inferior vena cava on the right side, renal vein on the left.

Nerves: from aortic and renal plexuses (ultimately 10 TH.).

Lymph-vessels *ascend to glands alongside vena cava or aorta.*

Uterine Tube.—Four inches long; quarter of an inch wide.

One end opens into anterior angle of uterine cavity; other end opens into peritoneal cavity. Part is imbedded

in wall of uterus. Emerges from uterus between body and fundus; enters broad ligament, and lies in its free edge. Pierces upper layer of ligament near side of pelvis, dragging off a peritoneal sheath with it, and curls round tubal end of ovary, overlapping its medial surface.

Medial inch, outside uterus, is narrow, straight, closely adherent to peritoneal covering, and is called **isthmus.** Remainder is wider and slightly convoluted, more loosely connected with peritoneum, and is called **ampulla.** Abdominal end is the funnel-shaped **infundibulum,** which is broken up into a number of finger-like processes called **fimbriæ.** One of them, longer than others and grooved, is attached to ovary and is called **ovarian fimbria.** Termination of uterine tube is separated by peritoneum from medial side of ureter.

Tube is made of non-striped muscle, enclosed in peritoneum and lined with mucous membrane which is covered with ciliated epithelium and is thrown into folds so that it almost fills lumen of tube; cilia create a sluggish stream of lymph downwards from peritoneal cavity to uterus, and that sucks ovum into tube and drags it onwards.

Blood-supply, from uterine and ovarian vessels. **Nerves,** from uterine and ovarian plexuses—ultimately from 11, 12 TH., 1 L. **Lymph-vessels** go with those of ovary to glands high up in abdomen.

Ep-oŏphoron.—Consists of several minute tubules that radiate forwards in the mesosalpinx from the attachment of the ovary, and end in a horizontal tubule called the **duct** of **ep-oŏphoron.** The duct is a remnant of mesonephric duct and represents canal of epididymis. The other tubules are remnants of mesonephric tubules and represent the ducts of testis and lobules of epididymis.

Par-oŏphoron, a few microscopic tubules that lie nearer uterus; derived from mesonephros; corresponds to paradidymis.

Appendices vesiculosæ, one or more small pedunculated cysts near infundibulum, derived from upper end of mesonephric duct.

Uterus lies between rectum and bladder. Obliquely placed, overhanging bladder.

3 in. long, 2 in. wide at its free end, and 1 in. thick.

Lower third is cylindrical; remaining two-thirds widens towards the free end.

It is a hollow organ; its walls are composed of non-striped muscle mingled with fibro-elastic tissue, are partly covered with peritoneum, and are lined with mucous membrane covered with ciliated epithelium. But it is firm in consistence, for its walls are half an inch thick and the cavity a mere chink (especially in nulliparæ).

The lower, cylindrical inch is called **cervix,** and is

inserted into vagina. Junction of cervix and body is called *isthmus*. Fundus, or rounded free end, is marked off from body, at the sides, by entrance of uterine tubes.

Long axis of uterus is directed forwards and upwards at right angles to vagina and pelvic brim, in the normal position of *anteversion*. When bladder is overdistended, uterus is raised up into line with vagina (*retroversion*). Body is more pliant than cervix and forms an angle with it, opens forwards. This is normal *anteflexion*. Uterus is never quite median. Usually it inclines to the right, and is twisted so that its vesical surface looks slightly towards the right, as well as downwards and forwards.

Vesical surface, nearly flat, is in relation to the bladder, but it may be separated by a loop of intestine. Covered with peritoneum only as far as the isthmus.

Intestinal surface, markedly convex, is covered with peritoneum all the way over body and upper part of cervix, as far as vagina, and the peritoneum passes on to the back of vagina. Pelvic colon or small intestine rests on it and separates it from rectum.

Each **lateral border** is connected with "broad ligament", and, between its layers, with lig. of ovary and lig. teres, branches of uterine art. and uterine venous plexus. These are imbedded in fatty, fibrous tissue, called *parametrium*, which is most abundant near cervix and vagina.

Cervix uteri is inserted into vagina almost at right angles, through anterior wall close to upper end.

Intravaginal part is clothed with mucous membrane reflected on to it from upper part of vaginal walls.

Supravaginal part is covered with peritoneum *posteriorly* and related to intestine; is separated from bladder by fatty tissue *anteriorly*; is connected *laterally* with broad ligament and parametrium containing blood-vessels.

Cavity is divided into cavity of body and cervical canal.

Cavity of Body.—A chink between its vesical and intestinal walls. An inch and a half long. Triangular in outline. Uterine tubes open into its basal angles, its apex is continuous with cervical canal. Mucous membrane is smooth.

Canal of Cervix.—An inch long; spindle-shaped. Uterine end is called *internal os of uterus*, and opens into cavity of body. Vaginal end—*external os*—opens into vagina.

Mucous membrane in cervical canal is raised into median longitudinal folds in front and behind. Secondary branching folds pass upwards and sidewards from these. The tree-like appearance is named **arbor vitæ.** The folds are usually absent after the first pregnancy.

Lig. of ovary is a remnant of the upper part of the gubernaculum of the ovary.

An inch long. Stretches from the uterine end of the ovary to the intestinal surface of the uterus near the entrance of the tube, raising a peritoneal ridge on the upper surface of broad ligament.

Lig. teres uteri is a remnant of the lower part of the gubernaculum.

Attached to the vesical surface of the uterus near the tube. Extends sidewards to the side-wall of the pelvis (raising a ridge on the lower surface of broad ligament), and thence to the deep inguinal ring.

It crosses the vaginal artery, obturator vessels and nerve, umbilical artery, external iliac vein, and, having reached the external iliac artery behind the inferior epigastric, it enters and traverses the inguinal canal, and then descends to end in the skin and fascia of the labium majus.

Arteries of uterus : uterine, and branches of ovarian.

Veins end in internal iliac.

Nerves : from sympathetic plexus around uterine and vaginal arteries ; ultimately from 10, 11, 12 TH. ; 1 L. ; 2, 3, 4, S.

Lymph-vessels : From *cervix* to glands (*a*) on rectum, (*b*) on the front of sacrum, (*c*) around iliac arteries. From *body*, (*a*) mostly with those of the ovary to glands high up on the back-wall of abdomen, (*b*) to glands around the external iliac artery, (*c*) along lig. teres to glands in the groin.

Vagina.—Lies in lower part of pelvis and in perineum. Long axis is parallel to plane of pelvic brim and at right angles to axis of uterus.

Anterior wall is 3 in. long; *posterior wall* is 3½ in. ; they lie in contact except at the upper end, where cervix uteri is thrust into the cavity of vagina through the uppermost part of its anterior wall.

Space between intravaginal portion of cervix and the walls of the vagina is divided into **anterior, lateral** and **posterior fornices,** of which the posterior is deepest, and anterior shallowest.

Objects lying in the recto-vaginal peritoneal pouch may be felt through posterior fornix. Lateral fornix is below parametrium and medial angle of broad ligament; is crossed from behind forwards by ureter, and latero-medially, above ureter, by uterine vessels;

pulsations of the artery can be felt through lateral fornix.

Vagina descends in pelvis behind bladder, in front of rectum, and between the levatores ani; it passes between their "anterior" borders, which can constrict it when the muscles contract; it then passes through the pelvic fascia, the sphincter urethræ and the perineal membrane; and it opens on the perineum between the labia minora.

Vaginal wall is made of:—1. A loose fascial sheath which contains large veins.

2. A muscular coat of unstriped muscle.

3. A layer of areolar tissue that resembles erectile tissue because of a close network of thin-walled blood-vessels which it contains.

4. Mucous membrane covered with stratified epithelium. The mucous membrane has no glands of its own; it is moistened by mucus from the uterus.

Lower end of vagina is partially closed, in virgin, by two folds of mucous membrane, called **hymen.** After rupture, the fragments of hymen persist as little nodules called **carunculæ hymenales.**

RELATIONS.—Vagina is surrounded by its sheath of pelvic fascia.

Anterior: Bladder; urethra, which is partly imbedded in vaginal wall so that it suffers when vagina is stretched during childbirth.

Posterior: *Upper third* or less (¼-1 in.) of posterior wall is *covered with peritoneum* and related to a loop of intestine which separates it from rectum. *Middle third* is in direct relation with lowest part of rectum. *Lower third* is in contact with the perineal body, which separates it from anal canal.

Lateral: Uppermost part is related to lower border of broad lig., and to ureter and uterine vessels; below that, it is related to fat on the pelvic surface of levator ani, and to the "anterior" border of levator; below that, it is related to the sphincter urethræ; below the perineal membrane, the side of lowest part of vagina is related to vestibular gland and bulb of vestibule, covered with bulbospongiosus muscle.

Arteries: uterine, vaginal, middle rectal, internal pudendal.

Nerves: from sympathetic and pelvic splanchnics.

Lymph-vessels go to glands on rectum and alongside iliac arteries; but *some from lower part* run forwards in perineum and then upwards *to glands in groin.*

Female External Genital Organs.—*See* p. 397.

Mammæ.—*See* p. 163.

DUCTLESS GLANDS

From entoderm	Thymus (part of)	*Pharyngeal group*	Endocrine Organs
	Thyroid gland		
	Parathyroid glands		
From ectoderm	Hypophysis cerebri	*Cerebro-glandular group*	
	Pineal body		
	Paraganglia	*Chromaffin group*	
	Carotid body		
	(Glomus coccygeum)		
	Suprarenal gland (medulla)		
	Suprarenal gland (cortex)	*Cortical group*	
	Occasional " accessory cortical bodies "		
From mesoderm	Bone-marrow		Blood-forming Organs
	Spleen		
	Hæmolymph-glands		
	Lymph-glands		
	Tonsils and other aggregations of lymphoid tissue, including—		
	Thymus (lymphoid part of)		

Ductless glands are a number of heterogeneous organs whose products are all removed by veins or by lymph-vessels. Some of them are adjunct to the vascular system, namely—bone-marrow, spleen, hæmolymph-glands, lymph-glands, lymphoid part of thymus, and other collections of lymphoid tissue. The others prepare chemical substances which, not being borne away by ducts, are called *internal secretions*; to these glands the name of **endocrine organs** has been given. [ἔνδον (endon) = *within*; κρίνω (crinō) = *select, set apart*, and, hence, *secrete*.] Ductless glands are so diverse that further division or classification serves no useful purpose; but more than one classification are combined in the Table above, and the student may glance at the arrangement as he reads the list of the names of the organs.

The paraganglia, the carotid body, and the medulla of the suprarenal gland are classed together as the *chromaffin group* or *chromophil system*; they contain a tissue called chromaffin or chromophil because of its affinity for chromium salts; their cells have this also in common that they produce the substance called *adrenine*; they are developed in association with the sympathetic system, and are closely connected with it anatomically. Recent investigations indicate that the carotid body should not be included among them.

The *cortical group* is represented almost solely by the cortex of the suprarenal gland—hence the name "cortical"; but accessory cortical bodies are made of the same tissue as the cortex of suprarenal, and so are the cortical parts of accessory suprarenal bodies. These two kinds of bodies are, however, not often found. They are minute parts of the suprarenal gland that break away in embryonic life and either remain near the main gland or descend with testis or ovary to lie in the epididymis, spermatic cord, or broad ligament. The product and function of cortical tissue are still undergoing experimental and clinical investigation; and, indeed, that may be said of all internal secretions, though a great deal has been found out about some of them already.

Internal secretion is a faculty possessed not only by the organs classified in the Table as endocrine, but also by glands that produce external secretions—*i.e.* products removed by a duct. For example, the internal secretion of the pancreas is no less important than its external secretion; the testis has potent internal secretions. The ovary is peculiar: it has a sexual product not borne away by lymph-vessels or by veins, but it has no duct in the usual sense of gland-duct; it creates internal secretions as well; and there periodically appears in it the *corpus luteum*, which, especially in its fully developed state during pregnancy, produces internal secretion. It would be difficult to deny endocrine function for any glandular structure; and even non-glandular organs have a claim: every muscle produces substances that are removed by veins or by lymph-vessels.

Owing to anatomical connexions and relationships many of the ductless glands are included in other systems. The **pineal body** and **hypophysis cerebri** are described with BRAIN. The **tonsils** and other aggregations of **lymphoid tissue** are described with ALIMENTARY CANAL; the **lymph-glands** and **hæmolymph-glands** with VASCULAR SYSTEM. If paraganglia had come into prominence before their function was found out they would have been described with the Sympathetic System; and bone-marrow could be included appropriately in an account of the structure of Bone.

BONE-MARROW

Bone-marrow produces both red and white blood-corpuscles; and, after birth it is the sole producer of red corpuscles. It is of two kinds—red and yellow.

Red marrow occupies the spaces in spongy bone, and is found also in the medullary cavity of long bones till puberty. Its redness is due to the number of blood-vessels—chiefly veins—and to the number of red corpuscles inside and outside the vessels. It is composed of: (1) delicate areolar tissue surrounding (2) blood-vessels and (3) cells of various kinds—(*a*) some fat-cells; (*b*) *marrow-cells*, which resemble white blood-corpuscles and give rise to them by division; (*c*) small nucleated, reddish-yellow cells, called *erythroblasts*, which become red blood-corpuscles by being moulded into discs and losing their nuclei; (*d*) a few large cells, called *megalocytes* or giant-cells, that resemble osteoclasts, and may possibly give rise to blood-platelets.

Yellow marrow occupies the medullary cavity of long bones, and owes its colour to abundance of fat. It consists of: (1) areolar tissue loaded with fat-cells; (2) blood-vessels; (3) a few cells that give rise to blood-corpuscles.

SPLEEN (LIEN)

The spleen is a bluish-purple, vascular, soft, and pulpy organ that performs slow rhythmical contractions to promote the circulation of the blood within it. It is not essential to life; but one of its functions is to act as a filter for the blood, removing foreign particles and also the outworn red corpuscles; its blood-vessels are therefore large out of proportion to the size of the organ, for they carry blood to be purified as well as for the nutrition of its tissues.

It varies greatly, but its average size is about 5 in. long, 3 in. broad, 1½ to 2 in. thick. It lies in the uppermost part of abdomen, on the left side, hidden behind fundus of stomach, opposite 9th, 10th, 11th ribs. It lies very obliquely, so that its long axis coincides with that of 10th.

Its *medial end* is at the level of the 10th thoracic spine, two inches from the median plane. The highest point on its *upper border* is opposite the 9th rib vertically below the inferior angle of scapula. The upper border is sharp and notched, and the prominent *angle* at its lateral end is opposite the 9th rib in the mid-axillary line. Its *lower border* is parallel to the 11th rib or space; the lateral end of that border is opposite that rib at the posterior axillary line. But, since the spleen varies in size, precise points are of little value. For practical purposes it is enough that it lies opposite the hand laid over the 9th, 10th, and 11th ribs well round at the back.

Surfaces.—Diaphragmatic : large, convex ; separated by diaphragm (1) from pleura, and, in its upper part, (2) from lung also.

Visceral : related to four viscera—stomach, left kidney, left colic flexure and pancreas—which make impressions on it, separated by blunt borders.

Gastric impression is the wide concave area that adjoins the *upper border* ; it is separated from the stomach by the gastro-splenic lig.

Renal impression is the strip that adjoins the *lower border* ; it is continuous with the gastric impression over a blunt margin, whose lateral part may show a slight *pancreatic impression* for the tail of the pancreas.

The *colic impression* is the flat or concave area at the *lateral end* of the organ, which is related to the phrenico-colic lig. as well as to the left flexure of colon.

Hilum is situated on the lower part of the gastric area ; it is a strip pitted by a linear series of 5 or 6 irregular depressions through which the vessels and nerves enter and leave the spleen.

Spleen is almost completely clothed with peritoneum. Gastro-splenic and lieno-renal ligaments, attached to the margins of its hilum, connect it with stomach and kidney.

Blood-vessels : Splenic branch of cœliac artery. Splenic vein ends in portal vein. **Nerves :** through a plexus around splenic art., from sympathetic and vagi. **Lymph-vessels** end in glands that lie in gastro-splenic lig., and on back-wall at upper border of pancreas.

Accessory Spleens.—Small, globular bodies which are sometimes found in the gastro-splenic ligament.

THYMUS

The thymus has a right and a left lobe closely bound together by fibrous tissue.

In a full-time fœtus it is a pink, soft organ, as large as the heart or a lung, and occupies a great part of interior of thorax ; but even at that age it is very variable in size. It lies between the two pleuræ, above the pericardium and overlapping it, and extends up into the root of the neck.

It continues to grow till puberty, after which it degenerates till it is represented by a pair of elongated, yellowish slips that vary in size, are composed chiefly of fatty fibrous tissue, and lie in front of the trachea and great vessels in upper part of thorax and in root of neck. (*See also* pp. 324, 602.)

In its undegenerated state its fibrous sheath sends in septa that divide and subdivide it into lobules and follicles. The follicles have cortical and medullary parts crowded with lymphocytes ; and the medullary parts contain the *concentric corpuscles* of Hassall. These corpuscles and the reticulum of branching cells that forms the frame-

work of the follicle are derived from entoderm, and they may have endocrine activities.

Occasionally the thymus retains its infantile size in the adult. In such cases there is an unusually large quantity of lymphoid tissue throughout the body, and the condition is called *status lymphaticus*.

Arteries: from internal mammary. **Lymph-vessels**: to glands alongside internal mammary artery, on the end of trachea, and in root of neck. **Nerves**: from vagi and sympathetic.

Accessory Thymi.—The entodermal part of thymus is developed from the third pharyngeal pouch. Part of it is sometimes left behind in the neck close to the lower parathyroid, and is called **accessory cervical thymus III** (denoting origin from third pouch). Particles of thymus tissue are, in rare instances, found near the upper parathyroid. They are developed from the fourth pouch, and are called **thymus IV vestiges.**

THYROID GLAND

The thyroid gland lies in the lower part of front of the neck, clasping the larynx and the upper part of trachea.

It is a reddish-yellow organ, vascular and soft, enclosed in a fibrous *capsule* and surrounded by a *sheath* of pretracheal fascia which binds it to the larynx. The venous network from which the thyroid veins spring lies on the surface of the gland between the capsule and the sheath.

The gland has a right and a left lobe, and an isthmus.

The **lobes** lie at the sides of the larynx and trachea, and are united at their lower part by the **isthmus.**

The thyroid gland varies in shape and also in size. It is smaller in thin people than in the well-nourished; and it is relatively smaller in men than in children and women—in whom the full, rounded contour of the lower part of the neck is due largely to the thyroid gland. (*See also* p. 324.)

Accessory thyroid glands are small isolated oval bodies of the same structure as the thyroid gland that are sometimes found near its lobes or near the hyoid bone.

PARATHYROID GLANDS

The parathyroid glands are small brownish-yellow bodies about the bulk of a small pea, but are lens-shaped. They are developed from the third and fourth pharyngeal pouches. Their position is uncertain, ranging from the back of pharynx to superior mediastinum, and one of

them may be within the thyroid gland. They vary also in number, extreme limits being 1 and 12.

Their normal number and position are :—A **lower** pair (derived from the third pouch) on the back of the lower ends of the lobes of the thyroid gland, imbedded in the capsule.

An **upper** pair (from the fourth pouch) similarly imbedded in the back of the lobes, but higher up—about the level of the cricoid cartilage.

If they are in their normal position, an anastomosing vessel that connects the superior and inferior thyroid arteries on the back of the lobe is a guide to them, for it passes close by their medial side.

SUPRARENAL GLANDS

Suprarenal glands are a pair of small, soft, yellowish-brown bodies about the size of a Brazil nut.

Each lies on the crus of the diaphragm opposite the vertebral end of the 11th intercostal space and 12th rib, and it overlaps the medial part of the upper end of the kidney.

Right is behind liver ; **left** is behind stomach. Between the two there are the crura, aorta, cœliac artery, cœliac plexus and ganglia, and the inferior vena cava.

Right gland, triangular. Anterior surface : devoid of peritoneum, except a small part below. Lateral part is covered by the liver ; medial part is overlapped by the inferior vena cava.

Hilum (where the vein issues) is near the upper end.

Left gland, semilunar. Anterior surface : overlapped at the lower end by the pancreas. Crossed by the splenic artery at the upper border of pancreas. Above that it is covered with peritoneum of the lesser sac, which separates it from the stomach.

Hilum, for the vein, is near the lower end.

Arteries : from aorta, phrenic and renal.

Vein ends in vena cava on the right side, in renal on the left.

Nerves (very numerous) : from cœliac plexus and ganglion.

Lymph-vessels end partly in glands that lie alongside, and partly in glands behind the pericardium.

Suprarenal glands are almost as large in the new-born as in the adult, owing to the great thickness of the innermost zone of the cortex of the fœtal suprarenal. That zone disappears after birth, and the growth of the other zones does little more than maintain the size of the organ.

PARAGANGLIA

Paraganglia are rounded nodules of chromaffin tissue, 1 to 3 mm. in diameter, which are present in several situations in close association with the sympathetic system :—1. Inside or closely related to the ganglia of the sympathetic trunk.

2. In connexion with ganglia in the sympathetic plexuses.

3. Scattered through the larger sympathetic plexuses.

4. In the delicate sympathetic plexuses in viscera—they have been found in the kidney, ureter, suprarenal gland, prostate, ovary and par-oöphoron.

The paraganglia which are largest in the fœtus are a pair that lie in the aortic plexus near the origin of the inferior mesenteric artery, and are called **aortic bodies** They, however, though 10 mm. long at birth, are microscopic at puberty and have disappeared at middle age.

Carotid Body.—Is a small nodule about the size of half a barleycorn, placed on the deep surface of the bifurcation of the common carotid artery, or, higher up, between external and internal carotids.

Consists of clumps of cells separated by areolar tissue mingled with nerve-filaments from the glosso-pharyngeal and the superior cervical ganglion of the sympathetic trunk.

Glomus coccygeum.—A small body placed on the front of the coccyx and closely connected with a terminal branch of the median sacral artery. It resembles the carotid body.

DEVELOPMENT

FORMATION OF THE EMBRYO

Early Stages

The mature ovum is called the **female gamete.** The spermatozoön is called the **male gamete.** *Fertilisation* is the union of male and female gametes; and by their union a single cell, called the **zygote,** is formed.

The **zygote** divides again and again to produce a round mass of cells called **morula,** from which both embryo and embryonic appendages are developed. Outermost layer of cells of the morula is called the **trophoblast;** remainder is called the **inner cell-mass.**

The cells of the inner cell-mass become differentiated into three groups, called the **ectoderm,** the **primary mesoderm,** and the **entoderm.**

The primary mesodermic cells multiply faster than the others and, presently, the envelope of trophoblast contains:—

1. A small, rounded cluster of ectodermic cells situated close to the upper[1] pole of the morula.

2. A smaller cluster of entodermic cells immediately below the ectodermic group.

3. A jelly-like mass of primary mesoderm that fills the rest of the envelope, insinuating itself as a thin layer between the trophoblast and the upper (or ectodermic) group, and also between the ectodermic and entodermic groups.

At the same time, cavities appear in the ectodermic and entodermic groups and convert them into two sacs with thin walls made of cells.

The cavity of the upper or ectodermic sac is called the **amnion-cavity;** the part of its wall in relation with the lower sac becomes part of the embryo; the rest of its wall becomes a membrane, called the **amnion,** which in time surrounds the embryo. The part of the wall of the lower or entodermic sac that is in relation with the upper sac becomes the entoderm of the primitive alimentary canal of the

[1] For the convenience of the student of Medicine, the ordinary terms of position are often used in this article; and they are made to harmonise as far as possible with the position of the embryo as he sees it in the diagrams he will have to consult. In many diagrams the head-end is forwards and the back is uppermost; in others the head and trunk are presented in the erect posture.

embryo; the rest of it becomes the entodermic layer of a bag called the **yolk-sac** or umbilical vesicle.

The embryo is developed from the parts of the two sacs that are in relation with each other. The region where they are related is therefore called the **embryonic area;** and it consists of an upper plate of ectoderm, a lower plate of entoderm, and an intervening sheet of primary mesoderm. All the other parts of the morula, including the trophoblast, become what are called the *appendages of the embryo.* The embryonic area is circular at first; but the sacs and the area grow faster in one diameter, so that the area becomes pear-shaped in outline—the larger end being the head-end.

A pair of clefts appear in the primary mesoderm opposite the sides of the embryonic area. They extend backwards and forwards, upwards and downwards, till they meet each other and form an extensive cavity, called the **extra-embryonic cœlom,** which splits the primary mesoderm into an outer and an inner part almost completely. And it expands, thinning out the two parts into: (1) a thin layer that lines the trophoblast; and (2) a thin layer that covers the two sacs and encloses them in one sheath, for the cavity does not extend into the embryonic area. At only one spot outside the embryonic area does the cœlom fail to divide the primary mesoderm into two layers, and that is opposite the tail-end of the embryonic area. In that situation the trophoblast remains connected with the two sacs by a mass of undivided primary mesoderm. As growth goes on, that mass grows in such a way that it becomes a pedicle or stalk called the **allantoic stalk** or body-stalk.

Soon after the embryonic area becomes distinct, a median linear streak, called the **primitive streak,** appears in its tailward half. The streak is a ridge or thickening of the ectoderm, and it grows towards the entoderm, pushing aside the intervening primary mesoderm. The deeper cells of the ridge (*i.e.* those next the entoderm) multiply and form—(1) the structure called the notochord; and (2) the secondary mesoderm, from which all or most of the persistent mesoderm of the embryo is developed.

Folding-off of Embryo

Growth in the greater part of the embryonic area is rapid, and is such as to increase its area rather than its thickness; but growth at its periphery is slow. The area is therefore ballooned up into the amniotic cavity till it resembles an oval basin laid on its mouth. And, growth being continued, it bulges out over its slow-growing margins all round—at the sides and at the tail-end and head-end—forming small **lateral folds,** a larger **tail-fold,** and a much larger **head-fold.** The formation of the tail-fold is hampered by the connexion with the allantoic stalk; and before the tail-fold is formed, a diverticulum from the entodermic sac, called the **allantois,** grows into the allantoic stalk.

When the area has ballooned up to resemble an overturned basin and has bulged out, its periphery or margin is then the rim of the mouth of the basin—in other words, the boundary of a wide opening. The opening is called the **umbilical orifice,** and in time it

becomes the *umbilicus* or navel. That is, the circumference or margin of the embryonic area becomes the margin of the adult umbilicus; and the commencement of the transition is the formation of the head- and tail- and lateral folds. (A simile can be drawn from a circular piece of cloth goffered to make a bag: the circumference of the piece of cloth is the puckered mouth of the closed bag.)

Part of the entodermic sac and cavity is of course included in the bulgings or folds. This included part of the sac becomes the entodermic lining of the **primitive alimentary canal.** The part not included (together with its covering of primary mesoderm) is called the **yolk-sac** or umbilical vesicle; and it communicates freely with the primitive alimentary canal through the umbilical orifice.

The part of the entodermic sac and cavity included in the head-fold is called the **fore-gut**, and from it are derived the pharynx, œsophagus, stomach, and greater part of duodenum. The part opposite the umbilical orifice is the **mid-gut**, and it becomes the greater part of the small intestine. The part in the tail-fold is the **hind-gut**; from it are derived the terminal part of the ileum and the large intestine from the cæcum and vermiform appendix to the middle of the anal canal.

Since the folds have been formed, and the circumference of the embryonic area has become the margin of the umbilical orifice, therefore the anterior or headward part of the embryonic area has now become the lower wall of the head-fold, and the anterior end of the area is not the anterior end of the embryo, but is now the anterior margin of the umbilical orifice. Similarly, the posterior extremity of the area is not the tail-end of the folded embryo, but is the posterior margin of the umbilical orifice.

Formation of Neural Tube

Immediately after the primitive streak is formed in the posterior part of the embryonic area, there appears, in the anterior part, another median longitudinal (but wider) strip of thickened ectoderm which is slightly grooved lengthwise; the groove is called the **neural groove.** At each margin of the groove there is a ridge or fold of ectoderm that overlies a thickening longitudinal bar of secondary mesoderm; the ridge is called the **neural fold.** From the first, the right and left folds meet each other round the anterior end of the groove near the anterior end of the embryonic area; rather later, they meet posteriorly across the primitive streak near its anterior end, so that the most anterior part of the streak is included in the neural groove. When the tail-fold is formed its tip is at the posterior end of the neural groove; the posterior part of the primitive streak lies therefore in the lower wall of the tail-fold, and from it the median part of the body-wall from coccyx to umbilicus is formed.

While the embryo is being folded off, the neural folds rise up, their edges approach each other, meet and fuse together in the median plane, converting the neural groove into the **neural tube** during the third week of embryonic life. When the edges of the neural folds fuse together they form a narrow median strip that connects the tube with the surface-ectoderm. Very soon the secondary mesoderm, growing medially from each side, breaks through the

continuity of surface-ectoderm with the linear strip, which is then left as a ridge along the dorsal surface of the neural tube and is called the **neural crest.** From the crest there are developed :—

1. The cells of primitive sheaths of nerves.
2. The ganglia of spinal and cranial nerves.
3. The ganglia of the sympathetic trunks and plexuses.
4. The chromaffin bodies.

Before the headward part of the groove is quite closed it undergoes dilatation in three places, one immediately behind the other ; these dilatations, when the tube is completed, are called **primary cerebral vesicles.**

The **anterior** vesicle develops into the fore-brain and lateral and third ventricles.

The **middle** becomes mid-brain and aqueduct.

The **posterior** develops into hind-brain, fourth ventricle, and central canal of lower half of medulla oblongata.

The remainder of the tube becomes the spinal cord and its central canal.

Formation of Notochord

The **notochord** is the forerunner of the vertebral column. It is derived from the primitive streak. It is a long, median, rounded rod of cells produced by multiplication of certain of the deeper cells of the headward part of the streak. Its headward end is at the level of the mid-brain ; its tailward end, when completed, is at the level of the part that becomes the tip of the coccyx. At first it becomes imbedded in the entoderm of the dorsal wall of the primitive alimentary canal, but, later, it extricates itself and lies between the entoderm and the neural tube. After a time the secondary mesoderm surrounds it, and it becomes nodulated. The mesoderm which surrounds it develops into :—

1. Posterior part of body of sphenoid and the basi-occiput.
2. Apical ligament of odontoid process.
3. Odontoid process.
4. Discs and bodies of vertebræ down to tip of coccyx.

The nodules persist in the pulpy centres of adult discs ; the rest begins to disappear during the second month of intra-uterine life.

Formation of Secondary Mesoderm

Secondary mesoderm is the persistent mesoderm of the embryo. It is derived from the primitive streak, chiefly from the smaller, headward part of the streak ; the only mesodermic structures derived from the tailward part are those in the perineum and in the median part of anterior abdominal wall from pubis to umbilicus. The deeper cells of the streak multiply rapidly. They form the notochord in the median plane ; and they spread sidewards and headwards and tailwards to form a layer of cells between ectoderm and entoderm throughout the embryonic area. That layer is the **secondary mesoderm,** and it extrudes the primary mesoderm from the embryonic area. (Possibly it blends with the primary mesoderm in the area ; if that is the case, then persistent mesoderm consists partly of primary mesoderm.)

The right and left halves of the secondary mesoderm are united in the primitive streak; but the secondary mesoderm is at first absent from the part of the median plane where the notochord lies; and it never invades the region immediately in front of the neural groove. That region is called the **bucco-pharyngeal area**; the primary mesoderm disappears from it, leaving ectoderm and entoderm in contact. In front of the bucco-pharyngeal area, at the very anterior end of the embryonic area, the two halves of the secondary mesoderm meet together and form a bar called the **pericardial bar** because the pericardium is developed from it.

When the head-fold is formed the pericardial bar and bucco-pharyngeal area lie in its lower wall, and therefore their relative positions are reversed; the bar is now behind the area—immediately in front of the umbilical orifice. It follows that their surfaces and borders also are reversed; the original anterior border is now posterior; the surface that looked downwards towards the entodermic sac looks now upwards towards the cavity of the fore-gut. The bucco-pharyngeal area lies now in the lower wall of the primitive pharynx; its entoderm and ectoderm separate the cavity of the pharynx from the primitive buccal cavity, and, together, are called the **bucco-pharyngeal membrane.**

Division of Secondary Mesoderm and Formation of Embryonic Cœlom

The secondary mesoderm is thickest near the median plane, alongside the notochord and neural groove. Peripherally it is thin; and at the margins of the embryonic area it is continuous with the primary mesoderm that lies outside the area.

In each half of the area it becomes divisible into three parts:—(1) The longitudinal bar alongside the notochord is named the **paraxial mesoderm,** and is united by (2) a longitudinal, thin strip called the **intermediate cell-tract** to (3) the remainder, which is called the **lateral plate.**

In each lateral plate there appear a number of clefts which unite together to form a space called the **embryonic cœlom.** The cœlom extends towards the periphery, dividing the lateral plate into two layers, and becomes continuous with the extra-embryonic cœlom at the margins of the embryonic area. It does not extend into the intermediate cell-tract; but at the anterior end of the area it invades the pericardial bar from both sides and converts it into a tube. The upper or outer layer of the lateral plate is called **somatic mesoderm;** it lines the lateral part of the ectoderm of the embryo, and, at the margins of the embryonic area or margins of umbilical orifice, it is continuous with the primary mesoderm that covers the amnion. The lower or inner layer is called **splanchnic mesoderm;** it covers the entoderm of the primitive alimentary canal, and is continuous, at the margins of the umbilical orifice, with the primary mesoderm that clothes the entoderm of the yolk-sac.

Each bar of paraxial mesoderm is divided by transverse clefts into segments called **mesodermic somites.** The most anterior part, however, is not divided. The undivided part and four of the somites lie in

the head-region; the remainder lie in what becomes neck and trunk and correspond, in number, to spinal nerves, except that there are several somites in the coccygeal region.

The intermediate cell-tract is undivided.

Derivatives of Secondary Mesoderm and of Embryonic Ectoderm, Entoderm, and Cœlom

The medial cells of the **paraxial mesoderm** multiply, pass medially and surround the notochord and neural tube in a continuous sheath, called the *membranous vertebral column*, from which there are developed the skull, the vertebræ, their ligaments, the discs, and the dura mater. (Pia and arachnoid *may* be mesodermic, but are probably derived from neural ectoderm.)

The remainder of the paraxial mesoderm gives rise to the striped muscles throughout the body.

The **somatic mesoderm** becomes :—

1. The unstriped muscle of head and neck and limbs and walls of trunk.
2. The bones and other connective tissues, except those of the vertebral column and skull.
3. Tunicæ vaginales of testes, parietal layer of peritoneum and of pleuræ and pericardium.

The **splanchnic mesoderm** becomes :—

1. The visceral layer of peritoneum, pleuræ and pericardium.
2. Connective and muscular tissues of alimentary canal, urinary bladder, spleen, heart and great blood-vessels.

The **intermediate cell-tract** becomes a great part of the urogenital system.

The **embryonic cœlom** becomes the cavities of the serous membranes—peritoneum, tunicæ vaginales, pleuræ and pericardium.

The **surface ectoderm** gives rise to :—

1. Epithelium of skin, including epidermis of vestibule of nose, of external auditory meatus and the lateral surface of tympanic membrane, and of the lower part of anal canal.
2. Epithelium of certain mucous membranes :—(*a*) of the inner surfaces of lips and cheeks; (*b*) of gums and hard palate; (*c*) of the cavity of nose and air-sinuses; (*d*) of naso-lacrimal duct; (*e*) of the terminal part of male urethra.
3. Secreting cells—(*a*) of sebaceous and sweat glands; (*b*) of ceruminous and mammary glands; (*c*) of lacrimal, tarsal and ciliary glands; (*d*) of glands of hard palate and vestibule of mouth; (*e*) of parotid gland; (*f*) of the anterior lobe of hypophysis.
4. Epithelium that lines the ducts of the foregoing glands.
5. Epithelium—(*a*) of conjunctiva, cornea and lens and of internal ear; (*b*) of hair-follicles and hairs; (*c*) of the enamel of teeth; (*d*) of the olfactory part of nose.

The **neural ectoderm** gives rise to :—

1. Ependyma, neuroglia, nerve-cells and nerve-fibres of central nervous system.
2. Cells and fibres of peripheral nervous system.

3. Chromaffin tissues.
4. Epithelium of retina and on the back of ciliary body and iris.
5. Epithelium of pineal body and posterior lobe of hypophysis.

The **entoderm** gives rise to :—

1. Epithelium of certain mucous membranes—(*a*) of tongue, floor of mouth, soft palate, pharynx, and the rest of the alimentary tube down to the middle of the anal canal ; (*b*) of gall-bladder ; (*c*) of pharyngo-tympanic tube, tympanum and antrum, and mastoid air-cells ; (*d*) of trachea and bronchi ; (*e*) of urinary bladder, female urethra, and most of male urethra.
2. Secreting cells—(*a*) of glands in and under the foregoing mucous membranes ; (*b*) of sublingual and submandibular glands ; (*c*) of liver and pancreas ; (*d*) of prostate, bulbo-urethal and vestibular glands.
3. Epithelium that lines the ducts of the foregoing glands.
4. Epithelium of alveoli of lungs.
5. Taste-buds.
6. Epithelium of vesicles of thyroid gland.
7. Concentric corpuscles and reticulum of thymus.

APPENDAGES OF EMBRYO AND FŒTUS

Amnion, Chorion, Yolk-Sac, Allantois ; Umbilical Cord, Placenta

The embryo is enclosed in two membranes called the **amnion** and the **chorion.** The chorion consists of trophoblast with its lining of primary mesoderm. In the region where the morula is imbedded in the mucous membrane of the uterus, the parts of chorion and of mucous membrane next the uterine wall are greatly thickened and specialised. From these thickenings the **placenta** is formed. The embryo is connected with the placenta by the **umbilical cord.** All these structures, except the maternal portion of the placenta, are derived from the zygote.

The zygote is formed in the upper part of the uterine tube ; after about five days, when it has reached the morula stage, it enters the uterus and at once imbeds itself in the uterine mucous membrane.

The mucous membrane of uterus is greatly increased in thickness and vascularity in order to receive the morula, and is then called the **decidua.** The decidua increases still farther in thickness and vascularity, and is divisible into three layers :—

1. *Compact stratum*, where interglandular tissue predominates, is nearest to the cavity of the uterus.
2. *Spongy stratum*, which consists largely of the dilated portions of uterine glands.
3. *Unchanged stratum*, next the muscular wall of uterus, contains the bases of the glands, which are unaltered.

The morula is implanted on the intestinal wall of the uterus near the fundus, and eats its way into the compact stratum of decidua.

The part of decidua between the morula and the muscular layer of the uterus is called **decidua basalis.** It forms the maternal portion of placenta ; it comprises the unchanged stratum, the spongy

stratum, and the outer portion of the compact stratum.

The part that covers the morula is called **decidua capsularis,** and it comprises the inner or superficial portion of the compact stratum.

All the rest of the decidua is called **decidua parietalis.** It lines the whole cavity of the body of the uterus, except the spot where the morula is imbedded.

The decidua capsularis is pushed before the enlarging embryo and its membranes till, at the end of the *second* month, it meets and fuses with decidua parietalis, obliterating the uterine cavity. The fused decidua capsularis and decidua parietalis atrophy, and are reduced to a thin layer.

The *allantoic stalk* of primary mesoderm is connected by one end with the mesoderm that covers the entodermic and ectodermic sacs at the hinder extremity of the embryonic area, by its other end with the mesoderm that lines the part of the trophoblast opposite decidua basalis, *i.e.* the part of the trophoblast that becomes the fœtal portion of placenta. A diverticulum, called *allantois*, grows from the entodermic sac into the stalk. When the tail-fold is formed, the posterior end of the embryonic area becomes the posterior margin of the umbilical orifice ; the stalk is then connected with the mesoderm at that margin of the orifice ; and umbilical blood-vessels from the embryo run along the allantois, traversing the stalk, to reach the placenta.

The part of the entodermic sac left outside the embryo forms the entodermic lining of the **yolk-sac.** It retains its continuity with the primitive alimentary canal inside the embryo, through the umbilical orifice, by a neck called the **vitello-intestinal duct** (*vitellus* = yolk). As the allantoic stalk elongates, the duct does so also ; it lies closely applied to the front or headward surface of the stalk, and its mesodermic covering fuses with the mesoderm of the stalk.

The **amnion** is the upper, larger part of the wall of the ectodermic sac—the lower part being the ectoderm of the embryonic area. The amnion is covered with primary mesoderm. When the embryo is formed and bulges into the amnion cavity, the amnion is continuous with the embryonic ectoderm at the margins of the umbilical orifice, and it is connected with the trophoblast by the allantoic stalk of mesoderm ; but, except for that connexion, its mesodermic covering is quite separated by the extra-embryonic cœlom from the mesodermic lining of the trophoblast. **Amniotic fluid** or liquor amnii accumulates in the amnion-sac and distends it in all directions, until the extra-embryonic cœlom is obliterated by fusion of the mesoderm that covers amnion (1) with the mesoderm that lines trophoblast, and (2) with the blended mesoderm of vitello-intestinal duct and allantoic stalk—both of which are now enclosed together in an amniotic sheath.

The **umbilical cord** is therefore composed of :—

1. The elongated allantoic stalk of primary mesoderm.
2. Allantois and (3) umbilical vessels contained within the stalk.
4. The vitello-intestinal duct with its covering of primary mesoderm fused with the stalk.
5. The enclosing amniotic sheath.

At birth, the cord is a spirally-twisted rope—20 inches long and barely as thick as a finger—which connects the umbilicus of the child with the placenta. The allantois and vitello-intestinal duct have shrivelled and disappeared. The amniotic sheath encloses *a pair* of spiral umbilical arteries and *a single* vein, all imbedded in a mucoid substance, called **Wharton's jelly**, derived from the mesoderm.

The **chorion** consists of the trophoblast and its lining of primary mesoderm. As soon as the morula is imbedded in the uterus, the outer part of the trophoblast becomes greatly thickened at the expense of the surrounding decidua, which it absorbs as it thickens. When it consumes the walls of the blood-vessels in the decidua, the vessels open directly into spaces that have appeared in the thickening trophoblast; the arteries pour their blood into the spaces and the veins remove it. These blood-spaces are distended by the maternal blood circulating in them. The strands and partitions of trophoblastic tissue between the spaces are called **chorionic villi**; chorionic mesoderm and twigs from the umbilical vessels grow into them and into numerous branches that sprout out from their sides into the blood-spaces; these branches also are called villi. In the part of the chorion covered by decidua capsularis the villi disappear. But the part connected with the allantoic stalk and related to decidua basalis shares in the formation of the placenta; in it the thickening of the trophoblast is much more marked, and the villi persist. They and the blood-spaces continue to enlarge; their branches re-branch and almost fill the spaces; and the greater part of the thickness of the placenta is made up of branching chorionic villi.

The **placenta** is made up of: —

1. Decidua basalis.
2. Branches of uterine blood-vessels.
3. Mesoderm and trophoblast of chorion largely developed into chorionic villi.
4. Branches of umbilical blood-vessels.

The blind end of the yolk-sac persists as a minute vestige under the amniotic covering of placenta.

The formation of the placenta is completed at the end of the *second month*, and the embryo is then called the *fœtus*.

The placenta is the respiratory, nutritive, and excretory organ of the embryo and fœtus. At first the zygote subsists on food-stuffs contained within itself at its formation; later, as the morula, it derives sustenance from the decidua by osmosis and from the actual decidual tissues consumed by the trophoblast; when the placenta begins to be formed, exchange of nutriment and excrement takes place between the maternal and embryonic blood; very soon the embryo, even before it becomes the fœtus, is wholly dependent on the placenta, and continues to be so during the rest of intra-uterine life. The embryonic (or fœtal) blood passes to and from the placenta by the umbilical vessels, and circulates through the capillaries in the chorionic villi, which bulge into the blood-spaces and are bathed in the maternal blood circulating in the spaces. Oxygen and nutritive material pass from the maternal blood, through the substance of the villi and the walls of the capillaries, into the embryonic blood.

Carbon di-oxide and other excretory matters pass the reverse way from embryonic blood to maternal blood.

Expulsion of Fœtus from Uterus.—When intra-uterine development is completed, the uterus contracts, the canal of cervix uteri dilates, amnion and chorion are ruptured where they overlie the canal, liquor amnii and the fœtus are expelled, the umbilical cord is cut by the doctor or the midwife and both ends are tied. Further contractions of the uterus separate the placenta and membranes from the uterine wall through the plane of the spongy stratum of decidua. They are expelled, the placenta coming first, through the rupture in the membranes; the membranes follow and are turned inside out, so that the amnion is outermost.

The membranes consist of the fused amnion and chorion, with shreds of the compact stratum of the fused decidua capsularis and parietalis on the surface of the chorion.

The *placenta at birth* is a disc of 6 to 8 inches in diameter and over an inch thick, and about a pound in weight. Its uterine surface is rough and lobulated. Its fœtal surface is smooth, owing to its covering of amnion, and near its centre the umbilical cord is attached to it.

Uterine vessels are torn when the placenta separates, and some blood escapes; profuse bleeding is prevented partly by the elastic shrinking of the uterus, but chiefly by its continued contraction. If the uterus relaxes after the separation of the placenta, a profuse, dangerous **post-partum hæmorrhage** results.

The uterine mucous membrane is re-constructed from the *unchanged stratum* of the decidua.

FORMATION OF NOSE AND MOUTH [1]

Upper part of head-fold projects forwards and is called **fronto-nasal process.** Pericardial mesoderm bulges upwards and forwards. Depression between them is called the **stomodæum.** Thickenings, called pharyngeal arches, appear in each side-wall of the fore-gut. First of these is called the **mandibular arch.** Its anterior end grows till it meets its fellow above the pericardial bulging. A thick, blunt projection, called the **maxillary process,** grows forwards and upwards, from the dorsal end of the mandibular arch, towards the fronto-nasal process.

Stomodæum is therefore bounded:—

Above, by the fronto-nasal process.

Below, by the pericardial bulging, and later by the mandibular arches.

On each side, by the mandibular arch and its maxillary process.

Its *dorsal wall* is the bucco-pharyngeal membrane, which disappears during the third week, and then the stomodæum communicates with the fore-gut.

Stomodæum develops into the *cavities of the nose* and the *upper part of the mouth.*

Two depressions, called **olfactory pits,** appear on the free, project-

[1] In this section, terms of position are used as though embryo were erect.

ing margin of the fronto-nasal process. Ectoderm that lines them becomes the olfactory epithelium of the nose and a part of the olfactory bulb. Pits deepen and grow backwards along the roof of the stomodæum, dividing the fronto-nasal process into a median nasal process and a pair of lateral nasal processes.

Free angles of the **median nasal process** become rounded and projecting, and they are called **globular processes.** Median region of the median nasal process is divided by a transverse ridge into two areas—an upper, triangular area, which becomes the dorsum of the nose, and a lower, quadrilateral area, which becomes the free part of the nasal septum. Globular processes come together and fuse to form the *philtrum*, *i.e.* the median part of upper lip.

Lateral nasal processes become the alæ of nose.

Maxillary process begins below the eye, and it extends forwards and medially to form :—

1. Lateral wall and floor of orbit.
2. Lower part of lateral wall of the cavity of the nose.
3. Cheek and lateral part of upper lip.

For a time it is separated from the lateral nasal process by a groove, called **oculo-nasal sulcus,** which leads from the eye-region to the stomodæum ; but, later, the maxillary process fuses with the lateral nasal process, and then, growing farther medialwards and dragging the lateral nasal process with it, it fuses with the globular process, separating the orifice of the olfactory pit from the rest of the stomodæum. Stomodæal orifice is thus divided into a pair of nostrils and a large oral orifice. Oculo-nasal sulcus becomes the lumen of the lacrimal sac and naso-lacrimal duct.

A pair of ridges, called **nasal laminæ,** grow backwards for a short distance along the roof of the stomodæum from the globular processes. They fuse, and form the premaxillary portions of the maxillæ. Behind these, a horizontal ledge grows medially from the inner surface of each maxillary process. The ledges fuse with each other in the median plane and with the nasal laminæ anteriorly ; and they form the *palate*. At the same time a median septum grows down from the under surface of the median nasal process and fuses with the palate. It contains a core of cartilage continuous with the cartilage of the base of the skull. This is replaced posteriorly by the *vomer* and *perpendicular part of ethmoid* ; anteriorly, it becomes the *septal cartilage*. Nasal and oral cavities are now separated, and the nasal cavity is divided into right and left halves. A process from the cartilage of the cranial base bulges into the upper lateral part of the nasal cavity and becomes the *labyrinth of ethmoid* and *inferior nasal concha*.

Hare-lip results from non-union of maxillary and globular processes ; *cleft palate*, from non-union of the palatine process with the nasal lamina and with its fellow.

DERIVATIVES OF PRIMITIVE ALIMENTARY CANAL [1]

Tuberculum Impar and Furcula.—Two elevations appear in the floor of the fore-gut. An upper, rounded, called **tuberculum impar,**

[1] In this section, terms of position are used as though embryo were erect.

becomes the part of the tongue immediately in front of the foramen cæcum. The lower, called **furcula,** is a ridge bent like a hair-pin; it encloses a median groove and is bounded by a groove called **sinus arcuatus.** Upper, closed end of furcula becomes the *epiglottis* and *ary-epiglottic folds.* Lips of the median groove meet and fuse to convert the groove into a tube; the tube becomes detached from the part of the floor of the fore-gut that forms the œsophagus, but retains communication, by its upper end, with the part that becomes the pharynx. The tube becomes the cavity of the *larynx* and *trachea.* Its lower end bifurcates to form the rudiments of the *bronchi,* before the lips close to form the tube. End of each bronchus enlarges to form the vesicles of the *lung.* Left divides into two, right into three—forming the lobes of the two lungs—and each invaginates its own side of the pleural part of the cœlom.

Pharyngeal Arches, Pouches and Grooves.—On each side, in the lateral wall of that part of the fore-gut which becomes the pharynx, localised thickenings of mesoderm produce six bars called **pharyngeal arches**—seen best from the inside. The first is the largest and uppermost. They diminish in size serially, and the fifth and sixth are seen only from the inside; the fifth is smallest and soon disappears. The arches are separated on the inside by furrows called **pharyngeal pouches,** and on the outside by furrows called **external pharyngeal grooves.** In these furrows between the arches, the surface ectoderm and the entoderm are separated by only a little mesoderm.

Entoderm of the first pouch becomes the epithelium of the mucous membrane of the *pharyngo-tympanic tube* and *tympanic cavity and antrum.* Ectoderm of the first groove becomes the epidermis of the *external meatus.* Both contribute to the *tympanic membrane.*

Ectoderm and entoderm of the second, third, fourth grooves and pouches assist in forming the epidermis of the neck and the epithelium of the pharynx; and the following also are derived from the pouches and their entodermic walls:—

Intratonsillar cleft from the second pouch.

Tonsillar pits from the second pouch by eight or ten entodermic buds which grow into the wall of the pharynx and become surrounded by the mesodermic lymphoid tissue of the tonsil.

Thymus is derived from a pair of buds which grow from the entoderm of the third pair of pouches. They descend in the neck to reach the pericardium. Stalks of the buds disappear; their lower ends enlarge, and, becoming surrounded with mesodermic lymphoid tissue, develop into the lobes of the thymus.

Space in front of the epiglottis and at its sides is a remnant of the third pair of pouches.

Parathyroid glands bud out from the third and fourth pairs of pouches and become surrounded by mesodermic fibrous tissue; and the stalks of the buds disappear. The parathyroid from the third pouch is dragged by the thymus to a lower level than parathyroid IV.

Thyroid Gland.—A median entodermic bud grows downwards, in front of the hyoid bone and larynx, from the groove behind the tuberculum impar, and it bifurcates to form the isthmus and lobes of the thyroid gland. Stem forms the *thyro-glossal duct,* whose upper end remains as the *foramen cæcum* of the tongue; the lower end

forms the *pyramidal lobe of thyroid*; and the main part becomes a fibrous cord, broken up by the hyoid bone. Duct may partly persist and form cysts above and below the hyoid bone.

Piriform fossa at side of larynx is a remnant of fourth pouch.

Ultimo-branchial or *post-branchial bodies* are a pair of gland-rudiments developed from a transitory fifth pair of pouches; what becomes of them is not known; they probably disappear.

First arch is called mandibular; second, hyoid; third, thyro-hyoid; the others, unnamed. Each consists of ectoderm and entoderm and a mesodermic core in which there are developed a *bar of cartilage*, a *nerve*, and an *arterial aortic arch* (which is dealt with under Vascular System, p. 700). Posteriorly, the pharyngeal arches blend with the side of the head in front of the plane of the neural tube. Anteriorly, in the early stage, they rest on the pericardium; but as the head grows they are carried beyond the pericardium and lie in the front of the neck.

First pair of arches form the lateral and lower boundaries of the stomodæum, and they meet together in front of the tuberculum impar. They form the soft tissues around the mandible and its teeth. A pair of protuberances grow from their inner surface near the median plane and form nearly the whole of the anterior two-thirds of the tongue.

The nerve of the first arch is the *mandibular*.

Cartilage in each first arch is called **Meckel's cartilage**. Its ventral end becomes included in the part of the *mandible* medial to the mental foramen. Dorsal end ossifies to form the *malleus* and *incus*. Remainder disappears, but the membrane around it forms the *spheno-mandibular lig.*

Maxillary process extends from the upper border of the dorsal end of the first arch to form the lateral part of the upper lip and the face between the orbit and the mouth. It contains a process of cartilage in association with which the *maxilla*, the *zygomatic* and *palatine* bones and the *medial pterygoid plate* are developed.

The other arches form the sides and front of the neck.

Ventral ends of the second and third arches insinuate themselves between the tuberculum impar and the furcula, and they fuse with their fellows of the opposite side: and these ventral parts of the third pair grow forwards over the second pair to become the lymphoid tissue and mucous membrane of the *posterior third of tongue*—pushing the second pair downwards and excluding them from the tongue.

Tongue is formed, therefore, from the first and third arches and tuberculum impar. *Sulcus terminalis* of the adult tongue indicates the division between the part formed by the third arch (supplied by glosso-pharyngeal nerve) and that formed by tuberculum impar and the first arch (supplied by lingual branch of mandibular).

Musculature of the tongue grows forwards from the paraxial mesoderm of the occipital region (taking the hypoglossal nerve with it), and invades the tongue from below.

Cartilage of the second arch is replaced by the *styloid process*, *stylo-hyoid lig.*, *lesser horn* and *medial part of body of hyoid*. Nerve of the second arch becomes the *facial*.

Ventral end of the cartilage of the third persists to form the *greater horn* and *lateral part of body of hyoid*; rest disappears. Nerve is the *glosso-pharyngeal*.

Greater part of the cartilages of the fourth and sixth disappear, but their ventral ends form the *cartilages of larynx*. Nerves are the *superior laryngeal* and *recurrent laryngeal* respectively.

Precervical Sinus.—A depression whose floor is the third and fourth arches. Its boundaries overlap it and then grow over it, shutting off the fourth arch from the surface. The buried ectoderm usually disappears, but may persist and give rise to a cyst in the neck. If not completely closed, it forms a fistula whose mouth is near the anterior border of the lower part of sterno-mastoid.

Platysma is an extension of the musculature of the second arch.

Œsophagus—Stomach—Duodenum

Furcula becomes a tube and is separated off to form the larynx and trachea. The part of the fore-gut from which it is separated becomes the *œsophagus*, which is elongated by the descent of the stomach.

Stomach appears, about the fourth week, as a fusiform dilatation of the fore-gut, below the furcula, in the region of the heart. It descends into the abdomen as the diaphragm is formed. Dorsal surface grows more rapidly—hence the *greater curvature*. It is rotated so that the left surface becomes ventral. Greater curvature continues to grow, and in a direction to the left and downwards.

Mesentery of stomach, or *dorsal mesogastrium*, is originally attached at the median plane, and its surfaces are right and left. Owing to the rotation of the stomach and continued growth of the greater curvature, the right surface of the mesogastrium comes to look forwards, and the left surface backwards. Part of the left or dorsal surface fuses with the parietal peritoneum, so that the upper part of the line of attachment is to the left of the median plane, and the lower part curves medially to reach the median plane.

Duodenum also rotates. Its mesentery fuses with the parietal peritoneum, and the right side of the duodenal loop becomes adherent to the dorsal wall of abdomen.

Lesser Sac and **Greater Omentum.**—Rudiment of *lesser sac* is produced by (1) rotation of stomach, (2) shifting of attachment of mesogastrium to the left, and (3) fixation of duodenum.

The two layers of the portion of the mesogastrium connected with the lower or right part of the greater curvature bulge downwards, and, increasing enormously in area, extend towards the pelvis as a reduplicated fold which becomes the *greater omentum*.

Spleen—Liver—Pancreas

Spleen develops from the mesoderm between the layers of the upper, left part of the mesogastrium, and divides it into *gastro-splenic* and *lieno-renal ligaments*.

Liver.—A diverticulum grows out from the ventral wall of the duodenum. It becomes separated into two parts:—

1. A hepatic section, which forms the hepatic duct and its branches and the main mass of the glandular substance of the liver.

2. A cystic section, which forms the *gall-bladder* with its duct, and the *bile-duct*, which, by differences of the rate of growth of the duodenum, moves its connexion with duodenum from the ventral surface, across the right or posterior surface, to the adult postero-medial position.

Hepatic rudiment grows into a mesodermic mass, called the septum transversum, which becomes part of the pericardium and diaphragm and provides the mesodermic elements of the liver. Rudiment enlarges and forms the right and left lobes of the *liver*.

Liver grows out of the septum again into the cavity of the abdomen, dragging with it mesodermic tissue, called the *ventral mesogastrium*, which becomes thinned down to form the *falciform ligament* and the *lesser omentum*. Liver grows completely out of the septum, but is retained in contact by mesodermic tissue which becomes the *coronary* and *right and left triangular ligaments*.

In the early months the liver almost fills the abdominal cavity. Growth is relatively less rapid in the later months, but even at birth it is one-eighteenth of the body-weight and fills half the cavity, and the left lobe touches the spleen and the left kidney. In the adult it is about one-fiftieth of the body-weight—the left lobe having been reduced relatively more than the right.

Pancreas.—Three pancreatic rudiments—a dorsal and two ventral—arise from the duodenal part of the fore-gut, but the left ventral soon disappears. The **dorsal rudiment** forms the *tail*, *body*, *neck*, and greater part of *head*. The persisting **ventral rudiment** arises in connexion with the bile-duct, and forms the *uncinate process* and the back of the adjoining lower part of the *head*. The rudiments fuse; and a communication between their ducts enlarges so that the contents of the duct of the dorsal part are diverted into the ventral duct, and the terminal part of the dorsal duct remains small. Body and tail grow into the part of the dorsal mesogastrium which fuses with the parietal peritoneum.

Intestine

Intestine is derived from the mid-gut and hind-gut, and is held to the dorsal wall of abdomen by a *mesentery*. The part that comes to form *jejunum*, *ileum*, *ascending* and *transverse colon* grows forwards as a loop which encloses an extension of the mesentery; and this extension contains the superior mesenteric vessels between its layers. Vitello-intestinal duct is attached to the apex of the loop; the duct usually loses connexion with the gut very soon, but it persists in 2 per cent. of bodies as the *diverticulum ilei*, situated about 3 feet from the end of the ileum.

Cæcum appears as a small outgrowth about the middle of the lower limb of the loop. After it appears, the ends of the loop come close together, and the loop is rotated through 90°, so that the upper limb of the loop becomes the right limb.

About the fifth week, the loop, from lack of room in the abdomen, passes into the umbilical cord, where the part that becomes the small

intestine elongates and is twisted into coils. About the tenth week, the loop is drawn back into the abdomen. The coils of small intestine enter on the right side of the mesentery of the descending colon and push it towards the left.

Further rotation, through another 90°, carries the colic limb of the loop across the front of the duodenum, so that the cæcum comes to lie below the right lobe of the liver. Cæcum descends to the iliac fossa about the sixth month. The apical part of the cæcum grows in length, but the lumen of that part remains small; and it becomes the *vermiform appendix*. Downward enlargement of the antero-lateral wall of the cæcum, from the region above the root of the appendix, brings the appendix to its adult postero-medial position above the blind end of the cæcum.

Mesentery may all persist, but the part in connexion with the descending colon usually fuses with the parietal peritoneum. Transverse mesocolon fuses with the posterior layers of the upper part of the greater omentum. Ascending colon is produced as the cæcum grows downwards from the liver; it has no mesentery, but may acquire one. Mesentery of small intestine assumes its oblique attachment as the cæcum grows downwards.

Cloaca.—At a very early stage the greater part of the hind-gut is divided into a dorsal and a ventral part by a septum which grows tailwards from the point of junction of hind-gut and allantois. The septum is split lengthwise, and the dorsal and ventral sections of the gut are then quite separate.

Dorsal section becomes, roughly, the *colon*; ventral section shrivels and becomes the *urachus*.

The terminal part of the hind-gut is for a time undivided, and expands to form a chamber called the **cloaca**; but a continuation downwards of the septum divides it also into two parts—the *rectum* and upper part of anal canal dorsally and a uro-genital part ventrally.

At the blind end of the cloaca, its cavity is separated from the amniotic cavity by the **cloacal membrane**, which consists of (1) cloacal entoderm and (2) surface-ectoderm of the caudal part of the ventral wall of the tail-fold, and is comparable to the bucco-pharyngeal membrane in the ventral wall of the head-fold. By increase of surrounding mesoderm, the membrane comes to form the floor of a surface-depression called the **cloacal fossa**. Mesoderm grows into the membrane from the sides and forms a transverse ridge which divides the fossa into the **proctodæum** dorsally and the **uro-genital fossa** ventrally; and the septum which divides the cloaca fuses with that ridge when it completes the division of cloaca.

Proctodæum forms the lower part of the *anal canal*; the sphincter ani externus develops in its walls; the part of the cloacal membrane that forms its floor and separates it from the upper part of the anal canal disappears during the third month. *Anal valves* may be remnants of that membrane.

Post-anal or *tail-gut* is a diverticulum of the hind-gut under the root of the tail. It usually disappears, but it may persist and give rise to tumours.

FORMATION OF URO-GENITAL ORGANS[1]

The uro-genital section of cloaca is divisible into an upper **urinary part** and a lower part called **uro-genital canal.** The part of the cloacal membrane that forms the floor of the uro-genital fossa and separates it from the canal disappears during the third month, and the canal then opens into the fossa.

At the anterior boundary of the uro-genital fossa there is an elevation divided into right and left parts, called **labio-scrotal folds,** and a median part, called the **genital eminence,** on to which the uro-genital fossa is prolonged as a groove.

In the female the urinary part of the cloaca becomes the greater part of the *bladder* and the whole of the *urethra.*

Uro-genital fossa remains open and enlarges to form the *pudendal cleft.*

Uro-genital canal becomes shorter and shorter till it merely surrounds the openings of the urethra and vagina into the pudendal cleft.

Genital eminence becomes the *clitoris.*

Labio-scrotal folds grow backwards at the sides of the uro-genital fossa and become the *labia majora.*

Labia minora are thin folds of skin developed at the margins of the fossa.

In the male the urinary part of the cloaca becomes the greater part of the *bladder* and the front and sides of the upper half of the *prostatic urethra, i.e.* down to the level of the orifice of the prostatic utricle.

Uro-genital canal becomes the lower half of the prostatic urethra and also the *membranous urethra.*

The lower opening of the canal is the slit-like uro-genital fossa, and its entoderm is prolonged into the groove on the genital eminence. The eminence elongates and forms the *penis.* The right and left lips of the opening of the canal and of the groove meet and fuse together, from behind forwards, to form the *spongy part of urethra,* which at first opens on the under surface of the penis behind the glans ; and a solid cord of ectodermic cells extends from the opening to the end of the glans along its under surface. That cord becomes grooved ; the opening then closes and the edges of the groove meet each other to form the terminal part of the urethra. Sometimes the groove fails to close, and the urethra then opens on the under surface of the penis permanently.

The labio-scrotal folds grow backwards, meet together behind the closing urethra, and enlarge to form the *scrotum* when the processus vaginales grow into them.

Vestibular and *bulbo-urethral glands* and the glands of the *prostate* arise as outgrowths from the uro-genital canal.

Mesonephric duct (Wolffian) is a mesodermic canal formed on the dorsum of the intermediate cell-tract near the head-end of the embryo. It grows tailwards, and its caudal end turns forwards and opens into the cloaca at the junction of the urinary part and the uro-genital canal.

Mesonephros (Corpus Wolffii) is developed from the intermediate cell-tract ; it consists largely of tortuous tubules—one end blind, the other opening into the mesonephric duct.

[1] Terms of position are used as though embryo were erect.

The *ureter* arises as a diverticulum from the mesonephric duct near its caudal end. The diverticulum elongates, growing headwards behind the body-cavity. Its blind end dilates to form the *pelvis of ureter*, and it divides and re-divides to form the *calyces* of the ureter and the *collecting tubules* of the kidney. The rest of the renal tubules are formed from metanephric tubules, which are like mesonephric tubules but are situated lower down.

The cloacal end of the mesonephric duct opens out and is gradually included in the wall of the urinary section of the cloaca, till the orifice of the ureter appears in the cloaca. The process of opening out and inclusion still goes on for a time and involves the ureter as well as the duct, till the orifice of the ureter is separated by a wide interval from that of the duct (which in the male becomes the orifice of the ejaculatory duct into the urethra). Therefore the back of the adult bladder is formed not from cloaca but from the caudal ends of the mesonephric ducts and their ureteral diverticula; and, in the male, the posterior wall of the upper half of the prostatic urethra also is formed from the ducts.

In the male the rest of the mesonephric duct becomes the *ejaculatory duct*, *vas deferens*, and *canal of epididymis*. The *seminal vesicle* is a diverticulum from it.

In the female the mesonephric duct largely disappears, but parts persist as the *duct of ep-oöphoron* and *appendices vesiculosæ*.

Mesonephric tubules nearly all disappear. Some persist to form, **in the male**, the *rete* and *efferent ducts* of the testis, the *lobules of the epididymis*, the *paradidymis*, the *aberrant ductules*, and one of the two *appendices testis*; **in the female**, the *par-oophoron* and the vertical tubules of *ep-oöphoron*.

Para-mesonephric ducts (Müller) are formed, one on each side, lateral to the mesonephros, by linear evagination of the mesoderm that lines the cœlom. Their cephalic ends open into the cœlom. They grow tailwards, cross in front of the mesonephric ducts, and their caudal parts unite to form a single tube which opens into the upper part of the uro-genital canal between the mesonephric ducts.

Fused portion becomes the *uterus* and *vagina*; owing to the shortening of the uro-genital canal, the vagina comes to open directly into the pudendal cleft. Unfused portions become the *uterine tubes*, which throughout life open into the cœlom or body-cavity.

In the male, the para-mesonephric ducts largely disappear; but parts persist as the *prostatic utricle* and the other *appendix testis*.

Genital Gland : Testis or **Ovary.**—On the back-wall of the cœlom, at the medial side of the mesonephros, a mesodermic ridge appears, called the *genital ridge*. It is covered with a layer of *germinal epithelium*, which consists of modified peritoneal epithelium intermingled with germinal cells. The germinal cells are the progenitors of ova or spermatozoa. Ova and ovarian follicles *or* spermatozoa and convoluted seminiferous tubules are developed from the germinal epithelium. The underlying mesoderm gives rise to the stroma of ovary or testis; outgrowths from the mesonephros form the ducts of the testis.

The genital gland becomes isolated, and slung by a short peritoneal fold called the *mesovarium* or *mesorchium*. A mesodermic band

begins at the skin that becomes the labium majus or the scrotum, extends through the lower part of the anterior wall of the abdomen and along the back-wall to the diaphragm; its lower part is called the **gubernaculum.** The gubernaculum is adherent to the genital gland, to the peritoneum below the gland, and, in the female, to the developing uterus and uterine tube at their junction. It does not grow *pari passu* with the body, and gets relatively shorter. It therefore draws the genital gland downwards.

In the female, the ovary is drawn only as far as the brim of the pelvis. After that the gubernaculum keeps pace with the rest of the body. The part of it between uterus and ovary is the *lig. of ovary* of the adult; the part between uterus and labium majus is the *lig. teres*. When, at the sixth year, the uterus sinks into the pelvis it drags the ovary with it.

In the male, the gubernaculum becomes relatively very much shorter. By the seventh month of intra-uterine life it has drawn the testis to the deep inguinal ring, and into the scrotum by the end of the eighth.

The descent of the testis into the scrotum is preceded and facilitated by the development of the **processus vaginalis.** The processus is a tubular diverticulum of the peritoneum that lies below the testis; it is dragged by the gubernaculum through the abdominal wall (whereby the inguinal canal is formed) into the scrotum.

The testis travels down behind it and invaginates the scrotal part, which becomes the *tunica vaginalis testis*. The upper part usually shrivels, and is called the *vestige of processus vaginalis*.

In some cases one or both testes may remain in the abdomen or may stick in the inguinal canal. In some animals the testes remain normally in the abdomen, *e.g.*, elephant. In others, *e.g.*, rabbit, the upper part of the processus remains open, and the testes are periodically withdrawn into the inguinal canal by the cremaster.

The vessels and nerves retain their origins in the region where the genital gland was formed, and they elongate to keep pace with it in its descent.

DIVISION OF EMBRYONIC CŒLOM AND FORMATION OF DIAPHRAGM[1]

Embryonic cœlom has a right and a left half united at their cephalic ends by the median portion in the pericardial bar.

The mesoderm that lines the cœlom becomes the *serous membranes* –peritoneum, pleuræ and pericardium. The headward parts of the two halves become the right and the left *pleural* cavities; and the median portion is the cavity of the *pericardium*. The tailward parts become the *peritoneal* cavity. They unite ventrally to form a single cavity after the embryo is folded off and when the umbilical orifice narrows down and closes; but even after birth a partial separation is maintained by the mesenteries, the falciform lig. and the folds connected with the stomach and spleen.

When the head-fold is formed, the pericardium lies in the lower wall of the fold, below the fore-gut, immediately in front of the umbilical orifice; and each pleural part lies at the side of the fore-gut.

[1] Embryo is in horizontal position, back uppermost.

The communication or continuity between the cavities of the pericardium and pleura is now a short passage that lies obliquely at the side of the lower or ventral part of the fore-gut—the part which becomes the trachea. When the pleural part is invaginated by the growing lung-bud, and expands in a ventral direction and headwards on the lateral side of an enlarging venous channel called the duct of Cuvier, that duct is pushed by it in a medial direction, compresses the communicating passage against the side of the developing trachea and obliterates the passage; so that very soon the pericardial cavity is isolated from the pleural cavity of each side.

The wall of the pericardial cavity nearest the umbilical orifice is thickened by the invasion of pre-muscular tissue from the mesodermic somites that correspond to the 3rd, 4th, and 5th cervical nerves—chiefly from the 4th somite. The thickened mass is called the **septum transversum.** It separates the fore-gut from the region of body-wall that lies immediately in front of the umbilical orifice.

Diaphragm.—Only the headward layer of septum transversum shares in the formation of pericardium. Its tailward parts develop into the falciform lig., lesser omentum, and the mesodermic elements of liver. The middle layer of the septum forms the *ventral part* of the **diaphragm,** *i.e.* the part between the œsophagus and the ventral wall of the body; and it retains its close connexion with the pericardium, liver, etc., throughout life.

The *dorsal part* of the diaphragm, *i.e.* the crura and the part between gullet and backbone, is derived from portions of the cervical somites that grow in between the fore-gut and the developing vertebral column and give rise to longus capitis and cervicis and the dorsal part of the diaphragm.

The *lateral part* is developed from a sickle-shaped ridge which appears in the side-wall of the cœlom and is connected ventrally with the side of the septum transversum. The edge of the sickle grows in a medial direction, constricting the cœlom and the serous lining; and it completely separates the pleural and peritoneal portions when it reaches the fore-gut and the dorsal part of the diaphragm. In some cases it fails to meet the dorsal part, especially on the left side. The pleural and peritoneal cavities are then not completely separated; and abdominal viscera may be herniated through the aperture of communication into the thorax.

Diaphragm, pericardium, and heart are originally formed in the neck and obtain their nerve-supply in the neck. During the course of development they migrate tailwards, and their nerves elongate to keep pace with them.

FORMATION OF BLOOD-VESSELS AND HEART[1]

First-formed Vessels

A network of vessels appears on the wall of the yolk-sac, out of which a pair of main vessels, called **vitelline veins,** emerge at the anterior and upper part of the sac.

[1] The embryo is horizontal, with back uppermost.

About the same time, just when the embryo begins to be folded off, a pair of vessels, called the **primitive aortæ**, appear in the lower or splanchnic layer of the pericardium. Their headward ends are continuous with the vitelline veins at the anterior margin of the embryonic area. As they increase in length at their tailward ends, each gives off : (*a*) a number of *vitelline* or *splanchnic arteries*, which end in the network on the yolk-sac ; and (*b*) an *umbilical artery*.

The umbilical artery arises by several roots, some of which communicate with the network on the sac ; it passes with the allantois into the allantoic stalk, to end in a vascular network in the chorion.

An *unpaired umbilical vein* from the chorion leaves the allantoic stalk at the tail-end of the embryonic area and divides into a pair of branches called the **right** and **left umbilical veins** ; these two veins run forwards, along the margins of the area, to end in the primitive aortæ at their junction with the vitelline veins.

Peristaltic contractions pass from head-end to tail-end of the primitive aortæ and propel the embryonic blood into their branches ; and the blood is returned by the umbilical and vitelline veins.

Arteries

When the head-fold is formed, and the pericardium comes to lie below the fore-gut with its surfaces reversed, the anterior parts of the primitive aortæ are carried round with it. Each aorta, therefore, is bent like a hook, and is divisible into three parts :—

1. The short limb of the hook, situated in the splanchnic (now upper) layer of the pericardium, is called the **ventral aorta** ; its caudal end was originally the cephalic end of the unbent aorta, and now lies in the septum transversum, where it is still continuous with the vitelline and umbilical veins.

2. The shank of the hook is called the **primitive dorsal aorta** ; it lies below or ventral to the mesodermic somites.

3. The bight of the hook is called the **first aortic** or **arterial arch** ; it lies in the first or mandibular pharyngeal arch.

When the tail-fold is formed, the proximal part of each **umbilical artery** is included in it. The artery springs by roots from the primitive dorsal aorta near the tail-end of the embryo, and it runs in the lower wall of the tail-fold to the umbilical orifice, where it enters the allantoic stalk. Its roots fuse together to form the *common* and *internal iliac* arteries. After birth the greater part of the umbilical artery loses its lumen and becomes the fibrous cord called the *lateral umbilical ligament*.

Each **ventral aorta** is divisible into an anterior and a posterior part.

The **posterior parts** of the two unite together in the median plane to form the primitive tubular **heart**. The tube grows in length and girth and is divided by slight constrictions into five parts named, from behind forwards, the *sinus venosus*, *atrium*, *ventricle*, *bulbus*

cordis and *truncus arteriosus*. The sinus is the tailward division and remains connected with the veins.

The **anterior part** of each ventral aorta lies in the neck, separate from its fellow. It is continuous with the end of the truncus. It is connected with the primitive dorsal aorta from the outset by the first arterial arch, and later by four others.

Six pairs of **arterial arches** appear in the pharyngeal arches at the sides of the fore-gut, and are *all connected with the primitive dorsal aorta* (except the fifth). The **first** is that already mentioned. The ventral ends of the **second, third,** and **fourth** are at first connected with the truncus arteriosus, but, later, are shifted on to the unfused part of the ventral aorta. The **sixth** is connected with the truncus. The **fifth** passes from the ventral end of the fourth arch to the sixth arch near its dorsal end ; and, like the fifth pharyngeal arch, it is short-lived.

Each **primitive dorsal aorta** is divisible into an anterior and a posterior part.

The **posterior part** fuses with its fellow to form the permanent *descending aorta* and the *median sacral artery*.

The **anterior** or **headward part** remains separate, and is connected with the truncus and ventral aorta by the arterial arches.

The following parts disappear :—

1st, 2nd, and 5th arches of both sides.

Dorsal part of right 6th arch.

Left dorsal aorta between 3rd and 4th arches.

Right dorsal aorta from the 3rd arch to the anterior point of fusion of right and left dorsal aortæ.

Persisting parts give rise to permanent vessels as follows :—

The *arch of aorta* has a multiple origin:—

1. The headward end of the truncus arteriosus forms its proximal part as far as the origin of the innominate artery.

2. The tailward end of the left ventral aorta forms the part between the origins of the innominate and left common carotid.

3. The left fourth arch forms the part between (*a*) the origin of common carotid and (*b*) the origin of subclavian or the point where the left vagus crosses the arch.

4. The left dorsal aorta, on the tailward side of the fourth arch, forms the remainder.

Right ventral aorta becomes the *innominate, right common carotid* and *external carotid*.

Left ventral aorta becomes part of the arch of aorta, and the *left common carotid* and *external carotid*.

Internal carotid of each side is developed from the third arch and the part of the dorsal aorta on the headward side of that arch.

Fourth arch of the left side forms part of the arch of aorta ; the *left subclavian* springs from the dorsal aorta at its junction with that arch.

Fourth arch of the right side forms the root of the *right subclavian* only as far as the point where it is crossed by the vagus ; the remainder of the right subclavian is derived from a branch that springs from the transient part of the right dorsal aorta at its junction with the fourth arch.

The roots of the right and left *pulmonary arteries* are formed from the ventral parts of the sixth pair of arches, and the rest of them from branches that spring from these arches.

The dorsal part of the right sixth arch disappears, while that of the left forms the *ductus arteriosus*, which becomes the *lig. arteriosum* after birth. The recurrent laryngeal nerve hooks round the sixth arch at the tailward side of its junction with the dorsal aorta. Therefore, after birth, the left nerve hooks round the lig. arteriosum behind its junction with the arch of aorta. The corresponding part of the right dorsal aorta and the adjoining part of the right sixth arch disappear ; the right recurrent laryngeal nerve slips up and is caught on the fourth arch, and therefore hooks round the root of the subclavian artery.

In rare cases the ventral aortæ fuse together as far headwards as the fourth pair of arches, forming a single stem which springs from the arch of aorta and divides into the right subclavian and both common carotids. Occasionally the right subclavian springs from the commencement of the descending aorta and passes obliquely behind the œsophagus to reach the right side ; in such a case the right fourth arch has disappeared and the section of the right dorsal aorta between the fourth arch and the junction of the two dorsal aortæ has persisted to form the thoracic part of the artery. Fairly often the left vertebral springs from arch of aorta between the left subclavian and carotid ; in that case the part of the somatic artery that normally forms the root of the left subclavian has opened out and been included in the arch of aorta. Similar absorption of roots of other stems which normally spring from the arch gives rise to different variations.

Besides the arterial arches, three series of branches spring from the primitive dorsal aortæ—(1) dorsal or somatic ; (2) lateral ; and (3) ventral or vitelline or splanchnic.

The **splanchnic arteries** supply the yolk-sac and alimentary canal. When the aortæ fuse the splanchnic pairs also fuse to form median, unpaired vessels. Most of them disappear. Some of them and their anastomoses persist to form the stems and branches of the *cœliac*, *superior mesenteric*, and *inferior mesenteric*, and also the *bronchial* and *œsophageal* branches of aorta.

The **lateral arteries** supply the structures developed in the intermediate cell-tract. Those that persist form the *middle suprarenal*, *renal*, and *testicular* or *ovarian*.

The **somatic arteries** arise in regular pairs opposite the intervals between mesodermic somites or segments. They persist in the greatest number ; and their stems and branches give rise to most of the arteries of the body. Each divides into a dorsal and a ventral division, which accompany the rami of a spinal nerve ; these divisions give off further branches, including the lateral branch of the ventral division, which accompanies a lateral cutaneous nerve. That arrangement survives in the chest and to a large extent in the loins. Longitudinal anastomoses between them and between their divisions and branches give rise to vertical arteries, wholly or in part, such as the *epigastrics*, the thoracic part of *internal mammary*, the second and fourth parts of *vertebral*, etc.

The **seventh** pair of **cervical** somatic arteries assumes great importance.

The *stem of the left* artery forms the subclavian up to the origin of vertebral.

The *stem of the right* forms the subclavian between the vagus and the origin of the vertebral.

On both sides, the *dorsal division* forms the first part of the vertebral; and the *ventral division* forms (*a*) the subclavian between the origins of the vertebral and internal mammary, and (*b*) the cervical part of internal mammary.

The *lateral branch of the ventral division* enlarges to form the second and third parts of the subclavian and its continuation into the upper limb. That continuation becomes the axillary, brachial, and anterior interosseous: the larger arteries of the forearm are branches of the original trunk—an aberrant origin of one of them giving rise to "high division" of the brachial artery.

The third part of the vertebral is developed from the *spinal branch of the first intersegmental artery* and the neural continuation of the spinal branch.

Common and internal iliac arteries are derived from the fused roots of the umbilical artery, which, in the fœtus, is the chief branch of the internal iliac. The roots were composed of blended somatic and splanchnic arteries, for the internal iliac is distributed both to parietes and to viscera.

The original artery of the lower limb was the inferior gluteal, which descended in the back of the thigh, passed in front of popliteus and ran down the back of the leg. The external iliac and its femoral continuation appear later. The only part of the original trunk to be incorporated in the persistent trunk is the popliteal artery down to the level of popliteus; the original portion in the leg becomes the peronal artery.

Heart

The heart is at first a simple median tube that lies in the dorsal or splanchnic layer of the inverted pericardium; but it is soon divided into the *sinus venosus, atrium, ventricle, bulbus cordis,* and *truncus arteriosus,* whose cavities are continuous with each other through slightly constricted orifices.

The bulbus is absorbed partly by the ventricle and partly by the truncus and will not be considered further.

The tubular heart elongates more than the pericardium, and therefore becomes bent; the ventricle bends and bulges in a ventral direction and tailwards; the atrium bulges headwards, dorsal to the ventricle. At the same time, septa begin to appear in the atrium, ventricle and truncus, to divide each of them into two.

Two thickenings appear on opposite sides of the boundary of the atrio-ventricular orifice; they approach each other and fuse together to form a bridge across the orifice, dividing it into two. The *fleshy part* of the *ventricular septum* grows upwards from the ventral part of the ventricle; it fuses with that bridge and with the *membranous part,* which grows into the ventricle as an extension of the septum of the truncus. The two ventricles intercommunicate in the

adult if one or other part of the septum is imperfectly developed.

The *septum of truncus* begins ahead of the orifices of the sixth pair of arterial arches—between them and the apical part of the truncus with which the roots of the ventral aortæ are connected. It grows tailwards to meet the ventricular septum, dividing the truncus into **ascending aorta** and **pulmonary trunk.**

The pulmonary trunk is the part in communication with right ventricle and with the sixth pair of arches—from which the right and left pulmonary arteries spring.

The aorta is the part in communication with the left ventricle and with the ventral aorta and the other arches.

To bring each part into communication with the proper ventricle the septum grows spirally. Spiral grooves at the edges of the septum deepen and split the septum—completely dividing ascending aorta from pulmonary trunk. The spiral curve of the septum accounts for the relation of the pulmonary trunk to the ascending aorta in the adult. The spiral is in rare cases left-handed, bringing the vessels into communication with the wrong ventricles, or it may be insufficient, leaving each vessel in communication with both ventricles.

Inside the atrium an *atrial septum* grows from the headward and dorsal wall to meet and fuse with the bridge across the atrio-ventricular orifice ; if fusion is imperfect, a patent **primary foramen ovale** is left in the septum. Before fusion is complete an aperture, called the **secondary foramen ovale,** appears in the septum. A second septum grows tailwards at the right side of the first, and overlaps the secondary foramen till after birth, when it fuses with the first septum and usually closes the secondary foramen completely. Its caudal edge becomes the **annulus ovalis** ; in some adult hearts, a small aperture—a remnant of the secondary foramen ovale—is hidden under the annulus at the upper part of the fossa ovalis.

The *sinus venosus* receives the veins and opens into the atrium on its dorso-caudal aspect. The atrial septum is set at the left side of the orifice. After the septum is formed, the sinus is modified into the shape of a pair of hollow horns whose mouths open side by side into the **right atrium.** The left horn becomes the **coronary sinus.** The right horn grows much larger, its mouth widens out, and it is gradually included in the right atrium. The part of the adult right atrium that has musculi pectinati (including auricle) is formed from the original atrium ; it is marked off from the part derived from the sinus venosus by the crista terminalis and the valves of the inferior vena cava and coronary sinus.

Two *pulmonary veins* from each developing lung unite to form a right and a left stem, which join to form a single trunk that opens into the **left atrium.** First the single trunk and then the two stems open out and are included in the left atrium, forming the upper part of its dorsal wall.

The various **valves of the heart** are formed from ingrowths from the margins of the orifices.

When the tubular heart bends and bulges ventrally, the bend includes (1) the bulging ventricle in the middle, (2) truncus arteriosus on the headward side of the ventricle, (3) atrium and sinus on the tailward side. As the bent tube invaginates pericardium, a fold (or

sheet of two layers) of invaginated pericardium, called the *mesocardium*, is formed in the concavity of the bend. The two layer, first adhere to each other and then break down: (1) forming the **transverse sinus** of pericardium; (2) leaving the truncus enclosed in a sheath of pericardium, and, therefore, the ascending aorta and pulmonary trunk are enclosed together in a single sheath of serous pericardium.

Veins

Venous networks pervade the tissues of the embryo and fœtus, as they do also in the adult. Linear localised enlargements of parts of the networks give rise to the named veins. These veins, since they are developed within networks, are connected together by numerous anastomoses. They and their anastomoses undergo transformations before the adult arrangement is arrived at; and variations are fairly common owing to disappearance of parts of primitive veins and their anastomoses that normally persist, and compensating persistence of parts that normally disappear.

The chief venous channels of the embryo, named in the order of their appearance, are:—

1. *Vitelline*, which collect blood from the yolk-sac and the alimentary canal.

2. *Umbilical*, which drain blood from the chorion and, later, from the placenta.

3. Somatic veins, which receive blood from the body of the embryo, namely (*a*) *precardinal*, (*b*) *post-cardinal*, (*c*) *duct of Cuvier*, (*d*) *subcardinal*, (*e*) *supracardinal*, and (*f*) the forerunners of the azygos and hemiazygos veins.

They are all paired, for even the unpaired umbilical divides when it reaches the embryo.

The two **vitelline veins** come from the yolk-sac, pass through the septum transversum and enter the sinus venosus. The liver grows into the septum, intercepts them and breaks them up into a network of wide channels which afterwards become the blood-capillaries of the liver. The cardiac ends of the vitelline veins, however, persist to form the *right* and *left hepatic veins*, which drain the network. After a time the left vein loses connexion with the sinus venosus and joins the right vein; the part of the right vein on the cardiac side of the junction becomes the *uppermost part of inferior vena cava*.

Below the liver the vitelline veins anastomose together across the ventral side and dorsal side of the developing duodenum. They and their anastomoses partly disappear; surviving parts form the *portal vein and its right and left branches*, which end in the network in the liver.

The *splenic* and *superior mesenteric veins* are evolved from networks in the mesogastrium and mesentery. They join the part of the left vitelline that becomes the commencement of the portal. The *inferior mesenteric* similarly is evolved from a mesenteric network.

The unpaired **umbilical vein** in the allantoic stalk (and, later in the umbilical cord) divides at the umbilical orifice into a **right** and

a **left umbilical vein,** which pass through the septum transversum into the sinus venosus. When the liver grows into the septum they end in the vitelline venous network inside it. Very soon, however, the right vein disappears and the left vein opens into the terminal part of the left branch of the portal. But, at the same time, a new channel, called the **ductus venosus,** has been evolved from part of the vitelline network; the ductus connects the left branch of the portal vein with the cardiac end of inferior vena cava, and carries most of the blood from the remaining umbilical vein straight to the vena cava. After birth the umbilical vein and ductus venosus, no longer having placental blood to carry, become fibrous cords known respectively as *lig. teres of liver* and *lig. venosum.*

The development of somatic veins in the human embryo requires further investigation, and the student is advised to omit it.

The **postcardinal vein** lies dorsal to the mesonephros. It extends from the pelvis to the root of the neck, where it joins the precardinal vein to form the duct of Cuvier. It conveys the blood from the body-wall, mesonephros, lower limb (and, for a time, upper limb) to the duct of Cuvier, which enters the sinus venosus. A great part of it disappears. Those of its **tributaries** that develop into *lumbar, intercostal,* and *external iliac veins* persist, though most of them come to end in veins derived from other primitive channels.

Surviving parts of the **left** postcardinal vein form (1) *internal iliac,* (2) commencement of *common iliac.*

Surviving parts of **right** vein form (1) *internal iliac,* (2) *common iliac,* (3) the very commencement of *inferior vena cava,* (4) terminal part of *vena azygos.* The greater part of the left common iliac is formed from an **anastomosis** between right and left postcardinals.

The **subcardinal vein** appears later. It lies ventro-medial to the mesonephros. It receives veins from that body and from the genital and suprarenal glands. Anastomoses connect it with its fellow and with the postcardinal of its own side; and its ends join the post-cardinal near the pelvis and in the thorax. Most of it disappears.

The surviving part of the **right** subcardinal vein forms the *right suprarenal*; and, by usurping a segment of the postcardinal, it forms the section of *inf. vena cava* that lies between the entrances of the right renal and suprarenal. At the same time that section becomes connected with the cardiac end of the right hepatic vein by a localised enlargement of the liver-network which becomes the part of the vena cava imbedded in the back of the liver. Therefore, at that stage, the blood from the lower limb and abdomen ceases to traverse the whole length of the postcardinal vein and to reach the heart *via* duct of Cuvier; it now passes from the tailward part of the postcardinal into these newly-formed parts of the inferior vena cava, and reaches the heart by a shorter route.

The surviving part of **left** subcardinal forms the *left suprarenal* vein and part of the *left renal.*

An **anastomosis** between subcardinals survives to form the greater part of the *left renal* (all the part to the right of the entrance of the

suprarenal). On each side, an **anastomosis** between the subcardinal and postcardinal receives the vein from the genital gland, and becomes part of the *testicular* or *ovarian*.

The **supracardinal** is the latest vein to appear. It lies dorso-lateral to the aorta. Anastomoses connect it with its fellow of the opposite side and with the other veins of its own side. The left vein disappears. The persisting part of the right vein forms the *inferior v. cava* up to the entrance of the renal vein. An **anastomosis** between the right supracardinal and subcardinal gives rise to the section of the *inferior vena cava* at the entrance of the renal veins. The original vein from right kidney joins that anastomosis.

The vein from the left kidney ends in an anastomosis between the sub- and supra- and post-cardinal, at the upper end of the left testicular—at the level of the transverse anastomosis that forms the greater part of the left renal.

The *azygos* and *hemiazygos veins* are formed from a pair of longitudinal trunks that develop dorso-lateral to the aorta, between the two sympathetic trunks. Between these two venous trunks there is a venous plexus whose persisting parts form the transverse parts of the hemiazygos veins and the parts of the *lower left lumbar* veins that cross behind the aorta.

The **precardinal** is the first somatic vein to appear. It lies in the head and neck and receives their veins; after a time it receives the vein from the upper limb (which at first enters the postcardinal). The precardinal joins the postcardinal of the same side in the root of the neck to form the **duct of Cuvier**—a wide venous channel which opens into the sinus venosus. As the heart migrates into the thorax the ducts are dragged with it and become longitudinal. **Right duct** becomes the intra-pericardial part of the *superior vena cava* (*i.e.* the part below entrance of vena azygos, whose upper part is formed from a postcardinal). **Left duct**—sometimes called "left superior vena cava"—shrinks and is represented in the adult by the *oblique vein of left atrium* and the ligament of the left vena cava in a fold of the pericardium.

Each precardinal vein is divisible into an extracranial and an intracranial part.

Extracranial part of **right** vein becomes the *internal jugular, innominate*, and extra-pericardial part of *superior vena cava*. That of the **left** vein becomes (1) *internal jugular*, (2) the part of *innominate* between its origin and the entrance of superior intercostal, (3) upper part of *superior intercostal*. Remainder of the left innominate is developed from an anastomosis between the precardinals.

Anterior and *external jugular* are local, linear enlargements of the venous networks of the superficial parts of neck. At first the *cephalic vein* of the upper limb crosses superficial to the clavicle and joins the external jugular. But, later, an anastomosis between the cephalic and the axillary enlarges to form its proximaal part and the part superficial to clavicle usually disappears.

Intracranial part of precardinal is called the **primary head-vein.** It lies longitudinally in the mesoderm that becomes the skull and meninges. Its anterior part (head regarded as in erect posture) is medial to the developing trigeminal ganglion; its posterior par is

lateral to the developing internal ear (otic vesicle). It is continuous with the extracranial part at the place where the jugular foramen is formed.

The veins from the region of the developing eye (optic vesicle) enter the anterior end of the primary head-vein : survivors of them fuse together to form the *ophthalmic vein* or *veins*.

The networks of veins that overlie the developing brain and pervade the tissues which become the skull and meninges are drained by three trunks into the primary vein. The **anterior trunk** enters it at its anterior end ; the **middle trunk** enters it between the trigeminal ganglion and the otic vesicle ; the **posterior trunk** enters it at its junction with the extracranial part in the region of the jugular foramen.

The continuity of the anterior trunk is soon broken—about its middle. Its upper part becomes connected with the middle trunk ; the lower part retains connexion with the anterior end of the primary vein, and becomes the *spheno-parietal sinus*.

The middle of the middle trunk is connected with the upper end of the posterior trunk by an anastomosis situated above the otic vesicle. That anastomosis enlarges. Simultaneously, the corresponding part of the primary vein disappears—*i.e.* the part between the entrance of the middle trunk and the entrance of the posterior trunk—and the posterior trunk is left in communication with the extracranial part of the precardinal vein at the jugular foramen.

As the brain grows and the mesoderm is folded in between its growing divisions to form the *falx cerebri* and *tentorium* and *tela chorioidea*, several channels are formed in the venous networks in the mesoderm, and they give rise to the *superior* and *inferior sagittal sinuses*, *straight sinus*, and *internal cerebral veins*. The upper part of the middle trunk elongates with the growth of the brain, which pushes it backwards and downwards ; and it becomes the *transverse sinus*, while the *sigmoid sinus* is formed from the supra-otic anastomosis and the posterior trunk. The lower part of the middle trunk becomes the *superior petrosal sinus*. The part of the primary vein in front of the entrance of the middle trunk becomes the *cavernous sinus*.

Inferior petrosal and *occipital sinuses* are channels developed in the venous network in the lower part of the brain-envelope.

FORMATION OF CENTRAL NERVOUS SYSTEM

Neural tube is at first a single layer of ectodermic cells. These multiply and become differentiated to form :—

1. The columnar ciliated *ependyma* of the central canal of the spinal cord and of the ventricles of the brain.

2. The *neuroglia* in the substance and on the surface of the spinal cord and brain.

3. The *nerve-cells and their processes*.

The multiplying nerve-cells aggregate in the side-walls of the tube, so that very soon the **central canal** is a narrow dorso-ventral slit, with thick side-walls and thin roof- and floor-plates. A longitudinal groove appears on the inner surface of the side-wall, and

the canal then becomes lozenge-shaped on cross-section. The part of the side-wall dorsal to the groove is called the *alar lamina*; ventral part is called the *basal lamina*. In the brain the *superior* and *inferior foveæ* and *sulcus hypothalamicus* indicate the line between the alar and basal laminæ.

Spinal Cord.—In the spinal cord the *posterior grey column* is developed in the alar lamina, and the *anterior grey column* in the basal lamina. The white matter is on the outside of the laminæ; it is produced by growth of fibres that arise in the spinal cord and by fibres that grow into it from the spinal ganglia and the brain. As the anterior grey columns grow and become covered with white fibres, each half of the spinal cord bulges forwards, and the *anterior median fissure* is formed between them. Dorsally, no fissure is formed; and the median septum which separates the posterior white columns consists of neuroglia.

Up to the fourth month the spinal cord extends the whole length of the vertebral canal. It extends only as far as the sacrum at the sixth month, to the third lumbar vertebra at birth, to the upper border of the second lumbar in the adult.

Brain.—Cephalic end of the neural tube is dilated, and it is divided by constrictions into three **primary cerebral vesicles,** which develop into fore-, mid-, and hind-brains. Fore-brain and the anterior part of the head are bent round the cephalic ends of the fore-gut and notochord, so that a sharp *cephalic flexure* is formed in the region of the mid-brain, which then forms the most prominent and bulging part of the head in young embryos. The whole head is bent forwards so that a *cervical flexure* is produced at the junction of hind-brain and spinal cord. This is undone after birth when the head is raised. Brain-tube is bent, without involving the head, in the region of the pons, so that a forward convexity is produced, called the *pontine flexure.*

Hind-Brain.—Its cavity becomes the *fourth ventricle* and the central canal of the lower half of medulla oblongata. Side-walls thicken by the development and growth of nerve-cells and nerve-fibres in them; and in the part where the ventricle is formed the side-walls fall apart from one another and form the right and left halves of the *pons* and upper half of *medulla oblongata.* The corresponding part of roof-plate becomes therefore greatly expanded; the *medullary vela* are formed in it, but at the lower part of the roof of the ventricle it becomes ependyma only. Floor-plate is greatly thickened by intercrossing fibres.

Before the side-walls fall apart, the dorsal edge of each, in the medullary section, curls sidewards, forming what is called the **rhombic lip.** The lip fuses with the adjacent outer surface of the alar lamina, covering in the tractus solitarius and spinal tract of V., which lay at first on the surface.

As in the spinal cord, the *motor nuclei* are developed in the basal lamina, and the *sensory nuclei* in the alar lamina (including the rhombic lip). The *hemisphere of cerebellum* also is derived from the alar lamina; the *vermis* is developed from cells of the alar lamina that migrate into the roof-plate. The *olivary nucleus, nuclei pontis, arcuate nuclei,* and *nucleus of circumolivary bundle* are derived from

cells of the alar lamina that migrate into the basal lamina. *Cerebellar peduncles* are formed in the alar lamina, in the latter half of intra-uterine life, by fibres that grow out of and into the cerebellum.

Mid-Brain.—Cavity becomes the *aqueduct. Corpora quadrigemina* are developed from the alar laminæ; *cerebral peduncles* in the basal laminæ. Floor is greatly thickened by intercrossing fibres.

Fore-Brain.—Cavity becomes the *third ventricle.* Floor is slightly thickened by intercrossing fibres. Roof remains as the ependymal *roof of the third ventricle.* Anterior wall persists as the *lamina terminalis.* Basal lamina becomes the parts in the floor of the third ventricle. Alar lamina develops into the parts in its side-wall.

From the basal part there grow out a pair of hollow protrusions which become the *optic nerves* and *retinæ.* From the alar parts, anteriorly, there grows a hollow bud which at once divides into two to form the *cerebral hemispheres.* Cavity in each becomes a *lateral ventricle.* Communications with the original cavity are retained as the *interventricular foramina.*

Each hemisphere grows both forwards and upwards and backwards. In its growth backwards it buries the upper and lateral surfaces of the thalamus and fuses with them. The part of the wall of the hemisphere that covers the upper surface of the thalamus remains ependymal, and the thalamus is seen through it in the floor of the lateral ventricle of the adult brain.

Inferior horn is the original posterior end of the lateral ventricle. The part of the hemisphere that encloses it turns round the thalamus and grows forwards as the temporal lobe. Its medial wall remains ependymal; in an adult, an instrument can therefore be passed into the inferior horn through the choroidal fissure after the pia has been taken away, for the invaginated ependymal wall is torn away with the pia. Posterior horn is a later diverticulum, and it is wholly surrounded by fibres from the corpus callosum.

Corpus striatum is developed as a thickening in the floor and lateral wall of the hemisphere. Fibres growing down from the cortex and up to the cortex divide it into *caudate* and *lentiform nuclei.*

Optic chiasma is formed by fibres intercrossing in the lower part of the lamina terminalis.

Upper part of the lamina terminalis thickens. Lower part of the thickening becomes partly isolated and fibres grow into it to form the *anterior commisure.*

Upper part of the thickening grows upwards and backwards with the hemispheres. Transverse fibres grow into its upper part to form the *corpus callosum.* Longitudinal fibres that connect the mamillary body with the hippocampus grow into the lower part and form the *fornix.* The part of the thickening between the corpus callosum and fornix becomes stretched to form the *septum lucidum,* and acquires a cavity.

As the thickening grows backwards and becomes invaded by the corpus callosum and fornix, it carries pia mater with it on both surfaces. The layer of pia on the inferior surface together with the layer already present on the roof of the third ventricle, forms the *tela chorioidea* of the third ventricle. *Choroid plexuses* are formed in it and bulge into the lateral ventricles, pushing their ependymal

medial walls before them. Inferior horn carries a prolongation of a plexus with it.

Insula is the part of the cortex in relation to the corpus striatum, and it is visible on the surface of the hemisphere up to the fifth month of intra-uterine life. Surrounding parts of the cortex begin to grow more rapidly and overlap the insula, so that it lies in a fossa ; and these overlapping parts finally cover the insula and form the *operc ula*. Opercula growing over insula from different points produce the stem and rami of the *lateral sulcus* and are kept apart by them.

Hypophysis cerebri is derived—(1) from the neural ectoderm and (2) from the surface-ectoderm that lines the stomodæum. The *posterior lobe* is a downgrowth from the fore-brain at the part which becomes the infundibular recess in the adult. The *anterior lobe* is developed from a recess formed in the roof of the stomodæum immediately in front of the dorsal attachment of the bucco-pharyngeal membrane. The recess extends upwards through the mesoderm that becomes the body of the sphenoid bone, and it is cut off from the naso-pharynx by the developing sphenoid.

FORMATION OF SENSE-ORGANS

Olfactory Apparatus.—Depressions called *olfactory pits* appear in the roof of the stomodæum underneath the fore-brain. A part of the ectoderm of the olfactory pit is separated to form part of the olfactory bulb. The rest forms the olfactory epithelium of the nose ; and processes grow from its cells into the olfactory bulb and become the *olfactory nerves*.

A ridge appears on the lower surface of cerebral hemisphere ; there is a corresponding depression inside the ventricle. The anterior part of this becomes separated as a hollow outgrowth which solidifies and becomes the *olfactory bulb*, *tract* and *pyramid*. The posterior part becomes the *roots* of the olfactory tract, *anterior perforated substance*, *paraterminal gyrus* and *uncus*.

Eye.—**Optic vesicles** grow out from the lower and anterior part of the fore-brain—from the region occupied by the adult *optic recess*. The vesicle becomes the *retina*.

The stalk of the optic vesicle elongates and, acquiring nerve-fibres that come from and go to the retina, becomes solid and forms the *optic nerve*. As development proceeds, the fibres pass farther back and become connected with the thalamus and the mid-brain. Some cross and form the *optic chiasma*, which is found only in the highest primates and is associated with binocular vision.

Simultaneously with the appearance of the lens, the infero-lateral wall of the vesicle and the distal part of the optic stalk become invaginated and form the *optic cup*. The optic cup has therefore two layers. The inner becomes the nervous and supporting layers of the retina and the pars ciliaris retinæ ; the outer becomes the pigmented layer. Pigmented cells at the back of the iris are derived from both layers.

Pathological separation of retina (" detachment of retina ") sometimes takes place between these two layers and fluid collects in the original cavity of the vesicle.

Vitreous is formed by modified cells of the retina which correspond to neuroglia. Blood-vessels grow in between the lens and the retina and carry with them a few mesodermic cells to the vitreous. The fissure produced by the invagination of the stalk closes up, so that the *arteria retinæ centralis*, derived from these blood-vessels, occupies the centre of the optic nerve, and its point of entrance marks the posterior limit of the invagination.

The ectoderm that overlies the optic vesicle becomes depressed to form a cup, and is then cut off as a closed sac of a single layer which forms the rudiment of the *lens*; it becomes separated from the surface-ectoderm by growth of mesoderm. It grows into the optic cup. Its posterior cells elongate and obliterate its cavity and form the *lens-fibres*. Its anterior cells remain as the *anterior epithelium of lens*. New lens-fibres are added at the margins by cells multiplying and elongating.

With age, the cells become changed into keratin, just as in the skin. Oldest cells keratinise first. They are in the centre; hence the central position of cataract.

Capsule of lens is formed by cells of the lens, not from mesoderm.

Lens becomes enveloped in a vascular tissue which, in man, disappears before birth. The anterior part of this vascular envelope is called the *pupillary membrane.*

Condensed mesoderm around the optic cup forms the *sclera, choroid, iris and ciliary body.*

A cleft appears in the mesoderm in front of the lens. That cleft becomes the *anterior chamber of eye.* Mesoderm behind it becomes the pupillary membrane. *Cornea* is formed from mesoderm in front of the cleft and from the surface-ectoderm. It becomes transparent.

Evelids are duplications or folds of ectoderm formed above and below the cornea, and they contain mesoderm. They grow towards each other and their edges fuse together during the third month. They separate about the end of the sixth month; but in some animals, *e.g.*, cats, they do not separate till some days after birth.

Internal Ear.—The ectoderm above the first pharyngeal groove opposite the hind-brain, becomes depressed, invaginated, and cut off to form the **otic vesicle,** which sinks into the subjacent mesoderm, is met by the outgrowing auditory nerve, and develops into the *membranous labyrinth.* The cartilaginous periotic capsule (p. 714) is developed in the mesoderm around it.

FORMATION OF SKELETON

Vertebral Column, Ribs, and Sternum

Portions of the mesodermic somites grow medially, surround the notochord and neural tube, and become condensed to form a **membranous vertebral column.** Vertebræ are formed in this, opposite the intersegmental septa, *i.e.* opposite the intervals between the somites; hence, each vertebra belongs to two somites. Vertebræ, like most other bones, pass through a pro-cartilage and a cartilage stage before ossification. The parts of a **pro-cartilage vertebra** are a *body* or

centrum and a horseshoe-shaped *vertebral bow*, which encloses the centrum.

Chondrification begins about the fourth week and a **cartilaginous vertebral column** is formed. Centrum becomes the main part of the body of a cartilaginous vertebra. The limbs of the bow become the vertebral arch and the postero-lateral parts of the vertebral body; and transverse processes and spine grow from the arch into the intersegmental septum. The ventral or median part of the bow disappears, except in the atlas, where it chondrifies and forms the anterior arch.

Ossification begins about the seventh week in the arches and about the tenth week in the bodies; and the **bony vertebral column** is formed.

Atlas vertebra is a completed vertebral bow. Centrum becomes the odontoid process; lateral mass represents the part of the body of a typical vertebra formed from the vertebral bow.

Ligaments of odontoid process represent the disc between the atlas and the last occipital segment.

The imperfect condition of the *coccygeal vertebræ* is owing to the failure of the limbs of the vertebral bow to chondrify and ossify.

The *laminæ of the last two sacral vertebræ* are incomplete, owing to imperfect chondrification and ossification.

Ribs are formed in the intersegmental septa. They articulate at first with only one vertebra; but, later, the heads of all, except 1st, 10th, 11th, 12th, are shifted so that each articulates with the disc and the vertebra above as well.

Sternum is formed in mesoderm in front of the pericardium. Manubrium arises in association with the ventral part of the shoulder-girdle; it sends downwards a pair of *sternal bars*, which fuse to form the body and the xiphoid process.

Skull

Brain is surrounded by a **membranous capsule** continuous with that which surrounds the spinal cord and notochord.

Chondrification begins in the base, but ossification of the membranous capsule begins in the calvaria before the chondrifying process has extended so far.

Bones formed in membrane are the *frontal*, *parietals*, *squamous temporals*, *greater wings of sphenoid* (except their roots) and *occipital above the nuchal lines*. Centres appear for these about the seventh week. Eminences of the frontal and parietal bones are produced owing to their greater convexity when bone is first formed—the sphere of the skull at the time having a small radius.

Fontanelles are unossified spaces at the angles of the parietal. They are closed at birth, or shortly after, except the anterior—the largest—which closes at the end of the second year.

Sutural bones are formed by small ossific centres which sometimes appear at the smaller fontanelles and help to close them.

Sagittal fontanelle is an unossified space in the region of the parietal foramen. If it is unclosed at birth the parietal foramen will be large in the adult skull.

In the hinder part of the base of the skull, a **basi-cranial plate** of cartilage partly encloses the notochord.

Anteriorly, the basi-cranial plate forms the *basi-occipital, posterior part of body of sphenoid* and *dorsum sellæ*.

Posteriorly, the plate extends sidewards to form the *condylar part of occipital bone*, from which expansions grow backwards, meet over the hind-brain, enclose the foramen magnum and form the *squamous part of occipital below superior nuchal line*. Fusion between this pair of expansions, behind the foramen magnum, is not complete till shortly after birth. The space between them is called the *occipital fontanelle*. It is filled by an extension of atlanto-occipital membrane. It is the commonest site for cerebral meningocele.

Periotic capsule is a mass of cartilage that surrounds the membraneous labyrinth and interior carotid artery. It forms :—

1. The *petro-mastoid* part of the temporal bone.
2. The cartilage of the *pharyngo-tympanic tube.*
3. The cartilage which fills the lower part of the foramen lacerum.

Tympanic plate is developed in the membrane that overlies the periotic capsule.

Ethmoidal plate of cartilage lies in front of the notochord. Posteriorly it joins the basi-cranial plate.

The ethmoidal plate forms the *cribiform plate of ethmoid* and the *anterior part of body of sphenoid.*

The plate is cleft by the *cranio-pharyngeal canal*—an opening through which a diverticulum from the stomodæal ectoderm passes to form the anterior lobe of the hypophysis.

A process from the ethmoidal plate grows down into the median nasal process. Part of that remains as the *septal cartilage of nose* ; part is ossified into the *perpendicular lamina of ethmoid* ; *vomer* arises in the membrane that covers the posterior part.

Processes grow out from the ethmoidal plate, on each side, to form the root of the *greater wing of sphenoid* and *lateral pterygoid plate, lesser wing of sphenoid, labyrinth of ethmoid*, and *cartilages of the side of the nose.*

Nasal and *lacrimal* bones and part of the *frontal process of maxilla* are formed in the membrane that covers the part of the process of the ethmoidal plate which forms the cartilages of the nose.

Zygomatic bone and arch, *maxilla, palatine* bone, and *medial pterygoid plate* are formed from the membrane that covers the cartilage in the maxillary process.

Union of Bones of Skull, and Growth of Skull.—Plates of *cartilage* unite the body of sphenoid with the basi-occiput and with the ethmoid, and the jugular process of the occipital bone with the petrous temporal. These cartilages are ossified at the 25th year.

Other bones of the skull are united by *sutures.*

Growth in the thickness of skull-bones takes place under the periosteum on their surfaces.

Increase of area (and therefore of the capacity of the cranial cavity) takes place partly at the cartilaginous joints but chiefly at the sutures. It is necessary therefore that the sutures should be

grouped in three planes: a horizontal, giving height; a coronal, giving length; a sagittal, giving breadth.

Metopic suture, between the halves of the frontal, is closed at the eighth year, except at its lower end. Other sutures persist till after maturity. They begin to be obliterated before middle age and are completely obliterated in old age.

Foramina of the skull are situated in the sutures between the bones or between the elements of which a bone is made up.

Growth of Face.—At birth the face forms only about *one-eighth* of the size of the head, owing to the small size of the jaws, nasal cavities, and air-sinuses. Increase takes place owing to the development of temporary teeth, and, still more, to the development of permanent teeth; to enlargement of the nasal cavities and the air-sinuses connected with them—especially the maxillary sinus; till, at maturity, the face forms *one-half* of the skull. Growth is greatly accelerated after the seventh year.

Limbs

Limbs grow out, as buds, from the sides of the body at the end of the third week. Each bud originates from several segments, and these segments correspond to the spinal nerves whose anterior primary rami send branches into the limb.

During the fifth week, constrictions mark off the *hand* and *foot*, and then the *forearm* and *leg*. *Shoulder* and *hip* remain buried in the body-wall. Grooves that mark off the *digits* appear at the seventh week.

Nails begin to appear at the third month and reach the ends of the digits at the beginning of the seventh month.

The extensor surface of a limb looks laterally; the flexor surface looks medially. The border which looks towards the head is called **pre-axial**; that which looks tailwards is called **post-axial**.

During the third month the limbs begin to be rotated in opposite directions, so that:—

1. The pre-axial border of the upper limb becomes lateral, and the extensor surface becomes posterior (when the forearm is supine).
2. The pre-axial border of the lower limb becomes medial and the extensor surface becomes anterior (but the rotation of the lower limb is not completed till after birth).

The limb-girdles probably share in the rotation.

Central mesoderm in each limb condenses to form a **pro-cartilage skeleton**, which chondrifies in the fifth week—except where joints are to be formed—and a **cartilaginous skeleton** is produced. Ossification in the large bones begins during the seventh and eighth weeks.

Where a **joint** is formed, the periphery of the central, condensed mesoderm becomes the *capsular ligament* of the **capsule**; the internal part, to a large extent, disappears and the *joint-cavity* is formed; but a part remains as the *synovial membrane*; and sometimes part is retained as *intra-articular discs* and *ligaments*.

INDEX

Abdomen, 359, 627
Acetabulum, 93
Acromion, 76
" Adam's apple ", 593
Adenoids, 622
Aditus ad antrum, 585, 587
Adrenin, 674
Agger nasi, 592
Allantois, 681, 687
Alveolus, 4
Alveus, 486
Amnion, 680, 686, **687**
Amphiarthrosis, 116
Anastomosis around elbow, 210
  around scapula, 178
  cruciate, 227
Angle, sacro-vertebral, 15
Annulus ovalis, **411**, 454, 704
Ansa hypoglossi, 298, 346
  lenticularis, 504
  peduncularis, 504
  subclavia, 347, 577
Antrum, 4
  pyloric, 629
  tympanic, 36, **587**, 685, 691
Aorta, 423
  abdominal, 433
  arch, 424, **603**, 701
  ascending, 424, 704
  descending, 433, **607**, 701
  primitive, 700, 701
Aponeurosis, 161
  epicranial, 259
  palatine, 617
  palmar, 195
  plantar, 251
Appendices epiploicæ, 636
  testis, 663, 697
  vesiculosæ, 669, 697
Appendix, vermiform, 634, 695
Aqueduct of cochlea, 590
  of midbrain, 508, 710
  of vestibule, 47, 589
Arachnoid, 287, 288, 540, 685
Arbor vitæ, 515, 671
Arches and **Arcus**—
  of aorta. *See* **Aorta**
  carpal, 191, 210
  of foot, 159
  hyoid, 691
  jugular, 291
  mandibular, 689, 691
  palato-glossal, 617
  palato-pharyngeal, 622
  palmar, 197, 201
  parieto-occipitalis, 471
  pharyngeal, 691, 692
  plantar, 256, 440
  pubic, 92, 96
  superciliary, 35
  tendineus, 385
  thyro-hyoid, 692
  venous, dorsal, 203, 238, 449
  zygomatic, 36
Area, bucco-pharyngeal, 684
  of cardiac dullness, 410
  cortical, 472, 474, **482**, 483
    See also **Centres**
  embryonic, 681
  postrema, 540
  striata, 475
  vestibular, 539, 540

Arteries, 423, 700
acetabular, 235
acromio-thoracic, 168, 432
aorta. *See* **Aorta**
appendicular, 438
arcuate, 242
ascending cervical, 334
auditory, internal, 430
auricular, 262, 301, **338**, 426
axillary, **166**, 432, 703
basilar, 430
brachial, **182**, 432, 703
bronchial, 608, 702
buccal, 427
of bulb, 403
calcanean, 250, 251, 255
carotico-tympanic, 428
carotid, common, **334**, 425, 604, 701
external, 301, **337**, 425, 701
internal, 57, 336, 428, 701
carpal, 190, 191, 210
cerebellar, 430
cerebral, 429, 430
of cerebral hæmorrhage, 496
choroid, 429, 430
ciliary, 68, 69
circumflex femoral, 221, 227, 235
fibular, 250
humeral, 168, **178**, 432
iliac, 211, 360, 371
scapular, 178, 432
coccygeal, 227
cœliac, 435, 702
colic, 437, 438
communicating, 428, 429
coronary, 416, 417
cremasteric, 371
crico-thyroid, 338
cystic, 437
deep cervical, 282
of clitoris or penis, 403
dental, 306, 427
descending scapular, 273
digital, of foot, 243, 255, 256
of hand, 198, 210
Arteries (*contd.*)—
dorsalis clitoridis, 403
indicis, 209
linguæ, 319
nasi, 69
pedis, **242**, 256, 441
penis, 403
pollicis, 209
duodenal, 437
epigastric, 211, 356, 360, **370**, 702
ethmoidal, 69
facial, 267, 318, 426
femoral, **219**, 440, 703
gastric, 435, 436
gastro-duodenal, 436
gastro-epiploic, 436
genicular, 220, **231**
gluteal, 225, 226, 391, 392, 703
hepatic, 370, 436
ileo-colic, 437
iliac, 390, 438, 439, 700, 703
ilio-lumbar, 377
infrahyoid, 338
infra-orbital, 427
innominate, 295, **330**, 424, **604**, 701
intercostal, 334, 356
interosseous, **191**, 209, 703
labial, of perineum, 401
lacrimal, 68
laryngeal, 334, 338
lingual, **318**, 425, 427
lumbar, 376, 434
malleolar, 242
mammary, internal, 333, **355**, 703
maxillary, 306, 426
mediastinal, 355, 608
meningeal, **55**, 56, 57, 62, 69, **306**, 427, 430
mental, 427
mesenteric, 437, 438, 702
metacarpal, 202, 210
metatarsal, 243, 256
musculo-articular, 220

Arteries (*contd.*)—
musculo-phrenic, 356, 370
mylo-hyoid, 427
obturator, 235, 391
abnormal, 370, 392
occipital, 262, 281, 298, 426
ophthalmic, 68
ovarian, 390, **435**, 702
palatine, **318**, 337, **427**, 428
palpebral, 69
pancreatico - duodenal, 436, 437
pericardiaco-phrenic, 355
peroneal, 250, 703
petrosal, 55
pharyngeal, **337**, 425, 428
phrenic, 434, 608
plantar, 255, 440
popliteal, **230**, 440, 703
princeps pollicis, 201
of pterygoid canal, 428
pubic, 370, 392
pudendal, external, 211, 220, 360
internal, 227, 392, **402**
pulmonary, 423, 702
radial, 189, 201, 209, 433
radialis indicis, 201
rectal, 390, 392, 403, 438
renal, 434, 702
retinæ centralis, **68**, 582, 712
of round ligament, 371
sacral, 390, 391, 701
saphenous, 220
sciatic, 227
scrotal, 397
somatic, 702
spheno-palatine, 428
spinal, 287, 357, 377, 430, 545
splanchnic, 700, 702
splenic, 436
sterno-mastoid, 298, 338
striate, 429, 494
stylo-mastoid, 338
subclavian, 273, 330, 431, 604, 720, 703
Arteries (*contd.*)—
subcostal, 357, 376
sublingual, 319
submental, 318
subscapular, 168, 432
suprahyoid, 319
supra-orbital, 69, 261
suprarenal, 434, 702
suprascapular, 177, 274, 333
supratrochlear, 69, 183, 261
tarsal, 242
temporal, 261, 262, 303, 426, 427
testicular, 435, 702
thoracic, 168, 432
thyreoidea ima, 330
thyroid, 333, 338, 425
tibial, 242, 250, 440, 441
tonsillar, 318
transverse cervical, 173, **274**, 333
facial, 267
perineal, 397, 401
tympanic, 55, 337, 426
ulnar, **190**, 197, 433
umbilical, **391**, 452, 454, 700
uterine, 392
vaginal, 392
of vas deferens, 392
vertebral, 281, 332, 429, 703
vesical, 391, 392
vitelline. *See* **A.**, splanchnic
zygomatic, 262
Asterion, 35
Atlas, 7, 17, 713
Auricle (of ear), 260, 583
Axilla, 166
Axis vertebra, 8, 17

Back of trunk, 171, 278
Band, diagonal, 485
moderator, 413
Basis pedunculi, 467, **508**, 511
Bladder, urinary, **658**, 685, 696
Bodies—
ano-coccygeal, 383
aortic, 679

Bodies (*contd.*)—
carotid, 679
geniculate, 502
mamillary, 468, **505**
perineal, 383, 400
pineal, 504, 685
post- or ultimo-branchial, 692
Bow, vertebral, 713
Brachia quadrigemina, 503, **507**, 510
Bregma, 38
Bronchi, **598**, 685, 691
Bulb, olfactory, **484**, 689, 711
of spinal marrow, 520
of vestibule, 400
Bulbus cordis, 700, 703
Bulla ethmoidalis, 72, 592
Bundles. *See also* **Tracts** and **Fasciculi**—
atrio-ventricular, 416
circumolivary, 527
medial longitudinal, 508, 520, **530**
pyramidal, 518, 548
Bursa, pharyngeal, 622
Bursæ, synovial, 162

Cæcum, 634, 694
Canaliculi—
of chorda tympani, 585, 586
cochlear, 48
lacrimal, 269
mastoid, 43
tympanic, 43
Canals—
alimentary, 621, 682, 685
anal, **638**, 695
carotid, 43, 45
condylar, 41
cranio-pharyngeal, 714
femoral, 219
hyaloid, 582
incisive, 73
infra-orbital, 65
inguinal, 367
naso-lacrimal, 65
palatine, 37
Canals (*contd.*)—
palatino-vaginal, **37**
pterygoid, 37, 40
pudendal, 395
sacral, 13, 14, **381**
semicircular, 589
spiral, 590
subsartorial, **217**
of tensor tympani, 42
urogenital, 696
vertebral, 6, **286**
Capsules of cerebrum, 495
periotic, 712, 714
Carpus, 85, 193
Cartilage, costal, 24
aortic, 415
of larynx, 593, 693
Meckel's, 692
of nose, 268, **591**, 690, 714
semilunar, 150
triticea, 594
Caruncle, lacrimal, 269
Carunculæ hymenales, 672
Cataract, 712
Cauda equina, 290
Cavity, glenoid, 75
Cavum trigeminale, 59
Cell-mass, inner, 680
Cell-tract, intermediate, 684, 685
Cells, giant, 675
air-, mastoid, 587, 685
Centres. *See also* **Area**
cardiac, 527
hearing, 473, 476, 483, 507
motor, 472, 482
respiratory, 527
sensory, 474, 483
sight, 474, **479**, 483, 507
smell and taste, 482, 484
speech, 472
vasomotor, 527
vomiting, 527
Centrum of vertebra, 16, 713
Cerebellum, 513, 709
Cerebrum, 469, 710
Cerumen, 584

Cheeks, 615, 689
Chiasma, optic, **468**, 710, 711
Chorion, 686, 688
Choroid, 581, 712
Chromaffin, 674, 685
Cingulum, 499
Circulation, fœtal, 451
Circulus arteriosus, 431
Cisterna chyli, 378, 455
Cisterns, subarachnoid, 541
Claustrum, 495
Clavicle, 73
Cleft palate, 689
Clitoris, 398, 696
Clivus of skull, 46
Cloaca, 695
Coccyx, 15, 18, 713
Cochlea, 589
Cœlom, 681, 684, 685, 698
Colliculus facialis, 539, 540
Colon, 635, 636, 695
Column, vertebral, 5, 15, 120, 685, 713
Commissures *of brain*—
  anterior, 498, 710
  habenular, 505
  hippocampal, 489
  posterior, 477, 504
Conchæ, nasal, 30, 72, 690
  sphenoidal, 29
Conduction of light, 513
  motor, 547
  sensory, 550
  of sound, 536
Confluence of sinuses, 52
Conjunctiva, 66, 269, 685
Connexus, interthalamic, 500
Conus medullaris, 545
Cord, oblique, 136
  spermatic, 664
  spinal, 289, **542**, 709
  umbilical, 452, 686, **687**
Cornea, 66, 268, **581**, 685, 712
Corona radiata, 487, 497
Corpora. *See also* **Bodies**
  callosum, 486, 710
  of clitoris, 398
Corpora (*contd.*)—
  of penis, 666
  quadrigemina, 507, 509, 510, 710
  striatum, 493, 710
  trapezoideum, 519
Corpuscles, concentric, 676, 686
  lamellated, 198
Crests—
  frontal, 44, 48
  infratemporal, 36, **40**
  infundibulo-ventricular, 414
  neural, 683
  obturator, 93
  occipital, 38, 47
  supinator, 81
  supramastoid, 36
Crista galli, 30, 43
  terminalis, 411, 704
Cuneus, 479
Cup, optic, 711

Decidua, 686
Decussation of lemnisci, 525
  of pyramids, 466, 521
Deglutition, 625
Descent of testis, 698
Detachment of retina, 711
Diaphragma sellæ, 51
Diaphysis, 3
Diarthrosis, 117
Diploë, 2
Disc, optic, 582
Discs, intervertebral, 119, 685
  intra-articular, 117, 715
Diverticulum ilei, 633, 694
Dorsum sellæ, 44, 714
Ducts, Ductules and **Ductus**—
  aberrant, 693, 697
  arteriosus, 452, 454, 702
  bile, 644, 694
  of Cuvier, 699, 706, 707
  cystic, 644
  ejaculatory, 665, 697
  endolymphatic, 590
  hepatic, 644
  lymphatic, right, 340

Duct, Ductules and **Ductus** (*contd.*)—
mesonephric, 696
naso-lacrimal, 271, **592**, 685, 689
para-mesonephric, 697
para-urethral, 660
re-uniens, 590
semicircular, 590
thoracic, 340, **455**, 607, 610
thyro-glossal, 691
utriculo-saccular, 590
venosus, 452, 454, **706**
vitello-intestinal, 687
Duodenum, 631, 693
Dura mater, 49, 287, 288, 685

Ear, 583, 683, 685, 712
Ectoderm, 680, 685
Elevation, tubal, 588, 621
Eminence, arcuate, 46
canine, 35
collateral, 491
frontal, 27, **34**, 713
genital, 696
hypothenar, 193
ilio-pubic, 91
parietal, 27, **35**, 713
thenar, 193
Eminentia medialis, 540
Endocardium, 416
Endocranium, 49
Endocrine, 673
Endolymph, 590
Endosteum, 3
Entoderm, 680, 686
Ependyma, **464**, 685, 707
Epicardium, 415, 420
Epididymis, 662, 697
Epiglottis, 594, 690
Epiphyses, 3
Epithelium, germinal, 697
Ep-oöphoron, 669, 697
Erythroblasts, 675
Ethmoid, **30**, 689, 714
Eversion, 118, **159**
Expansion, extensor, 206, 240
Eyeball, 66, **581**, 711
Eyelids, **269**, 712

Face, **263**, 715
Falx cerebelli, 50
cerebri, 49, 708
Fascia, 161
bucco-pharyngeal, 263, 324
cervical, 272, 291, **323**
clavi-pectoral, 165
cremasteric, 365
cribriform, 213
iliaca, 361, **374**
lata, 212
lumbar, 278, 374
obturator, 382
palpebral, 269
parotid, 263, 299
pharyngo-basilar, 625
phrenico-pleural, 601
pretracheal, **292**, 324
prevertebral, 324
spermatic, 361, 364
temporal, 303
transversalis, 361
Fasciculi. *See also* **Bundle, Fibres** and **Tract**—
cuneatus, 522, 546, 552
fronto-occipital, 499
gracilis, 522, 546, 552
longitudinal, 499
mamillo-thalamic, 506
pallido-rubro-olivary, 526, 528
retroflexus, 505
of spinal medulla, 545 *et seq.*
thalamo-temporal, 497
uncinatus, 476, **499**
Femur, 98
Fenestræ, 36, **586**
Fertilisation, 680
Fibres. *See also* **Tract**—
arcuate, 521, 524, 528, 553
association, 498
commissural, 498
cortico-pontine, 496, 519
intercrural, 367
itinerant, 497

Fibres (*contd.*)—
olivo-spinal, 526
ponto-spinal, 526
pyramidal, 547
Fibula, 106
Filum terminale, 288
Fimbria hippocampi, 488
Fissures. *See also* **Sulci**
choroid, 492
for lig. teres, 640
for lig. venosum, 641
orbital, 46, 64, 65
petro-squamous, 42
petro-tympanic, 42
pterygoid, 29, 39
pterygo-maxillary, 37
squamo-tmypanic, 42
transverse, of cerebrum, 492
tympano-mastoid, 36
Flexures of brain, 709
duodeno-jejunal, 632
Flocculus, 467, **515**
Fluid, amniotic, 687
cerebro-spinal, 288, 464, **541**
subarachnoid, 288, 541
Folds—
alar, 151
ary-epiglottic, 596, 691
of epigastric artery, 649
fimbriated, 618
gastro-pancreatic, 649
glosso-epiglottic, 594
ileo-cæcal, 637
interarytenoid, 596
labio-scrotal, 696
of left vena cava, **421**, 706
malleolar, 587
neural, 682
pharyngo-epiglottic, 594
recto-uterine, 385, 649
sacro-genital, 649
salpingo-pharyngeal, 621
sublingual, 616
synovial, 117
umbilical, 649
vascular, of cæcum, 637
vestibular, 596
Folds (*contd.*)—
vocal, 596
Folia linguæ, 619
Follicles, hair, 685
ovarian, 697
Fontanelles, 35, 38, 713, 714
Foramina—
anterior abdominal, 365
cæcum of skull, 44
of tongue, 618, 691
dental, 37
ethmoidal, 44, **64**
incisive, 39
infra-orbital, 35, 65
interventricular, 477, **490**, 710
intervertebral, 6, **290**
jugular, 43
lacerum, 41, **45**
magnum, 41
mastoid, **38**, 47
mental, 32
nutrient, 3
obturator, 93
olfactory, 44, 73
optic, 44, 64
ovale of heart, **452**, 454, 704
ovale of skull, **40**, 46
palatine, 38, 39
parietal, 38, 713
rotundum, 37, 46
sacral, 13, 14, **882**
sciatic, 92, **143**
sphenoidal emissary, 40
spheno-palatine, 37, 73
spinosum, **40**, 46
stylo-mastoid, 43
supra-orbital, 34
zygomatic, 35, 36, 65
Forceps major and minor, 486
Fore-brain, 710
Fore-gut, 682, 692
Fornix cerebri, 488, 710
Fossa, 5
canine, 35
cerebellar, 47
cloacal, 695
condylar, 41

Fossa (*contd.*)—
coronoid, 78
cranial, 43, **56**
cubital, 184
digastric, 32
hyaloid, 582
hypophyseal, 44
incisive, 39
incisor, 32
incudis, 585
infratemporal, 37, **305**
interpeduncular, 468
intrabulbar, 661
ischio-rectal, 394
jugular, 43
lacrimal, 64
malleolar, 107
olecranon, 78
ovalis, 411, 454
paraduodenal, 451
piriform, 596, 692
popliteal, 229
pterygoid, 29
pterygo-palatine, 37
radial, 78
scaphoid, 40
subarcuate, 47
sublingual, 32
submandibular, 32
subnasal, 35
supinator, 81
temporal, 36, 302
terminal, 661
trochlear, 64
urogenital, 695
vestibular, 399
Fovea, 5
centralis, 582
of fourth ventricle, 539, 540, 709
Frenulum veli, 516
Frontal bone, 27, 713
Funiculus separans, 540
Furcula, 691, 693

Gall-bladder, **644**, 685, 694
Gamete, 680
Ganglia, 461
cardiac, 579
ciliary, **71**, 577
cœliac, 580
impar, 577
otic, 309
spheno-palatine, 311
spinal, 289, 290
spiral, 536
submandibular, 320
sympathetic, 346, 379, 386, 577, 578, 579
trigeminal, 59
Glabella, 35
Glands—
buccal, 268, 615
bulbo-urethral, **396**, 686, 696
ceruminous, **584**, 685
ciliary, **270**, 685
labial, 268, 615
lacrimal, **71**, 271, 685
mammary, **163**, 685
molar, 268, 615
parathyroid, **325**, 677, 691
parotid, **299**, 620, 685
sublingual, **317**, 621, 685
submandibular, **316**, 620, 685
suprarenal, 678
tarsal, **270**, 685
thyroid, **324**, 677, 686, 691
vestibular, **401**, 686, 696
Glia, 462
Globus pallidus, 493
Glomus coccygeum, 390, 679
Grooves. *See also* **Sulcus**—
basilar, 467
bicipital, 78
carotid, 45
for glosso-pharyngeal, 47
infra-orbital, 65
lacrimal, 65
for meningeal artery, 46
mylo-hyoid, 32
neural, 682
obturator, 93
for occipital artery, 43
optic, 44

Grooves (*contd.*)—
for petrosal nerves, 46
for petrosal sinus, 47
pharyngeal, 691
for pharyngo-tympanic tube, 42
for sigmoid sinus, 47
spiral, 79
for sup. sagittal sinus, 48
for transverse sinus, 47
Growth of face and skull, 714
Gubernaculum, 698
Gums, **620**, 685
Gut, post-anal, 695
Gyri, 464; 472-485; 711

Habenula, 504
Hæmorrhage, cerebral, 496
post-partum, 689
Hare-lip, 690
Heart, **405**, 685, 700, 703
Helicotrema, 590
Hernia, 219, 367
Hiatus semilunaris, 72, 592
Hind-brain, 462, 709
Hind-gut, 682, 694
Hip-bone, 90
Hippocampus, 486, 491
Humerus, 77
Humor, aqueous, 583
Hymen, 399, 672
Hyoid bone, 33, 693
Hypophysis, 56, 685, 711

Ileum, 633, 694
Ilium, 90
Impression, petrous, 480
trigeminal, 46
Impulses, motor, 547
sensory, 549
Incus, 588, 692
Indusium griseum, 485
Inion, 38
Inlet of thorax, 26, **328**
Insula, 474, **476**, 711
Intestine, 631, 634, 694
Inversion, 118, 159
Iris, 582, 712
Ischium, 91
Isthmus, oro-pharyngeal, 617
pharyngeal, 621, 622

Jejunum, 633, 694
Jelly, Wharton's, 688
Joints, 115, 715
of larynx, 595
of lower limb, 145
mandibular, 123
neuro-central, 17
of pelvis, 120, 142
of ribs, 125
of sternum, 18, 19, 125
of upper limb, 128
vertebral, 119
Jugum sphenoidale, 29, **44**

Kidney, 654, 696
Kneeling posture, 103

Labia pudendi, 398, 696
Labrum, 77, 117, 131, 145
Lacrimal bone, 30, 714
Lacunæ, 52, 661
Lacus lacrimalis, 269
Lambda, 38
Lamella, costo-transverse, 7
Laminæ, 5
alar and basal, 709
nasal, 690
terminalis, 468, **505**, 710
Larynx, **593**, 691, 693
Lemniscus, 508, 519, 524, **553**
Lens, 583, 685, 712
Ligaments—
alar, 122, 713
annular, 134, 588
apical, 121, 713
arcuate, 151, **372**
arteriosum, **423**, 454, 702
bifurcated, 158
broad, 649
capsular, 117, 715

Ligaments (*contd.*)—
check, 67
conoid, 130
coronary, **642**, 694
cruciate, 121, 149
deltoid, 155
denticulatum, 288, 290
falciform, **642**, 694, 698
flava, 120
gastro-phrenic, 629, 648
gastro-splenic, 629, 648, 693
hepato-colic, 649
hyo-epiglottic, 594
ilio-lumbar, 142
infundibulo-pelvic, 649
inguinal, 213, **382**
intra-articular, 117, 715
of left vena cava, 421
lieno-renal, 648, 693
lumbo-costal, 126
lumbo-sacral, 120
nuchæ, 121, **279**
of ovary, 671, 698
patellæ, 149
pectinate, 581
pectineal, 364
phrenico-colic, 636, **648**
pterygo-mandibular, 125
pterygo-spinous, 125
pubo-prostatic, 385
pubo-vesical, 385
pulmonary, 600
quadrate, 135
radiate, 126, 127
of ribs, 126, 129
round, **642**, **671**, 698, 706
sacral, 120, 142, 143
spheno-mandibular, **125**, 306, 692
spino-glenoid, 131
spring, 157
sterno-pericardial, 421
stylo-hyoid, 125, **316**, 692
stylo-mandibular, 125, 299
suspensory, 67, 398, 583, 667
sutural, 49
teres. *See* **L.**, round
Ligaments (*contd.*)—
transverse, of foot, 251, 252
of hand, 141, 194, 196
of perineum, 396, 400
trapezoid, 130
triangular, 642, 694
umbilical, 391, 658, 700
utero-sacral, 385
venosum, 642, 706
vestibular and vocal, 596
Light, conduction of, 513
Limen insulæ, **476**
Lineæ and **Lines**—
alba, 361
arcuate, 91, 96; 366
epiphyseal, 3
gluteal, 91
median, of neck, 294
mylo-hyoid, 32
nuchal, 38
pectineal, 93
semilunaris, 359
soleal, 105
splendens, 288
temporal, 27, 34, **36**
Lips of mouth, 614, 689
rhombic, 709
Liquor amnii, 687
Liver, 454, **639**, 685, 693
Locus cœruleus, 540
Lung, 326, **610**, 686, 691
Lymphatic system, 455

Macula lutea, 582
Malleus, 588, 692
Mandible, 32, 692
Marrow of bones, 2, 674
Maxilla, 31, 692, 714
Meatus, 5
auditory, external, **584**, 691
internal, 47, 590
of nose, 72, 592
Mediastinum of thorax, 601
Medulla oblongata, 466, **520**, 709
Megalocytes, 675
Membranes—
of atlas, 122

Membranes (*contd.*)—
bucco-pharyngeal, 684
cloacal, 695
hyaloid, 582
intercostal, 350, 351
interosseous, 135, 154
mucous, 627
perineal, 395, 399
pupillary, 712
serous, 627, 698
suprapleural, 324
synovial, 117, 715
tectoria, 122
thyro-hyoid, 595
tympanic, 586, 691
Meningocele, 714
Mesenteries, 647, 648, 695
Mesocardium, 705
Mesoderm, 680; 683-685
Mesogastrium, 693, 694
Mesonephros, 696
Mesorchium, 697
Mesosalpinx, 650
Mesovarium, 650, 697
Metacarpus, 88
Metatarsus, 112
Mid-brain, 467, **506**, 710
Mid-gut, 682, 694
Modiolus, 589, 590
Morula, 680
Mouth, 614, 689
Muscles, 161
abductor digiti minimi, 197, 252
hallucis, 252
pollicis, 196, 207
adductor hallucis, 254
pollicis, 196
of thigh, 102, 233, 234
anconeus, 207
articularis genu, 216
auricular, 259
biceps, 180, 228
brachialis, 181
brachio-radialis, 205
buccinator, 265
bulbo-spongiosus, 402
Muscles (*contd.*)—
ciliary, 582
coccygeus, 383
constrictors, 293, 623, 624
coraco-brachialis, 180
corrugator cutis ani, 394
costalis, 283
cremaster, 365
dartos, 662
deltoid, 175
diaphragm, **371**, 693, 699
digastric, 313
dilatator pupillæ, 582
extensor carpi, 205, 206, 207
digiti minimi, 206
digitorum, 206
brevis, 240
longus, 239
hallucis, 240, 241
indicis, 208
pollicis, 207, 208
of face, 264
flexor accessorius, 253
carpi, 187, 202
digiti minimi, 197, 255
digitorum brevis, 252
longus, 248, 253
profundus, 188, 199
hallucis, 248, 253, 254
pollicis, 189, 196, 200
gastrocnemius, 247
gemelli, 224
genio-glossus, 315
genio-hyoid, 314
glutei, 223, 224
gracilis, 233
hyo-glossus, 315
iliacus, 216, **376**
ilio-costalis, 283
infraspinatus, 175
intercostal, 350
interossei, 202, 257
interspinales, 284
intertransverse, 284, 375
ischio-cavernosus, 402
of larynx, 597
latissimus dorsi, 172

Muscles (*contd.*)—
levator ani, 383
costæ, 280, 351
glandulæ thyreoideæ, 293
palati, 617
palpebræ superioris, 67, 270
scapulæ, 172
longissimus, 280, 283
longus capitis, 322
lumbricales, 200, 253
masseter, 299
multifidus, 284, 375
mylo-hyoid, 294, **314**
obliquus abdominis, 362, 365
capitis, 280
of eyeball, 67, 68
obturator, 224, 225, **234**, **382**
occipito-frontalis, 259
omo-hyoid, 173, 273, 293
opponens, 196, 197
orbicularis, 263, 264
palato-glossus, 618
palato-pharyngeus, 624
palmaris, 187, 194
papillary, 414, 415
pectinati, 411, 412
pectineus, 217
pectorales, 164, 165
peronei, 240, 241, 258
piriformis, 224, **382**
plantaris, 247
platysma, 162, **265**, 693
popliteus, 248
prevertebral, 322
pronator, 186, 189
psoas, 216, **375**, 376
pterygoid, 304
pyramidalis, 362
quadratus femoris, 215, 225
lumborum, 375
recto-urethral, 638
rectus abdominis, 362
capitis, 280, 322, 323
of eyeball, 67
femoris, 215
rhomboid, 173
rotatores 284

Muscles (*contd.*)—
sacro-spinalis, 280, 283
salpingo-pharyngeus, 625
sartorius, 214
scalene, 272, 321, 322
semimembranosus, 228
semispinalis, 280, 284
semitendinosus, 228
serrati, 165, 279
soleus, 247
sphincter ani, 394
pupillæ, 582
urethræ, 401
spinalis, 284
splenius, 271, **279**
stapedius, 589
sterno-costalis, 351
sterno-hyoid, 293
sterno-mastoid, 292
sterno-thyroid, 292
styloid, 314, 315, 321, 624
subanconeus, 181
subclavius, 165
subcostals, 351
subscapularis, 176
supinator, 207
supraspinatus, 175
suspensory, of duodenum, 632
temporal, 303
tensor fasciæ latæ, 214
palati, 304, 617
tympani, 588
teres, 175, 176
thyro-hyoid, 293
tibiales, 239 ; 249, 257
of tongue, 315, 618
transversus abdominis, 365
perinei, 402
thoracis, 351
trapezius, 171
triceps, 181
uvulæ, 617
vasti, 102, 215, 216
Myocardium, 416

Nails, 715
Nasal bone, 31, 714

Nasion, 34
Nerves, 461
abducent, 58, 61, 70, 532, **569**
accessory, **278**, 290, **344**, 534, 574
aortic, 354
auditory, 523, **535**
auricular, great, 261, **275**
posterior, 261
auriculo-temporal, 260, 308
buccal, 265, 267, 308
calcanean, 249, 251
cardiac, 344, 347, 418, 578, 607
carotico-tympanic, 342, 577, 585
carotid, 347, 577, 578
cervical, 275, 285, 347, 555
chorda tympani, **309**, 571
ciliary, 71
circumflex, 170, **177**, 560
coccygeal, 387
cochlear, 523, 536
cranial, 511, 518, 523, 568
cutaneous, of arm, 170, 174, 177, 179, 560
of the back, 171, 285
of calf, 232, 237, **245**, 566
of forearm, 170, 179, 180, 186, 560
of neck, 275
of palm, 194
perforating, 222, 389
of thigh, 211, 229, 232, 246, 380, 389, 563, 565
dental, 308, 310, 311
descendens, 298, 346
dorsal, of clitoris or penis, 404
ethmoidal, 56, 71
facial, **301**, 532, 569, 692
femoral, 218, 380, 563
frontal, 70
gastric, 609
genicular, 231, 232, 233, 243, 566, 567
genio-hyoid, 346
genito-femoral, 380, 563
glosso-pharyngeal, 320, 341, **533**, 571, 693
Nerves (*contd.*)—
gluteal, 225, 226; 389; 565
hæmorrhoidal, 404
hypoglossal, 320, 345, 535, 574, 692
ilio-hypogastric, 369
ilio-inguinal, 369
infra-orbital, 266, **311**
infrapatellar, 212, 237
infratrochlear, 71, 266
intercostal, 352, 561
intercosto-brachial, 168, 179, 353
interosseous, 191, **192**, **208**, 561
labial, 401
lacrimal, 70
laryngeal, 298, 343, 692
recurrent, 344, 606, 693, 702
to latissimus dorsi, **170**, 560
lingual, **309**, 319, 692
lumbar, 285, **379**, 562
mandibular, 60, **307**, 691
maxillary, 60, 310
median, 170, 183, 191, 198, 558
meningeal, 56, 289
mental, **267**, 309
musculo-cutaneous, of arm, 169, 183, 558
of leg, 244, 566
mylo-hyoid, 309, 319
nasal, 56, 266
naso-ciliary, 71
obturator, 234, 381, 387, 563
accessory, **381**, 563
to obturator internus, 227, 389, 565
occipital, 261, 275, 283
oculomotor, 58, 70, 511, 568
olfactory, 56, 578, 711
ophthalmic, 59
optic, **69**, 568, 710, 711
orbital, 311
palatine, 312
pectoral, **169**, 170, 558
perineal, 389, 397, 401, 404

Nerves (*contd.*)—
petrosal, **60**, 577, 578
phrenic, 348, **556**, 605, 606
plantar, 255, 256, 567
popliteal, 230, 232, 566, 567
of pterygoid canal, 60
pudendal, 227, 389, **403**
pulmonary, 573
to quadratus femoris, 226, 389, 565
radial, 170, 184, 191, 204, 560
to rhomboids, 173, **277**, 577
sacral, 286, 387, 564
saphenous, 218, 245
sciatic, 225, 388, 565
scrotal, 397
to serratus anterior, **169**, 278, 558
spheno-palatine, 311
spinal, 289, 554
spinosus, 307
splanchnic, 355, 579
pelvic, 388, 565, 580
to subclavius, **277**, 557
subcostal, 353, 369
subscapular, **170**, 560
supraclavicular, 162, **276**
supra-orbital, 70, **260**
suprascapular, 177, **277**, 558
supratrochlear, 70, **260**
sural, 231, 237, **245**, 251, 567
temporal, 307
thoracic, 171, 285, **351**, 561
thyro-hyoid, 346
thyroid, 578
tibial, 243, 249, 566, 567
trigeminal, **58**, 61, 531, 532
trochlear, 58, 61, 70, 511, 516, **568**
tympanic, 341
ulnar, 170, 183, 192, 198, 559
vagus, **342**, 533, 572, 606, 609
vestibular, 523, 535
zygomatic, 260, 266, **310**
Neuroglia, **462**, 685, 707
Node, atrio-ventricular, 416
sino-atrial, 416
Nodule, lentiform, 588
lymphoid, 633
Nose, 72, 268, **591**, 685, 689
Notches—
ethmoidal, 27
jugular, 41
nasal, 27
pre-occipital, 469
rhinal, 465
sciatic, 92
spheno-palatine, 31
supra-orbital, 34
trigeminal, 47
trochlear, 81
tympanic, 586
Notochord, 683
Nuclei, 461, 708
abducent, 532
accessory, 534
cochlear, 536
facial, 532
glosso-pharyngeal, 530, 533
hypoglossal, 534
oculomotor, 511
trigeminal, 512, 530, **531**
trochlear, 511
vagus, 530, 533
vestibular, 535
ambiguus, 526, 530, 533
amygdaloid, 490, **494**
arcuate, 527, 709
basal, 492
cardiac, 418, 533
caudate, 490, **493**, 710
of circumolivary bundle, 519, 526, 709
of corpus trapezoideum, 519
cuneatus, 522, 530
dentate, 515, 516
emboliformis, 516
fastigii, 516
globosus, 516
gracilis, 522, 530
habenulæ, 504
intercalatus, 540
interpeduncular, 505, 506
lateral, 525, 530

Nuclei (*contd.*)—
lentiform, 492, 710
olivary, **528**, 709
pontis, 467, 518, 709
postremus, 540
red, 510
subthalamic, 506
of tractus solitarius, 526, 530, 533
Nystagmus, 536

Obelion, 38
Obex, 539
Occipital bone, 28, **713**, **714**
Œsophagus, 326, 605, 608, **626**, 690, 693
Olive, 466, 521
Omentum, 629, **643**, **646**, 694, 698
Opening into lesser sac, 651
saphenous, 213
Opercula, 474, **711**
Ora serrata, 582
Orbit, 35, **64**, 689
Organ, spiral, 590
Os trigonum, 109, 114
Ova, 697
Ovary, **668**, 697

Pad, buccal, 263, 615
Palate, 39, **616**, 685, 689
Palatine bone, 31, 692, 714
Pancreas, **645**, 685, 694
Papilla, duodenal, 644
lacrimal, 269
sublingual, 616
Paradidymis, 663, 697
Paraganglia, 679
Parametrium, 670
Parietal bone, 27, 713
Par-oöphoron, 669, 697
Patella, 103, 153
Paths. *See* **Conduction**
Peduncles, cerebellar, inferior, 466, 521, **528**, 710
middle, 466, 518, **519**, 710
superior, 508, 515, **517**, 710
cerebral, 467, **507**, 710
Pelvis, 95, 381
Penis, 666, 696
Pericardium, 419, 685, 693, 698
Pericranium, 49
Perilymph, 590
Perineum, 393
Peritoneum, **646**, 685, 698
Pharynx, **621**, 685, 691
Philtrum, 615, 686
Pia mater, 288, 540, 685
Pits, olfactory, 689, 711
Placenta, 452, 686, **688**
Plate, basicranial, 714
cribriform, 30, 714
ethmoidal, 714
lateral, 684
tympanic, 29, **42**, 714
Platelets, blood, 675
Pleura, 326, **599**, 685, 698
Plexuses—
choroid, **489**, 490, 538, **539**, 710
nervous, aortic, 579
brachial, 168, 276, 557
cardiac, 579
carotid, 58, 577
cervical, 347, 556
coccygeal, 389
cœliac, 579
coronary, 579
gastric, 574
hypogastric, 386, 580
infra-orbital, 266
lumbar, 380, 562
œsophageal, 573, 609
patellar, 212
pelvic, 386, 580
pharyngeal, 344
pulmonary, 573
sacral, 388, 564
subsartorial, 219
tympanic, 342
vertebral, 578
venous, pampiniform, 390, **447**
pelvic, 393
pharyngeal, 297, 623
prostatic, 665
pterygoid, 306, 443

Plexuses, *venous* (*contd.*)—
suboccipital, 282
vertebral, 286, 287
Plica. *See also* **Folds**—
semilunaris, 269
Point, jugal, 36
mid-inguinal, 214, **363**
Pons, 466, 517, 709
Pouches, perineal, 396, 400
peritoneal, 638, 649
pharyngeal, 691
Precuneus, 479
Premaxilla, 690
Process, 5
ciliary, 582
clinoid, 29, **44**, 45
cochleariform, 586
fronto-nasal, 689
globular, 690
jugular, 28, 41
maxillary, 689, 692
nasal, 690
styloid, of skull, 28, **42**, 335, 692
vaginal, 649, 698
Proctodæum, 695
Pronation, 118, 136
Prostate, 665, 686
Protuberance, mental, 32
occipital, 38, 47
Pterion, 35
Pudendum muliebre, 397, 668
Pulvinar, 502, 503
Punctum lacrimale, 269
Putamen, 493
Pylorus, 629, 630

Radiation, auditory, 537
optic, 487, **513**
temporal, 497
Radius, 82
Rami communicantes, 346, 354, 379, 576, **577**
conjoined, 92, 93
Recess, epitympanic, 585
peritoneal, 632, 637
pleural, 600
Recess (*contd.*)—
sacciform, 135
spheno-ethmoidal, 72, 592
Rectum, 637, 695
Region, subthalamic, 506
Respiration, 127
Retina, **582**, 685, 710, 711
Retinacula, extensor, 204; 238
flexor, 193, 194; 246
of patella, 151
peroneal, 239
Rhinencephalon, 484
Ribs, 20, 127, 713
Ridge, genital, 697
interureteric, 660
pronator, 81
trapezoid, 74
Rima glottidis, 596
vestibuli, 596
Ring, femoral, 219
fibro-cartilaginous, 586
inguinal, 367

Sac, endolymphatic, 590
lacrimal, 271, 689
of peritoneum, 651, 693
yolk, 681, 682, 687
Saccule of ear, 590
of larynx, 596
Sacrum, 13, 18, 712
Salpinx, 650
Scalæ, 590
Scalp, 258
Scapula, 75
Sclera, 66, 268, **581**, 712
Scrotum, 661, 696
Sella turcica, 44
Sensations, 549 *et seq.*
Septa—
femoral, 219
intermuscular, of arm, 180
of leg, 238, 246
of thigh, 213
lucidum, 476, **488**, 710
recto-vesical, 385
transversum, 694, **699**
Sesamoid bones, 2, 90, 114, 196

Sheath, carotid, 324
of eyeball, 66
femoral, 219
fibrous flexor, 195, 251
of rectus, 366
synovial, 162, 241
in foot, 242, 251, 254
in hand, 189, 200, 203, 205
Sinuses, 5
air, 27, **62,** 63, **312**
anal, 638
arcuatus, 691
carotid, 335
of epididymis, 662
precervical, 693
prostatic, 660
tarsi, 109
venosus, 700, 703, 704
venosus scleræ, 581
venous, coronary, 417, 704
cranial, 51, 708
vertebral, 287
Skeleton, 1, 712
Skin, 685
Skull, **34,** 685, 713, 714
Slit, nasal, 43
Smegma, 667
"Snuff-box", 203
Somites, 684
Sound, conduction, 536
Sounds of cardiac valves, 415
Spaces—
extradural, 287
of irido-corneal angle, 581
quadrilateral, 176
retropharyngeal, 324
retropubic, 386
subarachnoid, 288, 541
subdural, 287
suprasternal, 291
triangular, 177
zonular, 583
Spermatozoa, 697
Sphenoid bone, 29, 713, 714
Spines, 5
ethmoidal, 44
nasal, 35, 39
Spines (*contd.*)—
suprameatal, 36
trochlear, 64
Spleen, **675,** 685, 693
Stalk, allantoic, 681, 687
Stapes, 588
Status lymphaticus, 677
Stephanion, 35
Sternum, **18,** 713
Stomach, 628, 693
Stomodæum, 689
Streak, primitive, 681
Striæ—
auditory, 519, **538**
habenularis, 489, **505**
longitudinal, 485
semicircularis, 490, **494**
visual, 475
Stye, 270
Substance or **Substantia**—
ferruginea, 519, 540
gelatinosa, 530, **544**
nigra, 467, **510**
perforated, anterior, 469, **485,** 711
posterior, 468, **506**
reticularis, 524, 527
Sulci, 5. *See also* **Groove**
of cerebral cortex, 463; 470 *et seq.*
hypothalamic, 501, 503, 709
oculo-nasal, 690
terminalis, of heart, 411
of tongue, 618, 692
tympanic, 586
valleculæ, 515
Supination, 118, **186**
Sustentaculum tali, 109
Sutural bones, 713
Suture, 115, 714
metopic, 35, 715
Swallowing, 625
Symphysis of mandible, 32
pubic, 144
Synchondrosis, 116
Syndesmosis, 115
Synergists, 161

Synostosis, 115
Synovia, 115, 117, 141, 162

Tæniæ pontis, 506
Tail-gut, 695
Tapetum, 487
Tarsal bones, 108, 113
Taste-buds, 619, 686
Tears, 271
Tectum, 467, **507**
Teeth, **619**, 685
Tegmen tympani, 46
Tegmentum, 467, **508**, 510
Tela chorioidea, **489**, **539**, 708, 710
Temple, 258
Temporal bone, **28**, 713, 714
Tendo calcaneus, 247
Tendon, 161
  conjoint, 366
Tentorium cerebelli, 50, 708
Testis, **662**, 697, 698
Thalamus, 501
Thorax, 26, 328, 349, 599
Thymus, 324, 602, **676**, 686, 691
  accessory, 677
Tibia, 103
Tissue, erectile, 666
Tongue, **617**, 685, 692
Tonsil, *the*, 622, 691
  cerebellar, 515
  lingual, 617
  naso-pharyngeal, 622
Trabeculæ carneæ, 413, 415
Trachea, 326, **598**, 605, 685, 691, 693
Tracts. *See also* **Bundles** and **Fasciculi**—
  ilio-tibial, 212
  mamillo-tegmental, 505
  olfactory, **484**, 711
  olivo-cerebellar, 527, 528
  optic, 408, 512
  solitarius, 525, 534, 709
  of spinal cord, 546
  spinal, of trigeminal, 521, 531
Tragus, 260, 583
Triangles and **Trigones**—
  of auscultation, 172
  collateral, 491
  habenular, 504
  inguinal, 368
  lumbar, 368
  suprameatal, 36
  vertebro-costal, 372
Trophoblast, 680
Truncus arteriosus, 701, 703
Trunk, costo-cervical, 334
  lumbo-sacral, 381, 387, 564
  pulmonary, 423, 704
  sympathetic, 346, 354, 378, 386, **577**
  thyro-cervical, 333
Tube, neural, 682, 708
  pharyngo-tympanic, 42, **587** 685, 691, 714
  uterine, 668, 697
Tuber, tubercle, tuberosity, 5
  adductor, 100
  carotid, 7
  cinereum, 468, **505**
  conoid, 74
  cuneate, 522
  deltoid, 74, 79
  genial, 32
  gluteal, 101
  gracile, 522
  impar, 690, 692
  jugular, 47
  mental, 32
  omentale, 640, 645
  peroneal, 110, 237
  pharyngeal, 40
  pterygoid, 40, 41
  quadrate, 99
  scalene, 21
  sellæ, 44
  trigeminal, 524
Tubules, seminiferous, 663, 697
Tunica vaginalis testis, 662, 685, 698
Tympanum, 585, 691

Ulna, 80

Umbilicus, 361, 682
Umbo, 587
Uncus, 481, 711
Urachus, 695
Ureter, 656, 697
Urethra, **660**, 685, 696
Uterus, 669, 697
Utricle of ear, 590
  prostatic, 697
Uvula palatina, 616
  vesicæ, 659, 665

Vagina, 671, 697
Vallecula cerebelli, 515
  cerebri, 468
  epiglottic, 594
Valves, anal, 638, 695
  of heart, 411 *et seq.*; 704
  ileo-colic, 635
  spiral, 645
  of vena cava, 411, 453, 454
Vas deferens, 663, 697
Veins and **Venæ**, 441, 705
  anastomotic, 475
  auricular, 262
  axillary, 167, **444**
  azygos, 338, **358**, 378, 442, 706, 707
  basal, 475
  basilic, 179, 186, 445
  basi-vertebral, 287
  cardiac, 417, 418
  cava inferior, **445**, 705, 706
    superior, 442, **603**, 707
  cephalic, 168, 178, 185, 445, 707
  cerebral, 475, 477, 479, 482, 490, 708
  choroid, 490
  circumflex femoral, 221
  circumflex iliac, 371
  cordis minimæ, 417
  cubital, median, 179, 445
  deep cervical, 282
  diploic, 54
  emissary, 51, 52, 54, 262
  facial, 267, 268, 443, 444
Veins and **Venæ** (*contd.*)—
  femoral, 221, **449**
  gastric, 451
  gastro-epiploic, 451
  hemi-azygos, 378, 442, 609, 707
  hepatic, 447, 705
  iliac, 393, 447, 448, 706
  ilio-lumbar, 377, 447
  innominate, 340, 442, 602, 707
  intercostal, anterior, 357
    posterior, 357, 706
      first, 334
    superior, **358**, 603, 707
  intervertebral, 287
  jugular, anterior, **291**, 444, 707
    external, **275**, 444, 707
    internal, **338**, 443, 707
  lingual, 319
  lumbar, 377, 447, 706, 707
  mammary, 355
  maxillary, 307, 443
  median, 186, 445
  meningeal, 55
  mesenteric, 450, 451, 705
  of nose, 443
  oblique, of left atrium, 418, 707
  obturator, abnormal, 370, 392
  occipital, 262, 282
  ophthalmic, 69, 708
  ovarian, 390, 447, 707
  pancreatico-duodenal, 451
  pharyngeal, 297
  phrenic, 447
  popliteal, **230**, 448
  portal, 450, 705
  postcardinal, 706
  precardinal, 707
  pre-central, 447
  prepyloric, **451**, 630
  primary head, 707
  profunda femoris, 221, 236, 448
  pubic, 448
  pulmonary, 441, 704
  renal, 447, 706
  retinæ centralis, 504
  sacral, median, 390, 448

Veins and **Venæ** (*contd.*)—
saphenous, 211, 231, 238, **245**, 449
spheno-palatine, 443
spinal, 287, 545
splenic, 450, 705
striate, 475
subcardinal, 706
subclavian, **274**, 443
subcostal, 378
supracardinal, 707
supra-orbital, 262
suprarenal, 447, 706
suprascapular, 274
supratrochlear, 262
temporal, 262
testicular, 447, 707
thalamo-striate, 490
thyroid, 297, **325**, 603
transverse cervical, 274
umbilical, 452, 454, 700, 705
vertebral, 332, 334
vitelline, 700, 705
vorticosæ, 504
Vela, medullary, 515, **516**, 709
Ventricle, fourth, 537, 709
lateral, 490, 710
third, 500, 710
Vertebræ, 5, 17, 685, 712
Vesicles, cerebral, 683, 709
optic, 711
otic, 712
seminal, 664, 697
umbilical. *See* **Sac**, yolk
Vestibule, aortic, 414
of nose, 592
of vagina, 399
Vestige of vaginal process, 367, 698
Villi, arachnoid, 541
chorionic, 688
intestinal, 633
synovial, 117
Vincula, 201, 254
Vitellus, 687
Vomer, **30**, 72, 689, 714
Vulva, 397, 668

Wax, ear, 584

Zona orbicularis, 145
Zonule, ciliary, 583
Zygoma, 28
Zygomatic bone, 32, 692, 714
Zygote, 680, 686

PRINTED IN GREAT BRITAIN BY R. & R. CLARK, LTD., EDINBURGH

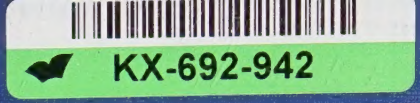
KX-692-942